

Treatment Planning Considerations in Congenitally Missing Maxillary Lateral Incisor: The Role of Orthodontics (In Orthodontic Aspect)

Jae Hyun Park^a; Sakiko Okadakage^b; Yasumori Sato^c; Yutaka Akamatsu^d; Kiyoshi Tai^e

^aJae Hyun Park, DMD, MSD, MS, PhD, Associate Professor and Chair, Postgraduate Orthodontic Program, Arizona School of Dentistry & Oral Health, A.T. Still University, Mesa, USA and International Scholar, College of Dentistry, Kyung Hee University, Seoul, South Korea.

^bSakiko Okadakage, DDS, private practice of orthodontics, Okayama, Japan.

^cYasumori Sato, DDS, PhD, private practice of orthodontic, Okayama, Japan.

^dYutaka Akamatsu, DDS, PhD, private practice of general dentistry, Okayama, Japan.

^eKiyoshi Tai, DDS, Visiting Adjunct assistant professor, Postgraduate Orthodontic Program, Arizona School of Dentistry & Oral Health, A.T. Still University, Mesa, AZ, and private practice of orthodontics, Okayama, Japan.

Corresponding author: Dr. Jae Hyun Park, Postgraduate Orthodontic Program, Arizona School of Dentistry & Oral Health, A.T. Still University, 5855 East Still Circle, Mesa, AZ 85206, USA. (e-mail: JPark@atsu.edu)

ABSTRACT

Clinicians agree that tooth agenesis regardless of gender or race becomes more prominent in recent societies. The congenital absence of one or more maxillary lateral incisors is a challenge to effective treatment planning for the restorative dentist. The one-sided orthodontic approach of moving canines mesially to eliminate restorative procedures also leads to compromise. Adult patients presenting with malocclusions, missing lateral incisors, and anterior crowding, who request esthetic solutions without proper orthodontic treatment will get compromised results. The avoidance of establishing a stable occlusion, proper alignment and proper axial inclination of the teeth compromises esthetic and periodontal results. Evaluation of anterior smile esthetics must include both static and dynamic evaluations of frontal and profile views to optimize both dental and facial appearance. This article presents how orthodontics is related with other specialties in treating congenitally missing lateral incisor. One case is used to illustrate how orthodontic treatment is progressed in collaboration with other specialists.

CLINICAL SIGNIFICANCE

Patients with missing teeth, crowding, midline deviation, unesthetic gingival contours, or other restorative needs may require the interaction between different specialists. For the successful treatment of orthodontic-restorative patients, interdisciplinary team management is vital.

INTRODUCTION

Nowadays demands and expectations of esthetic dentistry are increasingly high. To provide esthetic anterior tooth shape and correct agenesis cases, we must inform patients of their total dental needs, not just those limited specialty. To integrate and coordinate treatment, and not limit treatment to an isolated specialty, we need to present our patients with total treatment approaches, to maximize function, esthetics, and oral health. In many of our routine dental malocclusions, orthodontic treatment alone may be

limiting for ideal esthetic and functional dental occlusions. We must evaluate the facial profile, smile line, buccal corridor, black triangles, lip line, and crowding. One-sided approaches to multifaceted problems often produce compromise results.

Agenesis of one or more teeth constitutes one of the most common developmental anomalies in man.¹ Familial tooth agenesis is transmitted as an autosomal dominant, recessive or X-linked condition.² Reported incidence of permanent tooth agenesis varies from 1.6 to 9.6%, excluding third molars, which occurs in 20% of the population.³ Studies vary on the second most commonly missing teeth. Some studies⁴⁻⁸ have shown that it is the maxillary lateral incisor, whereas others⁹⁻¹² believe that mandibular second premolar agenesis has a higher incidence. Muller et al⁵ found an interesting correlation that maxillary lateral incisors are the most frequently missing teeth when only 1 or 2 teeth are absent, whereas second premolars are the most frequently missing teeth when more than 2 teeth are absent.

Maxillary lateral incisors show the highest genetic component of variability in the general population, whereas the smallest genetic influence on size of an anterior tooth is seen in the canine. Numerous twin studies¹³⁻¹⁵ illustrate hereditary factors in the mesio-distal dimensions of the teeth, and populations with chromosomal aberrations, such as occurs in Down's syndrome, display a generalized reduction in tooth size and number.¹⁶ Tooth agenesis is more frequent in the parents and siblings of individuals with missing teeth than in the population as a whole, a finding that supports the hypothesis that this condition is genetically determined.^{17,18}

TREATMENT OF THE MISSING ANTERIOR TEETH

When examining the esthetics of the anterior teeth and smile, the clinician should be aware of the morphology of the gingival contours, tooth contacts, tooth morphology, and tooth-size problems. To obtain ideal esthetic results, worn incisal edges, tooth shape, incisal contact, the contours of gingival margins, and black triangles should be considered before starting orthodontic treatment. The decision to re-shape or add tooth structure should be evaluated considering the width-to-length ratios of the Golden Proportion.¹⁹ The length of the central incisors should be divided into the width to obtain the proper percentage, with the ideal width being 75-80% of the length. The longer teeth in this range appear more feminine, and shorter teeth appear more masculine.

The question of what determines the shape and thickness of the architecture of the scalloped gingiva, the papilla and the thickness of the labial and lingual alveolar bone, is of interest. Clinically, it appears that long tapered triangular maxillary incisors

have more delicate thin arched gingival tissue, with longer delicate papilla, thin bone and a smaller more incisal contact point, as opposed to the more rectangular-shaped incisors, with thick gingiva and a flatter, wide, free gingival margin. These latter teeth have broad contacts. As a generalization, the more rectangular the teeth are, the thicker the gingival housing them and the alveolus.

The smile line and lip shape also should be evaluated. The position of the lip attachment at the nasolabial junction has a profound effect on the esthetics of the profile. We all need an understanding of facial proportions and facial esthetics to provide our patients with a comprehensive treatment plan.

There has been ongoing controversy in orthodontic and restorative dentistry over the treatment of agenesis cases, especially of the lateral incisors. Restorative dentists were opposed to mesial movement of the maxillary canine into the lateral incisor space, since this precluded the potential for developing canine-protected occlusion, because it places the canine in direct opposition to the mandibular lateral incisor. Stuart and Stallard,²⁰ and D'Amico²¹ advocated canine-protected occlusion in all dentitions. However, Nordquist and McNeill²² justified the mesial movement of canines into lateral incisor space which provided many orthodontists with the rationale for space closure. They stated that no difference existed in adequacy of occlusal function between canine-protected and group function, and no relation with periodontal status existed between the two groups. They also stated that treatment should be designed to eliminate prostheses, which contributed to accumulation of plaque and irritation.

Furthermore, studies^{22,23} have shown that two groups did not differ significantly in respect to occlusal function and the prevalence of temporomandibular dysfunction. Many orthodontic studies have shown that reshaping maxillary canines to resemble lateral incisors greatly improves esthetics.²⁴⁻²⁸

When maxillary lateral incisors are missing, there are several factors to consider treating patients with space opening or space closure. The type malocclusion, crowding/spacing, tooth size relationships, canine position, shape and color of canine, and maxillary lip length.²⁴⁻³⁰

The choice between these two modes of treatment should not be made empirically. In most instances the presence or absence of major occlusion problems serves as the primary criterion for either space closure or space opening.^{26,27} Lateral incisor spaces should be closed in cases with malocclusions which require the extraction of permanent mandibular teeth. Mandibular extractions may be indicated to relieve anterior or posterior arch length deficiency, to reduce mandibular dentoalveolar protrusion or to compensate for a Class II molar relationship.

In some orthodontic patients may be missing several permanent teeth including maxillary lateral incisors. If teeth have been missing for several years, the remaining teeth may have drifted. In these patients, orthodontists and restorative dentists may not be aware of restorative requirements or eventual restorative treatment plan. For these types of patients, it is recommended to predetermine the final occlusal and restorative outcomes by completing diagnostic wax set-ups.³¹ In addition, the trial set-up will allow identification of tooth surfaces which require functional and esthetic reduction so that equilibration may be initiated either at the beginning of or during the orthodontic treatment.

Diagnosing and treating growing children who are missing lateral incisors are a problem for many clinicians. If the patient and their parents decide on future implants, it is important to determine that the majority of vertical facial growth and tooth eruption is completed before implant placement.²⁹ Girls mature faster than boys, and their adolescent growth spurt occurs sooner. After completion of growth in stature (height), sequential cephalometric and hand-wrist radiographs verify the cessation of facial growth over a time-frame of approximately every six months to one year. Explanation of the sequence of treatment in cases of agenesis of anterior teeth must be explained to both the patient and their parents very thoroughly. They must realize that orthodontic treatment is the beginning of the sequence. The sequencing of periodontal therapy and final restorations should all be explained to the parents and patient. All treatment options should be discussed with the interdisciplinary team, just as all the options are explained in the orthodontic treatment phase.

ORTHODONTIC CONSIDERATIONS IN TREATMENT OF THE MISSING MAXILLARY LATERAL INCISORS

In a long-term clinical and radiographic follow-up study, by Thordarson et al²⁸ adolescent patients who had extensive remodeling of the permanent canines were evaluated. The canines were ground to the shape of lateral incisors as part of the orthodontic treatment and the patients were recalled after 10-15 years for clinical examination. The study demonstrated that extensive cuspal, labial, lingual, and interproximal recontouring, by the grinding of young teeth associated with orthodontic treatment, can be performed without discomfort to the patient and with only minor or no long-term clinical and radiographic reactions. They stated that this finding is encouraging, since better long-term esthetic results and healthier periodontal conditions may be achieved by recontouring canines, rather than by replacing missing incisors with

prosthetic appliances.

However, many esthetic dentists disagree with this conclusion. Isler,³² discussing facial beauty, stated that the bone is the under-structure, the scaffolding, and the major determinant of facial beauty. He also mentioned that a good smile is only partly about the teeth; it is primarily about the way in which the teeth appear to be placed in the face. Therefore, the design foundation of the smile is the very foundation of the teeth themselves, that is, the maxillary alveolar arch. Obviously, if a patient has bilateral agenesis of maxillary lateral incisors, the bone volume of the maxilla will be decreased. By erupting maxillary canines into the lateral incisor space, alveolar bone is developed, and by distalizing the buccal segments for the restoration of the lateral incisors, we can maintain the volume of the maxillary bone.^{29,33} In the canine substitution case, the alveolar canine buttressing of the canine roots is displayed anteriorly where the lateral incisors should be, and the dental arch narrows distally. With space closure, the arch form is condensed and constricted. Obvious gingival and tooth esthetics may be improved with gingival margin recontouring, and the reshaping of the maxillary canines. However, even if the canines esthetically are recontoured, the dentoalveolar arch curvature cannot be changed. The patient in full smile displays buccal corridor, since arch circumference is diminished with closure of the lateral incisor spaces. There is less dentoalveolar bone to work with to create an esthetic smile.

Henns³⁴ reported that the canine eminence is lost from its normal position which canines were used as laterals as the eminence accompanies the canine when it is moved. However, his study showed that the difference of the canine eminence did not exceed a 1.5 mm when the mean arch form recording of the Class I extraction group and the canine substitution group were superimposed. According to his evaluation using the upper study casts, the poor esthetic appearance of the canine eminence may have been exaggerated.

CASE REPORT

The 38-year-old Japanese female had difficulty in biting and desired to improve her facial esthetics. She had facial symmetry with a convex profile (Figure 1). She presented with an end-on Class II molar relationship on the right side and a mutilated molar relationship on the left side due to the loss of the mandibular left first molar. The missing area was replaced by three-unit bridge. The patient was also missing the

maxillary left lateral incisor and the maxillary dental midline was deviated to the left by 3.0 mm relative to the facial midline. Due to the loss of the maxillary left lateral incisor there were severe gingival marginal discrepancies between the maxillary left central incisor and canine. The lingually displaced mandibular right lateral incisor also showed gingival marginal discrepancy. The maxillary arch had mild crowding and the mandibular arch had severe anterior crowding. The maxillary left first premolar and mandibular left first premolar were in crossbite, and the maxillary right second premolar and the mandibular right second premolar were in Brodie bite. The patient had several restorations in both arches and had 2 mm overjet and 70% overbite. The maxillary left central incisor showed discolorization. The maxillary right lateral incisor and the first premolar exposed metal margins of porcelain-fused-to-metal (PFM) restorations due to gingival recession. The maxillary right first molar also showed gingival recession (Figure 2).

The panoramic radiograph showed no caries or pathologies. The patient received root canal treatments on the maxillary right and left first molars, maxillary right first premolar, maxillary right lateral incisor, maxillary left central incisor, mandibular central incisors and mandibular right first molar. The maxillary and mandibular third molars were missing (Figure 3A). The cephalometric analysis revealed the patient had a skeletal Class II ($ANB = 6.4^\circ$). The maxillary incisors were slightly proclined ($U1$ to $FH: 113.5^\circ$) and the mandibular incisors showed normal inclination ($IMPA: 94.1^\circ$). The upper and lower lips were slightly protrusive (Figure 3B). The etiology of the malocclusion was determined to be a combination of heredity and environmental factors.

Before orthodontic treatment, the patient was referred to a general dentist for restorative dentistry consultation as well as a periodontist for the evaluation of the existing periodontal condition especially thin attached gingiva on the mandibular canines. One treatment option was to open space to replace the missing maxillary left lateral incisor. However, this treatment plan was not chosen because it can procline the maxillary incisors and increase protrusive lips. Furthermore, the patient was reluctant to undergo a restoration for a single tooth space after orthodontic treatment. The other treatment option was to extract the maxillary right first premolar and mandibular right second premolar which had restorations. In addition, the three-unit bridge on the left posterior segment was planned to be removed to mesialize the left mandibular second molar using the temporary anchorage device (TAD). However, the patient did not want to extract a tooth in the mandibular arch and did not want to install TAD during treatment. The last treatment option was to extract the maxillary right lateral incisor to

correct the maxillary dental midline and slenderize the mandibular incisors to relieve the crowding. The patient was explained to replace the mandibular first molar after orthodontic treatment. However, severe gingival marginal discrepancies would result in a compromised gingival architecture. The patient agreed to choose this treatment plan.

Full-fixed .022" Tip-Edge (TP Orthodontics, Inc., LaPorte, IN) appliances were placed on both arches. Before placing the appliances, the left mandibular three-unit bridge was removed and temporary crowns were delivered. This preadjusted edgewise appliance permits crown tipping in one direction yet creates anchorage through bodily movement in the other. This appliance offers easy rotation and angulation control using auxiliaries like rotating springs and uprighting springs. The Tip-Edge bracket is derived from a single .022" straight-wire bracket merely by cutting away two diametrically opposed corners from the archwire slot. The addition of rotation wings and a vertical slot enhances both rotational and tip control. This unique arch slot can close the extraction space without extruding incisors by tipping in the mesiodistal direction in early period of treatment. Brackets have appropriate torque and in-out compensation to assure controlled finishing with rectangular archwires and upright springs.³⁵

To substitute canines in the position of missing laterals, special bracket placement was necessary for both maxillary canines and the first premolars. The lateral incisor brackets were bonded to the canines and the canine brackets were placed on the first premolars. Before bonding the lateral incisor bracket on the canine, the labial surface was reshaped for the bracket adaptation. It is necessary to position these brackets gingivally to permit the recontouring of the canines required for esthetics and function. To make the canine appear less curved and more like a lateral incisor, the bracket was placed more distally in the center of the canine rather than at the height of contour (Figure 4A). In addition, a canine bracket was placed on the first premolar in the same mesiodistal position (more distally) in which it is placed on the canine. However, to improve the interproximal contact points, offset bonds (in-out) was needed between the central incisor and canine (Figure 4B, C).

Maxillary and mandibular arches start with .016" high tensile stainless steel archwires with mild bite opening bends mesial to the first molars. To make a room for the lingually displaced mandibular right lateral incisor and to prevent proclination of the mandibular anterior teeth, interproximal reduction was performed in the anterior segment. At the leveling stage, .016" nickel titanium archwire was used in conjunction with the main .016" high tensile stainless steel archwire to speed the alignment of the mandibular anterior teeth. In the maxillary arch, space was closed using a .022" round

archwire. While protracting the maxillary right canine, the maxillary dental midline was slightly overcorrected because the patient did not wear elastics (Figure 5). During treatment enamel was recontoured to flatten and create an incisal edge on the canine cusp tip. To eliminate traumatic occlusion of the mandibular lateral incisors with the lingual surfaces of the canines and to establish a balanced occlusion, the lingual cusps of the maxillary canines and first premolars were recontoured (Figure 6).²⁵ At finishing stage, .0215" x .028" archwires were used for torquing control. At this stage, the patient was referred to the restorative dentist to evaluate space for the three-unit bridge on the left posterior segment. The patient was instructed to wear elastics all the time to correct dental midline. Uprighting springs were used to exert continuous, uprighting and torquing forces on the anterior teeth to ideal angulations.

Total treatment time was 23 months. Following the treatment, a 0.0175 inch twistflex wire fixed retainer was bonded from first premolar-to-first premolar on the mandibular arch. The mandibular central incisors could not be bonded successfully with the fixed retainer due to ceramic crowns which were fabricated after debonding. Mandibular Essix retainer also delivered as removable retainer. On the maxillary arch, Essix retainer was delivered. The patient was instructed to wear them 24 hours per day for one year, and then night time only after one year. Recall visits for retainer checks were given at one, three, and six months for the first year. To ensure continued satisfactory post-treatment alignment of the mandibular and maxillary anterior dentition, the use of fixed or removable retainers is recommended indefinitely. At the end of orthodontic treatment, the patient was referred to her general dentist for the restorative treatment and the periodontist for gingival margin discrepancies.

After the treatment, the patient's profile has been improved (Figure 7). The severe mandibular crowding has been relieved. Dental midlines were aligned with the facial midline, overbite and overjet has been improved (Figures 8 and 9). The panoramic radiograph showed proper space closure and acceptable root parallelism, with no signs of bone or root resorption (Figure 10A). Cephalometric analysis and revealed no significant skeletal changes (ANB= 6.2°). The maxillary incisors showed decent inclination (U1 to FH: 108.9°) and the mandibular incisors showed no significant changes (IMPA: 92.4°). Her upper and lower lip profile has been improved. (Figures 10B and 11, Table I). After six years of retention, the patient showed pretty stable occlusion (Figures 12-14).

DISCUSSION

From an esthetic viewpoint, observing the natural anatomy of the maxillary lateral incisor and the maxillary canine, the marked prominence of the canine roots at the corner of the mouth is quite obvious. The natural topography shows labial root prominence of the central incisor, the labial concavity of the lateral incisor root, and the labial prominence of the canine root. The next natural observation is the gingival scalloping height contours of the natural dentition. The gingival tissue is higher on the central incisors, drops down on the lateral incisors, is higher again for the canines, and again drops down on the first premolar. These heights of contour are critical for the esthetic smiles of our patients.³⁶

Placing the dentition into ideal occlusion in agenesis cases, especially involving the lateral incisors, is critical to obtain an ideal esthetic result. With ectopic canine positions in agenesis of unilateral or bilateral maxillary lateral incisor cases, the objective is to create space or to allow the permanent canines to erupt mesially adjacent to the maxillary central incisors. The periosteal matrix (the tooth and periodontal ligament) is responsible for the form, size and shape of the skeletal unit (the alveolar bone), and its maintenance. Basically, the alveolar bone exists if the tooth and periodontal ligament exist.

If there is no tooth to erupt into an area of the dental arch, alveolar bone cannot be formed. As a result, large defect in the alveolar process can make future implant placement almost impossible. As the canine erupts into the lateral incisor space, alveolar bone will form in a 2-4 mm area adjacent to the erupting tooth. It is therefore important for a tooth to erupt in the eventual implant area.

Carlson³⁷ has shown that, after tooth extraction, the maxillary anterior labio-lingual width is reduced by 23% in the first 6 months and, after 5 years, an additional 11% loss in ridge-width occurs. After tooth extraction, the ridge-width will narrow by approximately 34% over 5 years.

Cases in which canines erupt in close proximity to central incisors are best treated by space closure. However, cases presenting with Class I buccal occlusions and neither mandibular arch length deficiencies nor dentoalveolar protrusions favor treatment by orthodontic space opening and subsequent prosthetic lateral incisor replacements. In these patients, when maxillary lateral incisors are congenitally absent, spaces are created to allow ectopic canines to erupt adjacent to the central incisors. As the permanent canine is moved distally to create space for a lateral incisor implant or bridge, an alveolar ridge is created. The labio-lingual ridge width of bone over time in orthodontic cases of canines moved distally was addressed by a study by Kokich.³⁸ The amount of bone loss was less than 1% over 4 years, compared with the Carlson study of

extracted teeth which showed 34%. Kokich concluded that, if the edentulous alveolar ridge was created by orthodontic separation of two teeth, little resorptive change will occur over time.

Obviously, in many of Class II malocclusion cases with mesial eruption of the canines into the lateral incisor position, extensive distalization of the buccal dentition is required to create the mesial-distal space and to provide an alveolar ridge for esthetic lateral incisor pontic placement. The second molars have to be distalized into a Class I position, the first molars, the second premolars, the first premolars and, finally, the maxillary canines are distalized into a Class I occlusion, to provide the mesial-distal space necessary for achieving ideal restorative dentistry. It is obviously much easier to move the canines mesially, but in some cases if space opening is required, it is mechanically difficult and sometimes limited by the relative alveolar concavity between the canine and first premolar roots.²⁶

In creating the proper mesial-distal space for lateral incisor restoration, the clinician should properly position the central incisors with respect to the midpoint of the cupid's bow of the philtrum of the upper lip and upper face, and to have maxillary and mandibular midlines coincident. Obviously, the more important of these two is the maxillary midline to the upper lip and face. Radiographs are then taken of the created ridge and root positions of the central incisors and the canines. The root position must be evaluated by both the orthodontist and the surgeon in implant cases or restorative cases.

If patients require restorations after orthodontics, the restorative dentist should be involved in the finishing process. It is advantageous to require input from the restorative dentist during final stage of orthodontic treatment, especially in areas where restorations are planned. By this procedure, the patient benefit from the evaluation of the final results from the restorative dentist. In addition, the orthodontist and restorative dentist will be more aware of the treatment possibilities for the orthodontic-restorative patient.³¹

CONCLUSIONS

In treating congenitally missing lateral incisors, the two major alternatives, orthodontic space closure or space opening for prosthodontic replacements, can both compromise esthetics, periodontal health, and function. If orthodontists and other specialists including restorative dentists establish realistic objectives, communicate the sequence of treatment, interact during treatment, evaluate dental and gingival esthetics, and position

teeth to facilitate proper restorative treatment, the esthetics and long-term dental health of the overall treatment will be greatly enhanced.

REFERENCES

1. Shapiro SD, Farrington FH. A potpourri of syndromes with anomalies of dentition. In: Jorgenson RJ editors. Dentition genetic effects. Birth Defects: Original Article Series. New York: March of Dimes Birth Defects Foundation; 1983;129–40.
2. Burzynski NJ, Escobar VH. Classification and genetics of numeric anomalies of dentition. Birth Defects 1983;19:95-106.
3. Graber LW. Congenital absence of teeth: a review with emphasis on inheritance pattern. J Am Dent Assoc 1978;96:266-75.
4. Brekhus P, Oliver C, Montelius G. A study of the pattern and combination of congenitally missing teeth in man. J Dent Res 1944;23:117–31.
5. Muller TP, Hill IN, Peterson AC, Blayney JR. A survey of congenitally missing permanent teeth. J Am Dent Assoc 1970;81:101–7.
6. Baum BJ, Cohen MM. Studies on agenesis in the permanent dentition. Am J Phys Anthropol 1971;35:125–8.
7. Wojtowicz N, Kondrat-Wodzicka H. Congenital absence of teeth and malocclusions. Czas Stomatol 1972;25:969–77.
8. Malik SA. Missing and rudimentary upper lateral incisors: a statistical survey. J Dent 1972;1:25–7.
9. Grahnen H. Hypodontia in the permanent dentition: a clinical and genetical investigation. Odont Revy 1956;7:1–100.
10. Glenn FB. Incidence of congenitally missing permanent teeth in a private pedodontic practice. ASDC J Dent Child 1961;28:317–20.
11. Serrano J. Oligodontia and fusion. Oral Surg Oral Med Oral Pathol 1972;34:691–2.
12. Hundstadbraten K. Hypodontia in the permanent dentition. ASDC J Dent Child 1973;40:31–3.
13. Osborne RH, Horowitz SL, De George FV. Genetic variation in tooth dimensions: a twin study of the permanent anterior teeth. Am J Hum Genet 1958;10:350–6.

14. Ludwig FJ. The mandibular second premolars: morphologic variation and inheritance. *J Dent Res* 1957;36:263-73.
15. Lundstrom A. Tooth morphology as a basis for distinguishing monozygotic twins. *Am J Hum Genet* 1963;15:34-43.
16. Arvystas MG, Cohen MM. Mesiodistal crown diameters of the permanent teeth in Down's syndrome. *Am J Mental Defic* 1970;74:563-7.
17. Goose DH. Preliminary study of tooth size in families. *J Dent Res* 1967;46:959-62.
18. Lewis DW, Grainger RM. Sex-linked inheritance of tooth size. A family study. *Arch Oral Biol* 1967;12:539-44.
19. Ricketts RM. The biologic significance of the divine proportion and Fibonacci series. *Am J Orthod* 1982;81:351-70.
20. Stuart CE, Stallard H. Diagnosis and treatment of occlusal relations of the teeth. *Texas Dent J* 1957;75:430.
21. D'Amico A. The canine teeth-normal functional relation of the natural teeth of man. *J South Calif Dent Assoc* 1958;26:200.
22. Nordquist GG, McNeill RW. Orthodontic vs. restorative treatment of the congenitally absent lateral incisor – long term periodontal and occlusal evaluation. *J Periodontol* 1975;46:139-43.
23. Senty EL. The maxillary cuspid and missing lateral incisors: esthetics and occlusion. *Angle Orthod* 1976;46:365-71.
24. Carlson H. Suggested treatment for missing lateral incisor cases. *Angle Orthod* 1952;22:205-16.
25. Tuverson DL. Orthodontic treatment using canines in place of missing maxillary lateral incisors. *Am J Orthod* 1970;58:109-27.
26. McNeill RW, Joondeph DR. Congenitally absent maxillary lateral incisors: treatment planning consideration. *Angle Orthod* 1973;43:24-9.
27. Zachrisson BU. Improving orthodontic results in cases with maxillary incisors missing. *Am J Orthod* 1978;73:274-89.
28. Thordarson A, Zachrisson BU, Mjor IA. Remodeling of canines to the shape of lateral incisors by grinding: A long-term clinical and radiographic evaluation. *Am J Orthod Dentofac Orthop* 1991;100:123-32.
29. Kokich VO Jr. Congenitally missing teeth: Orthodontic management in the adolescent patient. *Am J Orthod Dentofacial Orthop* 2002;121:594-5.
30. Robertsson S, Mohlin B. The congenital missing upper lateral incisor. A retrospective study of orthodontic space closure versus restorative treatment. *Eur J Orthod* 2000;22:697-710.

31. Kokich VG, Spear FM. Guidelines of managing the orthodontic-restorative patient. *Semin Orthod* 1997;3:3-20.
 32. Isler S. Smile-maxilla, maxilla in the mouth and other interdisciplinary design guidelines: helpful hints for esthetic dental team. *Alpha Omegan* 2000;93:26-33.
 33. Kokich VG. Single-tooth implants in young orthodontic patients. *Inform Orthod Kieferorthop* 1994;1:45-62.
 34. Hennis RJ. The canine eminence. *Angle Orthod* 1974;44:326-8.
 35. Kesling PC. *Tip-edge guide*. Westville: Two Swan Advertising; 2003:1-20.
 36. Kokich VG, Nappen DL, Shapiro PA. Gingival contour and clinical crown length: Their effect on the esthetic appearance of maxillary anterior teeth. *Am J Orthod* 1984;86:89-94.
 37. Carlson G. Changes in contour of the maxillary alveolar process under immediate dentures. *Acta Odont Scand* 1967;25:1-31.
- 3 8 . Kokich VG. Single-tooth implants in young orthodontic patients. *Inform Orthod Kieferorthop* 1994;1:45-62.




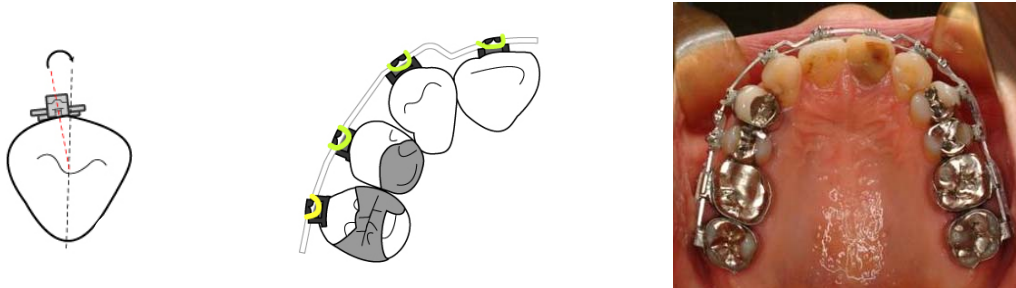
Figure 1. Initial facial photographs.

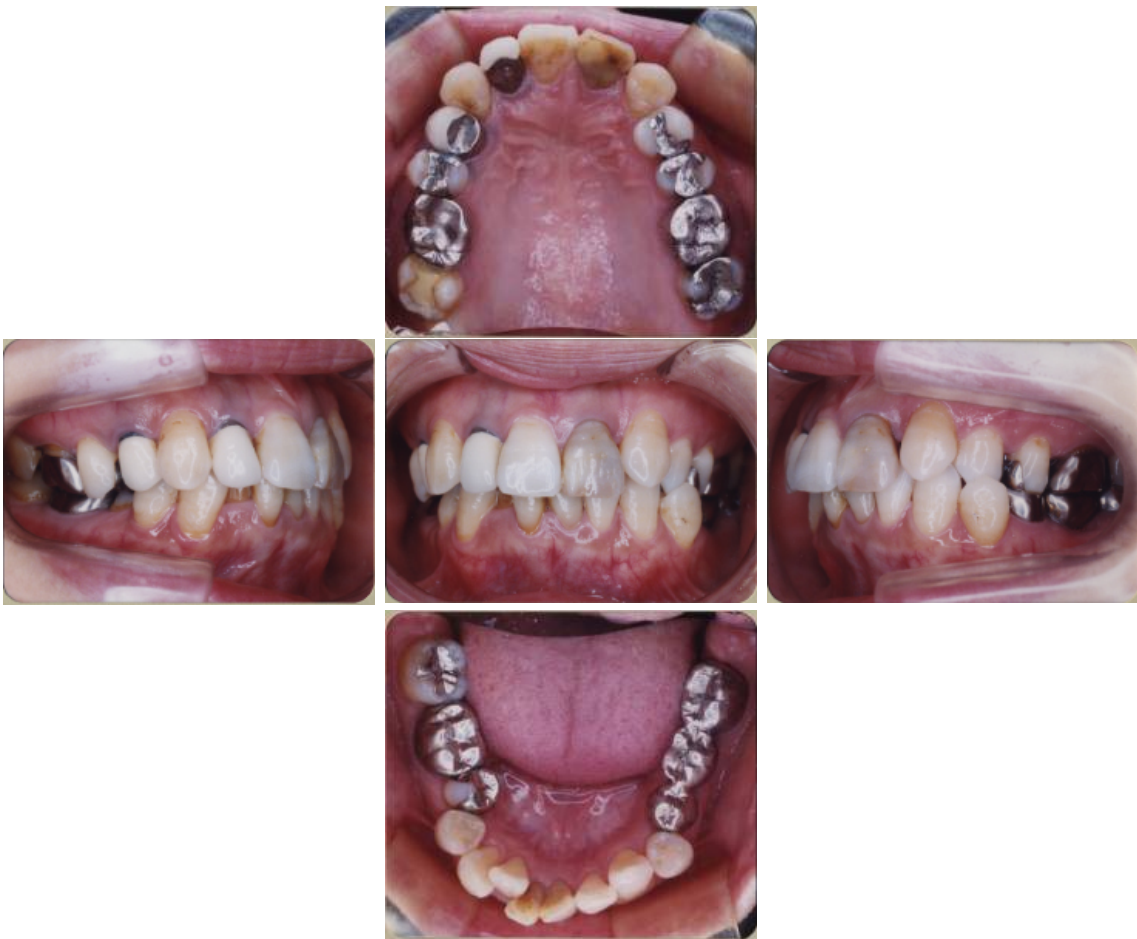

Figure 2. Initial intraoral photographs.

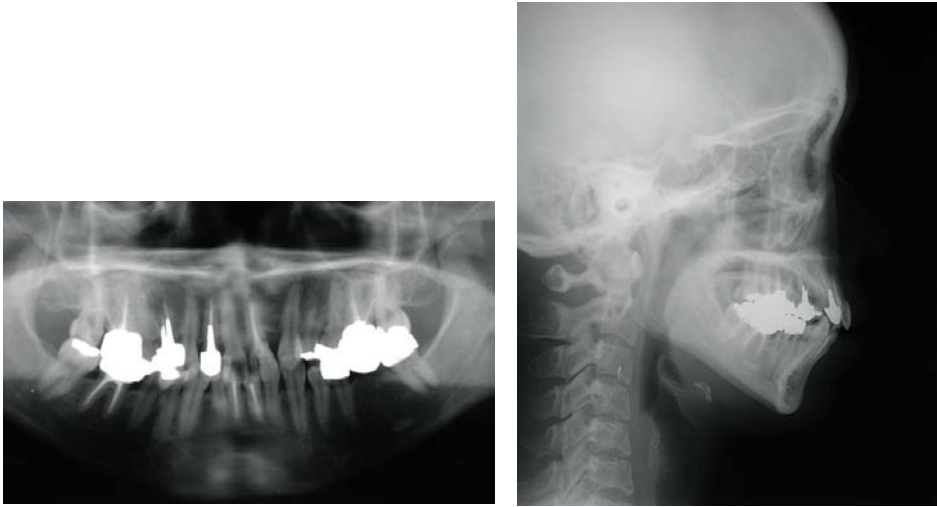

Figure 3. Initial radiographic views: A, Panoramic view. B, Lateral cephalometric view.



A

B

C

Figure 4. A. To make the canine appear less curved and more like a lateral incisor, the bracket is placed more distally in the center of the canine rather than at the height of contour. B. In the archwire design, to improve the interproximal contact points, the 1st order (in-out) bends was performed on the maxillary canines. C. Maxillary occlusal view of canine substitutions.

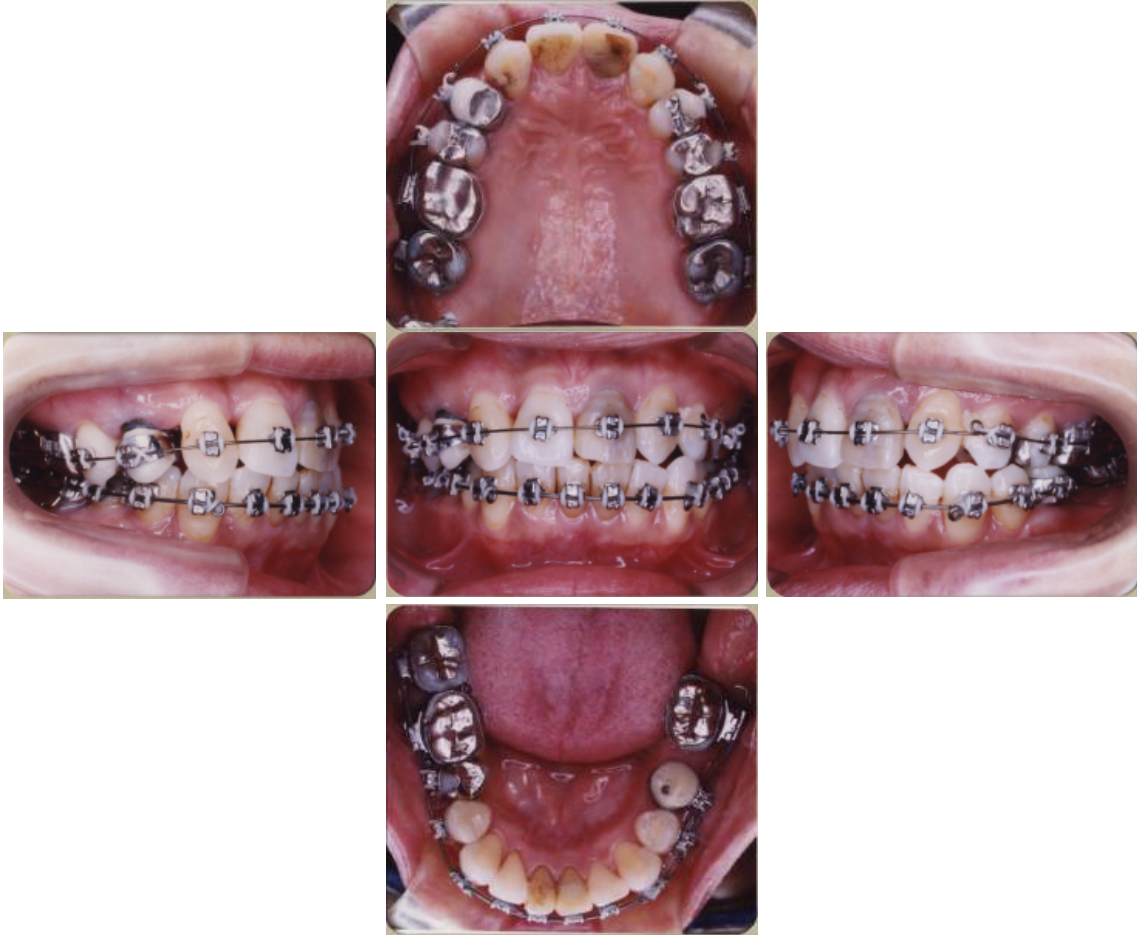

Figure 5. Progress intraoral photographs, after 10 months of treatment.

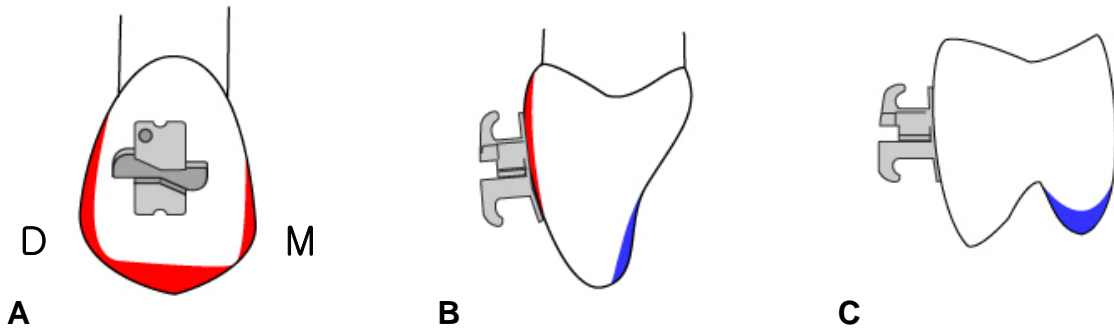


Figure 6. A. Recontouring (red color) of the maxillary canine to resemble like a lateral incisor. B. Recontouring (red color) of the prominent labial ridge of canine before bonding a bracket. The lingual surface was reduced (blue color) to establish a balanced occlusion. C. The lingual cusp of the maxillary first premolar for canine substitution was recontoured (blue color).



Figure 7. Final facial photographs.

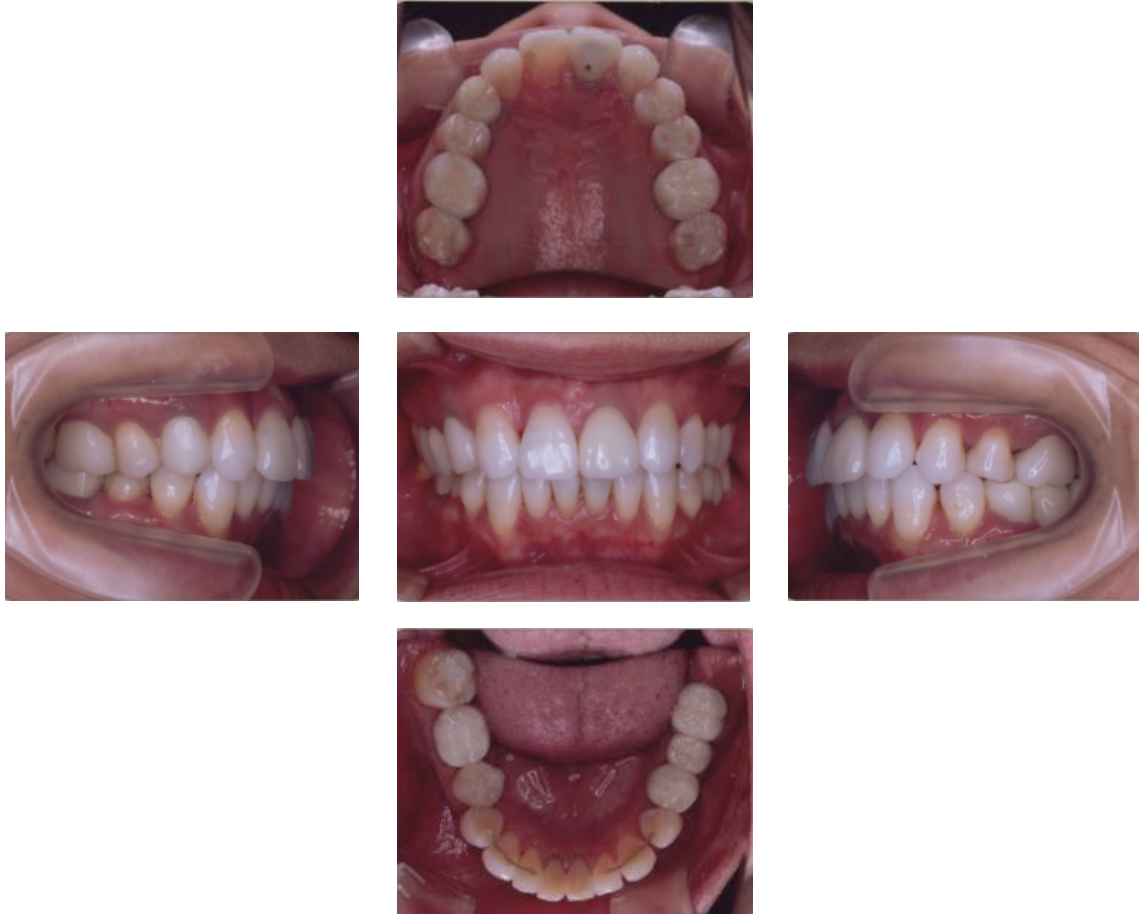

Figure 8. Final intraoral photographs.

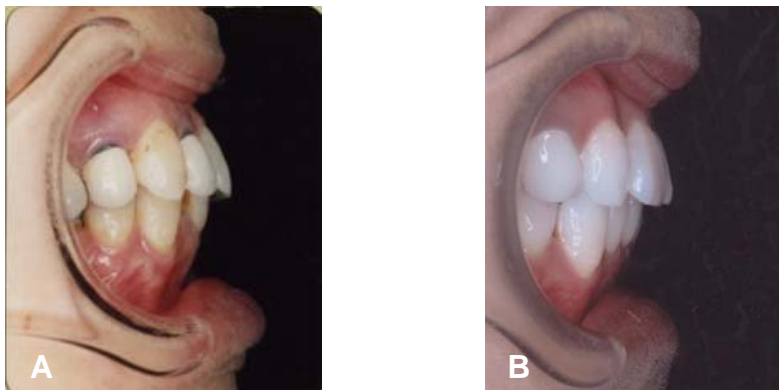


Figure 9. Intraoral lateral close-up views before (A) and after (B) treatment.

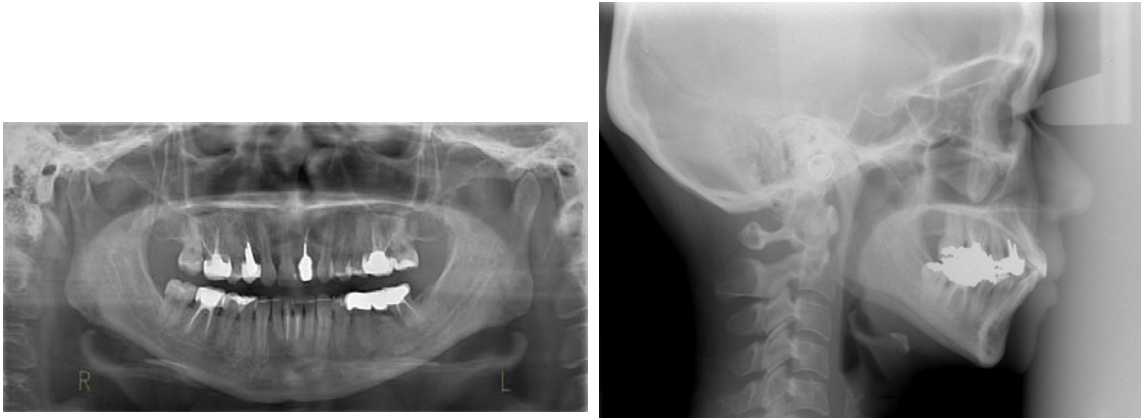


Figure 10. Final radiographic views: A, Panoramic view. B, Lateral cephalometric view.

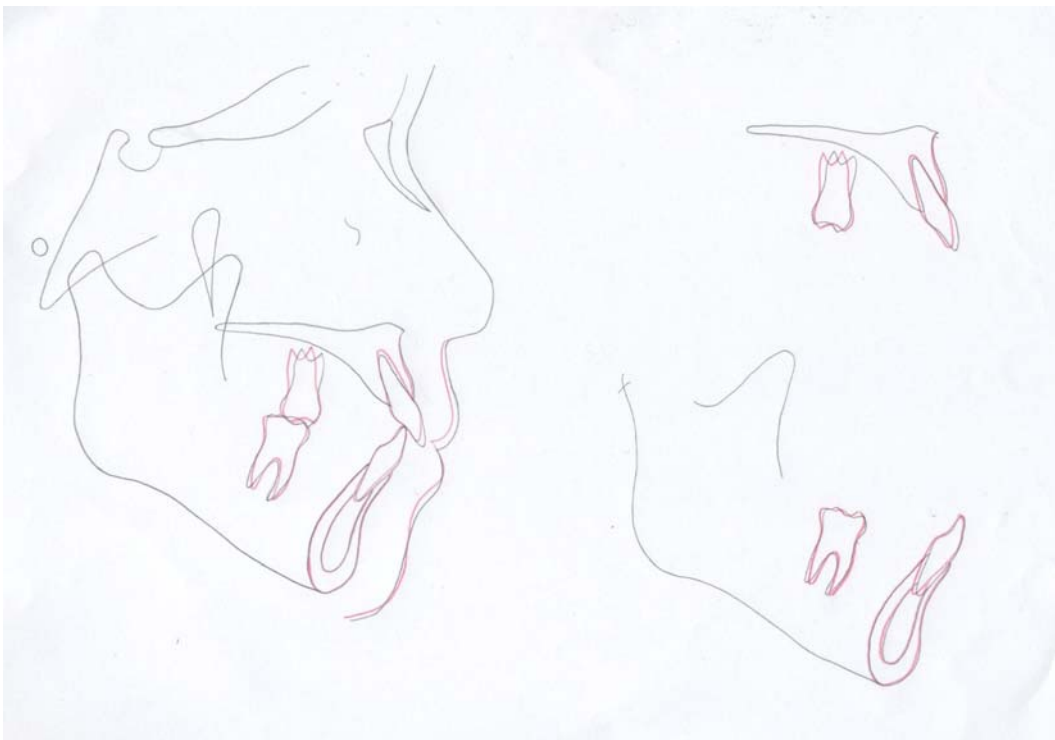


Figure 11. Superimposition of cephalometric tracings: pretreatment (black) and posttreatment (red).



Figure 12. Six-year of postretention (6 years posttreatment) facial photographs.

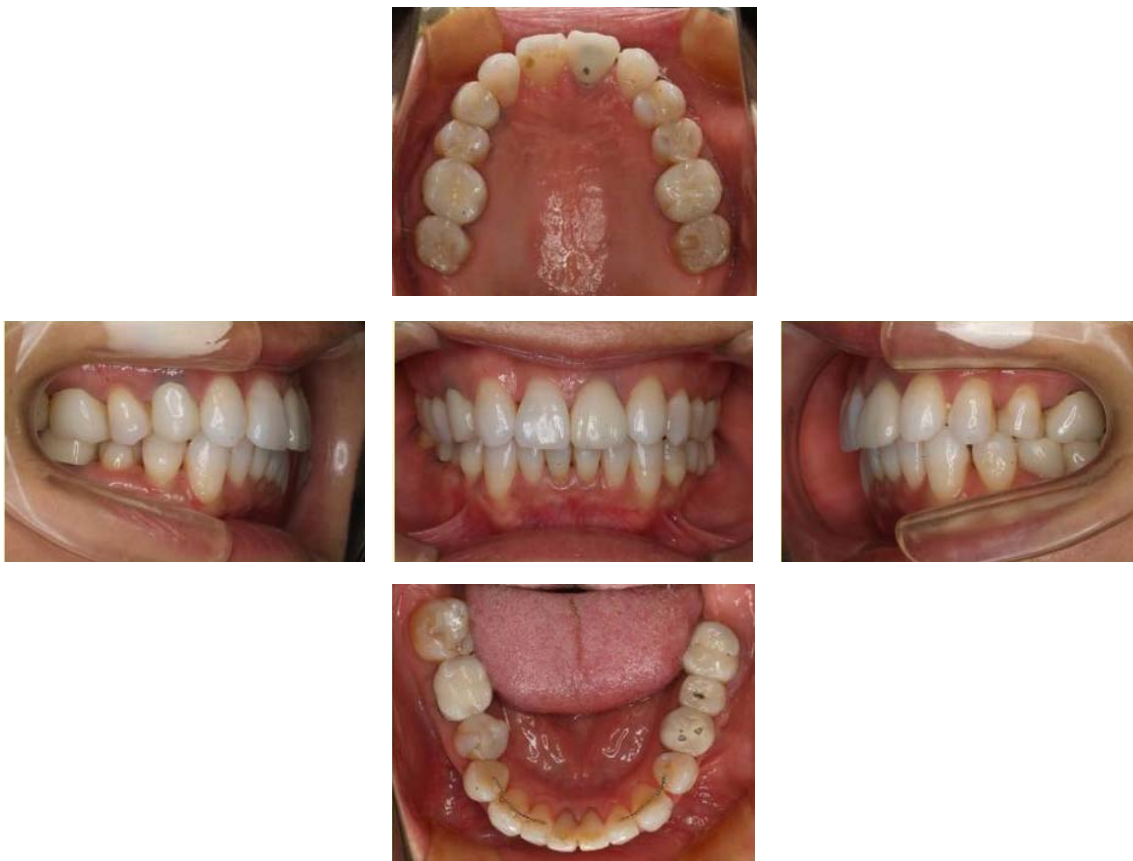

Figure 13. Six-year of postretention (6 years posttreatment) intraoral photographs.

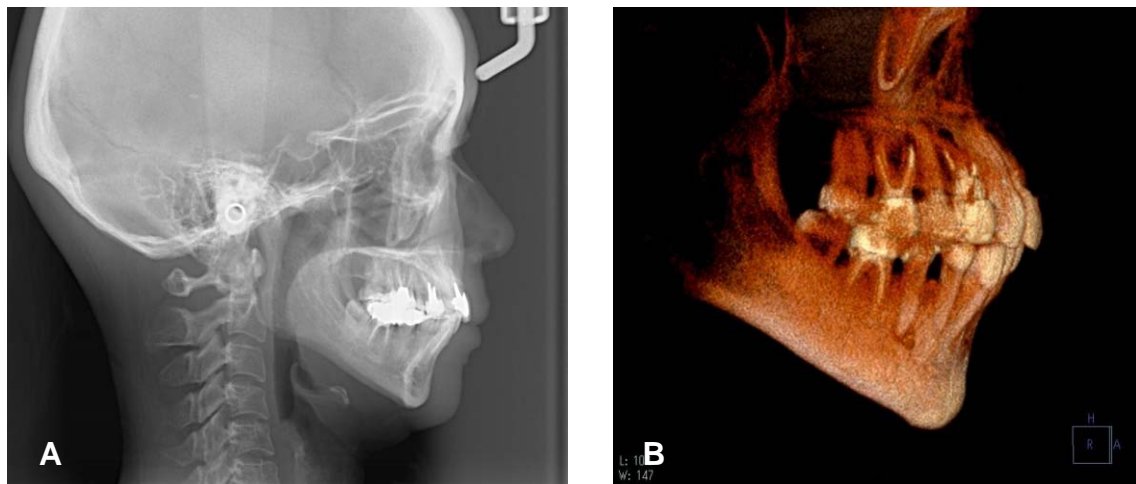


Figure 14. Radiographic views after six-year of postretention (6 years posttreatment): A, Lateral cephalometric view. B, The volume-rendering 3-dimensional computed tomography.

Table I. Cephalometric measurements

	<i>Japanese Norm</i>	<i>Pretreatment</i>	<i>Posttreatment</i>	<i>6 y posttreatment</i>
SNA angle(°)	82.3	85.1	85.2	84.9
SNB angle(°)	78.9	78.7	79	78.5
ANB angle(°)	3.4	6.4	6.2	6.3
FMA(°)	28.8	31.1	30.7	31.1
U1 to FH(°)	111.1	113.5	108.9	110.9
IMPA(°)	96.3	94.1	92.4	95.7
Interincisal angle(°)	124.1	121.4	128	122.2
Upper lip (mm)	0	1.5	-0.5	0.3
Lower lip (mm)	0.8	2	1.7	1.9