

Case Report

## A Case of Renal Transcatheter Arterial Embolization with Ethanol in Autosomal Dominant Polycystic Kidney Disease for Volume Reduction

Takashi Mukai<sup>a\*</sup>, Hidefumi Mimura<sup>b</sup>, Hideo Gobara<sup>b</sup>, Mitsuharu Shimizu<sup>a</sup>,  
Harutaka Niiya<sup>a</sup>, and Susumu Kanazawa<sup>b</sup>

<sup>a</sup>Department of Radiology, Okayama Medical Center, Okayama 701-1192, Japan, and

<sup>b</sup>Department of Radiology, Okayama University Graduate School of Medicine,  
Dentistry and Pharmaceutical Sciences, Okayama 700-8558, Japan

We report herein the case of a 76-year-old woman with autosomal dominant polycystic kidney disease (ADPKD) and chronic renal failure resulting in intractable abdominal distension and anorexia. Computed tomography (CT) showed enlarged and cystic kidneys. We performed transcatheter arterial embolization (TAE) for renal arteries with ethanol. Absolute ethanol with iodinated contrast medium or Lipiodol was delivered into both renal arteries. The patient's low-grade fever subsided in 5 days, and no other complication occurred. The sensation of abdominal distension diminished approximately 1 month after embolization. A progressive decrease in kidney size was observed soon after embolization. The percentage of the decrement of kidney size was approximately 50% after 17 months. These results indicate that renal TAE with ethanol is a safe, cost-effective, and minimally invasive technique to reduce kidney size in symptomatic ADPKD patients.

**Key words:** autosomal dominant polycystic kidney disease, transcatheter arterial embolization, ethanol

Autosomal dominant polycystic kidney disease (ADPKD) is a relatively common disorder that typically leads to renal failure. The kidneys of patients with ADPKD frequently continue to increase in size even after they begin dialysis, and the mass effects of enlarged kidneys can lead to severe symptoms. These symptoms include dysphagia, gastroesophageal reflux, early satiety, severe changes in bowel habits, dyspnea, and orthopnea.

Several methods reportedly reduce the size of enlarged kidneys: needle aspiration of the cyst fol-

lowed by injection of sclerosing agents [1], cyst decompression surgery [2], and surgical nephrectomy [3]. These methods are usually not safe or effective. Therefore, a safer and more effective therapy has been needed.

Ubara *et al.* have reported the use of therapeutic embolization of renal arteries with micro-coils for reducing kidney volume in ADPKD patients [4, 5]. The present report describes the successful treatment of ADPKD patients by using renal arterial embolization with ethanol instead of micro-coils.

### Case Report

A 76-year-old woman with ADPKD and chronic

Received March 25, 2011; accepted June 13, 2011.

\*Corresponding author. Phone: +81-86-294-9911; Fax: +81-86-294-9255  
E-mail: t-mukai@okayama3.hosp.go.jp (T. Mukai)

renal failure presented with intractable abdominal distension and anorexia. She had been diagnosed with ADPKD in her 50s. Hemodialysis was started for chronic renal failure at the age of 71. Her kidneys continued to enlarge progressively thereafter, and the sensation of abdominal fullness gradually developed. Ultrasonography-guided needle aspirations of the cysts were performed repeatedly to relieve her symptoms, but the success of this procedure was limited.

Computed tomography (CT) showed that her kidneys were enlarged and cystic. The right kidney measured  $13 \times 9.5 \times 19$  cm and the left kidney  $14 \times 10.5 \times 18$  cm (Fig. 1). The patient was not considered a good candidate for surgical nephrectomy due to her poor general condition. We therefore decided to perform transcatheter arterial embolization (TAE) of the renal arteries with ethanol after obtaining her informed consent.

The treatment was performed under local anesthesia and epidural anesthesia. A 5-Fr sheath introducer was percutaneously inserted into the aorta via the right femoral artery by the Seldinger technique. First, abdominal aortography was performed. The arteriogram obtained before TAE showed that both the renal arteries were narrowed and stretched. Selective angiography of the right renal artery was then performed using a 4-Fr shepherd hook catheter (Fig. 2). After the catheter was removed, a 4-Fr balloon catheter was placed over the guide wire in the right renal artery. A 4 : 1 mixture of absolute ethanol and iodinated contrast medium was delivered during

proximal balloon occlusion (Fig. 3). The embolic material was injected until the peripheral branches were enhanced. After 10 min, we evaluated whether the target arteries were completely embolized by

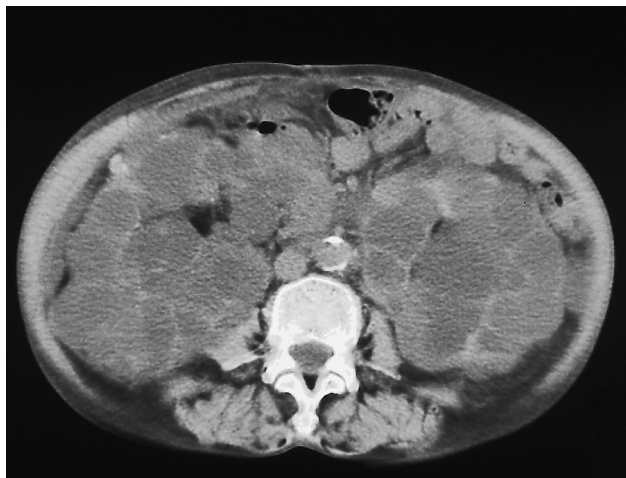


Fig. 1 A CT scan before TAE shows grossly enlarged polycystic kidneys.

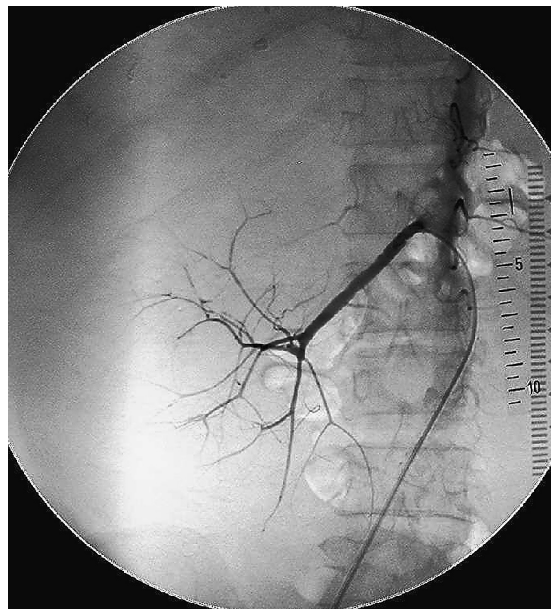


Fig. 2 A right renal arteriogram obtained before TAE shows narrowed and stretched renal arteries.

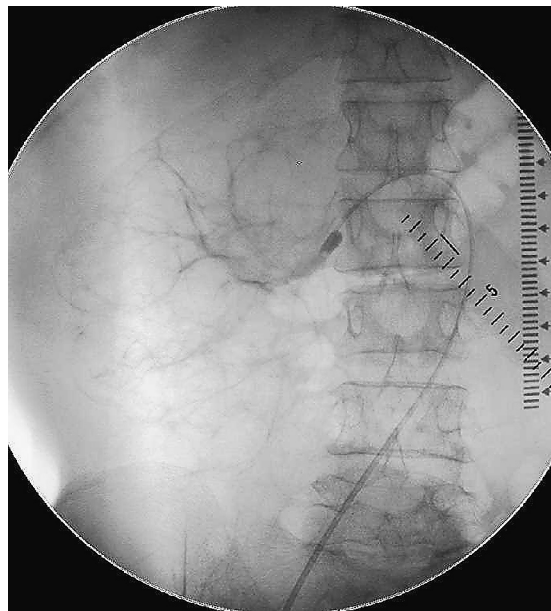


Fig. 3 A 4 : 1 mixture of absolute ethanol and iodinated contrast medium was delivered during proximal balloon occlusion.

arteriography in which a contrast medium was manually injected. If the embolization was not complete, embolic material injections were repeated in the same way. The total amount of embolic material injected to the right renal artery was 5.5ml.

It was not possible to introduce a balloon catheter to the left renal artery. Selective angiography of the left renal artery was therefore performed using a 4-Fr shepherd hook catheter (Fig. 4). To prevent reflux of injected ethanol into non-targeted areas, a 3-Fr microcatheter was inserted into the peripheral branches of the left renal artery through an intra-shepherd hook catheter and a 7 : 3 mixture of absolute ethanol and iodized oil (Lipiodol Ultra-Fluid, Mitsui, Tokyo, Japan) was cautiously delivered (Fig. 5). The total amount of embolic material injected into the left renal artery was 3.5ml. Aortography after TAE showed bilateral total occlusion of the renal arteries (Fig. 6).

The patient's low-grade fever subsided in 5 days, and no other complication occurred. The sensation of abdominal distension and anorexia diminished approximately 1 month after embolization. A progressive decrease in kidney size was observed after embolization, and a CT scan 17 months after TAE showed a marked decrease in the volume of both kidneys (Fig.

7). The right kidney measured  $8.5 \times 8.5 \times 15$  cm and the left  $12 \times 7.5 \times 15$  cm. The volume (according to the formula  $[\pi/6] \times [\text{length} \times \text{width} \times \text{depth}]$  as an

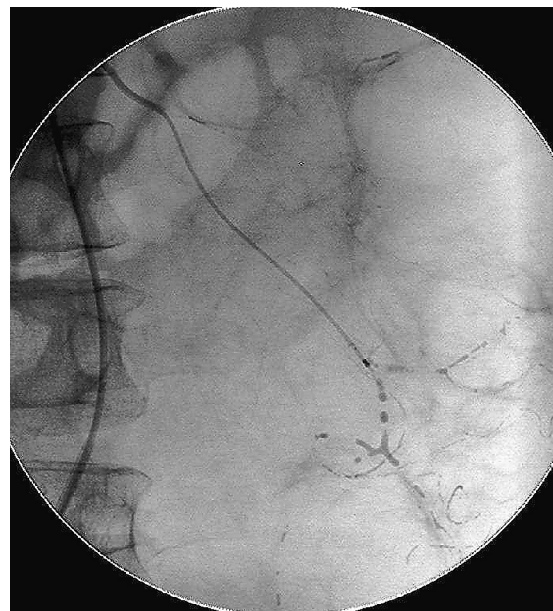


Fig. 5 A 3-Fr microcatheter was inserted into the peripheral branches of the left renal artery through an intra-shepherd hook catheter, and a 7 : 3 mixture of absolute ethanol and iodized oil was cautiously delivered.

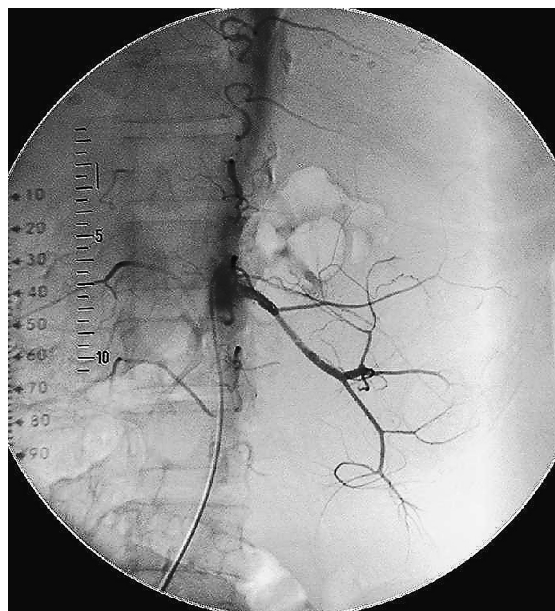


Fig. 4 A left renal arteriogram obtained before TAE shows narrowed and stretched renal arteries.

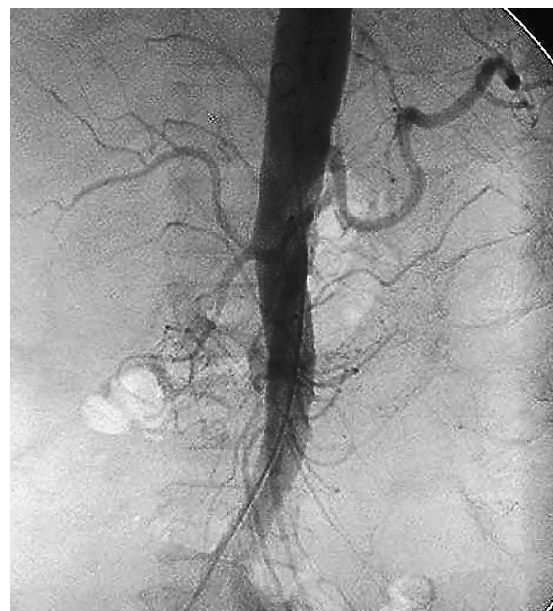

Fig. 6 Aortography after TAE showed total occlusion of bilateral renal arteries.



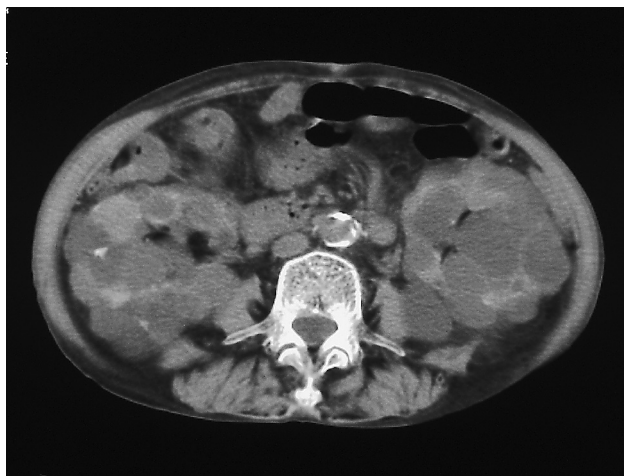


Fig. 7 A CT scan obtained at 17 months after TAE shows a marked decrease in the volume of both kidneys.

ellipsoid on CT images) of the right and left kidney decreased to 46.2% and 51.0%, respectively, of preinterventional values.

### Discussion

In 1999, Ubara *et al.* reported a case in which the size of an enlarged kidney was reduced by obstructing the renal arteries [4]. The kidneys of patients with ADPKD typically continue to increase even after the initiation of dialysis therapy because the renal parenchyma is replaced by numerous cysts. Histological examination showed that the remaining interstitium between the cysts was replaced by fibrous tissue but was well-vascularized. As renal failure progresses, the role played by the renal arteries appears to shift from supporting renal function to supplying fluid to multiple renal cysts. In this disease, angiogenesis presumably provides a feeding artery to the cysts. Thus, Ubara *et al.* have hypothesized that procedures designed to obstruct the well-developed renal arteries will lead to a shrinkage of renal cysts [4].

In 2002, a report by Ubara *et al.* described 64 patients treated with renal TAE [5]. Sixteen to 40 coils (mean, 31.2 coils) were used. Renal sizes decreased to 73.8%, 61.7%, and 53.4% of preinterventional values at 3, 6, and 12 months after therapy, respectively. Before objective confirmation of the diminution of renal size by diagnostic imaging, the majority of patients began to experience relief of

symptoms such as abdominal distention, dysphagia, and diminished oral intake within 1 to 2 weeks, and all patients experienced relief of symptoms within 1 month.

Renal contraction therapy by TAE with metallic coils effectively decreased renal size, but many coils were needed to embolize the renal arteries; therefore, the procedure is expensive and time-consuming. Furthermore, the possibility of recanalization is associated with this procedure [5, 6]. Sakuhara *et al.* have reported a case of TAE performed in combination with ethanol injection for ADPKD [6]. In this case, administration of ethanol effectively embolized the peripheral arteries through the recanalized arteries in which the coils had been placed. Rim *et al.* have reported a case of TAE with ethanol used to embolize the renal arteries of a patient with ADPKD, with no previous treatment such as coil embolization, in which the patient had experienced no recurrent symptoms or complications at 18 months after treatment [7]. We performed TAE for renal arteries with ethanol without previous treatment such as coil embolization. The kidney size decrement was 46.2% in the right kidney and 51.0% in the left at 17 months after therapy. The sensation of abdominal distention and anorexia in our patient had diminished approximately 1 month after embolization. In our case, the effectiveness and technical usefulness of ethanol were satisfactory.

Fluid emboli such as absolute ethanol are favored over particulates such as polyvinyl alcohol, Gianturco coil, or Gelfoam as embolic materials for unresectable renal cell carcinoma [8]. Most investigators use ethanol as the main embolic material, with or without iodized oil, in the embolization of renal angiomyolipoma [9]. A report by Lee *et al.* described 15 patients with 21 symptomatic renal angiomyolipomas that were treated with renal TAE [9]. All angiomyolipomas were successfully embolized with a 1 : 3 mixture of absolute ethanol and iodized oil. The symptoms produced by renal angiomyolipoma disappeared in all 15 patients within a few days after embolization. In their series, only 2 out of 18 tumors showed recurrence or rebleeding when complete embolization was achieved [9].

We favor embolization with ethanol as treatment over the use of coils. Ethanol is superior to coils in its high occlusion potential at the capillary level [6, 7] and is much less expensive than coils. In addition,

ethanol embolization is not as time-consuming as coil embolization for the narrowed renal arteries caused by polycystic kidneys.

In general, renal ethanol embolization can be safely performed, but reflux of injected ethanol into non-targeted areas may cause serious complications such as colonic infarction [10] and spinal cord infarction [11]. Our experience in the right kidney indicates that the use of a balloon catheter may prevent serious complications. However, the balloon catheter is occasionally difficult to place in the renal artery. In our case, it was not possible to introduce a balloon catheter into the left renal artery, and the embolic material was delivered from the peripheral branches of the left renal artery using a 3-Fr microcatheter. We used a 7:3 mixture of absolute ethanol and iodized oil as the embolic material. It has been reported that 50% and 75% ethanol-Lipiodol solutions result in embolization equal to that caused by absolute ethanol [12]. The mixture is radiopaque, and the embolization process can therefore be observed with fluoroscopy. The use of a mixture of absolute ethanol and iodized oil may contribute to safe embolization when the balloon catheter fails to enter the renal artery.

Back pain during ethanol injection to the renal arteries is a disadvantage of ethanol embolization. However, our patient tolerated the procedure under epidural anesthesia.

In conclusion, we have described a case of renal TAE with ethanol in ADPKD for volume reduction. Ethanol is superior to coils in its high occlusion potential at the capillary level and is much less expensive than coils. Although our experience is limited, we believe that renal TAE with ethanol instead of microcoils is a reasonable therapy for patients with ADPKD.

## References

1. Uemasu J, Fujiwara M, Munemura C, Tokumoto A and Kawasaki H: Effects of topical instillation of minocycline hydrochloride on cyst size and renal function in polycystic kidney disease. *Clin Nephrol* (1993) 39: 140–144.
2. Elzinga LW, Barry JM, Torres VE, Zincke H, Wahner HW, Swan S and Bennett WM: Cyst decompression surgery for autosomal dominant polycystic kidney disease. *J Am Soc Nephrol* (1992) 2: 1219–1226.
3. Dunn MD, Portis AJ, Elbahnasy AM, Shalhav AL, Rothstein M, McDougall EM and Clayman RV: Laparoscopic nephrectomy in patients with end-stage renal disease and autosomal dominant polycystic kidney disease. *Am J Kidney Dis* (2000) 35: 720–725.
4. Ubara Y, Katori H, Tagami T, Tanaka S, Yokota M, Matsushita Y, Takemoto F, Imai T, Inoue S, Kuzuhara K, Hara S and Yamada A: Transcatheter renal arterial embolization therapy on a patient with polycystic kidney disease on hemodialysis. *Am J Kidney Dis* (1999) 34: 926–931.
5. Ubara Y, Tagami T, Sawa N, Katori H, Yokota M, Takemoto F, Inoue S, Kuzuhara K, Hara S and Yamada A: Renal contraction therapy for enlarged polycystic kidneys by transcatheter arterial embolization in hemodialysis patients. *Am J Kidney Dis* (2002) 39: 571–579.
6. Sakuhara Y, Kato F, Abo D, Hasegawa Y, Shimizu T, Terae S and Shirato H: Transcatheter arterial embolization with absolute ethanol injection for enlarged polycystic kidneys after failed metallic coil embolization. *J Vasc Interv Radiol* (2008) 19: 267–271.
7. Rim H, Jung GS and Jung YS: Transcatheter arterial embolization using ethanol in a dialysis patient for contracting enlarged polycystic kidneys. *Korean J Radiol* (2010) 11: 574–578.
8. Park JH, Kim SH, Han JK, Chung JW and Han MC: Transcatheter arterial embolization of unresectable renal cell carcinoma with a mixture of ethanol and iodized oil. *Cardiovasc Intervent Radiol* (1994) 17: 323–327.
9. Lee W, Kim TS, Chung JW, Han JK, Kim SH and Park JH: Renal angiomyolipoma: embolotherapy with a mixture of alcohol and iodized oil. *J Vasc Interv Radiol* (1998) 9: 255–261.
10. Cox GG, Lee KR, Price HI, Gunter K, Noble MJ and Mebust WK: Colonic infarction following ethanol embolization of renal-cell carcinoma. *Radiology* (1982) 145: 343–345.
11. Gang DL, Dole KB and Adelman LS: Spinal cord infarction following therapeutic renal artery embolization. *JAMA* (1977) 237: 2841–2842.
12. Park JH, Jeon SC, Kang HS, Im JG, Han MC and Kim CW: Transcatheter renal arterial embolization with the mixture of ethanol and iodized oil (Lipiodol). *Invest Radiol* (1986) 21: 577–580.