
◎原 著

The relationship between the magnetic resonance imaging of the lumbar spine and low back pain

Shingo Takata, Eiichirou Yumoto, Makoto Okamoto,
Hirofumi Tsugeno, Seishi Harada, Yasuhiro Hosaki,
Takashi Mifune, Fumihiro Mitsunobu, Yoshiro Tanizaki
and Mine Harada¹⁾

Division of Medicine, Misasa Medical Branch

²⁾Second Department of Medicine, Okayama

University Medical School

Abstract : The purpose of this study was to examine the potential role of magnetic resonance imaging (MRI) in the evaluation of low back pain (LBP). The study group, 19 patients with low back pain (2 subjects aged 32–39 years and 17 aged 59–78), underwent MRI of the lumbar spine. Disc degeneration at L4/5 was the most common finding (68.4%). Overall in present study, all patients with LBP had abnormalities around the lumbar spine (evidence of disc degeneration, deformity of lumbar spine, disc bulging or protrusion, facet hypertrophy, nerve root compression and so on).

Key words : Magnetic resonance imaging • Lumbar spine • Disc disease

Introduction

LBP accounts for 30–40% of time lost due to industrial injury¹⁾. It is generally agreed that the heavier the work is, the more likely it is that back pain will develop^{2, 3, 4)}. However, the mechanisms that cause LBP are poorly understood⁵⁾.

Plain radiography of the spine is of little use in determining the cause of LBP^{6, 7)}. Magnetic resonance imaging (MRI) was first introduced into clinical practice in 1980⁸⁾. MRI offered a new approach for the evalu-

ation and study of LBP. It is a noninvasive technique without known harmful effects. Consequently, it can be used in longitudinal studies. Images may be produced in any plane and exhibit excellent soft tissue contrast. In the MR images of the lumbar spine, the paraspinal muscles, intervertebral discs and nerve roots can be observed in remarkable detail. The size and shape of the spinal canal are readily apparent. MRI allows the assessment of intervertebral disc hydration, enabling early signs of disc degeneration to be detected. Disc degeneration induces a gradual

loss of water from the nucleus pulposus, which manifests itself on a T2-weighted MR image as decreased signal from the disc. Protrusion of the intervertebral discs may also be delineated on MRI.

The purpose of this study was to undertake a critical review of the potential role of MRI in the evaluation of LBP.

Materials and Methods

Nineteen patients (8 males and 11 females; 2 subjects aged 32–39 years and 17 aged 59–78) with LBP were studied. All patients had low back pain, and 8 of them had paresthesia in their legs. All patients had the examination of MRI and received spa therapy.

Magnetic resonance imaging : The MRI scans of the lumbar spine were performed with a 1.5-T IGE Signa system, using a rectangular surface coil. From a coronal localizer scan, 5-mm sagittal images were prescribed with a 1.5-mm gap. A variable echo multiplanar (VEMP) spin echo sequence (TE 30 and 90 ms, TR 1500 ms) was used to give proton density and T2-weighted images, using a 256×256 matrix and a 24-cm field of view. From the midline sagittal image, axial slices were prescribed obliquely through each intravertebral disc. A T1-weighted pulse sequence (TE 2 ms TR 500 ms) was used with a 256×256 matrix and a 24-cm field of view and respiratory gating.

All scans were independently assessed by one experienced radiologist. Quantification of the imaging findings were made as follows : Disc degeneration was assessed subjectively by observing the signal intensity of each lumbar disc on the T2-weighted images. A disc was classified as being 'normal' or 'degenerate'. Disc configuration was classified according to the system described by

Jensen et al⁹). The terms used were : 'normal' ; no disc extension beyond the interspace, 'bulge' ; circumferential symmetrical extension of the disc beyond the interface, 'protrusion' ; focal or asymmetrical extension of the disc beyond the interface, with the base on the disc of origin broader than any other dimension of the protrusion, and 'extension' ; more extreme extension of the disc beyond the interface, with the base on the disc of origin narrower than the diameter of the extruding material itself or with no connection between the material and the disc of origin. The facet joints were assessed for hypertrophic change on the axial images. Nerve root compression was assessed on the sagittal and axial images.

Results

MRI findings

The MRI scans of the lumbar spine were classified as 'abnormal' if one or more of the following features were present: disc generation, deformity of lumbar spine, disc bulging or protrusion, facet joint hypertrophy, and evidence of nerve root compression. Lumbar spines that did not display any of these abnormal features were evaluated as normal. All subjects of this study were found to have abnormal lumbar spines on MRI.

Disc degeneration

Disc degeneration was present in one or more lumbar levels in 94.7% of all subjects (Fig. 1). The disc degeneration was most commonly observed at L4/L5, where 68.4% of the discs displayed evidence of disc degeneration.

Disc herniation

Disc herniation was found in 7 (36.8%) of all the subjects with LBP. Two (10.5%) of the subjects had bulging of one or more discs.

There were no disc herniations at L1/2 (Fig. 2).

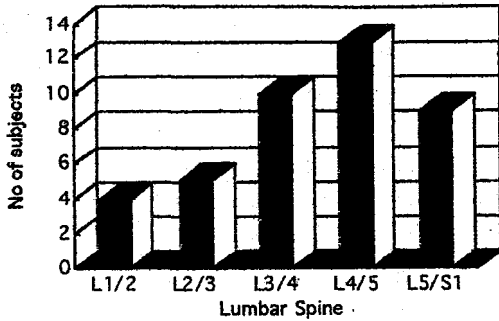


Fig. 1. Number of patients with disc degeneration

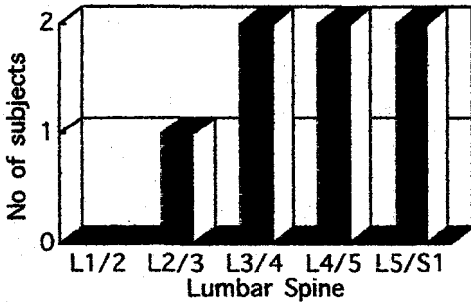


Fig. 2. Number of patients with disc herniation

Facet hypertrophy

Facet hypertrophy at one level or more was observed in 3 (15.8%) of the 19 subjects (Fig. 3). One subjects had facet hypertrophy and disc degeneration at the same level.

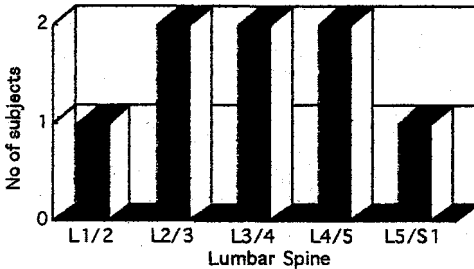


Fig. 3. Number of patients with facet hypertrophy

Nerve root compression

Nerve root compression at one level or more was observed in 4 (21.1%) of the subjects (Fig. 4). All of them were older patients between the ages of 59 and 78 years. The affected levels were at L2/3 (1 case), L4/5 (3 cases) and L5/S1 (2 cases).

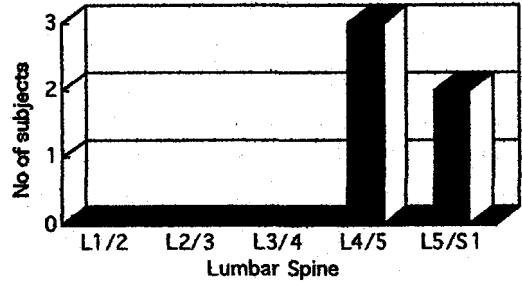


Fig. 4. Number of subjects with nerve root compression

Compression fracture

Compression fracture at one level or more was observed in 9 (47.4%) of all the subjects. All of them were older patients. The affected levels were L1 (2 cases), L2 (1 case), L4 (4 cases), L5 (3 cases) and S1 (2 cases) (Fig. 5).

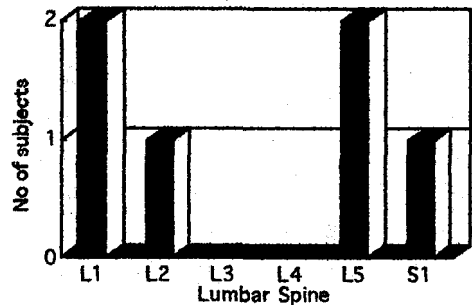


Fig. 5. Number of subjects with compression fracture

Spa therapy

Low back pain was improved in 10 (52.6%) of the subjects by spa therapy for 1-2 months. Spa therapy improved paresthesia in

their legs in 4 of the 8 subjects.

Discussion

In this study, disc degeneration was a common MRI feature in patients with LBP. Eighteen (94.7%) of all the subjects demonstrated disc degeneration. The most commonly affected discs were at L4/5 and L5/S1. It has been postulated that disc degeneration results from an intrinsic defect in the nuclear proteoglycans, which become unable to form macromolecular aggregates and thus lose their water binding capacity. This leads to cracks and fissures within the nucleus, which may secondarily disrupt the annulus and lead to herniation. Another possible cause is degeneration starting within the annulus fibrosus, which then fissures¹⁰. Degeneration with a grossly intact annulus results in an annular bulge, found as a general extension of the disc margin beyond the margin of the vertebral end plate¹¹.

The increasing prevalence of disc degeneration with age^{12, 13, 14} was confirmed. It is well known that disc degeneration is a normal consequence of aging and that biochemical and structural changes in disc occur simultaneously during ageing, leading to degeneration. At autopsy, 85–90% of individuals over the age of 50 years show evidence of disc degeneration¹⁵.

In regard to disc protrusion, the results of the present study were in agreement with the results by other reports^{12, 13, 14, 16}, showing that L4/5 and L5/S1 were the most commonly affected levels. Disc protrusions were more frequently observed in the older group than in the young group, suggesting that disc protrusion is age-related change¹⁰.

Despite the extraordinary ability of MRI to delineate the spine, several investigations

suggest that there is not a clear relationship between the MRI appearance and LBP^{8,12,13,14,17,18,19}. The causes of LBP are numerous, diverse and poorly understood. LBP might be caused by muscular in origin and due to a postural muscle strain or protective muscle spasm. Such an injury cannot be detected by MRI and neither can referred pain from viscera. But many of the subjects in this study who experienced LBP had abnormal MRI appearances.

A recent study²⁰ found that spa therapy was effective for patients with low back pain. A significant improvement of subjective symptoms, daily life activity, and total score was observed in patients with LBP after spa therapy. Objective symptom was also improved, however, this was not significant. In this study, low back pain and paresthesia in legs were also improved after spa therapy.

References

1. Gibson ES: The value of preplacement screening radiography of the low back, Back pain in workers, Deyo R, Hanley and Belfus, Philadelphia, 1988, 91–108.
2. Cust G, Pearson JCG, Mair A: The prevalence of low back pain in nurses. *Int Nurs Rev*, 19: 169–179, 1972.
3. Rowe M1: Are routine spinefilms on workers in industry cost- or risk-benefit effective? *J Occup Med*, 24: 41–44, 1982.
4. Svensson HO: Low back pain in 40–47 year old men. II. socioeconomic factors and previous sickness absence, *Scand J Rehab Med*, 14: 55–60, 1982.
5. Dillane JB, Fry J, Kalton G: Acute back syndrome—a study from British practice. *BMJ*, 2: 82, 1966.
6. Gibson ES, Martin RH, Terry C: Incidence of low back pain and preplacement X-ray

- screening. *J Occup Med*, 22 : 515, 1980.
7. Rowe ML : Low back pain in industry. *J Occup Med*, 11 : 161-169, 1969.
 8. Steinberg E, Sisk J, Locke K : X-ray CT and magnetic resonance imagers : diffusion patterns and policy issues. *N Engl J Med*, 313 : 859-864, 1985.
 9. Jensen MC, Brant-Zawadzki MN, Obuchowski N, Modic MT, Malkasian D, Ross JS : Magnetic resonance imaging of the lumbar spine in people without back pain. *N Engl J Med*, 331 : 69-73, 1994.
 10. Lipson SJ, Mair H : Experimental intervertebral disc degeneration. *Arthritis Rheum*, 24 : 12-21, 1981.
 11. Masaryk TJ, Ross JS, Modic MT : High resolution of sequestered lumbar intervertebral discs. *Am J Radiol*, 150 : 1155-1161, 1988.
 12. DeCandido P, Reinig JN, Dwyer AJ, Thompson KJ, Ducker TB : Magnetic resonance assessment of the distribution of lumbar spine disease. *J Spinal Disord*, 1 : 9-15, 1988.
 13. Boden SD, Davies DO, Dina TS, Patrons NJ, Wiesel SW : Abnormal magnetic resonance scans of the lumbar spine in asymptomatic subjects. *J Bone Joint Surg Am*, 72 : 403-408, 1990.
 14. Savage RA, Whitehouse GH, Roberts N : The relationship between the magnetic resonance imaging appearance of the lumbar spine and low back pain, age and occupational in males. *Eur Spine J*, 6 : 106-114, 1997.
 15. Blaser SI, Berns DH, Ross JS, Modic MT : Disks, degeneration and MRI. *MRI Decis*, 2 : 18-26, 1988.
 16. Matsui H, Kanamori M, Ishihara H, Yudoh K, Naruse Y, Tsuji H : Familial predisposition for lumbar degenerative disc disease A case-control study. *Spine*, 23 : 1029-1034, 1998.
 17. Modic MT, Pavlicek W, Weinstein MA, Boumphrey F, Ngo F, Hardy R, Duchesneau PM : Magnetic resonance imaging of intervertebral disk disease. *Radiology*, 152 : 103-111, 1984.
 18. Evans W, Jobe W, Seibert C : A cross-sectional prevalence study of lumbar disc degeneration in a working population. *Spine*, 14 : 60-64, 1989.
 19. Paaajanen H, Erkintalo M, Kuusela T, Dahlstrom S, Kormano M : Magnetic resonance study of disc degeneration in young low-back pain patients. *Spine* 14 : 982-985, 1989.
 20. Okamoto M, Ashida K, Yamamoto K, Iwagaki N, Tsugeno H, Mifune T, Mitsunobu F, Tanizaki Y, Tada S and Harada M : Clinical effect of spa therapy on lumbago. Annual reports of Misasa Medical Branch, Okayama University Medical School, 68 : 51-58, 1997 (in Japanese).

腰椎MRI画像と腰痛の関係

高田真吾, 湯本英一朗, 岡本 誠, 柘野浩史,
原田誠之, 保崎泰弘, 御船尚志, 光延文裕,
谷崎勝朗, 原田実根¹⁾

岡山大学医学部附属病院三朝分院内科

¹⁾岡山大学医学部第二内科

この研究の目的は腰痛評価におけるMRIの役割を検討することであった。対象は腰痛を訴え腰椎MRIを受けた19名(32歳から39歳2名, 59歳から78歳17名)であった。椎間板変性はL4/5 levelで最も多く認められた(68.4%)。本研究において腰痛を有する全患者に腰椎の異常(椎間板変性, disc bulging, protrusion, facet hypertrophy, 神経根圧迫, 腰椎変形など)を認めた。

索引用語 : MRI, 腰椎, 椎間板変性