

Medicine

Otorhinolaryngology fields

Okayama University

Year 2001

False-positive magnetic resonance image
in the diagnosis of small acoustic
neuroma

Manabu Maeta*

Ryusuke Saito†

Hideo Nameki‡

*Okayama University

†Okayama Saiseikai General Hospital

‡Shizuoka Red Cross Hospital

This paper is posted at eScholarship@OUDIR : Okayama University Digital Information Repository.

<http://escholarship.lib.okayama-u.ac.jp/otorhinolaryngology/1>

False-positive magnetic resonance image in the diagnosis of small acoustic neuroma

MANABU MAETA, M.D., RYUSUKE SAITO, M.D.*, HIDEO NAMEKI, M.D.†

Abstract

A patient presented with sudden hearing loss on her first visit to our department. Gadolinium-DTPA-enhanced magnetic resonance imaging (MRI) of the posterior cranial fossa portrayed an intracanalicular tumour image (2-3 mm), and the pure tone average (PTA) and speech discrimination score (SDS) values were 65 dB and 60 per cent, respectively. Surgical intervention to remove the suspected tumour was scheduled by the translabyrinthine approach. Intracanalicular observations by the retrolabyrinthine approach revealed limited oedema on the inferior vestibular nerve with vascular dilation. The tumour image disappeared two years after the operation. Surgical findings and the post-operative course advocate that gadolinium-DTPA-enriched MRI image of an intracanalicular lesion such as arachnoiditis might produce a false-positive result.

Key words: Acoustic Neuroma; Magnetic Resonance Imaging

Case report

A 53-year-old woman was referred to our department on October 7, 1995 complaining of ringing and deafness in her right ear. Upon first examination, the patient displayed a right sensorineural hearing loss of 103 dB (PTA) (Figure 1). She was diagnosed with sudden deafness and admitted on the same day. Although the patient received tapering steroidal therapy over a two-week period, improvement in hearing was slight and tinnitus persisted, and she was kept on a regimen of vitamin B₁₂ and ATP after discharge. On October 27, posterior cranial fossa MRI after administration of gadolinium-DTPA using a 1.5 tesla magnet revealed a 2-3 mm tumour image in the right internal auditory canal (Figure 2). During this period, neither dysequilibrium nor facial palsy was encountered.

Observations thereafter for seven months revealed no changes in hearing, and another posterior cranial fossa MRI taken on May 10, 1996 again indicated a gadolinium-DTPA-enhanced 2-3 mm tumour image in the right internal auditory canal. At this point, the subject indicated sensorineural hearing loss in the right ear with a PTA value of 65 dB (Figure 1). The SDS indicated 60 and 95 per cent for the right and left ears, respectively. With self-recording audiometry, the right ear was found to be of Jerger type II. IPL I-V of auditory brain stem response (ABR) indicated 5.40 and 4.55 msec for the right and left ears, respectively. In the caloric test, the right and left ears scored 188 and 222 sec, respectively. Based on computed tomography (CT) scan of the temporal bone, laterality differences in the diameter of the internal auditory canal and other intracanalicular abnormalities were not encountered (Figure 3).

Based on diagnosis of the right acoustic neuroma and other findings derived from the above examinations, tumour removal with surgical intervention via the transla-

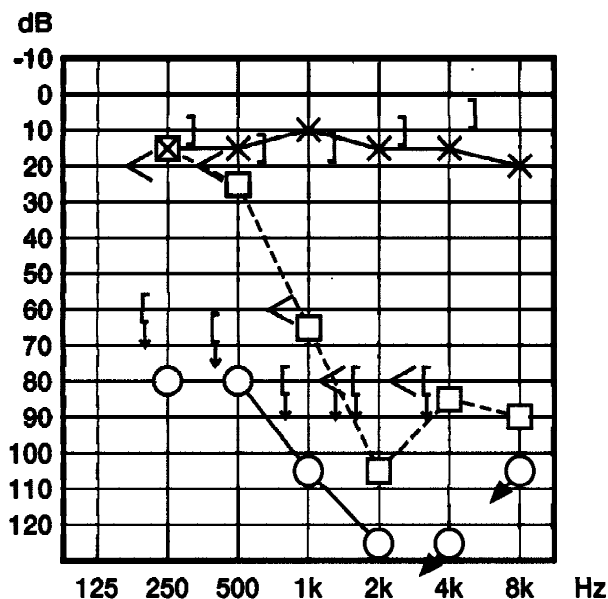


FIG. 1

Pure tone audiogram during initial diagnosis and pre-operation. The right (∇) and left (\times) air conduction levels are represented by the respective solid lines, while the right (\square) and left (\square) bone conduction levels are indicated accordingly. Right air conduction levels immediately before operation (\square) are illustrated by a broken line with bone conduction levels (\square).

abyrinthine approach was scheduled for May 13, 1996. However, as development of the mastoid cavity was excellent, intracanalicular exploration was judged to be

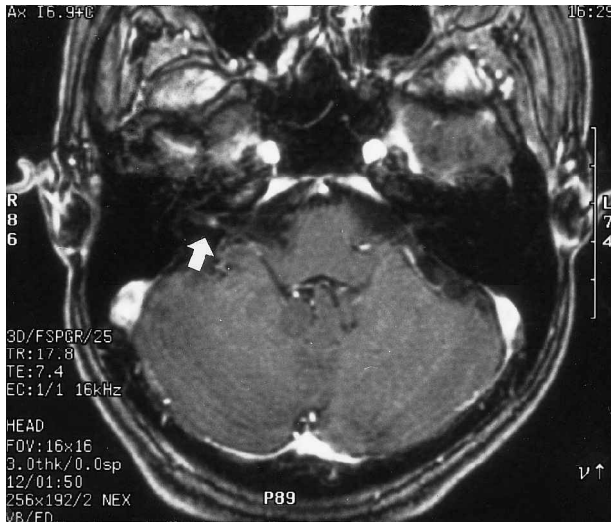


FIG. 2

In an axial gadolinium-DTPA-enhanced T1-weighted MRI, a right intracanalicular tumour image of 2–3 mm is portrayed (arrow).

possible by the retrolabyrinthine approach. Briefly, the semicircular canals were skeletonized after initial mastoidectomy, and the internal auditory canal was explored after the bone between the posterior cranial fossa and the labyrinth was drilled without injuring the labyrinth (Figure 4). Observations of the internal auditory canal after surgical exposure of the dura revealed slight oedema on certain parts of the surface of the inferior vestibular nerve and vascular dilation was noted, although other abnormalities in intracanalicular blood vessels and signs of tumour development were not encountered. As such, surgical intervention was terminated with mere surgical exploration of the internal auditory canal. Facial palsy was not

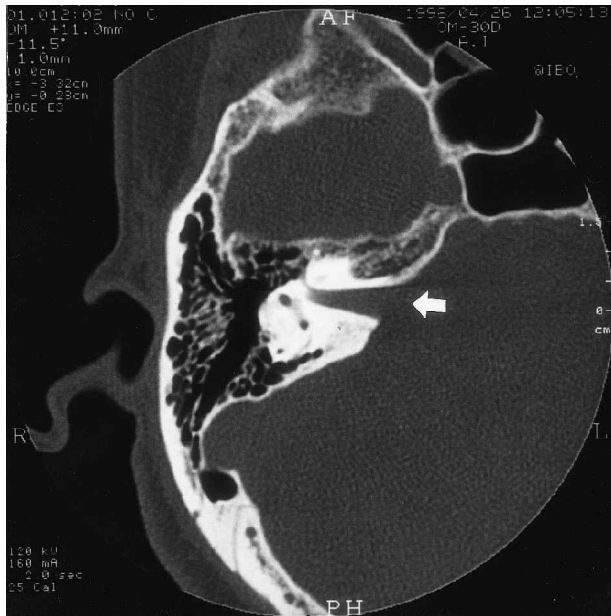


FIG. 3

In an axial CT scan of a bone window setting of the pre-operative right temporal bone, enlargement of internal auditory canal is not observed (arrow).

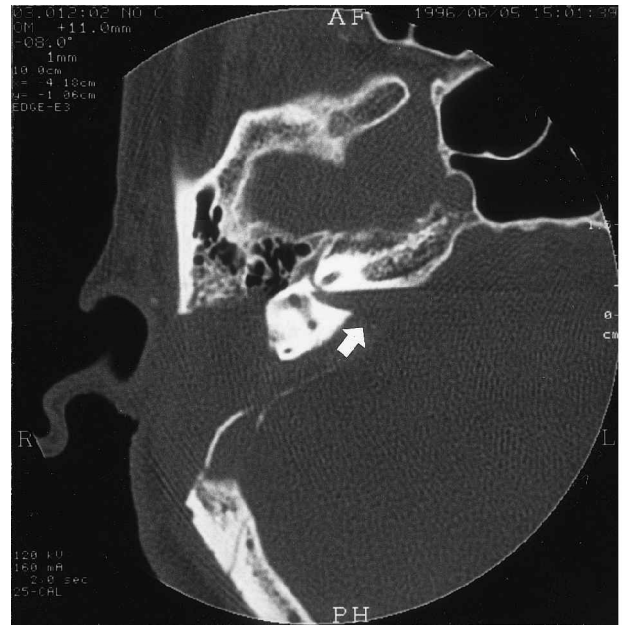

FIG. 4

In an axial CT scan of a bone window setting of the post-operative right temporal bone, intact labyrinth in the anterior section and a thin bony wall on the posterior cranial fossa in the posterior section remained. The bony wall of the internal auditory canal was surgically removed, exposing the internal auditory canal to indicate supposed existence of the MRI-portrayed tumour (arrow).

encountered after surgery, and initial post-operative hearing loss in response to low-tone stimuli was gradually restored two months thereafter.

Two years after the operation, the pre-operative 2–3 mm tumour image manifested by gadolinium-DTPA-enhanced posterior cranial fossa MRI was not seen, although the hearing remained at pre-operative level.

Discussion

Diagnosis of early-phase small intracanalicular acoustic neuromas has become possible with gadolinium-DTPA-enhanced MRI. While in the past, the minimization of diagnostic oversight in acoustic neuroma cases was a major issue, improvement in the clarity of MRI for intracanalicular lesions has conversely given rise to false-positively diagnosed cases.¹⁻⁶ According to our data-pool, the number of cases manifesting false-positive diagnosis of suspected intracanalicular acoustic neuromas by MRI without neoplastic lesions on surgical exploration has hitherto accumulated to 11 cases. The intracanalicular abnormalities found during surgical exploration include a vascular loop around the inferior and superior vestibular nerves,¹ arachnoiditis,²⁻⁴ neuritis of the vestibulocochlear nerve,⁵ a tiny arteriovenous malformation,⁵ hyperaemic and oedematous VIIIth nerve⁶ as well as neural inflammatory sequelae.⁴ Of these abnormalities, arachnoiditis scored the highest incidence with a rate of four out of 11 reported cases. Together with disappeared tumour image and surgical findings of slight oedema in certain sites of the inferior vestibular nerve surface and vascular dilation, false-positive portrayals of an intracanalicular lesion such as arachnoiditis in gadolinium-DTPA-enhanced image is highly conceivable, even in our present case report.

Even by recent audiological and radiological examinations, it is still difficult to discriminate an intracanalicular tumour from inflammation. According to Arriaga *et al.*,⁴ surgeries performed on 'tumours' involving the internal auditory canal reveal a false-positive incidence of 3.5 per cent, while for cases limited to intracanalicular lesions the rate increases to more than 20 per cent. In short, incidences of small acoustic neuromas are expected to further increase with technical advent in MRI diagnosis, yielding a higher false-positive rate in future. Technological innovation and novel approaches affording concrete and appropriate differentiation of hitherto established false identification of tumours with diagnostic imaging are therefore warranted for discriminative diagnosis.

References

- 1 Haberman RS II, Kramer MB. False-positive MRI and CT findings of an acoustic neuroma. *Am J Otol* 1989;**10**:301-3
- 2 von Glass W, Haid C-T, Cidlinsky K, Stenglein C, Christ P. False-positive MR imaging in the diagnosis of acoustic neurinomas. *Otolaryngol Head Neck Surg* 1991;**104**:863-7
- 3 Donnelly MJ, Cass AD, Ryan L. False positive MRI in the diagnosis of small intracanalicular vestibular schwannomas. *J Laryngol Otol* 1994;**108**:986-8
- 4 Arriaga MA, Carrier D, Houston GD. False-positive magnetic resonance imaging of small internal auditory canal tumors: a clinical, radiologic, and pathologic correlation study. *Otolaryngol Head Neck Surg* 1995;**113**:61-70
- 5 Han MH, Jabour BA, Andrews JC, Canalis RF, Chen F, Anzai Y, *et al.* Nonneoplastic enhancing lesions mimicking intracanalicular acoustic neuroma on gadolinium-enhanced MR imaging. *Radiology* 1991;**179**:795-6
- 6 Barbara M, Saliola S, Filipo R. False-positive MRI in a patient with otoneurological pathology. *J Laryngol Otol* 1993;**107**:465-7

Address for correspondence:
Manabu Maeta, M.D.,
Department of Otolaryngology,
Okayama University Medical School,
2-5-1 Shikata-cho,
Okayama 700-8558,
Japan.

Fax: +81-86-235-7308
E-mail: m-maeta@ichigo.okayama.okayama.jp

Dr M. Maeta takes responsibility for the integrity of the content of the paper.
Competing interests: None declared
