

Acta Medica Okayama

Volume 44, Issue 4

1990

Article 7

AUGUST 1990

A new open reduction treatment for congenital hip dislocation: long-term follow-up of the extensive anterolateral approach.

Hirofumi Akazawa*

Gozo Tanabe†

Yoshimasa Miyake‡

*Okayama University,

†Okayama University,

‡Okayama University,

A new open reduction treatment for congenital hip dislocation: long-term follow-up of the extensive anterolateral approach.*

Hirofumi Akazawa, Gozo Tanabe, and Yoshimasa Miyake

Abstract

Congenital hip dislocation, which is conservatively unmanageable, has usually been treated using open reduction. However, a long-term follow-up study of the results suggests that this procedure is unsatisfactory. Since 1973, Tanabe has used a new open reduction procedure that circumferentially dissects the joint capsule and produces sufficient concentric reduction of the femoral head in the acetabulum immediately after the surgery. Fifty-six children (65 hips) from the age of 1 to 3 years were treated by this procedure, and fifty-one of them were clinically and roentgenographically followed up from 6.3 to 12.4 years after the surgery. At the final follow-up session, all children had grown to be over 9 years of age, and no patient had clinically significant symptoms. According to Severin's classification, 33 hips were rated in Group I, and 14 hips in Group II. Another 10 hips were in Group III, and one hip was in Group IV. The incidence of avascular necrosis was 5.2 per cent. These data suggest that our procedure is more useful than the previous ones.

KEYWORDS: congenital hip dislocation, new open reduction, follow-up study, anterolateral approach

*PMID: 2244477 [PubMed - indexed for MEDLINE]

Copyright (C) OKAYAMA UNIVERSITY MEDICAL SCHOOL

A New Open Reduction Treatment for Congenital Hip Dislocation: Long-term Follow-up of the Extensive Anterolateral Approach

Hirofumi Akazawa*, Gozo Tanabe and Yoshimasa Miyake

Department of Orthopaedic Surgery, Okayama University Medical School, Okayama 700, Japan

Congenital hip dislocation, which is conservatively unmanageable, has usually been treated using open reduction. However, a long-term follow-up study of the results suggests that this procedure is unsatisfactory. Since 1973, Tanabe has used a new open reduction procedure that circumferentially dissects the joint capsule and produces sufficient concentric reduction of the femoral head in the acetabulum immediately after the surgery. Fifty-six children (65 hips) from the age of 1 to 3 years were treated by this procedure, and fifty-one of them were clinically and roentgenographically followed up from 6.3 to 12.4 years after the surgery. At the final follow-up session, all children had grown to be over 9 years of age, and no patient had clinically significant symptoms. According to Severin's classification, 33 hips were rated in Group I, and 14 hips in Group II. Another 10 hips were in Group III, and one hip was in Group IV. The incidence of avascular necrosis was 5.2 per cent. These data suggest that our procedure is more useful than the previous ones.

Key words: congenital hip dislocation, new open reduction, follow-up study, anterolateral approach

Many open reduction procedures have been introduced since Alfonso Poggi's report (1) to treat congenital hip dislocations in children who have reached walking age or in whom conservative treatments have failed. However, few satisfactory results from these procedures have been reported because of shortening of the extra-articular soft tissues, adhesion of the capsule and ilium (2), dysplasia of the acetabulum, hypertrophy of the ligamentum capitis femoris, hypertrophy of fibro-fatty tissue in the acetabulum, inversion of the labrum and other factors (3-9).

Similarly poor results have been obtained in

our department. We performed the open reduction method of Howorth (10) in 1964, but redislocation was experienced. Procedures of Scaglietti and Calandriello (4) and Ludloff (11) also were tried on thirteen hips in our clinic; two of these hips were rated in Group II, one in Group III, four in Group IV, one in Group V, and five in Group VI, according to Severin's classification. Thus, secondary procedures were necessary in 84.6 per cent of the patients, since good concentration could not be secured after one operation. Although good concentration was obtained immediately after Colonna's method (12), the hips did not develop normally as shown by Chung *et al.* (13).

*To whom correspondence should be addressed.

To overcome those problems, one of the authors (G.T.), devised in 1973 an extensive anterolateral approach for an open reduction method which allows complete dissection of the joint capsule, and also complete removal of all ascertained obstacles (14). The present paper is to describe the method, and to evaluate the clinical and roentgenographic results of a follow-up study.

Materials and Methods

Patients and evaluation. Fifty-six patients born between September 1971 and August 1977 failed to obtain concentric reduction by conservative treatment. They were all examined by arthrograms, and showed interpositions without concentric reduction. Only those patients with typical congenital hip dislocations were considered in this study. Cases with subluxation or dislocation associated with spina bifida, spasticity or arthrogryposis were excluded. The age at the time of the operation was from twelve to thirty-six months after birth. Forty-five patients were girls, and six were boys. Fifty-eight hips of the fifty-one patients (91.1 per cent) were clinically and roentgenographically followed up from 6.3 years to 12.4 years after initial surgery (average 9.7 years). The age at the time of review ranged from 9 to 14.3 years (average 11.3 years).

Thirty-eight of the fifty-one children were afflicted with unilateral dislocation (fifteen right and twenty-three left hips); thirteen of the children, with bilateral dislocations. Our open reduction was performed in all thirty-eight cases of unilateral dislocation and in seven cases of bilateral dislocations. In one case of bilateral dislocation, one hip was reduced by Colonna's arthroplasty, the other one by our open reduction. In the remaining five cases of bilateral dislocation, the other hips were treated conservatively; two hips reduced by a Pavlik harness, and three hips treated by manual reduction and the hip spica cast immobilization process under general anesthesia.

Secondary operations were carried out in nine cases (17.6 per cent) that still had acetabular dysplasia or deformity of the proximal femur after the open reduction: varus derotational osteotomy of the femur in four cases, Salter's innominate osteotomy (15) in three cases, Pemberton's osteotomy (16) in one case, and Colonna's arthroplasty in one case.

The clinical evaluation at the final visit included the range of hip motion, significant limp, presence of pain,

Trendelenburg's sign, and discrepancies in leg length. For clinical comparisons, we used the classification of Gibson and Benson (6). At this visit, measures were also made of Wiberg's CE-angle from the anteroposterior radiograph of each hip. For evaluating avascular necrosis, Salter's criteria (17) were used. The anatomical results were evaluated according to Severin's classification (18).

Extensive anterolateral open reduction. A transverse incision was made from the medial border of the sartorius to just distal to the greater trochanter, 3 cm distal to the anterior superior iliac spine with the patient in a supine position. The interspace between the sartorius and the tensor fasciae latae was identified, and the sartorius was retracted medially, and the tensor fasciae latae laterally. The fascia lata and the tensor fasciae latae were transversely dissected at the level of incision. Generally, highly dislocated hips and older patients have shortened pelvi-femoral muscles, such as the hip adductors and the tensor fasciae latae. In such cases, in lowering the femoral head to the level of the acetabulum, a femoral shortening osteotomy may be necessary; however, no such situation existed before three years of age.

The gluteus medius and minimus were temporarily detached from their insertions. The rectus femoris with its reflected head was exposed and the edges of the reflected head clearly defined with a blunt dissection. The straight head of the rectus femoris was detached from the anterior inferior iliac spine to obtain a better view of the operative field. The psoas tendon was also detached from the lesser trochanter and later transferred to the anterior surface of the proximal femur. The fibrous adhesion was dissected for thorough exposure of the joint capsule. Tendon of the piriformis was transected at its insertion, to visualize the posterior surface of the capsule and to dissect the posterior adhesions. At this point, the ascending branch of the medial femoral circumflex artery was protected. Then the joint capsule was incised circumferentially near the acetabular rim.

Transection of the transverse acetabular ligament alleviated inversion of the labrum. When the inversion is not corrected by this procedure, eversion is attempted as much as possible, by making an incision at one or two sites on the labrum, but without excision. The hypertrophied ligamentum capitis femoris and the fibro-fatty tissues in the acetabulum were removed. The redundant parts of the capsule were trimmed away; capsulorrhaphy was not necessary. While the hip was held in slight flexion, in full internal rotation and about 30 degrees abduction, a complete reduction was confirmed roentgeno-

graphically. The transected and detached muscles were reattached except for the piriformis. A hip spica cast was applied in the position mentioned, and changed after three weeks. Five weeks later the plaster was removed and active movement was allowed. Weight bearing was postponed until sixteen weeks after surgery.

Results

Operative findings. Some extracapsular and

intracapsular obstacles were encountered during reduction. The iliopsoas muscle was an important extracapsular obstacle (75 per cent). When the femoral head was not in the acetabulum, the iliopsoas tendon was stretched so tightly that the capsule was compressed against the inlet of the acetabulum (Fig. 1). Tough adhesion between the anterior capsule and the iliopsoas tendon was a frequent complication (57 per cent), which made an hourglass constriction of the capsule. The adhering and taut iliopsoas tendon obviously acted

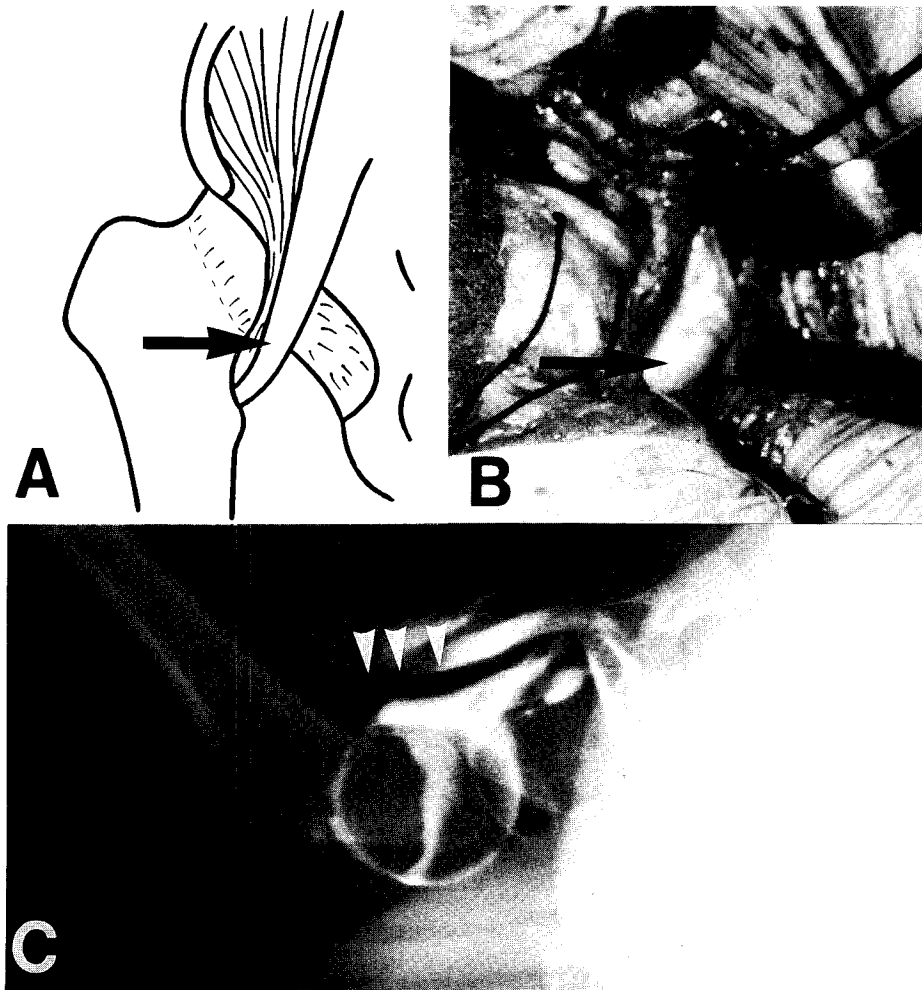


Fig. 1 Obstacle to reduction: iliopsoas. **A** : In the dislocated hip, the iliopsoas tendon (arrow) produces a so-called isthmus. **B** : The iliopsoas during our open reduction procedure. **C** : This lateral arthrogram shows the isthmus after compression by the iliopsoas tendon (arrowheads).

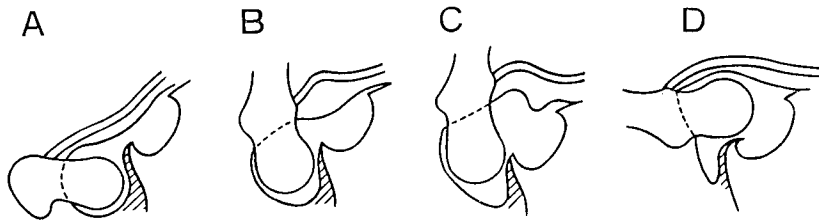


Fig. 2 Adhesion between the capsule and ilium. **A** : Coronal section with severe adhesion between the capsule and ilium. **B** : When the hip is flexed, the taut iliopsoas tendon is loosened. **C** : Although vertical traction is applied, the femoral head can not override the posterior labrum because of the posterior capsule adhering to the ilium. The inlet of the acetabulum is open. **D** : When the hip is abducted, the femoral head inverts the posterior labrum.

as an obstacle to closed reduction.

The fibrous adhesion around the posterior capsule was also one of the main extracapsular

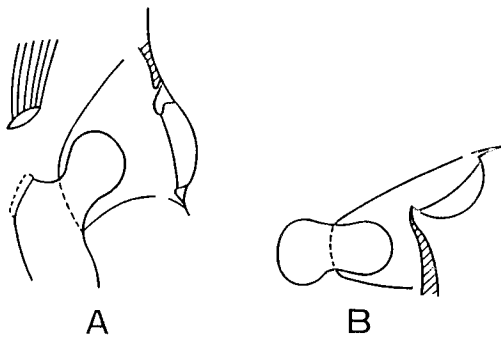


Fig. 3 The joint capsule is incised circumferentially near the acetabular rim, and the ligamentum capitis femoris is also excised. **A** : Anterior-posterior view. **B** : Lateral view.

obstacles (93 per cent). When the femoral head remained dislocated against the lateral pelvic wall for a prolonged period, the joint capsule often thickened and adhered heavily (Fig. 2). Such adhesion of the capsule could be relieved by our wide capsule exposure, by freeing the capsule from the surrounding muscles and dissecting the adhering tissue. This facilitated the circumferential incision of the joint capsule near the acetabular rim (Fig. 3), and also the complete dissection of the infero-anterior and infero-posterior parts of the capsule from the acetabular rim, the latter of which was most important to our concentric reduction (Fig. 4).

Inversion of the labrum was also an intracapsular obstacle to reduction (90 per cent). In such an inversion, the rounded and thickened labrum thorn and the narrowed inlet of the acetabulum

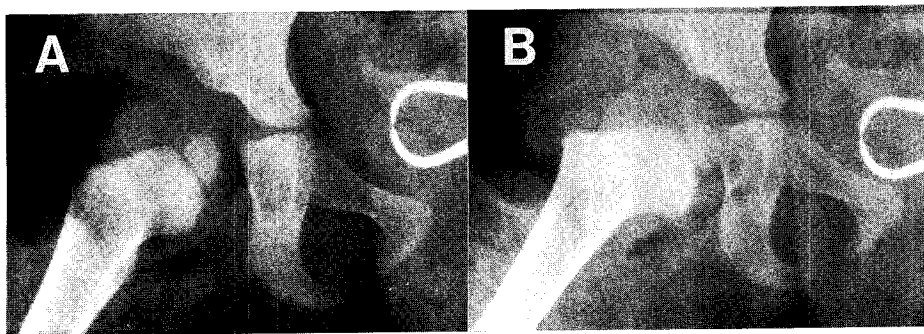


Fig. 4 Radiographic view of concentration by our procedure. **A** : When an attempt is made to reduce the femoral head before the joint capsule is incised circumferentially near the acetabular rim, a concentric reduction can not be made within the acetabulum. **B** : After dissection of the whole capsule, the femoral head is reduced satisfactorily.

were constantly observed. We rarely encountered labrum inversion at the postero-superior part as described by Somerville and Scott (3), except in cases subjected to long-term pre-operative conservative therapy. Most of our cases had an inversion of the anterior part of the labrum (70.9 per cent).

When the femoral head was reduced, it was easy to override the posterior labrum, though inversion of the anterior labrum frequently remained uncorrected and interposed between the femoral head and the acetabulum. This inversion was caused in part by tension along the transverse acetabular ligament. Transection of the ligament alleviated the inversion, and allowed a reduction of

the femoral head into a more concentric position. The incision at one or two sites on the labrum was useful when the inversion of the labrum was not corrected by the ligament transection. Removal of the hypertrophied ligamentum capitis femoris and the fibro-fatty tissue in the acetabulum was only necessary when they were intracapsular obstacles.

Clinical assessment. At the final visit, no patient had negative clinical signs, such as a significant limp, a positive Trendelenburg's sign, or coxalgia. They had no undue restrictions in school or home life or sport activities. The range of hip motion was not limited except for external rotation. In the thirty-seven unilateral cases,

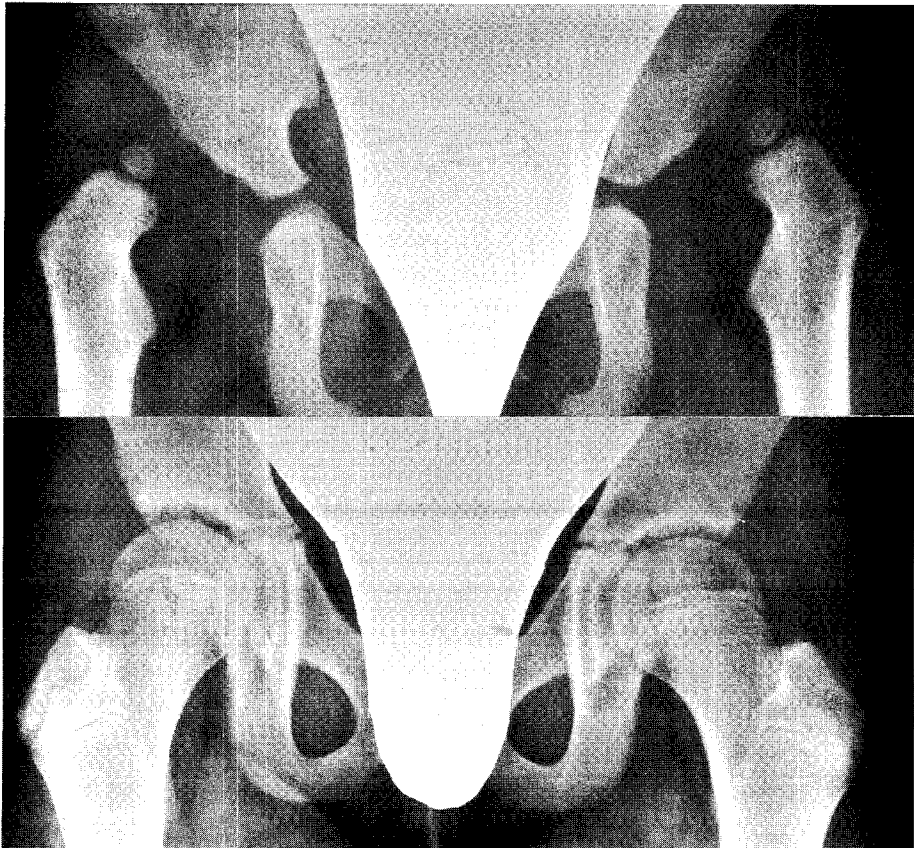


Fig. 5 A Severin's Group Ia result following our procedure. Top: Preoperative radiograph of a 17-month-old girl who had bilateral congenitally dislocated hips. By our open reduction method, the left hip was reduced at 19 months of age and the right hip at 2 years of age. Bottom: Radiograph made 10 years postoperatively, demonstrating normal hips.

Table 1 The discrepancies in the length of the affected leg to that of the other leg at the final follow-up session of the unilateral cases

Discrepancy	Number of cases
- 1.0 cm	1
0	12
0.5	7
1.0	13
1.5	4
	Total 37

external rotation was limited in eight hips (21.6 per cent), and twenty-four affected legs were longer than the normal leg (Table 1). Twelve patients had no discrepancy in leg length. In one case, the affected leg was 1 cm shorter than the other leg.

According to Gibson's classification (6), forty-eight patients (94.1 per cent) were clinically in Group I or excellent. Three cases were classified in Group II. No patients were included in Group III or IV.

Roentgenographic assessment. According to Severin's classification, thirty-three hips (56.9 per cent) were rated in Group I (Fig. 5), fourteen hips (24.1 per cent) in Group II, ten hips (17.2 per cent) in Group III, and one hip (1.7 per cent) in Group IV. There were no hips in Groups V or VI (Table 2).

Table 2 Radiological grading at the final visit

Treatment	Number of hips	Severin's Group											
		I			II			III		IV			
		a	b	%	a	b	%	%		a	b	%	
Open reduction	49	24	8	65.3	7	4	22.4	5	10.2	1	0	2.0	
Open reduction and subsequent op.	9	1	0	11.1	2	1	33.3	5	55.6	0	0	0.0	
Total	58	25	8	56.9	9	5	24.1	10	17.2	1	0	1.7	

Avascular necrosis of the hip was present in three patients, who had been treated unsuccessfully by manual reduction or a Pavlik harness before surgery. The incidence of avascular necrosis was 5.2 per cent of the fifty-eight hips in this series.

Complications. There were no intraoperative or postoperative complications, including wound infections. A redislocation in plaster occurred in one hip; a secondary operation was performed three weeks after the primary operation, and a good course followed subsequently.

Discussion

Indications for open reduction. In a child from one to three years of age, a careful closed reduction after a period of traction is a beneficial treatment method (9,19). However, closed reduction must usually be preceded by a long period of preoperative traction to minimize the risk of avascular necrosis (20,21). Also, after closed reduction most patients eventually undergo at least one additional surgical procedure.

Renshaw (22) cautioned that the femoral head cannot be relied on to compress the intervening soft tissue and seat itself normally, and suggested that open reduction may be indicated in such occasions. Leveuf (23) reported that a true luxation established by arthrography had to be treated by open reduction. Berkeley *et al.* (8) described that closed reduction should no longer be attempted for patients with a dislocated hip at walking age. However, we limited indication for

our open reduction to congenitally dislocated hips with interposed tissue revealed by arthrography (24), or to hips in which closed reduction could not be obtained under general anesthesia or maintained by Salter's human position (17).

Operative comparisons with other procedures.

In open reduction, Scaglietti and Calandriello (4) have emphasized the advantage of ample joint exposure and removal of all obstacles to achieve complete and stable reduction without stress. They have further described that any interference between the acetabulum and the femoral head is to be removed (4). Marchetti (25) has clearly supported this view from his follow-up study of operative cases. MacEwen (19) found that the inferior capsule is more difficult to view than the upper portion of the acetabulum and that the transverse acetabular ligament could not be fully visualized through the Smith-Petersen approach. Ludloff (11) and others (26, 27) have used the medial approach. Mau *et al.* (28) have reported that the medial approach is good for children under two years, but is not advisable for those over two years of age, because of reactive fibrosis and because contractures of soft tissues posterior to the hip joint cannot be adequately dealt with. Weinstein and Ponseti (29) have also supported the medial approach, saying that it provides a safe and effective way to reduce a dislocated hip in infancy.

However, detection of all obstacles is difficult. Although the medial approach is more useful for some patients under twelve months of age (29), the overhead traction method is effective, and in our experience for such cases there seems to be less risk of avascular necrosis.

Features of our open reduction procedure. Severin (18) showed that if the dislocated femoral head was brought to the inlet of the acetabulum in

closed treatment, it gradually seated in, resulting in reposition. However, if complete concentric reduction of the femoral head into the acetabulum is not obtained during open reduction, the space between the femoral head and the acetabulum becomes occupied with fibrous tissue, such as that found by Scaglietti and Calandriello (4) or Ludloff (11). Therefore, a surgical procedure is needed that removes various obstacles to reduction and assures reposition, even if the approach is rather extensive.

The adhesion around the capsule and torsion of the capsule are the main obstacles to reduction (2,14). Our procedure allows a complete dissection and circumferential incision of the capsule and also sufficiently removes any obstacle preventing complete reduction of the femoral head (14).

As described previously, our procedure was based on our findings that the early lack of joint concentricity is primarily responsible for high risk of degenerative changes of the joint (14). Similar findings have been reported by Gibson and Benson (6).

Comparison with results of other surgical procedures. As shown in Table 3, Gibson and Benson (6) examined their data on patients treated by Somerville's (3) method (preliminary traction, open reduction with excision of the labrum, and subsequent femoral osteotomy), and stated that only 46.5 per cent of hips reached Severin's Group I or II by this method. Platou (30) reported that four of sixteen cases showed excel-

Table 3 Radiographic results of open reduction of other studies

Investigators	Number of hips	Patients age (Years)	Percentage in Severin Group I or II	Follow-up period (Years)
Gibson and Benson (6)	147	1-3	46.5	16-31(av.21.5)
Platou (30)	16	1-5	25.0 ^a	10-13
Blockey (7)	27	1-4	48.1	18-27
Zionts and MacEwen (9)	13	1-3	61.5	7-23(av.15.5)
Salter and Dubos (5)	140	1.5-4	96.3	1.5-11(av.5.5)
Berkeley <i>et al.</i> (8)	51	1-3	92.0	2-12(av.6.1)
Marchetti (25)	234	1-3	59.8 ^b	3-

a: Excellent or good by Platou's criteria

b: Group I or II by McFarland's criteria

av: Average

lent or good results by his criteria. Blockley (7) showed that 48.1 per cent of his series reached Severin's Group I or II by a modified Somerville's method. Zions and MacEwen (9) reported that good results were obtained in eight of thirteen hips by the Smith-Petersen approach. Salter and Dubos (5) reviewed the results in patients who were treated by preliminary traction followed by open reduction, capsulorrhaphy, and innominate osteotomy. Berkeley *et al.* (8) described their results after open reduction, with a concomitant femoral derotation osteotomy and Pemberton's osteotomy. Marchetti (25) reported his results of open reduction by Scaglietti's method. Although Berkeley *et al.* (8), Marchetti (25), and Salter and Dubos (5) reported excellent or good results, the follow up periods were short.

In childhood, the clinical results of treatment are invariably better than the radiological results. However, Scaglietti and Calandriello (4) have described that normal motion was obtained in only 50 of 171 hips at six months to ten years after open reduction. Although our procedure requires a more extensive exposure than any other approach reported, a nearly normal range of hip motion was found (see above). In our long-term roentgenographic examination (9.7 years in the average), favorable results were obtained in 81 per cent (Severin's Group I or II) (see above). These data strongly indicate that our procedure is more useful than the previous ones, including the medial approach. However, it is considered that further follow-up studies may be necessary to predict the ultimate fate of hips treated by our procedure.

A disturbance in acetabular development is a common problem following open or closed reduction of a congenitally dislocated hip. Open reduction frequently requires additional surgical treatments, such as femoral osteotomy, a shelf operation, or pelvic osteotomy (5,8). Gibson and Benson (6) reported that additional secondary femoral and acetabular osteotomies were required in fifty-four hips (37 per cent) of their series. In only nine of our hips (17.6 per cent), secondary

operations were necessary, because a more normal acetabular development was obtained during the course of recovery. In ten of our hips, a dysplastic acetabulum inadequately covered the enlarged head; these hips showed no subluxation and were rated in Severin's Group III.

The incidence of avascular necrosis was 5.2 per cent in the present study. It was similar or lower in comparison with other studies after closed or open reduction (5, 6, 9, 21). Berkeley *et al.* (8) reported no avascular necrosis in his procedure. We consider our necrosis to be unrelated to surgical invasion, since avascular necrosis with epiphysial and metaphysial changes were present on radiographs before our open reduction.

Acknowledgments. We are grateful to Prof. Hajime Inoue and Dr. Koh Oda for their critical reading of this paper.

References

1. Poggi A: Contributo alla cura cruenta della lussazione congenita coxo-femorale unilaterale. *Arch Ortop* (1890) 7, 105.
2. Kidner FC: Importance of capsule attachments in the reduction of congenital dislocations of the hip. *J Bone Joint Surg* (1931) 13, 104-106.
3. Somerville EW and Scott JC: The direct approach to congenital dislocation of the hip. *J Bone Joint Surg* (1957) 39-B, 623-640.
4. Scaglietti O and Calandriello B: Open reduction of congenital dislocation of the hip. *J Bone Joint Surg* (1962) 44-B, 257-283.
5. Salter RB and Dubos JP: The first fifteen years' personal experience with innominate osteotomy in the treatment of congenital dislocation and subluxation of the hip. *Clin Orthop* (1974) 98, 72-103.
6. Gibson PH and Benson MKD: Congenital dislocation of the hip. Review at maturity of 147 hips treated by excision of the limbus and derotation osteotomy. *J Bone Joint Surg* (1982) 64-B, 169-175.
7. Blockley NJ: Derotation osteotomy in the management of congenital dislocation of the hip. *J Bone Joint Surg* (1984) 66-B, 485-490.
8. Berkeley ME, Dickson JH, Cain TE and Donovan MM: Surgical therapy for congenital dislocation of the hip in patients who are twelve to thirty-six months old. *J Bone Joint Surg* (1984) 66-A, 412-420.
9. Zions LE and MacEwen GD: Treatment of congenital dislocation of the hip in children between the ages of one and

- three years. *J Bone Joint Surg* (1986) **68-A**, 829-846.
10. Howorth MB: Congenital dislocation of the hip. Technic of open reduction. *Ann Surg* (1952) **135**, 508-519.
 11. Ludloff K: The open reduction of the congenital hip dislocation by an anterior incision. *Am J Orthop Surg* (1913) **10**, 438-454.
 12. Colonna PC: Capsular arthroplasty for congenital dislocation of the hip. A two-stage procedure. *J Bone Joint Surg* (1953) **35-A**, 179-197.
 13. Chung SMK, Scholl HW Jr, Ralston EL and Pendergrass EP: The Colonna capsular arthroplasty: A long-term follow-up study of fifty-six patients. *J Bone Joint Surg* (1971) **53-A**, 1511-1527.
 14. Tanabe G, Kunisada H and Miyake Y: A modified technique for open reduction of congenital dislocation of the hip. *J Jpn Orthop Assoc* (1977) **51**, 503-511 (in Japanese).
 15. Salter RB: Innominate osteotomy in the treatment of congenital dislocation and subluxation of the hip. *J Bone Joint Surg* (1961) **43-B**, 518-539.
 16. Pemberton PA: Pericapsular osteotomy of the ilium for the treatment of congenitally dislocated hips. *Clin Orthop* (1974) **98**, 41-54.
 17. Salter RB, Kostuik J and Dallas S: Avascular necrosis of the femoral head as a complication of treatment for congenital dislocation of the hip in young children: A clinical and experimental investigation. *Can J Surg* (1969) **12**, 44-61.
 18. Severin E: Contribution to the knowledge of congenital dislocation of the hip joint. Late results of closed reduction and arthrographic studies of recent cases. *Acta Chir Scand* (1941) **84**, 1-142.
 19. MacEwen GD: Treatment of congenital dislocation of the hip in older children. *Clin Orthop* (1987) **225**, 86-92.
 20. Gage JR and Winter RB: Avascular necrosis of the capital femoral epiphysis as a complication of closed reduction of congenital dislocation of the hip. A critical review of twenty years' experience at Gillette Children's Hospital. *J Bone Joint Surg* (1972) **54-A**, 373-388.
 21. Ponseti I V and Frigerio ER: Results of treatment of congenital dislocation of the hip. *J Bone Joint Surg* (1959) **41-A**, 823-846.
 22. Renshaw TS: Inadequate reduction of congenital dislocation of the hip. *J Bone Joint Surg* (1981) **63-A**, 1114-1121.
 23. Leveuf J: Results of open reduction of "true" congenital luxation of the hip. *J Bone Joint Surg* (1948) **30-A**, 875-882.
 24. Miyake Y: Evaluation of arthrogram of congenital dislocation of the hip. —Especially for the strangulation of ligamentum transversum acetabuli—. *Cent Jpn J Orthop Traumat* (1967) **10**, 467-483 (in Japanese).
 25. Marchetti PG: Open reduction of congenital dislocation of the hip: 384 consecutive cases; in *Congenital Dislocation of the Hip*, Tachdjian ed, 1st Ed, Churchill Livingstone, New York (1982) pp401-415.
 26. Ferguson AB Jr: Primary open reduction of congenital dislocation of the hip using a median adductor approach. *J Bone Joint Surg* (1973) **55-A**, 671-689.
 27. Salzer M und Zückriegel H: Die Operationstechnik der offene Hüftgelenksreposition nach Ludloff. *Z Orthop* (1967) **103**, 409-417.
 28. Mau H, Dörr WM, Henkel L and Lutsche J: Open reduction of congenital dislocation of the hip by Ludloff's method. *J Bone Joint Surg* (1971) **53-A**, 1281-1288.
 29. Weinstein SL and Ponseti IV: Congenital dislocation of the hip. Open reduction through a medial approach. *J Bone Joint Surg* (1979) **61-A**, 119-124.
 30. Platou E: Open operation for congenital dislocation of the hip: Results in forty-four cases (fifty hip joints). *J Bone Joint Surg* (1950) **32-B**, 193-202.

Received February 26, 1990; accepted May 8, 1990.