

Acta Medica Okayama

Volume 60, Issue 5

2006

Article 6

OCTOBER 2006

Severe Interstitial Pneumonia Induced by Paclitaxel in a Patient with Adenocarcinoma of the Lung

Noriyuki Suzaki, *Okayama University*
Akio Hiraki, *Okayama University*
Nagio Takigawa, *Okayama University*
Hiroshi Ueoka, *Okayama University*
Yasushi Tanimoto, *Okayama University*
Toshiyuki Kozuki, *Okayama University*
Masahiro Tabata, *Okayama University*
Arihiko Kanehiro, *Okayama University*
Katsuyuki Kiura, *Okayama University*
Mitsune Tanimoto, *Okayama University*

Severe Interstitial Pneumonia Induced by Paclitaxel in a Patient with Adenocarcinoma of the Lung*

Noriyuki Suzaki, Akio Hiraki, Nagio Takigawa, Hiroshi Ueoka, Yasushi Tanimoto, Toshiyuki Kozuki, Masahiro Tabata, Arihiko Kanehiro, Katsuyuki Kiura, and Mitsune Tanimoto

Abstract

A 71-year-old Japanese man with adenocarcinoma of the lung developed interstitial pneumonia after treatment with paclitaxel. The patient had acute chills and fever on the fourth day after the second exposure to paclitaxel, rapidly got worse despite empiric therapies, and developed prolonged respiratory failure requiring mechanical ventilation. Four months later, he died of respiratory failure due to progression of both interstitial pneumonia and lung cancer. This is the first case developing fatal paclitaxel-induced pulmonary toxicity to date. Interstitial pneumonia should be considered one of the possible life-threatening complications during treatment with paclitaxel.

KEYWORDS: paclitaxel, adverse effect, lung cancer, interstitial pneumonia

*PMID: 17072376 [PubMed - in process]

Case Report

Severe Interstitial Pneumonia Induced by Paclitaxel in a Patient with Adenocarcinoma of the Lung

Noriyuki Suzaki^a, Akio Hiraki^{a,b}, Nagio Takigawa^{a*}, Hiroshi Ueoka^{a,b},
Yasushi Tanimoto^a, Toshiyuki Kozuki^a, Masahiro Tabata^a,
Arihiko Kanehiro^a, Katsuyuki Kiura^a, and Mitsune Tanimoto^a

^aDepartment of Respiratory Medicine, Okayama University Hospital, Okayama 700-8558, Japan, and

^bDepartment of Respiratory Medicine, NHO Sanyo National Hospital,
Respiratory Disease Center, Ube, Yamaguchi 755-0241, Japan

A 71-year-old Japanese man with adenocarcinoma of the lung developed interstitial pneumonia after treatment with paclitaxel. The patient had acute chills and fever on the fourth day after the second exposure to paclitaxel, rapidly got worse despite empiric therapies, and developed prolonged respiratory failure requiring mechanical ventilation. Four months later, he died of respiratory failure due to progression of both interstitial pneumonia and lung cancer. This is the first case developing fatal paclitaxel-induced pulmonary toxicity to date. Interstitial pneumonia should be considered one of the possible life-threatening complications during treatment with paclitaxel.

Key words: paclitaxel, adverse effect, lung cancer, interstitial pneumonia

Paclitaxel (Taxol, Bristol-Myers-Squibb, Princeton, NJ, USA) is a taxane anti-neoplastic agent with a broad spectrum of activity for various cancers. Major adverse effects are peripheral neuropathy, myelotoxicity, bradycardia, hypotension, arthralgia, myalgia, granulocytopenia and hypersensitivity [1, 2]. Hypersensitivity reactions are well-recognized complications of paclitaxel administration and typically occur during the first or second exposure [3, 4]. These reactions, consisting of dyspnea with or without bronchospasms, urticaria, rashes, hypotension, or angioedema, have been thought to be attributable to both paclitaxel itself

and to its diluent, Cremophor EL. Because of the high incidence of hypersensitivity reactions, a standardized premedication regimen using high-dose dexamethasone, diphenhydramine, and cimetidine is prescribed for prophylaxis of paclitaxel-induced hypersensitivity reactions in Japan.

Although several cases developing paclitaxel-induced interstitial pneumonia have been reported to date [5], they have generally responded to corticosteroid treatment. A fatal case of paclitaxel-induced interstitial pneumonia has not been reported in the literature to date. We describe here a patient with advanced adenocarcinoma of the lung developing acute life-threatening interstitial pneumonia on the fourth day after the second exposure to paclitaxel, and review the previous reports of interstitial pneumonia induced by paclitaxel.

Received March 27, 2006; accepted May 22, 2006.

*Corresponding author. Phone: +81-86-235-7227; Fax: +81-86-232-8226
E-mail: ntakigaw@md.okayama-u.ac.jp (N. Takigawa)

Case Report

A 71-year-old Japanese man was diagnosed with adenocarcinoma of the lung by the cytological examination of pleural effusion at a local clinic and referred to our hospital. He had a 40-pack-a-year history of cigarette smoking and no history of pulmonary disease. He had been a clerical staff member at city hall, and he had no allergic history.

Physical examination on admission revealed a weakness of breath sounds in the right lung. Laboratory findings showed an elevated white blood cell (WBC) count (9,000/mm³), serum levels of C-reactive protein (CRP: 7.3 mg/dl), carcinoembryonic antigen (CEA: 29.76 ng/ml), progastrin releasing peptide (pro-GRP: 38.3 pg/ml), sialyl Lewis-X-I antigen (SLX: 54.1 U/ml), and neuron-specific enolase (NSE: 18.70 ng/ml). Arterial blood gas analysis revealed that the pH was 7.42, PaO₂ 77.3 mmHg,

and PaCO₂ 40.0 mmHg. Computed tomography (CT) scans of the chest revealed a nodule on the right S³_b, mediastinal lymph node swelling, and right pleural effusion without interstitial lung disease. Pulmonary function data were as follows: 1-second forced expiratory volume, 79.4%; vital capacity, 47.9%; carbon monoxide diffusing capacity, 12.5 mL/min/mmHg (78.9%). After completion of the staging work-ups, the clinical stage was determined to be T4N2M1 (stage IV). Systemic chemotherapy consisting of paclitaxel 80 mg/m² (130 mg/body) by 1-hour intravenous infusion given on days 1 and 8 was started. He was given premedication consisting of dexamethasone (16 mg), diphenhydramine (50 mg), and ranitidine (50 mg).

On day 12, he felt feverish and had chills. His temperature was 37.9 °C, pulse 75/min, blood pressure 138/80 mmHg, respiratory rate 25/min, and oxygen saturation (SaO₂) 90% with room air. Arterial blood gas analysis showed that pH was 7.46,

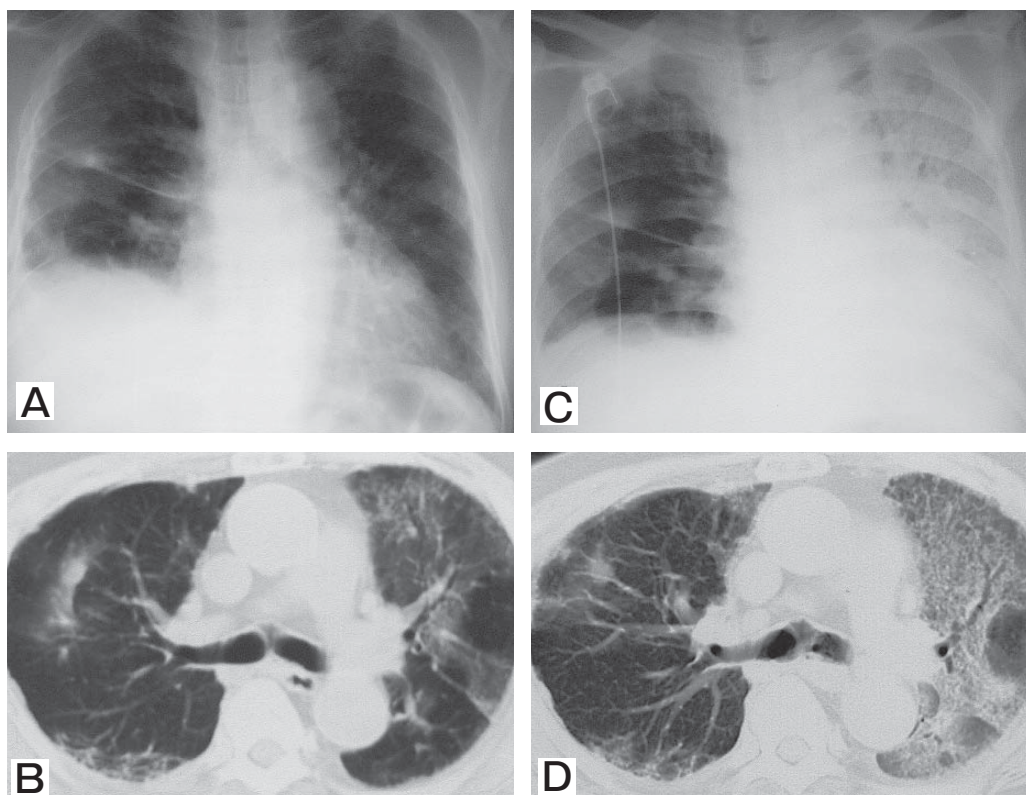


Fig. 1 A, Chest radiograph shows diffuse shadows in the left middle and lower lung fields; B, CT scans of the chest demonstrate ground-glass opacities; C, D: Chest radiograph and CT scans of the chest showed extensive areas of ground-glass opacities and traction bronchiectasis. The distribution was predominantly in the lower zone.

PaO₂ 63.5 mmHg, and PaCO₂ 34.4 mmHg. Mild fine crackles were audible in the left lung. The WBC count was 3,300/mm³, including 70.0% neutrophils and 22.0% lymphocytes. Serum levels of CRP, lactate dehydrogenase, and KL-6 were 15.0 mg/dl, 704 U/l, and 1,139 U/ml, respectively. Culture of the sputum and peripheral blood detected no pathogenic organisms. Serological tests for candida, mycoplasma, pneumocystis jiroveci, and cytomegalovirus were negative. The chest radiograph showed diffuse shadows in the left middle and lower lung fields (Fig. 1A). CT scans of the chest demonstrated ground-glass opacities (Fig. 1B). We therefore determined that he had paclitaxel-induced interstitial pneumonia.

He was immediately treated with steroid pulse therapy (methylprednisolone, 1 g/day for 3 days). Five days later, since his symptoms and the interstitial shadows on the chest radiograph did not improve, he received the second cycle of steroid pulse therapy (methylprednisolone, 2 g/day for 3 days). Furthermore, he was given cyclophosphamide (750 mg/day) on day 31 from the initiation of chemotherapy (10 days after the last pulse therapy), but his general condition did not improve. CT scans of the chest showed extensive areas of ground-glass opacities with interlobular septal thickening and traction bronchiectasis, and the distribution was predominantly in the lower zone (Fig. 1C, D). He was then intubated with mechanical ventilatory support the next day. On day 128 from the initiation of chemotherapy, he died of respiratory failure due to progression of interstitial pneumonia and lung cancer. Autopsy was not allowed.

Discussion

Drug-induced interstitial pneumonia is a rare complication of paclitaxel administration. There have been a few reports of paclitaxel-induced interstitial pneumonia to date. Furuse *et al.* have reported that the incidence of interstitial pneumonia in patients with previously untreated advanced NSCLC is approximately 3% in phase II [1], but that it increases to approximately 50% in patients with locally advanced NSCLC receiving concurrent radiotherapy [6]. Although premedication for paclitaxel administration is commonly carried out for prophylaxis of hypersensitivity reactions, the true efficacy is still unconfirmed because severe hypersensitivity reactions have been reported despite premedication, just as we experienced in this case. Docetaxel and paclitaxel have similar mechanisms of action as microtubule-stabilizing drugs and have similar adverse effects of interstitial pneumonia. Although there have been several reports of severe interstitial pneumonia by docetaxel [7, 8], this is the first known case to developing fatal paclitaxel-induced pulmonary toxicity. Interstitial pneumonia induced by gefitinib and leflunomide tends to occur in Japanese more frequently than in Westerners [9, 10]. To our best knowledge, interstitial pneumonia has not been reported in Western phase II studies of paclitaxel monotherapy, although there have been a few case reports [4, 5, 11]. Two Japanese phase II studies, reported by Furuse *et al.* and Sekine *et al.*, have shown the frequency of interstitial pneumonia to be 3% and 1.7%, respectively [1, 2]. As such, there may be ethnic differences in the frequency of interstitial pneumonia by paclitaxel.

The mechanism of drug-induced interstitial pneumonia is not well understood. Most researchers agree that it is the consequence of a cell-mediated immunologic reaction. Drug-induced interstitial pneumonia is diagnosed by a drug lymphocyte stimulation test (DLST) coupled with bronchoalveolar lavage or transbronchial lung biopsy findings. However, these examinations could not be performed in the present case due to severe respiratory failure caused by life-threatening pneumonia. DLST using peripheral blood is also useful as an *in vitro* method of screening for drug allergy. It should have been performed in this patient, although the positive ratio was reported to be only 33% [12] and a positive result does not indicate the drug responsible for the symptoms, only a sensitization to that drug [13]. In the present case, paclitaxel-induced pneumonia was diagnosed by excluding the other possible etiologies and considering the clinical course.

The first treatment for paclitaxel-induced interstitial pneumonia is the withdrawal of this drug. Some patients developing paclitaxel-induced pneumonia improve spontaneously [11]. The second choice of treatment is administration of corticosteroid. Usually prednisolone at a dose of 30 to 60 mg per day is given for 2 to 3 weeks, and higher doses like pulse

therapy are administered for more severe conditions such as acute respiratory failure, with a slow and careful tapering-off period. Because paclitaxel-induced interstitial pneumonia usually responds rapidly to steroid therapy [5, 11], steroid-refractory cases have not been reported. Although this patient had no history of pulmonary disease or thoracic radiation therapy, he responded to neither an immunosuppressive agent nor steroid pulse therapy. In several cases, predominant CT findings showed ground-glass opacities and interlobular septal thickening [14]. The CT images of drug-induced pneumonia are usually classified into interstitial pneumonia/fibrosis, diffuse alveolar damage, organizing pneumonia reaction, or a hypersensitivity reaction [15]. Ichikado *et al.* have reported that patients with acute interstitial pneumonia who have CT findings suggestive of the fibroproliferative phase of diffuse alveolar damage, particularly findings of architectural distortion, and ground-glass attenuation associated with traction bronchiectasis, have a worse prognosis than patients without these findings [16]. In the present case, CT findings showed ground-glass opacities and traction bronchiectasis, which were compatible with acute lung injury characterized pathologically by diffuse alveolar damage [17]. If CT findings in paclitaxel-induced pneumonia show traction bronchiectasis during the acute phase, the prognosis may be worse.

In conclusion, we have reported herein a case with advanced lung cancer developing paclitaxel-induced, acute life-threatening interstitial pneumonia. Although this complication rarely occurs, physicians should be alert to this unusual and possibly life-threatening adverse effect of paclitaxel, in order to begin treatment as soon as possible.

References

1. Furuse K, Naka N, Takada M, Kinuwaki E, Kudo S, Takada Y, Yamakido M, Yamamoto H and Fukuoka M: Phase II study of 3-hour infusion of paclitaxel in patients with previously untreated stage III and IV non-small cell lung cancer. West Japan Lung Cancer Group. *Oncology* (1997) 54: 298–303.
2. Sekine I, Nishiwaki Y, Watanabe K, Yoneda S and Saijo N: Phase II study of 3-hour infusion of paclitaxel in previously untreated non-small cell lung cancer. *Clin Cancer Res* (1996) 2: 941–945.
3. Fujimori K, Yokoyama A, Kurita Y, Uno K and Saijo N: Paclitaxel-induced cell-mediated hypersensitivity pneumonitis. Diagnosis using leukocyte migration test, bronchoalveolar lavage and trans-bronchial lung biopsy. *Oncology* (1998) 55: 340–344.
4. Wong P, Leung AN, Berry GJ, Atkins KA, Montoya JG, Ruoss SJ and Stockdale FE: Paclitaxel-induced hypersensitivity pneumonitis: radiographic and CT findings. *Am J Roentgenol* (2001) 176: 718–720.
5. Sotiriou C, van Houtte P and Klasterky J: Lung fibrosis induced by paclitaxel. *Support Care Cancer* (1998) 6: 68–71.
6. Reckzeh B, Merte H, Pfluger KH, Pfab R, Wolf M and Havemann K: Severe lymphocytopenia and interstitial pneumonia in patients treated with paclitaxel and simultaneous radiotherapy for non-small-cell lung cancer. *J Clin Oncol* (1996) 14: 1071–1076.
7. Wang GS, Yang KY and Perng RP: Life-threatening hypersensitivity pneumonitis induced by docetaxel (taxotere). *Br J Cancer* (2001) 85: 1247–1250.
8. Read WL, Mortimer JE and Picus J: Severe interstitial pneumonitis associated with docetaxel administration. *Cancer* (2002) 94: 847–853.
9. Cohen MH, Williams GA, Sridhara R, Chen G, McGuinn WD Jr, Morse D, Abraham S, Rahman A, Liang C, Lostritto R, Baird A and Pazdur R: United States Food and Drug Administration Drug Approval summary: Gefitinib (ZD1839; Iressa) tablets. *Clin Cancer Res* (2004) 10: 1212–1218.
10. McCurry J: Japan deaths spark concerns over arthritis drug. *Lancet* (2004) 363: 461.
11. Ramanathan RK, Reddy VV, Holbert JM and Belani CP: Pulmonary infiltrates following administration of paclitaxel. *Chest* (1996) 110: 289–292.
12. Kondo A: Drug-induced pneumonitis. *Kekkaku* (1999) 74: 33–34 (in Japanese).
13. Nakamura R, Imamura T, Onitsuka H, Mishima K, Ishikawa T, Nagoshi T, Fujiura Y, Date H, Maeno M, Matsuo T, Koiwaya Y and Eto T: Interstitial pneumonia induced by ticlopidine. *Circ J* (2002) 66: 773–776.
14. Akira M, Ishikawa H and Yamamoto S: Drug-induced pneumonitis: thin-section CT findings in 60 patients. *Radiology* (2002) 224: 852–860.
15. Cleverley JR, Screamon NJ, Hiorns MP, Flint JD and Muller NL: Drug-induced lung disease: high-resolution CT and histological findings. *Clin Radiol* (2002) 57: 292–299.
16. Ichikado K, Suga M, Muller NL, Taniguchi H, Kondoh Y, Akira M, Johkoh T, Mihara N, Nakamura H, Takahashi M and Ando M: Acute interstitial pneumonia: comparison of high-resolution computed tomography findings between survivors and nonsurvivors. *Am J Respir Crit Care Med* (2002) 165: 1551–1556.
17. Schwarz MA: Acute lung injury: cellular mechanisms and derangements. *Paediatr Respir Rev* (2001) 2: 3–9.