

Acta Medica Okayama

Volume 38, Issue 5

1984

Article 4

OCTOBER 1984

Brain tumors in hamsters induced by murine sarcoma virus (Moloney).

Makoto Motoi*

Katsuo Ogawa†

*Okayama University,

†Okayama University,

Brain tumors in hamsters induced by murine sarcoma virus (Moloney).*

Makoto Motoi and Katsuo Ogawa

Abstract

Murine sarcoma virus, CS-Moloney substrain, was inoculated intracranially into 2 litters of newborn Syrian hamsters within 24 h of birth. Seven of 12 hamsters which survived more than 30 days developed brain tumors in the cerebral cortex 104 to 153 days, 139 days on the average, after the virus inoculation. The tumors consisted of spindle-shaped, round or polygonal astrocytes which showed a positive reaction for glial fibrillary acidic protein by the immunoperoxidase method.

KEYWORDS: brain tumors, hamsters, MSV-CS-Moloney

*PMID: 6097099 [PubMed - indexed for MEDLINE]

Copyright (C) OKAYAMA UNIVERSITY MEDICAL SCHOOL

Acta Med. Okayama 38, (5), 447-452 (1984)

BRAIN TUMORS IN HAMSTERS INDUCED BY MURINE SARCOMA VIRUS (MOLONEY)

Makoto MOTOI and Katsuo OGAWA

Department of Pathology, Okayama University Medical School, Okayama 700, Japan

(Director : Prof. K. Ogawa)

Received May 9, 1984

Abstract. Murine sarcoma virus, CS-Moloney substrain, was inoculated intracranially into 2 litters of newborn Syrian hamsters within 24 h of birth. Seven of 12 hamsters which survived more than 30 days developed brain tumors in the cerebral cortex 104 to 153 days, 139 days on the average, after the virus inoculation. The tumors consisted of spindle-shaped, round or polygonal astrocytes which showed a positive reaction for glial fibrillary acidic protein by the immunoperoxidase method.

Key words : brain tumors, hamsters, MSV-CS-Moloney.

Since 1960, numerous attempts to induce experimental brain tumors in mammals by both RNA and DNA types of oncogenic viruses have been made (1). The histological characteristics of the tumors appear to be distinctive for each oncogenic virus.

In 1965, murine sarcoma virus of the Moloney strain (MSV-M) was isolated from leukemic mice inoculated with the Moloney leukemic agent (2). In 1969, Ida *et al.* (3) isolated a MSV-CS-Moloney substrain (MSV-CS-M) from "congenital sarcoma" in newborn mice that had undergone intrauterine injection with MSV-M. When the substrain virus was inoculated intraperitoneally into newborn Sprague-Dawley rats, the rats developed sarcoma and bone tumors (3). When the virus was injected intracranially into newborn rats and mice, most of the animals developed brain tumors which histologically corresponded to gliomas with hemangiomatous components (4-6).

The present paper deals with the brain tumors induced by MSV-CS-M in Syrian hamsters.

MATERIALS AND METHODS

Virus preparations. Four mice inoculated intracranially with MSV-CS-M were supplied by the courtesy of Dr. N. Ida (Toyo Kogyo Hospital, Hiroshima, Japan). The brains infected with the virus were minced, suspended in 0.02 M phosphate-buffered saline (PBS) (1 g/ml) and homogenized with a Potter and Elvehjem type of homogenizer. The homogenate was centrifuged at 10,000 rpm for 30 min. at 4°C. The supernatant was used as inoculum.

Animals and virus inoculation : Seventeen newborn hamsters from two litters were inoculated intracranially with 0.02 ml of the virus fluid in the right parieto-occipital region. Twelve

hamsters that survived more than 30 days were observed until death by tumor or until moribund.

Histological and immunohistochemical examinations. All hamsters were subjected to a necropsy. The brains were fixed immediately in 10 % formalin and cut sagittally. The specimens were embedded in paraffin, sectioned and stained with hematoxyline and eosin, and silver impregnation. For detection of glial fibrillary acidic protein (GFAP), the tissue sections were stained by the peroxidase anti-peroxidase method described previously (7). Antiserum against GFAP was obtained commercially from DAKO Laboratories and used at a 1 : 100 dilution.

RESULTS

Seven of the 12 hamsters available for the observation developed brain tumors 104 to 153 days, 139 days on the average, after the virus inoculation (Table 1). Some of them showed neurological symptoms such as convulsions or paralysis of the legs. Brain tumors were fairly well defined and soft in consistency. The cut surface was solid and reddish-gray in color. All of the tumors developed in the cerebral cortex. Most of the tumors enlarged so much that the primary site could not be decided precisely. No tumor developed in the cerebellum, spinal cord or any other organs.

All of the brain tumors showed essentially the same histological features. Tumors were always highly cellular, and composed mainly of spindle-shaped, fibrillated cells that formed an interlacing pattern (Fig. 1). The nucleus was oval or elongated with one or two distinct nucleoli. The cytoplasm was slender and eosinophilic (Fig. 2). In some parts, round tumor cells intermingled with spindle-shaped ones or appeared in clusters (Fig. 3). The round cells had a round or oval eccentric nuclei with distinct nucleoli and a deeply eosinophilic

TABLE 1. INDUCTION OF BRAIN TUMORS IN HAMSTERS BY MSV-CS-M

No. of hamsters Inoculated with virus*	No. of hamsters which survived more than 30 days	No. of hamsters with brain tumor	Latency period (Days)
17	12	7 (58.3 %)	104 - 153

*The virus was inoculated intracranially.

Fig. 1. Spindle-shaped tumor cells form interlacing bundles H.E., $\times 100$

Fig. 2. A high power view of the spindle-shaped tumor cells shown in Fig. 1. H. E. $\times 400$

Fig. 3. Round tumor cells resembling gemistocytic astrocytes proliferate in clusters. H. E. $\times 40$

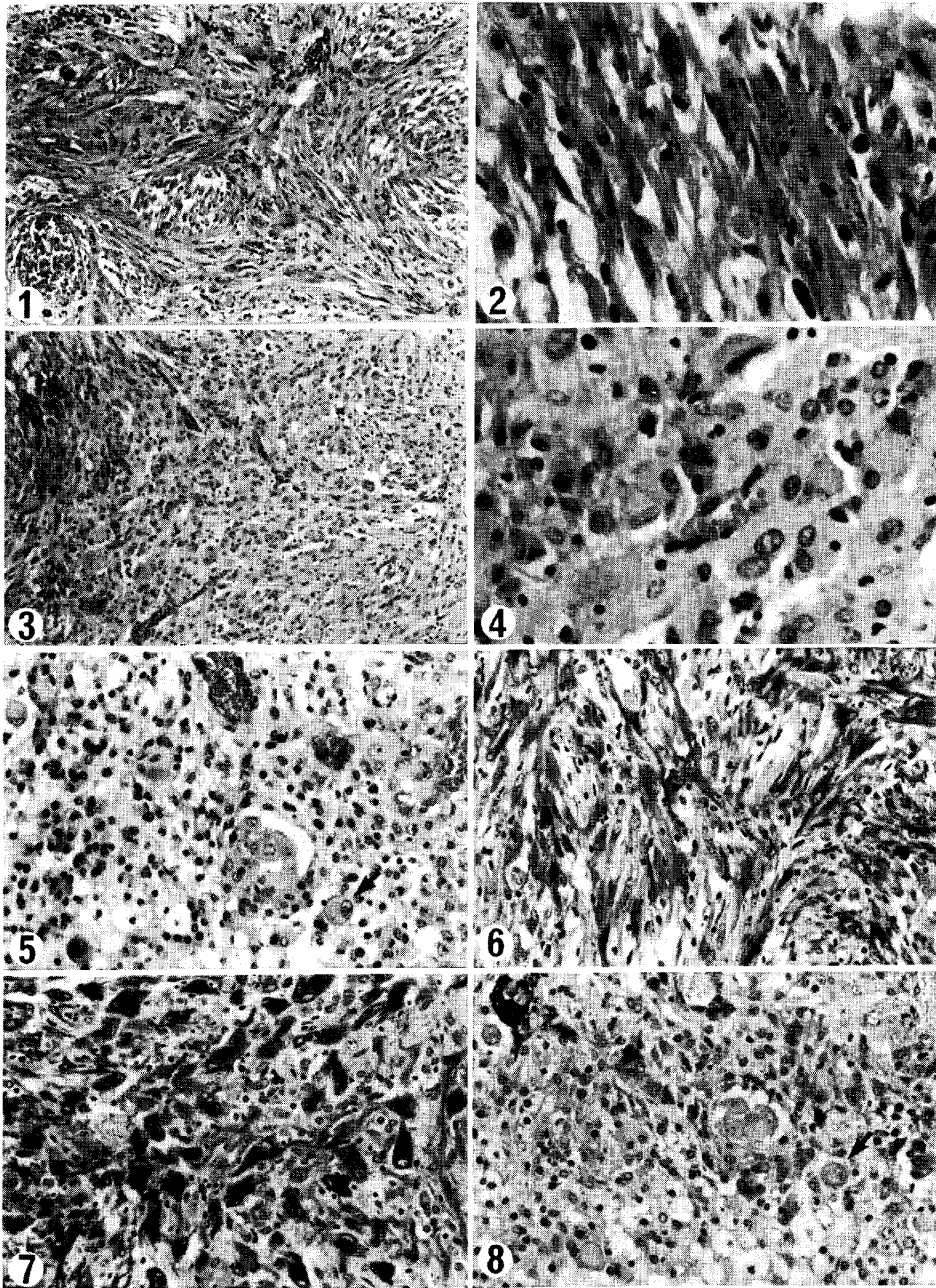
Fig. 4. A high power view of the round or polygonal tumor cells shown in Fig. 3. H. E. $\times 400$

Fig. 5. Granulomatous lesion with large round cells (arrow) around a brain tumor. H. E. $\times 200$

Fig. 6. Spindle-shaped tumor cells are positive for GFAP. PAP method, $\times 200$

Fig. 7. Round tumor cells are positive for GFAP. PAP method, $\times 200$

Fig. 8. Large round cells (arrow) in a granulomatous lesion are negative for GFAP. PAP method, $\times 200$



cytoplasm. The cell border was not distinct in hematoxyline-eosin stained sections (Fig. 4). These tumor cells were slightly atypical, but multinucleated giant cells were not found. There were neither necrotic foci nor endothelial proliferation of the vessels in the tumor tissue. With silver impregnation, no reticulin fibers were seen among tumor cells except for perivascular areas.

Around some brain tumors, granulomatous lesions were found which consisted of inflammatory cell infiltration, vascular proliferation and reactive gliosis. The lesions also contained a few large round cells with large round nuclei and abundant eosinophilic cytoplasm (Fig. 5).

Cytoplasm and processes of both elongated and round or polygonal tumor cells stained positively for GFAP (Figs. 6, 7). In particular, the round tumor cells were strongly positive. However, the intensity of the immunostain and the number of positive cells varied among the tumors. On the contrary, large round cells in the granulomatous lesions were negative for GFAP (Fig. 8).

DISCUSSION

MSV-Moloney (MSV-M) (8), MSV-Harvey (9) and MSV-Kirsten (10) are known to produce various mesenchymal tumors in soft tissues of mice and rats. In the central nervous system, Ribacchi and Giraldo (11) reported that MSV-M induced leptomenigeal hemangioendothelioma, meningioma and glioblastoma in rats. Moreover, Ida *et al.* (3) isolated the MSV-CS-M substrain after serial transplantation of a sarcoma that developed in newborn mice exposed to intrauterine infection with MSV-M. The virus induced angiogenic tumors with coexisting gliomas in the brain of mice and rats (4). These results were confirmed and examined in detail by Nakamura (6) and Jinno (5).

Results of the present experiment indicate that MSV-CS-M produces intracranial tumors in hamsters with a relatively high incidence. The tumors are classified as astrocytomas according to their histological appearance and the intracytoplasmic presence of GFAP, and are essentially similar to those reported in rats (4, 6) and mice (4, 5).

Coexisting granulomatous lesions are characteristic of MSV-CS-M-induced brain tumors in mice and rats, especially so in mice. The length of the latency period for tumor development seems to influence for the extent of granulomatous lesions. The average latency period has been shown to be 18 days (4) or 16.5 days (5) in mice, 26 days (4) or 84 days (6) in rats. Granulomatous lesions in rats (6) have been found to be prominent 8 to 35 days after the virus inoculation and to result in gliosis after more than 35 days. In contrast to the short latency period in mice and rats, that in hamsters was as long as 139 days. Granulomatous lesions in brain tumors were not as prominent in hamsters as in mice and rats and were located close to tumors in the cerebral cortex.

These granulomatous lesions are considered to be a kind of inflammatory reaction to the virus infection and are known to diminish gradually in the course

of time. However, true neoplastic proliferation of astrocytes occurred in the granulomatous lesions independent of inflammatory reactions. As Ohshima has reported in connection with the oncogenesis of chicken sarcoma (12), the accompanying granulomatous lesions may be necessary also for development of MSV-CS-M-induced brain tumor, at least in the early cancerous stage.

The histology of the MSV-CS-M-induced brain tumors is quite similar to that of tumors induced in mice and rats with Rous sarcoma virus (RSV) (13). The main cellular component of RSV-induced brain tumors was the gemistocytic astrocyte, but the tumors also contained spindle-shaped cells in clusters and small cells with fibrillary processes. In some tumors, blood vessels were abundant, and the tumor had an angiomatous appearances.

DNA tumor viruses induce meningioma, ependymoma and undifferentiated neuroectodermal tumors, while MSV and RSV, RNA viruses of the murine and avian leukosis complex, preferentially induce mature gliomas of the same astrocytic nature regardless of the animal specieses (1). Moreover, in contrast to DNA virus-induced brain tumors, the gliomas induced by RNA viruses are often accompanied by granulomatous lesions in the early developmental stage.

REFERENCES

1. Motoi, M. and Ogawa, K.: Exrerimental brain tumors induced by oncogenic viruses. In *Gendai Byorigaku Taikei* Vol. 23 B ed. S. Iijima, E. Ishikawa, K. Kageyama, and T. Shimamine, Nakayama-Shoten, Tokyo, in press (in Japanese).
2. Moloney, J.B.: The application of studies in murine leukemia to the problems of human neoplasia. In *Some Recent Developments in Comparative Medicine*, ed. R. Finnes, Academic Press Inc., London, pp. 251-258, 1965.
3. Ida, N., Ikawa, Y. and Ohba, Y.: Studies on hypodiploid and hyperdiploid virus-induced mouse leukemias and the vertical transmission of MSV-Moloney. In *Comparative Leukemia Research 1969*. *Bibl. Haemat.* 36, ed. R.M. Dutcher, Karger, Basel, pp. 221-233, 1970.
4. Ida, N., Ikawa, Y., Ogawa, K., Takada, M. and Yokoi, E.: Intracranial tumors in rats and mice produced by MSV-CS-Moloney substrains. *Proc. Jpn. Cancer. 29th Ann. Meet.* p. 97, 1970 (in Japanese).
5. Jinno, K.: Large round cell granulomas induced by murine sarcoma virus (Moloney) in mouse. *Acta Med. Okayama* 29, 291-317, 1975.
6. Nakamura, S.: The pathology of brain tumors induced by murine sarcoma virus, Moloney strain. *Acta Med. Okayama* 30, 227-244, 1976.
7. Motoi, M., Yoshino, T., Kawabata, K., Ikehara, I., Ohsumi, S. and Ogawa, K.: Immunohistochemical demonstration of lysozme in normal, reactive and neoplastic cells of the mononuclear phagocyte system. *Acta Med. Okayama* 38, 125-133, 1984.
8. Moloney, J.B.: A virus-induced rhabdomyosarcoma of mice. *Natl. Cancer Inst. Monogr.* 22, 139-142, 1966.
9. Harvey, J.J.: An unidentified virus which causes the rapid production of tumors in mice. *Nature* 204, 1104-1105, 1964.
10. Kirsten, W.H. and Mayer, L.A.: Morphologic responses to a murine erythroblastosis virus. *J. Natl. Cancer Inst.* 39, 331-335, 1967.

11. Ribacchi, R. and Giraldo, G.: Intracranial tumors in rats injected intracerebrally with murine sarcoma virus (MSV), Moloney's strain. Preliminary report. *Lav. Anat. Pat. Perugia* **26**, 141-148, 1966.
12. Ohshima, F.: Pathology of chicken sarcoma. *Acta Pathol. Jpn.* **40**, 13-21, 1951.
13. Ikuta, F. and Kumanishi, T.: Experimental virus-induced brain tumors. In *Progress in Neuropathology*, vol. II, ed. H.M., Zimmerman, Grune & Stratton, New York, London, pp. 253-334, 1973.