

Acta Medica Okayama

Volume 43, Issue 1

1989

Article 8

FEBRUARY 1989

Angiocardiographic quantitative evaluation of double-outlet right ventricle: special reference to the morphology of the common outflow tract.

Sugato Nawa* Makoto Yamada[†] Eiji Sugawara[‡]
Kohichi Kino** Shigeru Teramoto^{††}

*Okayama University,

[†]Okayama University,

[‡]Okayama University,

**Okayama University,

^{††}Okayama University,

Angiocardiographic quantitative evaluation of double-outlet right ventricle: special reference to the morphology of the common outflow tract.*

Sugato Nawa, Makoto Yamada, Eiji Sugawara, Kohichi Kino, and Shigeru Teramoto

Abstract

Geometrical measurements of angiocardiograms of the common outflow tract (COT) of 13 patients were made to determine in which cases internal conduit repair was feasible, and under which conditions a patch enlargement of the COT was indicated. In the pulmonary stenosis (PS) group, the area of the narrowest cross-section of the COT was significantly smaller than that in the pulmonary hypertension (PH) group (p less than 0.025). In the PS group, the area was rarely sufficient to be shared by systemic and pulmonary circulation. Therefore, stenosis in the outflow tract to the pulmonary artery will occur if the intraventricular tunnel technique is applied, without patch enlargement of this portion, to patients with PS. On the contrary, the cross-sectional areas of the COT and pulmonary arteries were significantly larger in the PH group than in the PS group. Accordingly, the intracardiac conduit operation may be possible in such patients without a patch enlargement, even in young patients if other intracardiac conditions allow. Preoperative angiocardiographic evaluation of the COT is helpful in preoperatively selecting the proper operative procedure for this anomaly.

KEYWORDS: double-outlet right ventricle, angiocardiography, common outflow tract, intraventricular tunnel technique, patch enlargement

*PMID: 2718771 [PubMed - indexed for MEDLINE]

Angiocardiographic Quantitative Evaluation of Double-Outlet Right Ventricle : Special Reference to the Morphology of the Common Outflow Tract.

Sugato Nawa*, Makoto Yamada, Eiji Sugawara, Kohichi Kino, and Shigeru Teramoto
Second Department of Surgery, Okayama University Medical School, Okayama 700, Japan

Geometrical measurements of angiocardiograms of the common outflow tract (COT) of 13 patients were made to determine in which cases internal conduit repair was feasible, and under which conditions a patch enlargement of the COT was indicated. In the pulmonary stenosis (PS) group, the area of the narrowest cross-section of the COT was significantly smaller than that in the pulmonary hypertension (PH) group ($p < 0.025$). In the PS group, the area was rarely sufficient to be shared by systemic and pulmonary circulation. Therefore, stenosis in the outflow tract to the pulmonary artery will occur if the intraventricular tunnel technique is applied, without patch enlargement of this portion, to patients with PS. On the contrary, the cross-sectional areas of the COT and pulmonary arteries were significantly larger in the PH group than in the PS group. Accordingly, the intracardiac conduit operation may be possible in such patients without a patch enlargement, even in young patients if other intracardiac conditions allow. Preoperative angiocardiographic evaluation of the COT is helpful in preoperatively selecting the proper operative procedure for this anomaly.

Key words : double-outlet right ventricle, angiocardiography, common outflow tract, intraventricular tunnel technique, patch enlargement

Witham coined the phrase double-outlet right ventricle (DORV) in 1957 (1). Since then, much research has been done to define the anomaly as a distinct entity (2). Lev (3) and Kawashima (4) indicated that the various conotruncal malformations formed a continuous spectrum, rather than being distinct and separate entities. Therefore, preoperative evaluation of each case of DORV is necessary to select the best operative procedure. Many procedures have

been developed since the successful repair by Kirklin *et al.* (5). Intraventricular rerouting through a baffle is now the most common operative method, and results with this procedure are particularly satisfactory in patients with subaortic ventricular septal defect (VSD) (6). It has not been clearly demonstrated, however, under what anatomical conditions intraventricular tunnel repair is possible. We undertook this study to clarify what geometrical dimensions allowed the intraventricular rerouting technique. We also studied how to avoid postoperative

* To whom correspondence should be addressed.

stenosis in the pulmonary part of the right ventricular outflow tract.

Methods

The definition of DORV used in this study was that of Lev (3) and Pacifico *et al.*(7). The classification referring to pulmonary stenosis (PS) and/or pulmonary hypertension (PH) was based on the relationship of VSD to the great arteries.

Patients. During the past eleven years, we experienced a total of thirteen patients with DORV (Table 1). The mean age at the time of the angiocardigraphic study was four years and ten months, ranging from 0.1 to 21.0 years. Of the patients with PS, three had undergone one or two palliative operations. None of the patients with PH received pulmonary artery banding. Corrective surgery was performed for five of the patients with PS, and three of those with PH.

Surgical Methods. The basic surgical procedure

was the creation of an internal conduit (IC) from VSD to the aortic ostium (Table 1). PS was concomitantly relieved by infundibular cardiomyectomy in four cases and by pulmonary valvulotomy in three cases. Enlargement with an outflow patch was used in only one case (Case 6). The Damus method (9) was applied to one case (Case 12), and a modification of the Fontan operation (10) was applied to another case (Case 11).

Angiocardigraphic evaluation method. For the evaluation of the COT, anteroposterior and lateral biplane projections of biventriculograms were obtained preoperatively. The external diameter of the catheter used was measured at the diaphragmatic level to calculate the magnification rate. The diameter of the pulmonary arterial outflow tract (DPAOT), the diameter of the pulmonary annulus, and that of the aortic annulus (DAoA) were measured in accordance with the report by Blackstone *et al.*(11). The narrowest point of the main pulmonary artery was measured at the

Table 1 Characteristics of patients, operative procedures, and results

Cases ^a	Age (years)		Sex	Type ^b	VSD ^c	PAP ^d	Previous op.	Operative procedure	Operative results
	at angio.	at op.							
1	1.8	2.2	F	SDD	SA	PH	-	IC	Dead
2	0.1	1.8	M	SDD	SA	PS	-	IC, IM, PVT	Alive
3	10.4	-	M	SLL	NC	PS	BT, PVT	-	-
4	5.0	-	M	NDD	NC	PS	-	-	-
5	0.2	-	F	SDD	DC	PS	-	-	-
6	8.1	9.5	F	SDD	SA	PS	BT	IC, IM, OTP, PVT	Dead
7	0.6	-	M	ILD	NC	PH	-	-	-
8	21.0	21.3	F	ILL	SA	PS	-	IC, IM, PVT	Alive
9	0.3	1.0	M	SDD	DC	PH	-	IC	Dead
10	2.0	2.4	M	SDD	SA	PS	-	IC, IM	Alive
11	10.8	10.9	F	SDD	NC	PS	BT	Fontan's op. (10)	Dead
12	2.3	2.1	F	SDD	SP	PH	-	Damus's op. (9)	Dead
13	0.4	-	M	SDD	SA	PH	-	-	-

a: Cases 3,4,5,7, and 13 did not undergo corrective surgery.

b: Van Praagh's terminology (8).

c: Relationship of VSD to the great arteries.

d: Pulmonary arterial pressure (PAP) is expressed as PS or PH.

Abbreviations: angio, angiocardigraphy; op., operation; VSD, ventricular septal defect; F, female; SA, sub-aortic; PH, pulmonary hypertension; IC, internal conduit; M, male; PS, pulmonary stenosis; IM, infundibular myectomy; PVT, pulmonary valvulotomy; NC, non-committed; BT, Blalock-Taussig shunt; DC, doubly committed; OTP, outflow tract patch; SP, subpulmonary.

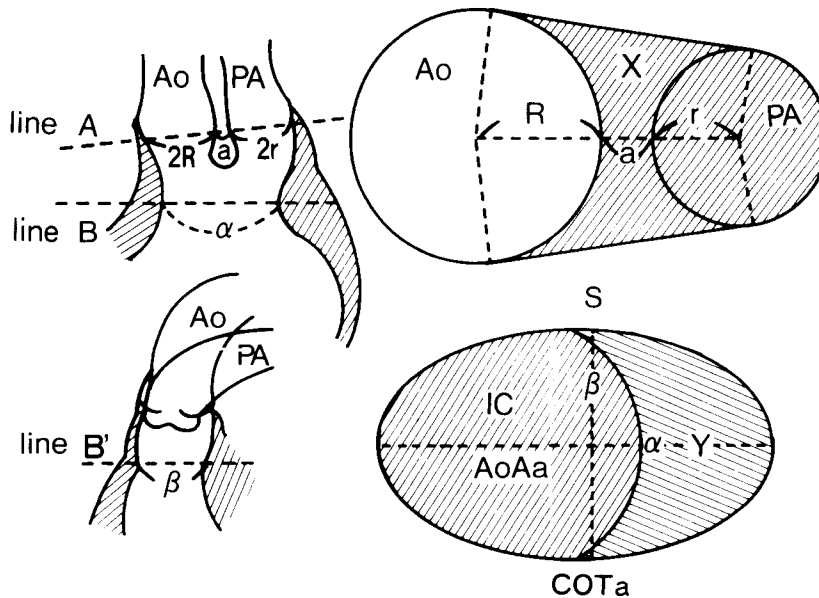


Fig. 1 Geometrical evaluation of angiocardigrams of the right ventricular outflow tract. Abbreviations : Ao, aorta ; PA, pulmonary artery ; 2R, aortic annular diameter ; 2r, pulmonary annular diameter ; a, distance between the two annuli ; α , the smallest diameter of the common outflow tract (COT) in the anteroposterior projection ; β , the smallest sagittal diameter of the COT at the same level as the line B ; S, the cross-sectional area of the COT at the level of the line A ; X, the residual area to the pulmonary artery obtained by S minus πR^2 ; COTa, the cross-sectional area of the COT at the level of the line B ; IC, internal conduit ; AoAa, aortic annular area given by πR^2 ; Y, residual area to the pulmonary artery at the level of the line B obtained by COTa minus πR^2 .

systolic phase, as was the DPAOT. These diameters were used to calculate the cross-sectional area of the pulmonary arterial outflow tract (PAOTa) and that of the aortic annulus (AoAa) under the assumption that the transsectional shape of these portions were truly circular. The anteroposterior projection was used whenever possible, but occasionally the lateral projection was also used if the details were clearly shown on it. From diameters obtained, the cross-sectional areas of the right pulmonary artery (RPAa), the left pulmonary artery, and the main pulmonary artery (PAa) were calculated. These values were compared with the respective areas of the normal heart obtained from equations below (12-14). The mean value (PAa) of the cross-sectional areas of the right and left pulmonary arteries was also calculated, and was compared with the RPAa of the normal heart.

The cross-sectional area of the right pulmonary artery of the normal heart (N-RPAa) was calculated by :

$$N-RPAa = -0.3546 + 2.7989 \cdot (BSA),$$

where BSA is the body surface area.

The cross-sectional area of the main pulmonary artery of the normal heart (N-PAa) was calculated by :

$$N-PAa = -0.536 + 4.035 \cdot (BSA).$$

The diameter of the pulmonary arterial outflow tract of the normal heart (N-DPAOT) was calculated by :

$$N-DPAOT = 15.29 + 11.42 \cdot \log_{10}(BSA).$$

The diameter of the aortic annulus of the normal heart (N-DAoA) was calculated by :

$$N-DAoA = 0.967 + 3.51 \cdot \log_{10}(BSA).$$

Fig. 1 shows the method of angiocardiographic evaluation of the COT. The line A is drawn from the right margin of the aortic annulus to the left margin of the pulmonary annulus. The aortic annular diameter (DAoA) is indicated as 2R, and the pulmonary annular diameter as 2r. The distance between the two annuli is shown as a; this does not represent the conal septal thickness. The cross-sectional area of the COT (S) at the

level of the line A was geometrically calculated. The area of the residual orifice to the pulmonary artery is indicated by X (S minus πR^2 , the area covered by oblique lines in the upper right figure) under the supposition that the internal baffle is placed so that the internal tunnel has the same cross-sectional area as the AoAa, that is πR^2 .

The line B indicates the narrowest part of the COT, where the smallest diameter (α) of the COT is found at the end-systole in the anteroposterior projections. The line B' in the lateral projection is at the same level as the line B, and is where the sagittal diameter of the COT at the end-systole (β) is found. The cross-sectional area of the COT at the level of the line B, indicated as COTa, was also calculated geometrically, under the assumption that the transsectional shape of this portion was elliptical with the longest diameter of α and the shortest one of β , as shown in the lower right figure. The cross-sectional area of the internal tunnel, which is created so as to have the same cross-sectional area as the AoAa (πR^2), is labeled IC and covered with oblique lines slanting down to the left. The residual area of the COTa (labeled Y and covered with oblique lines slanting down to the right) after tunnel formation is calculated by the COTa minus AoAa. S and COTa were standardized using the body surface area of each case, and were then expressed as SI and COTaI in cm^2/m^2 .

Variables were evaluated by dividing the subjects into two groups, the PS and PH groups. The data were comparatively analyzed with Student's unpaired *t* test, and a $p < 0.05$ was considered to be statistically significant. All data are presented as means \pm standard deviation (SD).

Results

Some values in Case 1 were not available because of poor angiocardiograms. The distal pulmonary arterial size was evaluated by the ratios $\overline{\text{RPAa}}$ to N-RPAa ($\overline{\text{RPAa}}/\text{N-RPAa}$), and $\overline{\text{PAa}}$ to the N-RPAa ($\overline{\text{PAa}}/\text{N-RPAa}$). $\overline{\text{RPAa}}/\text{N-RPAa}$ in the PH group was 1.87 ± 0.31 , which was significantly larger than 0.88 ± 0.50 of the PS group ($p < 0.01$). $\overline{\text{PAa}}/\text{N-RPAa}$ in the PH group was also statistically larger than that of the

PS group (1.71 ± 0.29 vs. 0.85 ± 0.38 , $p < 0.05$; Fig. 2). The size of the proximal part of the pulmonary artery was evaluated by the ratios $\overline{\text{PAa}}$ to N-PAa ($\overline{\text{PAa}}/\text{N-PAa}$), and $\overline{\text{DPAOT}}$ to N-DPAOT ($\overline{\text{DPAOT}}/\text{N-DPAOT}$) (Fig. 3). $\overline{\text{PAa}}/\text{N-PAa}$ was significantly smaller in the PS group than in the PH group (1.00 ± 0.62 vs. 3.14 ± 1.01 , $p < 0.01$), and $\overline{\text{DPAOT}}/\text{N-DPAOT}$ was markedly larger in the PH group. The aortic size was evaluated by the ratio $\overline{\text{DAoA}}$ to N-DAoA ($\overline{\text{DAoA}}/\text{N-DAoA}$), which was 1.20 ± 0.08 in the PH group and 1.44 ± 0.26 in the PS group, there being no sig-

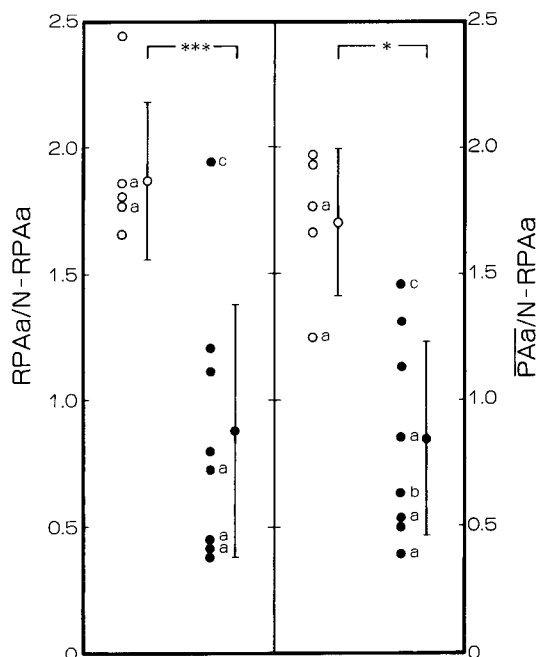


Fig. 2 Evaluation of the size of distal pulmonary arteries. Open circles indicate the values for the patients with pulmonary hypertension, and closed circles for those with pulmonary stenosis. a, Patients who did not undergo corrective surgery; b, Patient operated upon with the Fontan procedure (10); c, Patient who received a patch enlargement of the COT. Means given at right with bars to represent \pm SD. Abbreviations: $\overline{\text{RPAa}}$, cross-sectional area of the right main pulmonary artery; N-RPAa , the $\overline{\text{RPAa}}$ of the normal heart (12); $\overline{\text{PAa}}$, mean value of the cross-sectional areas of the right and left pulmonary arteries; COT, common outflow tract. ***, $p < 0.01$; *, $p < 0.05$.

nificant difference (Fig. 4). The ratio β to DAoA was calculated to be 1.45 ± 0.34 in the PH group and 0.80 ± 0.10 in the PS group; the difference was significant ($p < 0.005$).

The cross-sectional area of the COT at the level of the line A, *i. e.*, SI, was $9.42 \pm 0.29 \text{ cm}^2/\text{m}^2$ in the PH group and $7.04 \text{ cm}^2/\text{m}^2$ in the PS group; the difference was not significant. The cross-sectional area at the level of the line B, *i. e.*, COTaI, was $8.23 \pm 1.96 \text{ cm}^2/\text{m}^2$ in the PH group and $4.16 \pm 1.83 \text{ cm}^2/\text{m}^2$ in the PS group. This difference was statistically significant ($p < 0.025$) (Fig. 5).

The ratio X to N-PAOTa (X/N-PAOTa) was 3.37 ± 0.38 and 1.31 ± 0.47 in the PH and PS groups, respectively. This difference was significant ($p < 0.005$) (Fig. 6). However, the residual area at this level (line A) was sufficiently large in most

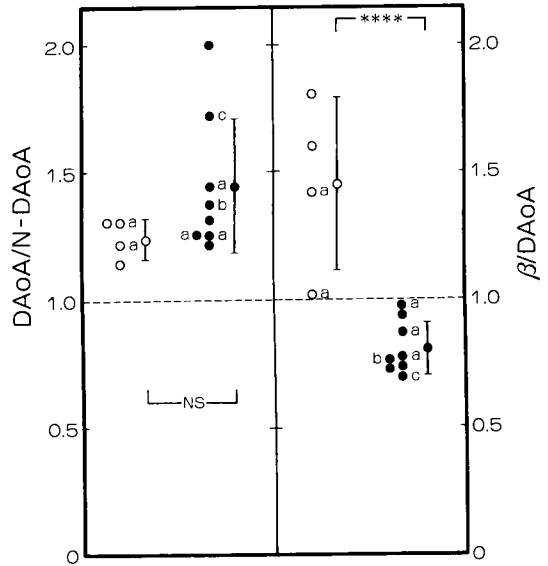


Fig. 4 The aortic annular diameter and comparison with the sagittal diameter of the common outflow tract (β). Symbols are the same as in Fig. 2. Abbreviations: DAoA, diameter of the aortic annulus; N-DAoA, DAoA of the normal heart (14); β , sagittal diameter of the common outflow tract (Fig. 1); NS, not significant. ****, $p < 0.005$.

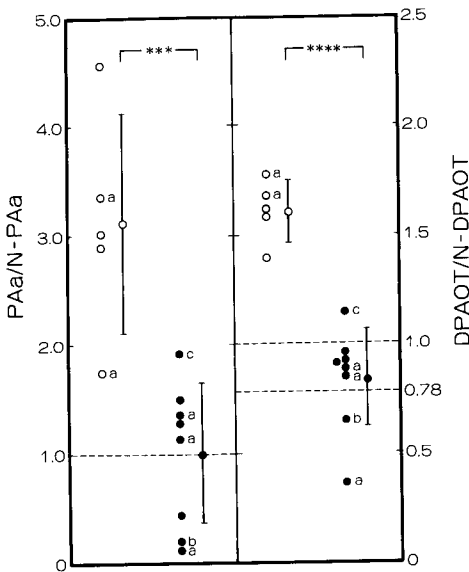


Fig. 3 Evaluation of the size of the proximal part of pulmonary arteries. Symbols are the same as in Fig. 2. Abbreviations: PAA, cross-sectional area of the main pulmonary artery; N-PAA, the PAA of the normal heart (13); DPAOT, diameter of the pulmonary arterial outflow tract; N-DPAOT, DPAOT of the normal heart (14). ***, $p < 0.01$; ****, $p < 0.005$.

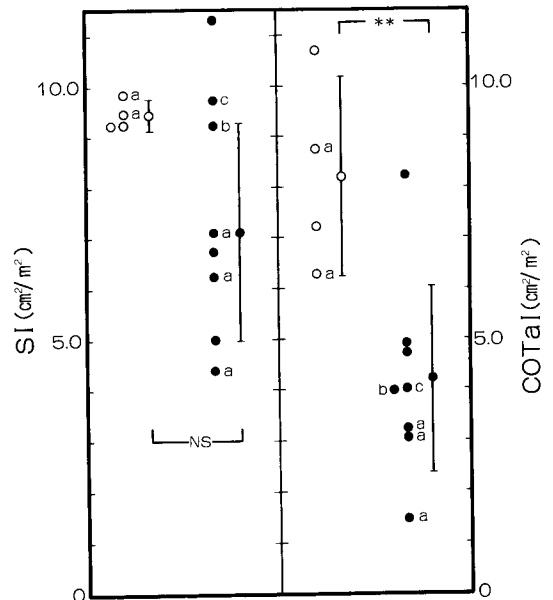


Fig. 5 Evaluation of the cross-sectional area of the right ventricular outflow tract. Symbols are the same as in Fig. 2. Abbreviations: SI, S standardized according to the body surface area (See Fig. 1); COTaI, standardized value of COTa (See Fig. 1); NS, not significant. **, $p < 0.025$.

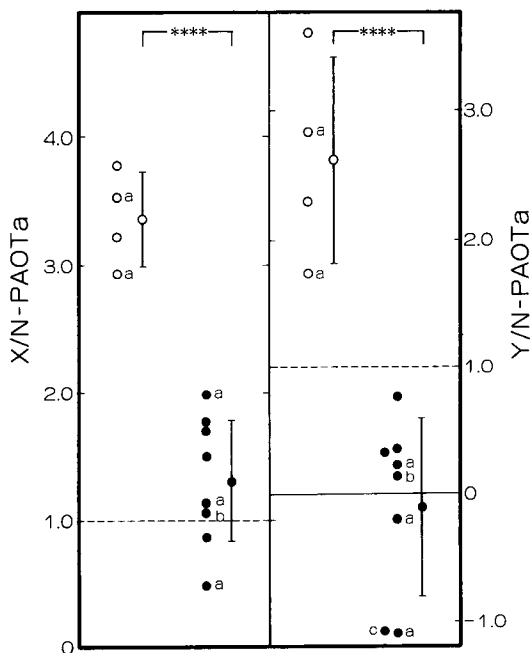


Fig. 6 Evaluation of residual cross-sectional area of the right ventricular outflow tract to the pulmonary circulation after the internal conduit operation. Symbols are the same as in Fig. 1. Abbreviations : N-PAOTa, trans-sectional area of the pulmonary arterial outflow tract of the normal heart (14) ; OTP, outflow tract patch. ****, $p < 0.005$.

cases of the PS group not to cause an outflow tract stenosis to the pulmonary artery, since $X/N\text{-PAOTa}$ was larger than 1.0. On the contrary, $Y/N\text{-PAOTa}$ in the PH group (2.62 ± 0.80) was significantly different from that in the PS group (-0.10 ± 0.70) ($p < 0.005$). It was revealed that the residual area to the pulmonary circulation at this level (line B) was very restricted in the PS group, since $Y/N\text{-PAOTa}$ was much smaller than 1.0 (Fig. 6).

Discussion

This study was undertaken to clarify the preoperative criteria for deciding whether a complete or palliative operation should be selected, and to determine under what geometrical circumstances a patch enlargement

of the COT, pulmonary annulus, or both were indicated. The ultimate purpose of this study was to clarify what intracardiac, geometrical dimensions allowed or prohibited intraventricular tunnel repair.

It is generally considered that the fundamental policy for surgical managements of PS associated with various cardiac anomalies is based on that for PS in the tetralogy of Fallot. From our experience with the tetralogy of Fallot, we have considered that a palliative operation is indicated when $RPAa/N\text{-}RPAa$ is less than 0.36, or when $PAa/N\text{-}RPAa$ is less than 0.32 (15,16). Accordingly, with only the size of distal pulmonary arteries as a criterion, complete repair of the DORV was contraindicated in few cases of this series. The size of the main pulmonary artery and its orifice were sufficient in most of the cases. However, $PAa/N\text{-}PAa$ was 0.12 and 0.19 in Cases 4 and 11, and $DPAOT/N\text{-}DPAOT$ was 0.36 and 0.64 in Cases 3 and 11, respectively. In Cases 3 and 4, no surgery was done, and in Case 11 a modification of the Fontan operation was applied. As in this way, when the case does not meet with the criteria indicating either corrective surgery on the tetralogy of Fallot or the Fontan procedure (17), a palliative operation should be preferred to a corrective one. In the PH group, on the contrary, pulmonary annulus and the distal and main pulmonary arteries were dilated, and there was no problem concerning the size of pulmonary arteries.

It is necessary to determine where a stenosis in the outflow tract to the pulmonary artery could develop in cases where tunnel repair is applied. The sagittal diameter of the COT (β) was measured and compared with the DAoA to give the ratio $\beta/DAoA$. The result of the analysis with this ratio indicates that the cross-sectional shape of the tunnel has to be elliptic in order to give an internal tunnel the same cross-sectional

area as AoAa. That is, the tunnel will laterally expand and will be anteroposteriorly compressed as in Fig. 1, even if the patch roof of the tunnel fully expands anteriorly to the inner surface of the free wall of the outflow tract, since β is always smaller than the aortic annular diameter, *i. e.*, $\beta/DAoA < 1.0$. Accordingly, the conduit wall must protrude into the pulmonary part of the COT. In the present series, the COTa was statistically smaller in the PS group than in the PH group, so that Y was significantly smaller than the N-PAOTa in the PS group.

Although X/N-PAOTa was statistically smaller in the PS group than in the PH group, all patients in the former group were observed to have sufficient cross-sectional area of the remaining outflow tract to the pulmonary circulation after the internal tunnel operation, except Case 3 in which no operation has been performed. This observation indicates that the pulmonary outflow tract stenosis would not develop at the level of the line A after tunnel repair. However, the residual cross-sectional area at the level of the line B in the COT, represented by Y/N-PAOTa, was found to be significantly smaller in the PS group, and consequently postoperative stenosis in the pulmonary outflow tract could develop here unless this portion were enlarged using a patch or some other procedure. Among the patients with PS upon whom we operated, Y/N-PAOTa was the lowest in Case 6, at -1.14 , and the highest in Case 2, at 0.78 . By our own criteria for the tetralogy of Fallot (15, 16), all the patients in the PS group should have received a patch enlargement of the outflow tract, although the procedure was used only in Case 6. However, in spite of the patch enlargement, the patient died from low cardiac output. It was thought that the low cardiac output was caused by the residual stenosis of newly created outflow tract to the pulmonary artery (Y/N-PAOTa of -1.14

in this case) being inadequately narrow even after the patch enlargement. Other operative procedures such as extracardiac conduit operation or a modification of the Fontan operation should have been performed in this case. Stewart *et al.* (2, 19) also recommended a patch enlargement or an external conduit operation even when PS was absent because simple infundibular dissection and pulmonary valvulotomy could not prevent postoperative stenosis of the pulmonary outflow tract after tunnel repair. Angiographic evaluation of the outflow tract as described in the present study should help surgeons to decide preoperatively whether to patch or not to patch, and whether the patch enlargement technique is feasible or not.

In our cases of PH, the SI, COTaI, X/N-PAOTa, and Y/N-PAOTa were all large, and none of the unfavorable geometries was present, indicating that there was no risk of postoperative stenosis in the pulmonary outflow tract developing after the intraventricular tunnel operation, although there remained a problem concerning the location of VSD (6). Nevertheless, the operative results in the PH group of our series were poor, with high pulmonary arterial pressure early after corrective surgery. Pulmonary artery banding to prevent the development of pulmonary vascular obstructive disease was not performed in these cases, and that might account for the unsatisfactory results in the PH group. There also may be some question as to whether intraventricular tunnel repair is feasible in very young patients. However, our observation was that the COT in the PH group had sufficient area to be shared by both the systemic and pulmonary circulation even during the early time of life, so that an intracardiac tunnel operation should be possible.

It was concluded that preoperative evalu-

ation of the morphology of the COT as described herein might help physicians to select the proper operative procedure for DORV. It was recommended that the COT should be enlarged using a patch in most cases of PS when intraventricular tunnel repair is to be applied.

References

1. Witham AC: Double-outlet right ventricle. A partial transposition complex. *Am Heart J* (1957) **53**, 928-933.
2. Stewart S: Double-outlet right ventricle. A collective review with a surgical view point. *J Thorac Cardiovasc Surg* (1976) **71**, 355-365.
3. Lev M: A concept of double-outlet right ventricle. *J Thorac Cardiovasc Surg* (1972) **64**, 271-281.
4. Kawashima Y: Definition and classification of the double-outlet of right ventricle. *J Jpn Assoc Thorac Surg* (1981) **29**, 962-971.
5. Kirklin JW, Harp RA, and McGoon DC: Surgical treatment of origin of both vessels from right ventricle, including pulmonary stenosis. *J Thorac Cardiovasc Surg* (1964) **48**, 1026-1036.
6. Kirklin JW, Pacifico AD, Blackstone EH, Kirklin JK, and Bargerion LM Jr: Current risks and protocol for operation for double-outlet of right ventricle. Derivation from 18 years experience. *J Thorac Cardiovasc Surg* (1986) **92**, 913-930.
7. Pacifico AD, Kirklin JW, and Bargerion LM Jr: Complex congenital malformations. Surgical treatment of double-outlet right ventricle; in *Advances in Cardiovascular Surgery*, Kirklin ed, Grune and Stratton, New York (1973) pp 57-76.
8. Van Praagh R, Perez-Trevino C, Reynolds JL, Moes CAF, Keith JD, Roy DL, Belcourt C, Weinberg PM, and Parisi LF: Double-outlet right ventricle (SDL) with subaortic ventricular septal defect and pulmonary stenosis. *Am J Cardiol* (1975) **35**, 42-53.
9. Damus PS, Thomson NB Jr, and McLoughlin TG: Arterial repair without coronary relocation for complete transposition of the great vessels with ventricular septal defect. *J Thorac Cardiovasc Surg* (1982) **83**, 316-318.
10. Fontan F and Baudet E: Surgical repair of tricuspid atresia. *Thorax* (1971) **26**, 240-248.
11. Blackstone EH, Kirklin JW, Bertranou EG, Labrosse CJ, Soto B, and Bargerion LM Jr: Preoperative prediction from cineangiograms of postrepair right ventricular pressure in tetralogy of Fallot. *J Thorac Cardiovasc Surg* (1979) **78**, 542-552.
12. Castellanos A, Hernandez FA, and Mercado H: Angiocardiographic measurement of the right main pulmonary artery in congenital heart disease. *Angiology* (1966) **17**, 743-755.
13. Hernandez FA and Castellanos A: The size of the main pulmonary artery in congenital heart disease. *Angiographic measurement. Acta Cardiol (Brux)* (1966) **21**, 1-19.
14. Rowlatt UF, Rimoldi HJA, and Lev M: The quantitative anatomy of the normal heart. *Pediatr Clin North Am* (1963) **10**, 499-588.
15. Nawa S, Kino K, Yoshida H, Sano S, Yamamoto M, Ohmori Y, Nohso M, Beika M, Senoo Y, and Teramoto S: Evaluation of operative procedure and predictive factors for perioperative postrepair right ventricular pressure in tetralogy of Fallot. *J Jpn Assoc Thorac Surg* (1981) **29** (Suppl) 201.
16. Nawa S, Yoshida H, Kino K, Sano S, Beika M, Ozaki K, Nagase H, Nakayama Y, Mondori E, Murakami T, Senoo Y, and Teramoto S: Complete repair of TOF by jumping graft from the right ventricle to the pulmonary artery. An evaluation of late postoperative hemodynamics and cardioangiographic findings. *J Jpn Assoc Thorac Surg* (1982) **30** (Suppl) 252.
17. Nawa S, Matsuki T, Shimizu A, Kurita A, Tago M, Murakami T, Senoo Y, and Teramoto S: Pulmonary artery connection in the Fontan procedure. Flexible polytetrafluoroethylene conduit for expansion. *Chest* (1987) **91**, 552-557.
18. Choussat A, Fontan F, Besse P, Vallot F, Chauve A, and Bricaud H: Selection criteria for Fontan's procedure; in *Pediatric Cardiology*, Anderson and Shinebourne eds, Livingstone, London (1979) pp 559-566.
19. Stewart RW, Kirklin JW, Pacifico AD, Blackstone EH, and Bargerion LM Jr: Repair of double-outlet right ventricle. An analysis of 62 cases. *J Thorac Cardiovasc Surg* (1979) **78**, 502-514.

Received October 18, 1988 ; accepted December 27, 1988