

Acta Medica Okayama

Volume 62, Issue 1

2008

Article 7

FEBRUARY 2008

Clinical Features, ARIX and PHOX2B Nucleotide Changes in Three Families with Congenital Superior Oblique Muscle Palsy

Sayuri Imai*

Toshihiko Matsuo†

Emi Itoshima‡

Hiroshi Ohtsuki**

*Okayama University,

†Okayama University,

‡Okayama University,

**Okayama University,

Clinical Features, ARIX and PHOX2B Nucleotide Changes in Three Families with Congenital Superior Oblique Muscle Palsy

Sayuri Imai, Toshihiko Matsuo, Emi Itoshima, and Hiroshi Ohtsuki

Abstract

We analyzed nucleotide changes in 3 genes, ARIX, PHOX2B, and KIF21A, in 6 patients of 3 families with congenital superior oblique muscle palsy. Three exons of ARIX, 3 exons of PHOX2B, and exons 8, 20, and 21 of KIF21A were amplified by polymerase chain reaction from genomic DNA isolated from the peripheral blood. The DNA fragments were directly sequenced in both directions. In 2 different families, a heterozygous nucleotide change, ARIX 153G>A, in the 5'-untranslated region was found in common between a father and daughter with muscle palsy and between a mother and daughter with muscle palsy (Family No. 1 and No. 3). In the other family (Family No. 2), a heterozygous 15-nucleotide deletion, PHOX2B 1124del15, resulting in loss of 5 alanine residues in the alanine repeat of the protein, was found in the daughter with muscle palsy and her father with normal traits, but was not found in the mother with muscle palsy. No KIF21A nucleotide change was found in any patients. The ARIX 153G>A polymorphism might be a genetic risk factor for the development of congenital superior oblique muscle palsy.

KEYWORDS: ARIX, PHOX2B, KIF21A, congenital superior oblique muscle palsy, familial (hereditary) disease

Original Article

Clinical Features, *ARIX* and *PHOX2B* Nucleotide Changes in Three Families with Congenital Superior Oblique Muscle Palsy

Sayuri Imai, Toshihiko Matsuo*, Emi Itoshima, and Hiroshi Ohtsuki

*Department of Ophthalmology, Okayama University Graduate School of Medicine,
Dentistry and Pharmaceutical Sciences, Okayama 700–8558, Japan*

We analyzed nucleotide changes in 3 genes, *ARIX*, *PHOX2B*, and *KIF21A*, in 6 patients of 3 families with congenital superior oblique muscle palsy. Three exons of *ARIX*, 3 exons of *PHOX2B*, and exons 8, 20, and 21 of *KIF21A* were amplified by polymerase chain reaction from genomic DNA isolated from the peripheral blood. The DNA fragments were directly sequenced in both directions. In 2 different families, a heterozygous nucleotide change, *ARIX* 153G > A, in the 5'-untranslated region was found in common between a father and daughter with muscle palsy and between a mother and daughter with muscle palsy (Family No. 1 and No. 3). In the other family (Family No. 2), a heterozygous 15-nucleotide deletion, *PHOX2B* 1124del15, resulting in loss of 5 alanine residues in the alanine repeat of the protein, was found in the daughter with muscle palsy and her father with normal traits, but was not found in the mother with muscle palsy. No *KIF21A* nucleotide change was found in any patients. The *ARIX* 153G > A polymorphism might be a genetic risk factor for the development of congenital superior oblique muscle palsy.

Key words: *ARIX*, *PHOX2B*, *KIF21A*, congenital superior oblique muscle palsy, familial (hereditary) disease

Strabismic syndromes, characterized by congenital limitation of eye movements from abnormal innervation of the extraocular muscles, have recently been grouped as congenital cranial dysinnervation disorders [1, 2]. These conditions include Duane retraction syndrome, congenital fibrosis of the extraocular muscles (CFEOM), congenital oculomotor nerve palsy, Mobius syndrome, double elevator palsy, and congenital horizontal gaze palsy.

Congenital superior oblique muscle palsy is the most common isolated cranial nerve palsy and has been considered a neurogenic palsy among the congenital

cranial dysinnervation disorders [2]. The clinical features of congenital superior oblique muscle palsy are hypertropia (upward deviation of the eye), ocular motility disorders such as underaction of the superior oblique muscle and overaction of the unopposed antagonist inferior oblique muscle, abnormal head posture such as head tilt toward the non-paralyzed side, the presence of large vertical fusional amplitudes, and sometimes amblyopia in the non-dominant eye. The etiology of congenital superior oblique muscle palsy remains basically unknown. Anatomical abnormalities, recorded to date in patients with congenital superior oblique muscle palsy, include aplasia of the trochlear nucleus, the absence or hypoplasia of the tendon and/or muscles [3–8], and orbital pulley structure anomalies [9]. On rare occasions, congenital superior

Received October 31, 2007; accepted December 14, 2007.

*Corresponding author. Phone: +81-86-235-7297; Fax: +81-86-222-5059
E-mail: matsuo@cc.okayama-u.ac.jp (T. Matsuo)

oblique muscle palsy shows familial occurrence and follows an autosomal dominant mode of inheritance [10–14].

Understanding of the genetics of congenital cranial dysinnervation disorders has advanced in recent years. *KIF21A* gene mutations have been identified in patients with CFEOM type 1 [15–18], which shows an autosomal dominant trait and is associated with the absence of the superior branch of the oculomotor nerve. *ARIX* gene mutations have been found in patients with CFEOM type 2 [19, 20], which shows an autosomal recessive trait and is proposed to result from aberrant development of the oculomotor and trochlear nerve and nuclei in the brainstem [21].

Based on the working hypothesis that congenital superior oblique muscle palsy might be a clinically milder variant of CFEOM type 2, we previously analyzed *ARIX* and *PHOX2B* gene polymorphisms in patients with congenital superior oblique muscle palsy [22, 23]. The *PHOX2B* gene is a homologue of the *ARIX* gene, 100% identical to *ARIX* in the homeodomain region and 75% identical in the brachyury-like domain [19]. In this study, we described clinical features in 3 small families with congenital superior oblique muscle palsy, and examined polymorphisms of the *ARIX*, *PHOX2B* and *KIF21A* genes in patients of the families.

Materials and Methods

Genomic DNA from members of three families with congenital superior oblique muscle palsy (Fig. 1) was used for the study. The diagnosis of superior oblique muscle palsy was based on the presence of hypertropia (upward deviation of the eye) on the affected paralyzed side, which became greatest in the gaze toward the nasal field of the involved eye. The additional diagnostic feature was a positive Bielschowsky head tilt test, showing an upward deviation of the involved eye when the head is tilted toward the affected paralyzed side (Fig. 2). In the congenital cases, these features were present from birth and other causative factors such as trauma were absent. The study was approved by the Institutional Review Board at Okayama University Medical School, and written consent was obtained from each patient or a parent when the patient was below age 15. All of the procedures conformed to the Declaration of Helsinki.

Briefly, peripheral leukocytes were isolated from 10 ml blood by gradient centrifugation, and the genomic DNA was purified by phenol/chloroform extraction and ethanol precipitation. Polymerase chain reaction (PCR) amplification for the *ARIX* and *PHOX2B* genes was performed as described previously [22, 23]. For the *KIF21A* gene, 6 sets of primers were used to amplify exons 8, 20, and 21 from 100 ng of genomic DNA. PCR was carried out with AmpliTaq Gold DNA polymerase (Roche,

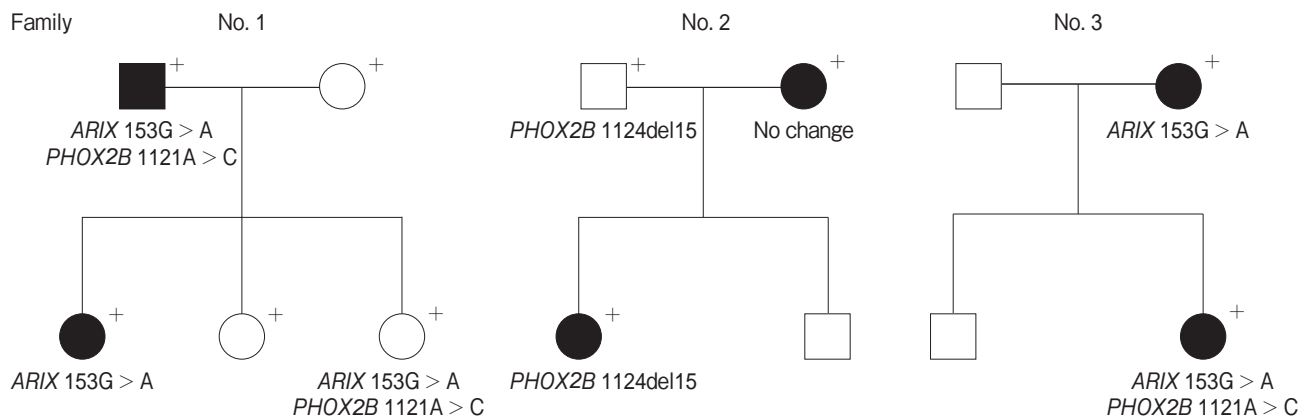


Fig. 1 Pedigrees of 3 families with congenital superior oblique muscle palsy and genomic DNA nucleotide changes in *ARIX* and *PHOX2B*. Members who underwent the genomic DNA analysis are indicated by a symbol "+". Females are denoted by circles, males by boxes, unaffected females and males by open circles and boxes, affected females and males by closed circles and boxes.

Branchburg, NJ, USA): initial denaturation at 95 °C for 15 min, followed by 35 cycles at 94 °C for 40 sec, 52 °C for 1 min, and 72 °C for 1 min, and a final extension at 72 °C for 10 min. The sequences of the primers for *ARIX*, *PHOX2B*, and *KIF21A* are shown in Table 1.

The PCR products were purified with ExoSAP-IT (USB, Cleveland, OH, USA) and used as a template

for direct sequencing with the ABI 310 Genetic Analyzer (Perkin-Elmer, Foster, CA, USA) using the BigDye Terminator Cycle Sequencing Kit (Perkin-Elmer). Both strands were sequenced for each DNA fragment. The DNA sequences were aligned with the published human *ARIX* sequences (GenBank Accession Numbers: AF022722, AF022723, and AF022724), *PHOX2B* sequence (GenBank Accession

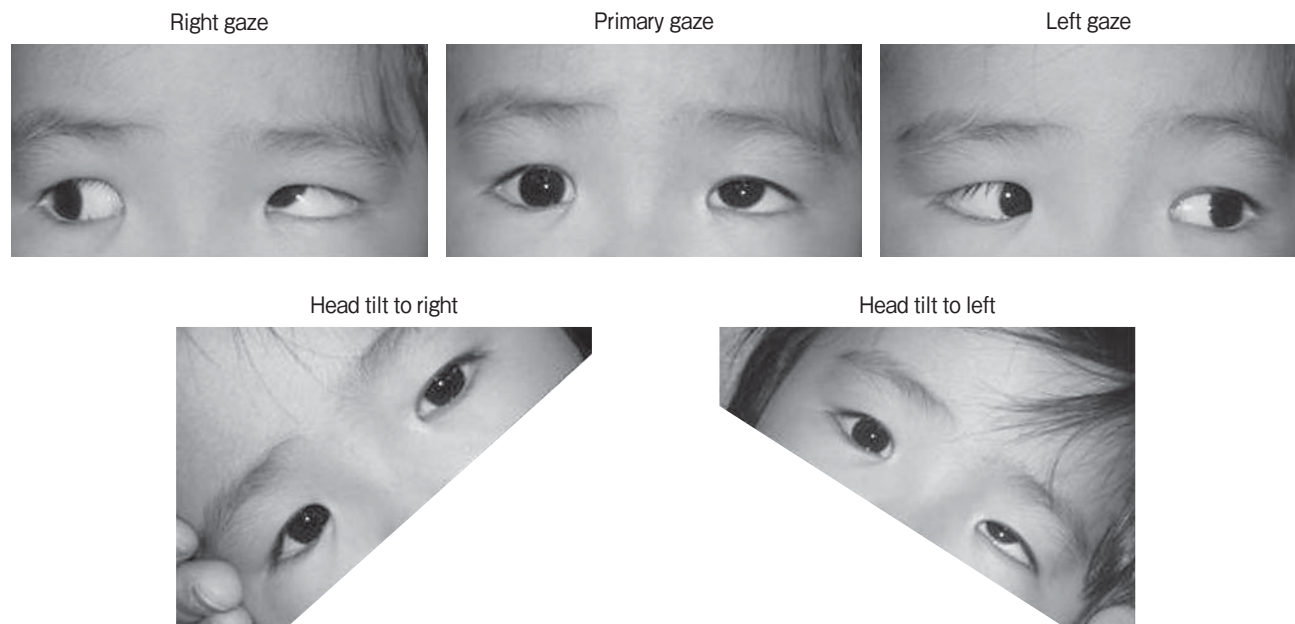


Fig. 2 Eye deviations in the daughter of Family No. 2. Upward deviation of the left eye at the primary gaze position becomes greatest at the gaze toward the right, namely, at the nasal field of the affected left eye. Upward deviation of the left eye also becomes apparent when the head is tilted to the left side.

Table 1 Sequences of primers used in polymerase chain reaction for *ARIX*, *PHOX2B*, and *KIF21A* gene amplification

	Forward 5'-3'	Reverse 5'-3'
<i>ARIX</i> exon 1a	TCCACACCTCTGAGCCCTAAGACGG	GCCGCAGGGGGCTGTATTGGAAGC
<i>ARIX</i> exon 1b	CCCCGGGCCGATGGACTACT	AGCGGGCCCAGGGATTTC
<i>ARIX</i> exon 2	CCCCGGAGCTGGACACAAC	GCTCCCACACCTCCTTCCA
<i>ARIX</i> exon 3a	GATCTCACTCGAGCCTTGC	CTGCACGTGGACTCCTTGA
<i>ARIX</i> exon 3b	CGGGCCAAGTTCGCAACAGGAG	GGAGTTTCTGGGGCAGGCTCGGA
<i>PHOX2B</i> exon 1	GCGTTGAGCTGTGCACATCTC	GCTTCCTATATACGGGCGG
<i>PHOX2B</i> exon 2	GAGTCCTCACATTCTAGCTCC	CACTCGAGGCTCCAGGACTTCG
<i>PHOX2B</i> exon 3a	GGCCACCCTAACCGGTGC	CTGCTGCGCCGCCCTTG
<i>PHOX2B</i> exon 3b	CCAGCTGCGGGGCGAATG	CTGGCTCGCCCGCTGTC
<i>KIF21A</i> exon 8	TTTTAGCATTTTAGGTGCTTTT	AAAGTGCCAGCCTTAGATGT
<i>KIF21A</i> exon 20	AAATGGCTCATTATTTGGCA	CAGGGAACAAAATTGGAAGA
<i>KIF21A</i> exon 21	GGGGTTTGATGGTACTGTAT	CTTCATGTA AAAACTGAAAGTGCT

Number: AF117979), and *KIF21A* sequence (GenBank Accession Number: NT029419).

Results

Clinical features of the 3 families with congenital superior oblique muscle palsy are summarized in Table 2. The father and daughter in Family No. 1 shared congenital superior oblique muscle palsy while the mothers and daughters shared the palsy in Families No. 2 and No. 3. The laterality of the superior oblique muscle involved in the palsy was the right side for both patients in Family No.1 and the left side for both in Family No. 2; by contrast, the laterality of the palsy differed between mother and daughter in Family No. 3 (Fig. 1). The degrees of vertical deviation were comparable between the afflicted members of each family. Some members showed binocular fusion on the Bagolini striated glasses test and hence had measurable stereopsis at near vision while the others

showed suppression or diplopia.

The atrophy of the superior oblique muscle was defined as less than 50% of the cross-sectional area of the muscle on the paralyzed side compared with the non-paralyzed side by magnetic resonance imaging [6]. The father in Family No. 1 and the mother in family No. 2 showed muscle atrophy while the daughter in Family No. 2 appeared to completely lack the superior oblique muscle. In contrast, the other patients had no atrophy (Fig. 3). The mother of Family No. 3 did not undergo magnetic resonance imaging.

Gene polymorphisms detected in this study are summarized in Fig. 1. *ARIX* gene heterozygous polymorphism in the 5'-untranslated region, 153G > A (Fig. 4), was found in common in the father and daughter of Family No. 1 and also in the mother and daughter of Family No. 3. In contrast, the afflicted members of Family No. 2 did not have this polymorphism. The heterozygous amino acid-preserving polymorphism of exon 3 of the *PHOX2B* gene (Fig. 4),

Table 2 Clinical characteristics of patients with congenital superior oblique muscle palsy in 3 families

Family No.	Member	Age at first visit (years)	Laterality of SO palsy	Dominant eye	Abnormal head posture	Deviation at 5 m (prism diopter)	Bagolini striated glasses test		TNO Test (second of arc)	Surgical procedure	SO atrophy by MRI
							at 5 m	at 0.3 m			
1	Father	54	Right	Right	Head tilt to Left	RHT30	Fusion	Diplopia	Absent	LIR recession 4 mm	Yes
	Daughter	24	Right	Right	Head tilt to Left	RHT25	Fusion	Fusion	60	RIO recession	No
2	Mother	33	Light	Right	Head tilt to Right	LHT20	Left eye	Left eye	Absent	No surgery	Yes
	Daughter	2	Light	Right	Head tilt to Right	LHT25	suppression *unknown	suppression *unknown	Absent	LIO recession	Yes (SO Absence) Not done
3	Mother	48	Right	Light	Head tilt to Left	RHT14	Right eye	Fusion	60	RIO recession	No
	Daughter	14	Light	Right	Head Tilt to Right	LHT12	Right eye	Fusion	240	No surgery	No

ET, esotropia; LHT, left hypertropia; LIO, left inferior oblique muscle; LIR, left inferior rectus muscle; MRI, magnetic resonance imaging; RHT, right hypertropia; RIO, right inferior oblique muscle; SO, superior oblique muscle; X, exophoria; XT, exotropia. *unknown due to the young age of subject.

1121A > C, was detected only in the father of family No. 1 and the daughter of Family No. 3. The daughter with congenital superior oblique muscle palsy in Family No. 2 had a heterozygous 15-base pair deletion encompassing 1,124 to 1,138 of the *PHOX2B* gene, resulting in loss of 5 alanine residues in the alanine repeat (Fig. 5). This *PHOX2B* 15-base pair deletion derived from the apparently normal father, but not from the mother with congenital superior oblique muscle palsy. The *KIF21A* gene polymorphisms, namely those in exons 8, 20 and 21, were absent in all patients.

Discussion

The goal of this study was to search for the role of candidate genes in the development of congenital superior oblique muscle palsy in patients of 3 families. Family No. 1 has been included in genetic analysis in our previous reports [22, 23]. In this study, we ana-

lyzed 2 additional families with congenital superior oblique muscle palsy. We selected 3 genes, *ARIX*, *PHOX2B*, and *KIF21A*, as candidate genes since *KIF21A* and *ARIX* were identified as causative genes for CFEOM type 1 [15, 16] and type 2 [19, 20], respectively. Furthermore, *PHOX2B* is a closely related counterpart of *ARIX*. Both *ARIX* and *PHOX2B* are homeodomain proteins and expressed in the developmental process of the trochlear nuclei in the brainstem [24, 25]. *KIF21A* encodes a kinesin motor involved in anterograde axonal transport [15, 16]. We also suppose that congenital superior oblique muscle palsy might be a milder clinical variant of CFEOM.

We described in this study clinical features of 3 families with congenital superior oblique muscle palsy (Fig. 2 and Table 2). The present study is the first to describe a series of families with congenital superior oblique muscle palsy in the Japanese population. The laterality of the muscle palsy was the same in the 2

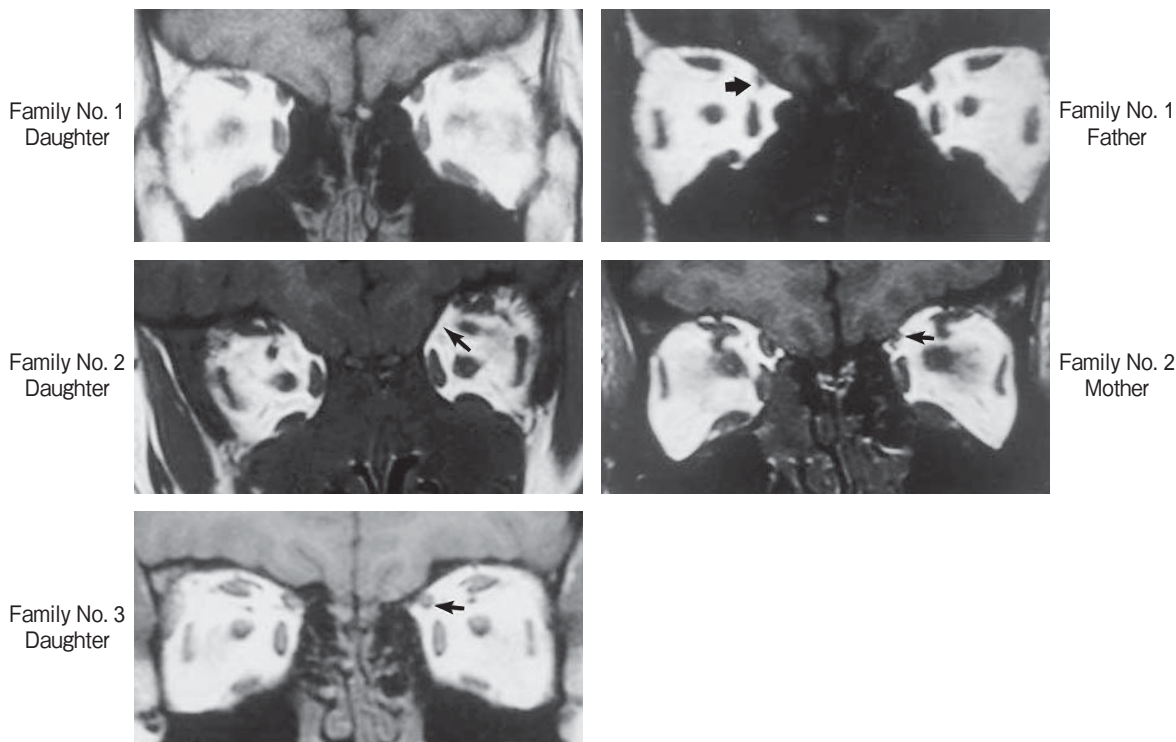


Fig. 3 Magnetic resonance imaging in three families with congenital superior oblique muscle palsy. Arrows in the father of Family No. 1 and the mother of Family No. 2 show more than 50% atrophy of the muscle cross section compared with the opposite side. The daughter in Family No. 2 appears to lack the muscle entirely (arrow). The daughter in Family No. 3 has no atrophy (arrow) and the mother in Family No. 3 did not undergo magnetic resonance imaging.

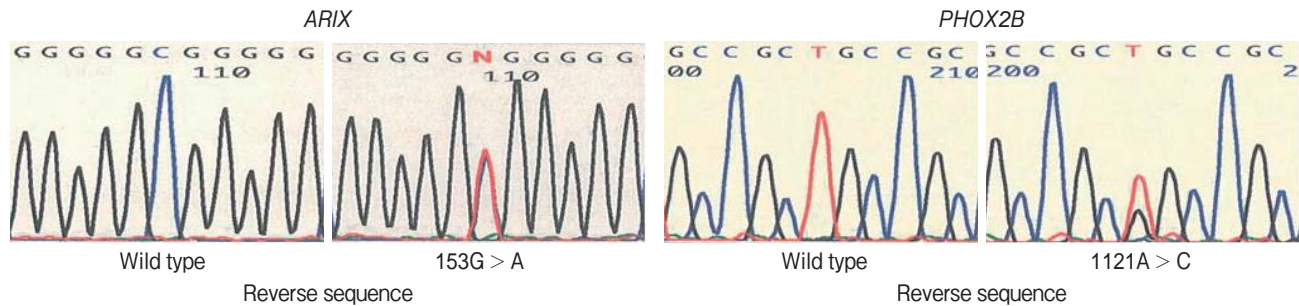


Fig. 4 Electropherograms of the reverse sequences, showing the heterozygous *ARIX* polymorphism, 153G > A, and the heterozygous *PHOX2B* polymorphism, 1121A > C. *ARIX* wild type, mother of Family No. 2; *ARIX* 153G > A, mother of Family No. 3; *PHOX2B* wild type, eldest daughter of Family No. 1; *PHOX2B* 1121A > C, father of Family No. 1.

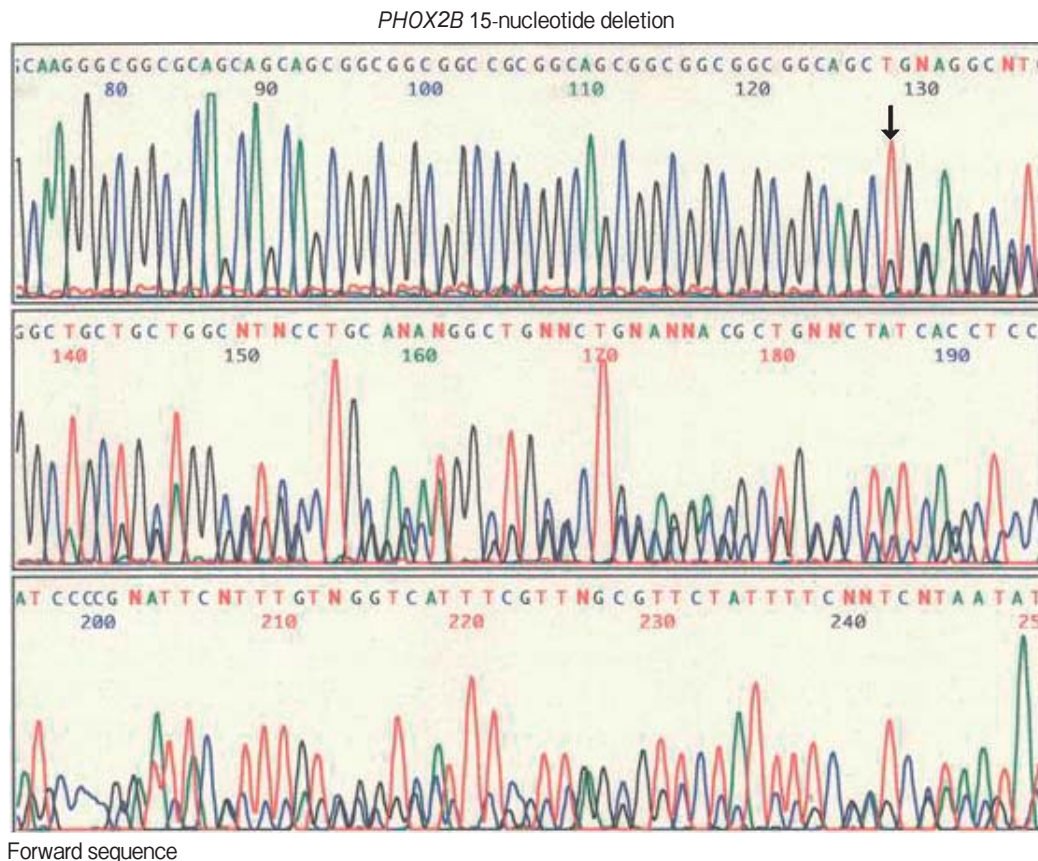


Fig. 5 Electropherogram of the forward sequence, showing a heterozygous *PHOX2B* 15-base pair deletion encompassing 1,124 to 1,138, resulting in loss of 5 alanine residues in the alanine repeat, in the daughter of Family No. 2. The starting point of the deletion is noted by an arrow.

afflicted members of 2 families (Families No. 1 and No. 2), but on opposite sides in the 2 afflicted members of the other family (Family No. 3). All 6 patients showed head tilt to the opposite side of the palsy muscle. The degrees of vertical deviation were comparable between patients in the same family. However, the levels of binocular vision such as fusion and stereopsis were variable. Atrophy of the superior oblique muscle, revealed by magnetic resonance imaging, was not necessarily consistent between the patients within families. Previous reports from other countries have described the same or inconsistent laterality of the superior oblique muscle palsy within families [10–14].

A heterozygous nucleotide change in *ARIX*, 153G > A, was found in common in the patients of 2 families (Family No. 1 and No. 3) while this nucleotide change was not found in the patients of the third family (Family No. 2). In our previous studies [22, 23], the *ARIX* 153G > A polymorphism has been found in normal Japanese individuals and also in patients with congenital superior oblique muscle palsy, though the rate of the *ARIX* 153G > A polymorphism was significantly higher in patients with congenital superior oblique muscle palsy than in normal individuals. The *ARIX* 153G > A polymorphism might have been a genetic risk factor in the development of congenital superior oblique muscle palsy in the 2 families of this study. A major drawback for this reasoning is the fact that the *ARIX* gene changes were not examined in all normal members in the families. Furthermore, Family No. 2, which lacked the *ARIX* 153G > A polymorphism, might harbor other polymorphisms in the introns or upstream regions of the gene that were not sequenced in this study.

Congenital superior oblique muscle palsy sometimes occurs on both sides and shows smaller vertical deviations at the primary gaze position. Even in bilateral involvement, clinical clues such as the presence of large torsional deviations will help establish the diagnosis. In Family No. 1, the youngest daughter with normal traits harbored the *ARIX* 153G > A polymorphism (Fig. 1), but bilateral superior oblique muscle palsy was ruled out by clinical examinations [22, 23]. In general, it is considered more plausible to have bilateral involvement of superior oblique muscle palsy in the presence of the *ARIX* gene polymorphism. The explanation for the frequent unilateral

involvement would be that gene dosage or expression might differ between the right side and the left side.

A heterozygous 15-nucleotide deletion in the *PHOX2B* gene, 1124del15, was found in the daughter with congenital superior oblique muscle palsy in Family No. 2. This deletion was not found in the mother with the muscle palsy but was found in the father without the muscle palsy. The inconsistent segregation of the *PHOX2B* deletion with the muscle palsy indicates that the 15-nucleotide deletion is not responsible for the development of the congenital superior oblique muscle palsy in this family. The same 15-nucleotide deletion in the *PHOX2B* gene was discovered in normal Japanese individuals and also in patients with schizophrenia and exotropia [26]. In that study, the 15-nucleotide deletion was concluded not to be associated with the development of exotropia in schizophrenic patients [26]. The 15-nucleotide deletion in *PHOX2B* results in the loss of 5 alanine residues in the alanine repeat of the protein, and the protein function remains at the 60% level of normal counterparts. Therefore, this deletion would not necessarily exert marked influence.

Single nucleotide changes, insertions, and deletions in *PHOX2B* were also found in neuroblastoma, Hirschsprung's disease, and congenital central hypoventilation syndrome [27–31]. The single nucleotide changes result in amino acid substitution. The deletions are not in units of 3 nucleotides; hence, they result in frame shift mutations. The insertions are in units of 3 nucleotides and result in the addition of alanine residues in the alanine repeat. In contrast with alanine residue loss, alanine residue addition caused marked loss of the protein function [26].

The single nucleotide change in the *PHOX2B* gene, 1121A > C, resulting in no amino acid substitution, was found in 2 separate patients with congenital superior oblique muscle palsy in different families in this study. In our previous study, *PHOX2B* 1121A > C was found only in patients with congenital superior oblique muscle palsy and not in normal individuals, suggesting that *PHOX2B* 1121A > C might be a genetic risk factor for the development of congenital superior oblique muscle palsy [23]. Nevertheless, in this study, the *PHOX2B* 1121A > C polymorphism did not segregate with the muscle palsy in the families, suggesting that this change might not be a genetic risk factor for the development of congenital superior

oblique muscle palsy.

The patients of the three families did not harbor any nucleotide changes in the analyzed exons 8, 20, and 21 of *KIF21A*. We analyzed these 3 exons by sequencing since so far the mutations found in patients with CFEOM type 1 have resided in these exons [15–18]. Therefore, we cannot exclude the possibility that other exons of *KIF21A* harbor nucleotide changes. *KIF21A* gene mutations have been found in CFEOM type 1, which involves primarily the oculomotor nerve, but not the trochlear nerve [15–18]. Based on this fact, the *KIF21A* gene might basically play a minor role in congenital superior oblique muscle palsy, which is caused by trochlear nerve impairment.

In conclusion, we present the clinical characteristics of patients with congenital superior oblique muscle palsy in 3 families, and analyzed candidate genes in the patients of these families. The *ARIX* 153G > A polymorphism was found in common between the patients in 2 families and might be a genetic risk for the development of congenital superior oblique muscle palsy. A *PHOX2B* gene 15-nucleotide deletion, found in 1 patient of the other family (Family No. 2), is not considered responsible for the development of congenital superior oblique muscle palsy. Unknown polymorphisms in the *ARIX* gene, or polymorphisms in the other genes, for instance, involved in the formation of the extraocular muscle, might play a role in the muscle palsy in this family.

Acknowledgments. Supported in part by a Grant-in-Aid (C19592023) for Scientific Research from the Japan Society for the Promotion of Science.

References

- Engle EC: The genetic basis of complex strabismus. *Pediatr Res* (2006) 59: 343–348.
- Traboulsi EI: Congenital abnormalities of cranial nerve development: overview, molecular mechanisms, and further evidence of heterogeneity and complexity of syndromes with congenital limitation of eye movements. *Trans Am Ophthalmol Soc* (2004) 102: 373–389.
- Helveston EM, Krach D, Plager DA and Ellis FD: A new classification of superior oblique palsy based on congenital variations in the tendon. *Ophthalmology* (1992) 99: 1609–1615.
- Plager DA: Tendon laxity in superior oblique palsy. *Ophthalmology* (1992) 99: 1032–1038.
- Matsuo T, Ohtsuki H, Sogabe Y, Konishi H, Takenawa K and Watanabe Y: Vertical abnormal retinal correspondence in three patients with congenital absence of the superior oblique muscle. *Am J Ophthalmol* (1988) 106: 341–345.
- Sato M, Yagasaki T, Kora T and Awaya S: Comparison of muscle volume between congenital and acquired superior oblique palsies by magnetic resonance imaging. *Jpn J Ophthalmol* (1998) 42: 466–470.
- Sato M: Magnetic resonance imaging and tendon anomaly associated with congenital superior oblique palsy. *Am J Ophthalmol* (1999) 127: 379–387.
- Chan TK and Demer JL: Clinical features of congenital absence of the superior oblique muscle as demonstrated by orbital imaging. *J AAPOS* (1999) 3: 143–150.
- Clark RA, Miller JM, Rosenbaum AL and Demer JL: Heterotopic muscles pulleys or oblique muscle dysfunction? *J AAPOS* (1998) 2: 17–25.
- Franceschetti A: Über doppelseitige, kongenitale (familiäre) trochlearislähmung und ihre beziehung zur alternierenden hyperphoria. *Z Augenheilk* (1926) 59: 17–34.
- Bhola RM, Horne GV, Squirell DM, Chan TK and Kumar D: Autosomal dominant congenital superior oblique palsy. *Eye* (2001) 15: 479–484.
- Botelho PJ and Giangiacomo JG: Autosomal-dominant inheritance of congenital superior oblique palsy. *Ophthalmology* (1996) 103: 1508–1511.
- Harris DJ Jr, Memmen JE, Katz NN and Parks MM: Familial congenital superior oblique palsy. *Ophthalmology* (1986) 93: 88–90.
- Astle WF and Rosenbaum AL: Familial congenital fourth cranial nerve palsy. *Arch Ophthalmol* (1985) 103: 532–535.
- Yamada K, Andrews C, Chan WM, McKeown CA, Magli A, De Berardinis T, Loewenstein A, Lazar M, O'Keefe M, Letson R, London A, Ruttum M, Matsumoto N, Saito N, Morris L, Monte MD, Johnson RH, Uyama E, Houtman WA, De Vries B, Carlow TJ, Hart BL, Krawiecki N, Shoffner J, Vogel MC, Katowitz J, Goldstein SM, Levin AV, Sener EC, Ozturk BT, Akarsu AN, Brodsky MC, Hanisch F, Cruse RP, Zubcov AA, Robb RM, Roggenkaemper P, Gottlob I, Kowal L, Battu R, Traboulsi EI, Franceschini P, Newlin A, Demer JL and Engle EC: Heterozygous mutations of the kinesin KIF21A in congenital fibrosis of the extraocular muscles type 1 (CFEOM1). *Nat Genet* (2003) 35: 318–321.
- Chan WM, Andrews C, Dragan L, Fredrick D, Armstrong L, Lyons C, Geraghty MT, Hunter DG, Yazdani A, Traboulsi EI, Pott JWR, Gutowski NJ, Ellard S, Young E, Hanisch F, Koc F, Schnall B and Engle EC: Three novel mutations in KIF21A highlight the importance of the third coiled-coiled stalk domain in the etiology of CFEOM1. *BMC Genet* (2007) 8: 26.
- Lin LK, Chien YH, Wu JY, Wang AH, Chiang SC and Hwu WL: KIF21A gene c.2860C > T mutation in congenital fibrosis of extraocular muscles type 1 and 3. *Mol Vis* (2005) 11: 245–248.
- Shimizu S, Okinaga A and Maruo T: Recurrent mutation of the KIF21A gene in Japanese patients with congenital fibrosis of the extraocular muscles. *Jpn J Ophthalmol* (2005) 49: 443–447.
- Nakano M, Yamada K, Fain J, Sener EC, Selleck CJ, Awad AH, Zwaan J, Mullaney PB, Bosley TM and Engle EC: Homozygous mutations in *ARIX* (*PHOX2A*) result in congenital fibrosis of the extraocular muscles type 2. *Nat Genet* (2001) 29: 315–320.
- Yazdani A, Chung DC, Abbaszadegan MR, Al-Khayer K, Chan WM, Yazdani M, Ghodsi K, Engle EC and Traboulsi EI: A novel *PHOX2A/ARIX* mutation in an Iranian family with congenital fibrosis of extraocular muscles type 2 (CFEOM2). *Am J Ophthalmol* (2003) 136: 861–865.
- Engle EC, Goumnerov BC, McKeown CA, Schatz M, Johns DR, Porter JD and Beggs AH: Oculomotor nerve and muscle abnormalities in congenital fibrosis of the extraocular muscles. *Ann Neurol*

- (1997) 41: 314-325.
22. Jiang Y, Matsuo T, Fujiwara H, Hasebe S, Ohtsuki H and Yasuda T: ARIX gene polymorphisms in patients with congenital superior oblique muscle palsy. *Br J Ophthalmol* (2004) 88: 263-267.
 23. Jiang Y, Matsuo T, Fujiwara H, Hasebe S, Ohtsuki H and Yasuda T: ARIX and PHOX2B polymorphisms in patients with congenital superior oblique muscle palsy. *Acta Med Okayama* (2005) 59: 55-62.
 24. Pattyn A, Morin X, Cremer H, Goridis C and Brunet JF: Expression and interactions of the two closely related homeobox genes *Phox2a* and *Phox2b* during neurogenesis. *Development* (1997) 124: 4065-4075.
 25. Pattyn A, Hirsch MR, Goridis C and Brunet JF: Control of hind-brain motor neuron differentiation by the homeobox gene *Phox2b*. *Development* (2000) 127: 1349-1358.
 26. Toyota T, Yoshitsugu K, Ebihara M, Yamada K, Ohba H, Fukasawa M, Minabe Y, Nakamura K, Sekine Y, Takei N, Suzuki K, Itokawa M, Meerabux JMA, Iwayama-Shigeno Y, Tomaru Y, Shimizu H, Hattori E, Mori N and Yoshikawa T: Association between schizophrenia with ocular misalignment and polyalanine length variation in *PMX2B*. *Hum Mol Genet* (2004) 13: 551-561.
 27. McConville C, Reid S, Baskcomb L, Douglas J and Rahman N: PHOX2B analysis in non-syndromic neuroblastoma cases shows novel mutations and genotype-phenotype associations. *Am J Med Genet Part A* (2006) 140: 1297-1301.
 28. Amiel J, Laudier B, Attie-Bitach T, Trang H, de Pontual L, Gener B, Trochet D, Etchevers H, Ray P, Simonneau M, Vekemans M, Munnich A, Gaultier C and Lyonnet S: Polyalanine expansion and frameshift mutations of the paired-like homeobox gene *PHOX2B* in congenital central hypoventilation syndrome. *Nat Genet* (2003) 33: 459-461.
 29. Matera I, Bachetti T, Puppo F, Di Duca M, Morandi F, Casiraghi GM, Cilio MR, Hennekam R, Hofstra R, Schober JG, Ravazzolo R, Ottonello G and Ceccherini I: *PHOX2B* mutations and polyalanine expansions correlate with the severity of the respiratory phenotype and associated symptoms in both congenital and late onset Central Hypoventilation syndrome. *J Med Genet* (2004) 41: 373-380.
 30. Trochet D, Bourdeaut F, Janoueix-Lerosey I, Deville A, de Pontual L, Schleiermacher G, Coze C, Philip N, Frebouret T, Munnich A, Lyonnet S, Delattre O and Amiel J: Germline mutations of the paired-like homeobox 2B (*PHOX2B*) gene in neuroblastoma. *Am J Hum Genet* (2004) 74: 761-764.
 31. Benailly HK, Lapierre JM, Laudier B, Amiel J, Attie T, De Blois MC, Vekemans M and Romana SP: *PMX2B*, a new candidate gene for Hirschsprung's disease. *Clin Genet* (2003) 64: 204-209.