

Acta Medica Okayama

Volume 50, Issue 4

1996

Article 3

AUGUST 1996

Superoxide Dismutase Activity in Cerebrospinal Fluid and Its Relation to Compression of the Lumbosacral Nerve Root

Toshinori Tamada*

Hajime Inoue†

Akitane Mori‡

*Okayama University,

†Okayama University,

‡Okayama Univeristy,

Superoxide Dismutase Activity in Cerebrospinal Fluid and Its Relation to Compression of the Lumbosacral Nerve Root*

Toshinori Tamada, Hajime Inoue, and Akitane Mori

Abstract

In the pathophysiology of lumbosacral radiculopathy, inflammation of the nerve root is of critical importance. Additionally, free radicals have been shown to be associated with some inflammatory process. This study was designed to investigate whether free radicals participate in the pathophysiology of nerve root involvement. We measured superoxide dismutase (SOD) activity in cerebrospinal fluid (CSF) of 31 patients with unilateral lumbosacral radiculopathy caused by a herniated disc using electron spin resonance (ESR) spectrometry. Then SOD activity was compared with the type of nerve root compression as seen on preoperative myelography. SOD activity in the normal control group was 7U/ml, while that in the hernia group remarkably decreased. The concentration gradient of SOD activity was different between central herniation and centrolateral herniation. Our findings indicate that free radicals are generated after nerve root compression. Under severe deficiency of SOD activity in CSF, serum SOD penetrates into CSF after further compression. In addition, SOD in CSF may play an important role in protecting against nerve root involvement.

KEYWORDS: superoxide dismutase(SOD), cerebrospinal fluid(CSF), nerve root compression, inflammation, free radicals

*PMID: 8874581 [PubMed - indexed for MEDLINE]

Copyright (C) OKAYAMA UNIVERSITY MEDICAL SCHOOL

Superoxide Dismutase Activity in Cerebrospinal Fluid and Its Relation to Compression of the Lumbosacral Nerve Root

Toshinori TAMADA*, Hajime INOUE and Akitane MORI^a

Department of Orthopaedic Surgery, Okayama University Medical School and ^aDepartment of Neuroscience, Institute of Cellular and Molecular Medicine, Okayama University Medical School, Okayama 700, Japan

In the pathophysiology of lumbosacral radiculopathy, inflammation of the nerve root is of critical importance. Additionally, free radicals have been shown to be associated with some inflammatory process. This study was designed to investigate whether free radicals participate in the pathophysiology of nerve root involvement. We measured superoxide dismutase (SOD) activity in cerebrospinal fluid (CSF) of 31 patients with unilateral lumbosacral radiculopathy caused by a herniated disc using electron spin resonance (ESR) spectrometry. Then SOD activity was compared with the type of nerve root compression as seen on preoperative myelography. SOD activity in the normal control group was 7 U/ml, while that in the hernia group remarkably decreased. The concentration gradient of SOD activity was different between central herniation and centrolateral herniation. Our findings indicate that free radicals are generated after nerve root compression. Under severe deficiency of SOD activity in CSF, serum SOD penetrates into CSF after further compression. In addition, SOD in CSF may play an important role in protecting against nerve root involvement.

Key words: superoxide dismutase (SOD), cerebrospinal fluid (CSF), nerve root compression, inflammation, free radicals

In the pathophysiology of lumbosacral radiculopathy, inflammation of the nerve root is of critical importance (1). Lumbosacral radiculopathy is probably initiated by mechanical nerve root compression and becomes more severe by disturbance of microcirculation (2) and/or blockage of cerebrospinal fluid (CSF) flow (3-9) inside the nerve root. However, no systematic review has been done on the morphological and physiological aspects of

nerve root compression. We think that lumbosacral radiculopathy, which has so far been presumed to be induced by the above process, is produced at the final stage of some inflammatory process.

Free radicals play important roles in the pathogenesis of various diseases and have been shown to be associated with some inflammatory process. Superoxide (O_2^-), an oxygen-derived free radical, is generated during ischemia-reperfusion injury of microcirculation (10, 11) and following activation of granulocytes (12). Superoxide dismutase (SOD)(13), which catalyzes the dismutation of O_2^- , participates in the scavenging systems due to free radicals and thereby protects the aggravation against tissue injuries associated with inflammation. SOD activity can be measured by electron spin resonance (ESR) spectrometry (14, 15), and the fluctuation in SOD activity indicates the generation of O_2^- . We expect that O_2^- and SOD may fluctuate at a certain stage of the inflammatory process from nerve root compression to lumbosacral radiculopathy.

This study was designed to investigate whether free radicals participate in the pathophysiology of nerve root involvement. We measured SOD activity in CSF of 31 patients with unilateral lumbosacral radiculopathy caused by a herniated disc using ESR spectrometry, and then SOD activity was compared with the type of nerve root compression as seen on preoperative myelography. We hypothesize that the inflammatory process from nerve root compression progresses to the formation of intraneural edema.

Materials and Methods

Subjects. The subjects of this study were 31 patients with unilateral lumbosacral radiculopathy caused

* To whom correspondence should be addressed.

by a herniated disc (hernia group). Soon after hospitalization for acute radicular pain, they underwent lumbar myelography. Four of these patients were treated conservatively with bed rest, but the other 27 patients were operated on and a herniated disc was confirmed. In the normal control group, 18 patients with trauma in the lower extremities but without neurological symptoms such as radicular pain were included.

The hernia group consisted of 10 women and 21 men, ranging in age from 19 to 59 years (mean age, 39 years). The control group consisted of 6 women and 12 men, ranging in age from 11 to 55 years (mean age, 32 years).

Evaluation by myelography. All the patients were evaluated by preoperative lumbar myelography to determine the involvement of the dural sac and/or the nerve root. Using myelographic findings on the posteroanterior projection, we classified the patients in the hernia group into two types (Fig. 1): those with central herniation who had unilateral radiculopathy and a positive myelogram on the non-symptomatic as well as the symptomatic side, and those with centrolateral herniation who had a positive myelogram on the symptomatic side alone. This classification by myelographic findings accorded with the findings at surgery regarding the site of the herniated disc and the magnitude of compression. The patients with centrolateral herniation showed more compression against the nerve root than against the dural sac, and had severer radicular pain than those with central herniation.

Collection of CSF. CSF was taken by lumbar puncture at the time of lumbar myelography in the hernia

group and lumbar anesthesia in the control group. Immediately after lumbar puncture, 0.5 ml of CSF as "Initial CSF" and then 5 ml of CSF as "Final CSF" were collected from the level of the herniated disc or above. When nerve root compression affects CSF locally and its effect diffuses farther, initial CSF should fluctuate firstly and final CSF does secondly. Initial CSF appeared to indicate current CSF, while final CSF appeared to indicate past CSF with respect to persistent local fluctuation. CSF samples were centrifuged at 1000 *g* for 10 min, and the supernatant solutions were frozen and kept at -80°C until analysis.

Measurement of SOD activity. SOD activity in CSF was measured by ESR spectrometry using the spin-trap method (14, 15); O_2^- generated by hypoxanthine (2 mM, 50 μl) and xanthine oxidase (0.326 U/ml, 50 μl) *in vitro* was simultaneously trapped with the use of 5, 5-dimethyl-1-pyrroline-1-oxide (DMPO: 9.8 mM, 15 μl), and DMPO- O_2^- spin adduct was analyzed using a JES-FE1XG ESR spectrometer (JEOL, Tokyo, Japan). SOD activity was calculated under the standard curve using decreased spin adduct with known SOD unit and the unit was defined according to McCord and Fridovich (13). The values obtained by ESR method closely correlated with those obtained by the cytochrome *c* reductase method (15). The conditions of ESR spectrometry were as follows: magnetic field, 335 ± 5 mT; power, 8.0 mW; modulation, 0.8 mT; amplitude, 400; response, 0.1 sec; sweep time, 2 min; and at room temperature.

Statistical analysis. Statistical analysis was

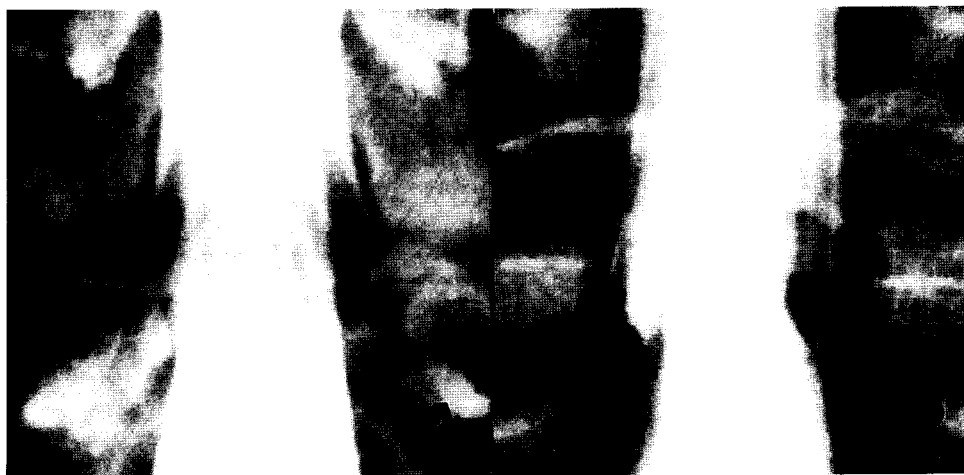

Fig. 1 Preoperative myelograms on the posteroanterior projection of two types of herniated discs at L4/L5 level. In both cases, symptoms were right-sided. A: Central herniation, B: Centrolateral herniation.

performed using Student's *t*-test. The paired *t*-test was used to compare SOD activity between initial CSF and final CSF, while the unpaired *t*-test was used to compare two groups or two types of herniated discs. We considered differences significant when $P < 0.05$.

Results

In the normal control group, neither age nor sex had any effect on SOD activity in CSF and mean SOD activity was 6.927 U/ml in initial CSF and 7.335 U/ml in final CSF. There were no differences ($P = 0.19$) in SOD activity between initial CSF and final CSF. In all the patients with a herniated disc, central herniation or centrolateral herniation, SOD activities in both initial

CSF and final CSF were significantly less than in the control group (Figs. 2 and 3). SOD activity of final CSF in the patients with centrolateral herniation was far less ($P < 0.05$) than that in the patients with central herniation.

We defined the concentration gradient as the difference in SOD activity between initial CSF and final CSF:

$$\text{Concentration gradient} = \frac{\text{SOD activity in initial CSF} - \text{SOD activity in final CSF}}{\text{SOD activity in CSF}}$$

The concentration gradient of SOD activity was negative ($P < 0.05$) in the patients with central herniation and positive ($P < 0.05$) in the patients with centrolateral herniation, while no gradient ($P = 0.19$) was observed in the control group (Table 1).

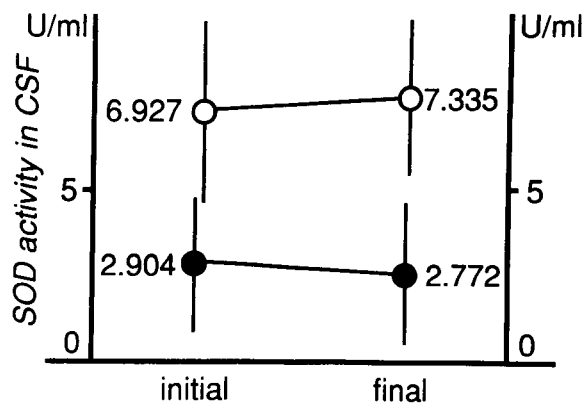


Fig. 2 Superoxide dismutase (SOD) activity in cerebrospinal fluid (CSF). In the hernia group (●—●), SOD activities in both initial CSF and final CSF were significantly less ($P < 0.00001$) than in the normal control group (○—○).

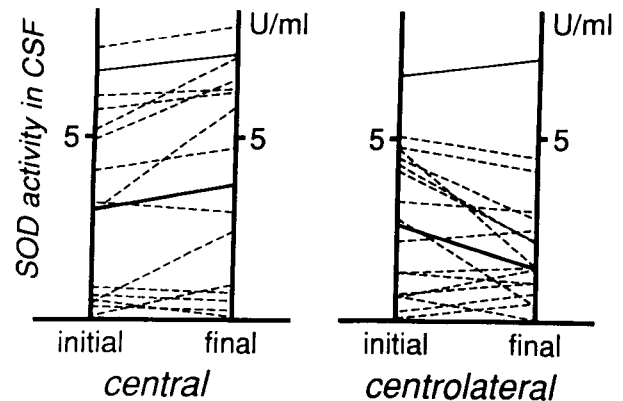


Fig. 3 SOD activities for all the patients with herniated discs (dotted lines). The mean for each hernia type is shown with a thick solid line. The mean for the control group is shown with a thin solid line. SOD: See legend to Fig. 2

Table I Superoxide dismutase (SOD) activity in cerebrospinal fluid (CSF)

Group	No. of cases	SOD activity (U/ml) [±]		Concentration gradient (U/ml) [±]
		Initial	Final	
Hernia				
Central	14	3.150 ± 2.541	3.828 ± 3.054*	-0.678 ± 1.077**
Centrolateral	17	2.703 ± 2.040	1.902 ± 1.185*	0.798 ± 1.440**
Total	31	2.904 ± 2.298	2.772 ± 2.397	0.132 ± 1.473
Normal				
Normal	18	6.927 ± 2.796	7.335 ± 2.508	-0.408 ± 1.281

[±], Mean ± SD; *, $P < 0.05$; **, $P < 0.005$.

Discussion

The question designed in this study is whether free radicals participate in the pathophysiology of nerve root involvement. If the generation of free radicals exceeds the capacity of the scavenging systems, excess free radicals may contribute markedly to the aggravation of tissue injuries associated with inflammation.

Lumbar CSF springs from the fourth ventricle and circulates in the subarachnoid space with the flow shifting to the cephalic or the caudal direction depending on the respiratory and cardiac cycles (16, 17), but its flow in the lumbar spine is absent or minimal (17). Because CSF has only minimal flow in the lumbar spine, the fluctuation of SOD activity under pathological conditions persists for some time. This persistent local fluctuation brings about the concentration gradient of SOD activity in CSF. The nerve root and its fibers are surrounded by CSF, which may offer them mechanical protection (2) as well as nutritional support (4-6, 8). Morphological observations by electron microscopy have demonstrated that CSF is linked with the endoneurial fluid inside the nerve root (18-20). Therefore, the study of CSF makes it possible to investigate the pathophysiology of nerve root involvement.

The first finding is that free radicals are generated after nerve root compression. In fact, SOD activity in the control group was approximately 7U/ml, while that in the hernia group remarkably decreased (Figs. 2 and 3). Experimental studies have shown that blood flow inside the nerve root is disturbed during nerve root compression and is restored after its release (21, 22). Disturbance of microcirculation results in increased anaerobic metabolism of the nerve root (23). McCord and Granger proposed that ischemia-reperfusion injury of microcirculation under hypoxic conditions leads to the generation of O_2^- via the xanthine oxidase (XO) pathway, and we concur with this view (10, 11). The O_2^- generated by this process is immediately quenched by the scavenging systems in the endoneurial fluid. Consequently, SOD activity decreases in initial CSF firstly and obviously has a negative concentration gradient. In fact, the gradient was negative in the patients with central herniation (Fig. 3 and Table 1). Under severe deficiency of SOD activity, if excess free radicals are generated after further compression, the scavenging systems are broken down.

The second finding is that serum SOD penetrates into

CSF after further nerve root compression under severe deficiency of SOD activity in CSF described above. In fact, the concentration gradient of SOD activity was different between central herniation and centrolateral herniation. Theoretically, the concentration gradient of SOD activity would be expected to be negative. On the contrary, the concentration gradient was positive under severe deficiency of SOD activity in the patients with centrolateral herniation (Fig. 3 and Table 1). It has been previously reported that serum proteins penetrate into CSF in the patients with lumbosacral radiculopathy and sciatica (24), especially with centrolateral herniation (25). Recent magnetic resonance imaging (MRI) studies have demonstrated gadolinium-DTPA enhancement of the nerve root compressed by a herniated disc (26). Experimentally (19, 22, 27, 28) and clinically (29), further compression leads to increased microvascular permeability of vessels intrinsic to the nerve root and the breakdown of the blood-nerve barrier, resulting in the formation of intraneurial edema. Normal SOD activity in serum is approximately 5U/ml (14). We suggest that serum SOD penetrates into CSF after further compression. SOD activity increases with serum SOD, in initial CSF firstly. Thus, the finding of a positive concentration gradient of SOD activity implies that further compression may lead to the breakdown of the blood-nerve barrier.

We propose that the blood-nerve barrier breaks down by the following inflammatory process: After nerve root compression and its release, O_2^- is generated around endothelial cells via the XO pathway, which is activated by ischemia-reperfusion injury of microcirculation (10, 11). This reaction initiates the production of chemical mediators and adhesion molecules, enabling the interaction of granulocytes with endothelial cells (12). These activated granulocytes generate excess O_2^- via the NADPH oxidase pathway. The excess O_2^- leads to the breakdown of the blood-nerve barrier (30). Under severe deficiency of SOD activity in CSF, oxygen-derived free radicals readily aggravate tissue injuries.

In summary, our findings indicate that free radicals participate in the pathophysiology of nerve root involvement. In addition, SOD in CSF may play an important role in protecting against its progression. We have formulated the following hypothesis concerning the pathophysiology of nerve root involvement: Free radicals are generated during ischemia-reperfusion injury of microcirculation after nerve root compression. The blood-nerve barrier is then broken by the damage due to excess free

August 1996

Pathophysiology of Nerve Root Involvement 201

radicals after further compression, resulting in the formation of intraneurial edema. Although the present findings help clarify the inflammatory process of the acute and early stage in the pathophysiology of nerve root involvement, it is still unknown which stage may be connected with each neurological symptom such as radicular pain, sensory deficit and muscle weakness. We believe that these symptoms may be attenuated if the progression of nerve root involvement could be stopped during the above process.

SOD activity in CSF and its concentration gradient may help quantify nerve root involvement not previously detectable by imaging modalities. In addition, SOD may prove useful for the treatment of lumbosacral radiculopathy. Without the breakdown of the scavenging systems due to free radicals, some patients with a herniated disc may have less severe neurological symptoms.

References

- Garfin SR, Rydevik BL and Brown RA: Compressive neuropathy of spinal nerve roots: A mechanical or biological problem? *Spine* (1991) **16**, 162-166.
- Rydevik B, Brown MD and Lundborg G: Pathoanatomy and pathophysiology of nerve root compression. *Spine* (1984) **9**, 7-15.
- Olmarker K, Rydevik B, Hansson T and Holm S: Compression-induced changes of the nutritional supply to the porcine cauda equina. *J Spinal Disorders* (1990) **3**, 25-29.
- Olmarker K: Spinal nerve root compression: Nutrition and function of the porcine cauda equina compressed *in vivo*. *Acta Orthop Scand* (1991) **242** (Suppl) 1-27.
- Olmarker K and Rydevik B: Pathophysiology of sciatica. *Orthop Clin North Am* (1991) **22**, 223-234.
- Rydevik B, Holm S, Brown MD and Lundborg G: Diffusion from the cerebrospinal fluid as a nutritional pathway for spinal nerve roots. *Acta Physiol Scand* (1990) **138**, 247-248.
- Rydevik B: Neurophysiology of cauda equina compression. *Acta Orthop Scand* (1993) **251** (Suppl) 52-55.
- Yoshizawa H, Kobayashi S and Kubota K: Effects of compression on intradiscal blood flow in dogs. *Spine* (1989) **14**, 1220-1225.
- Yoshizawa H, Kobayashi S and Hachiya Y: Blood supply of nerve roots and dorsal root ganglia. *Orthop Clin North Am* (1991) **22**, 195-211.
- Granger DN, Rutigliano G and McCord JM: Superoxide radicals in feline intestinal ischemia. *Gastroenterology* (1981) **81**, 22-29.
- McCord JM: Oxygen-derived free radicals in postischemic tissue injury. *N Engl J Med* (1985) **312**, 159-163.
- Grisham MB, Hernandez LA and Granger DN: Xanthine oxidase and neutrophil infiltration in intestinal ischemia. *Am J Physiol* (1986) **251**, G567-574.
- McCord JM and Fridovich I: Superoxide dismutase: An enzymic function for erythrocuprein (hemocuprein). *J Biol Chem* (1969) **244**, 6049-6055.
- Hiramatsu M and Kohno M: Determination of superoxide dismutase activity by electron spin resonance spectrometry using the spin trap method. *Jpn Electron Opt Lab News* (1987) **23A**, 7-9.
- Hiramatsu M, Kohno M, Edamatsu R, Mitsuta K and Mori A: Increased superoxide dismutase activity in aged human cerebrospinal fluid and rat brain determined by electron spin resonance spectrometry using the spin trap method. *J Neurochem* (1992) **58**, 1160-1164.
- Lane B and Kricheff II: Cerebrospinal fluid pulsations at myelography: A videodensitometric study. *Radiology* (1974) **110**, 579-587.
- Rubin JB and Enzmann DR: Imaging of spinal CSF pulsation by 2DFT MR: Significance during clinical imaging. *Am J Roentgenol* (1987) **148**, 973-982.
- Kobayashi S, Yoshizawa H, Hachiya Y, Kurose J and Ukai T: Fine structure of subarachnoid space in cauda equina region: Scanning electron microscopic study. *Cent Jpn J Orthop Traumatol* (1990) **33**, 1999-2000 (in Japanese).
- Kobayashi S, Yoshizawa H, Hachiya Y, Nakagawa M and Ukai T: Fine structure of lumbosacral spinal nerve root: Transmission electron microscopic study. *Cent Jpn J Orthop Traumatol* (1991) **34**, 463-465 (in Japanese).
- Malloy JJ and Low FN: Scanning electron microscopy of the subarachnoid space in the dog: II. Spinal nerve exits. *J Comp Neurol* (1974) **157**, 87-108.
- Kobayashi S, Yoshizawa H, Nakai S, Nishizawa K and Hachiya Y: Experimental study on the effect of mechanical compression on the lumbar nerve root in dog. *Cent Jpn J Orthop Traumatol* (1989) **32**, 135-138 (in Japanese).
- Olmarker K, Rydevik B, Holm S and Bagge U: Effects of experimental graded compression on blood flow in spinal nerve roots: A vital microscopic study on the porcine cauda equina. *J Orthop Res* (1989) **7**, 817-823.
- Nakagawa M, Yoshizawa H, Kobayashi S, Ukai T and Hachiya Y: Pathophysiology of nerve root compression: Changes of PO₂ and pH in nerve root due to acute compression. *Cent Jpn J Orthop Traumatol* (1992) **35**, 395-396 (in Japanese).
- Tunevall TG: Cerebrospinal fluid protein: An aid in the diagnosis of herniated discs. *Acta Chir Scand* (1984) **520** (Suppl) 85-86.
- Skouen JS, Larsen JL and Vollset SE: Cerebrospinal fluid proteins as indicators of nerve root compression in patients with sciatica caused by disc herniation. *Spine* (1993) **18**, 72-79.
- Toyone T, Takahashi K, Kitahara H, Yamagata M, Murakami M and Moriya H: Visualisation of symptomatic nerve roots: Prospective study of contrast-enhanced MRI in patients with lumbar disc herniation. *J Bone Joint Surg [Br]* (1993) **75**, 529-533.
- Kobayashi S, Yoshizawa H, Hachiya Y, Kurose J and Ukai T: Effects of changes in cerebrospinal fluid flow on nerve root. *J Jpn Orthop Assoc* (1991) **65**, S935 (in Japanese).
- Olmarker K, Rydevik B and Holm S: Edema formation in spinal nerve roots induced by experimental, graded compression: An experimental study on the pig cauda equina with special reference to differences in effects between rapid and slow onset of compression. *Spine* (1989) **14**, 569-573.
- Takata K, Inoue S, Takahashi K and Ohtsuka Y: Swelling of the cauda equina in patients who have herniation of a lumbar disc: A possible pathogenesis of sciatica. *J Bone Joint Surg [Am]* (1988) **70**, 361-368.
- Hernandez LA, Grisham MB, Twohig B, Arfors KE, Harlan JM and Granger DN: Role of neutrophils in ischemia-reperfusion-induced microvascular injury. *Am J Physiol* (1987) **253**, H699-703.

Received November 15, 1995; accepted March 28, 1996.