

# *Acta Medica Okayama*

---

*Volume 34, Issue 6*

1980

*Article 5*

DECEMBER 1980

---

## Transplantable murine plasma cell leukemia with polyclonal gammopathy

Tokichi Yumoto\*

Haruhiko Yoshida†

Kazufumi Ando‡

Toshio Tanaka\*\*

\*Tottori University,

†Tottori University,

‡Tottori University,

\*\*Okayama University,

# Transplantable murine plasma cell leukemia with polyclonal gammopathy\*

Tokichi Yumoto, Haruhiko Yoshida, Kazufumi Ando, and Toshio Tanaka

## Abstract

A transplantable plasma cell leukemia cell line, designated as S27, was established from a 12-month-old female New Zealand Black mouse (NZB); serum showed polyclonal elevation of gamma globulin with agarose-agar gel electrophoresis. Immunoelectrophoretic analysis of the serum showed precipitation lines in the IgG1, IgG2a, IgG2b and IgM regions. The amount of serum immunoglobulin increased rapidly with tumor growth. S27 cells proliferating in the spleen contained simultaneously IgG1, IgG2a, IgG2b in the cytoplasm as revealed by indirect immunofluorescence. Membrane immunofluorescence revealed IgG1 on the tumor cell surface. S27 cells were transplantable to syngeneic NZB mice with inoculation of spleen cell suspension, and showed the same histological and immunological findings as those of the original mouse. These findings imply that a single clone of plasma cells has the capacity to produce more than one class of immunoglobulin.

**KEYWORDS:** polyclonal gammopathy, plasma cell leukemia, mouse

---

\*PMID: 6451145 [PubMed - indexed for MEDLINE]

Copyright (C) OKAYAMA UNIVERSITY MEDICAL SCHOOL

Acta Med. Okayama 34, (6), 389—399 (1980)

## TRANSPLANTABLE MURINE PLASMA CELL LEUKEMIA WITH POLYCLONAL GAMMOPATHY

Tokichi YUMOTO, Haruhiko YOSHIDA, Kazufumi ANDO  
and Toshio TANAKA\*

*Department of Pathology, Tottori University School of Medicine, Yonago 683; and*

*\*Pathology Section, Central Laboratories, Okayama University*

*Medical School, Okayama 700, Japan*

*Received October 17, 1980*

*Abstract.* A transplantable plasma cell leukemia cell line, designated as S27, was established from a 12-month-old female New Zealand Black mouse (NZB); serum showed polyclonal elevation of gamma globulin with agarose-agar gel electrophoresis. Immunoelectrophoretic analysis of the serum showed precipitation lines in the IgG<sub>1</sub>, IgG<sub>2a</sub>, IgG<sub>2b</sub> and IgM regions. The amount of serum immunoglobulin increased rapidly with tumor growth. S27 cells proliferating in the spleen contained simultaneously IgG<sub>1</sub>, IgG<sub>2a</sub>, IgG<sub>2b</sub> in the cytoplasm as revealed by indirect immunofluorescence. Membrane immunofluorescence revealed IgG<sub>1</sub> on the tumor cell surface. S27 cells were transplantable to syngeneic NZB mice with inoculation of spleen cell suspension, and showed the same histological and immunological findings as those of the original mouse. These findings imply that a single clone of plasma cells has the capacity to produce more than one class of immunoglobulin.

*Key words:* polyclonal gammopathy, plasma cell leukemia, mouse.

It is well known that New Zealand Black mice (NZB) spontaneously develop autoimmune disease as indicated by autoimmune hemolytic anemia, immune complex glomerulonephritis and lymphoreticular malignancies because of characteristic immune abnormalities (1, 2). Recent studies suggest that a loss of suppressor T cell function leads to the induction of autoimmune disease (3–6). NZB are a suitable model for investigating the relationship between autoimmune disease and malignant lymphoma, as we have reported previously (7–9). We report here a transplantable plasma cell leukemia, designated as S27, which secretes polyclonal gamma globulin, and discuss the relationship between malignant transformation and differentiation of immunoglobulin-producing cells.

### MATERIALS AND METHODS

*Mouse.* NZB used came originally from the M. D. Anderson Hospital and Tumor Institute, Houston, Texas (10), and have been maintained in our laboratory. Some other strains including CBA, A/J, C<sub>3</sub>H, AKR, BALB/c, CF<sub>1</sub> and (NZB×A/J)F<sub>1</sub> mice were used as controls.

*Tumor transplantation.* Serial transplantations of S27 cells were made by inoculating a piece of spleen tissue, 1×1mm in size, subcutaneously, or 0.2ml spleen cell suspension (tenfold, weight/vol) intraperitoneally to 1- to 2-month-old female NZB.

*Serum protein.* Electrophoresis and immunoelectrophoresis were performed in 1% agarose-agar gel buffered with Veronal buffer (pH 8.6,  $\mu=0.05$ ) on glass plates for 70 min at 140 vol. Rabbit anti-mouse IgG<sub>1</sub>, IgG<sub>2a</sub>, IgG<sub>2b</sub> and IgM sera were prepared as reported previously (8).

*Histological examination.* Tissues were fixed with 10% neutral formalin and 95% alcohol, and sections were stained with hematoxylin and eosin, periodic acid-Schiff, methylgreen pyronine and silver. For electron microscopy, tumor tissue was fixed with 4% glutaraldehyde, washed with phosphate buffer and postfixed with 2% osmic acid for 1.5 h. After being dehydrated in graded acetone, they were embedded in Epon 812. Double staining with saturated uranyl acetate and lead nitrate was employed.

*Indirect immunofluorescent method.* The specimens were fixed with an equivalent solution of acetone-alcohol. After being washed twice with cold staining buffer, one drop of diluted rabbit antisera of about 5 gamma was placed on a section, which was then incubated in a humid chamber at 37°C for 30 min. Each section had diluted FITC-conjugated goat anti-rabbit IgG added for 5 h, was incubated in a humid chamber for 30 min at room temperature, washed again twice with cold staining buffer, and mounted in an equal volume of glycerol and staining buffer. Antisera were the same as those used in immunoelectrophoresis. The procedure for membrane immunofluorescence was as follows: Washed spleen cell suspension (0.1 ml/5×10<sup>5</sup> cells) was incubated at 37°C for 30 min with an equivalent volume of diluted antisera, washed three times with cold staining buffer, resuspended in 0.1 ml staining buffer, had 0.1 ml diluted FITC-conjugated goat anti rabbit IgG added, incubated for 30 min at room temperature, washed three times with cold staining buffer, and observed under a fluorescent microscope.

## RESULTS

### Original Tumor

Plasma cell leukemia occurred spontaneously in a 12-month-old female NZB. Grossly, there were marked splenomegaly of 2.31 g, hepatomegaly and generalized lymphadenopathy (Fig. 1). Histological examination showed massive proliferation consisting of plasmacytoid and large lymphoid cells at the follicles; this caused splenomegaly. Plasmacytoid cells were closely packed, were medium sized, and had a round to oval nucleus and relatively abundant, faintly basophilic cytoplasm. White pulp of the spleen (Fig. 2), lymph nodes (Fig. 3) and periportal area and sinusoids of the liver were extensively infiltrated by tumor cells.

Using agarose-agar gel electrophoresis, serum protein analysis of tumor-

bearing mouse revealed the presence of a diffuse band in the gamma globulin region. Immunoelectrophoresis showed marked precipitation against anti-mouse IgG<sub>1</sub>, IgG<sub>2a</sub>, IgG<sub>2b</sub> and IgM antisera (Fig. 4).

#### Transplantation Experiment

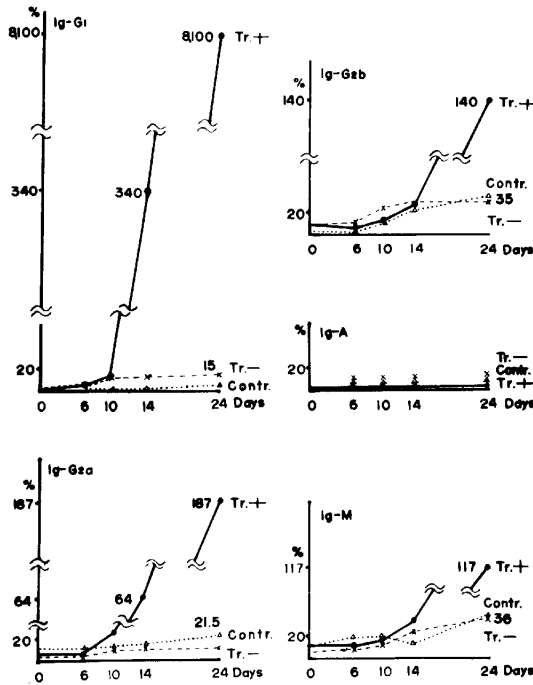
By transplanting tumor cells from S27-bearing mouse, similar lesions appeared in recipient mice such as splenomegaly complicated by enlarged liver and lymph nodes (Fig. 5). Tumors did not appear at the site of inoculation while transplantation proceeded successfully. Tumor developed at a high incidence of 77.2%, being 88 of 114 treated mice, up to the 10th generation (Table 1). The survival time ranged from 16 to 200 days (means: 40.8 days).

TABLE 1. TRANSPLANTATION EXPERIMENT OF S27-PLASMA CELL LEUKEMIA

Generation of transplantation	Tumors in take (%)	Survival time, Mean (days)	Spleen weight, Mean (g)
T-1	3/3(100)	127.6	2.08
T-2	2/9(22.2)	139.5	1.18
T-3	5/6(83.3)	92.8	1.53
T-4	7/13(53.8)	50.1	1.57
T-5	15/18(83.3)	39.1	1.27
T-6	14/16(87.5)	27.3	1.22
T-7	12/14(85.7)	30.0	1.46
T-8	12/12(100)	27.1	1.45
T-9	8/11(72.7)	31.6	1.26
T-10	10/12(83.3)	20.6	1.14

It shortened to a few weeks following repeated passages. A transplantation was successful to (NZB×A/J)F<sub>1</sub> mouse, but not to allogeneic mice such as CF<sub>1</sub>, C<sub>3</sub>H, AKR, BALB/c and CBA. Tumors never developed in NZB that were injected intraperitoneally with cell-free extract of the spleen from S27-bearing mouse.

*Serum immunoglobulin (Ig).* With agarose-agar gel electrophoresis, the sera of S27-bearing mice developed diffuse polyclonal elevation of gamma globulin region 10 days after inoculation. Thereafter, paralleling tumor growth, the gamma globulin, in particular IgG<sub>1</sub>, rapidly increased 800-fold in comparison with that of mice of the same age (Text Fig. 1). This characteristic had been retained in all mice throughout serial transplantations. Immunoelectrophoresis with Ig class-specific antisera indicated that hypergamma-globulinemia was due to increased IgG<sub>1</sub>, IgG<sub>2a</sub>, IgG<sub>2b</sub> and IgM. Precipitation lines were more intense with rabbit anti-mouse IgG<sub>1</sub> antiserum and faintly recognizable with anti-mouse IgG<sub>2a</sub>, IgG<sub>2b</sub> and IgM antisera (Fig. 6).



Text Fig. 1. Sequential change of immunoglobulins in serum from S27-plasma cell leukemia-bearing mouse. —••• Tr. + : S27 Tumor-bearing mouse ; ×---× Tr. - : S27 Tumor-untaken mouse ; △•••△ Contr: Control NZB mouse.

*Light microscopic findings.* Histologically, the original and serially transplanted tumors did not differ much. The spleen and lymph nodes showed prominent proliferation of mixed plasmacytoid and large lymphoid cells to manifest enlarged follicles (Fig. 7). The cytoplasm was stained strongly positive with methylgreen pyronine. Cells also infiltrated the sinusoids of the liver, and perivascular spaces of the lung and kidney. Epithelioid granulomas composed of large pale histiocytic cells and eosinophils were occasionally seen in the involved spleen and lymph nodes.

*Electron microscopic observation.* Tumor cells were divided into two major groups, *i.e.*, plasmacytoid and lymphoid cells; lymphoid cells appeared to transform to plasmacytoid cells. The cytoplasm of plasmacytoid cells had well developed, distended, rough endoplasmic reticula, well developed Golgi's apparatus, and large mitochondria scattered among rough endoplasmic reticula. The nucleus was oval with aggregated chromatin and a prominent large nucleolus. The lymphoid cells presented with a sequence of cell maturation. In general, they had an oval nucleus and scant cytoplasm. The cytoplasm had

polysome clusters scattered throughout, a few rough endoplasmic reticula and large mitochondria around the nucleus. The nucleus had chromatin concentrating along the margin and a few nucleoli (Fig. 8).

*Immunofluorescent findings.* The tumor cells forming follicles in the spleen were stained with anti-IgG<sub>1</sub> antiserum and a few with anti-IgG<sub>a</sub> and -IgG<sub>b</sub> antisera. IgM-positive cells were distributed in the red pulp near the follicles (Figs. 9 and 10). Cytoplasmic IgG<sub>1</sub> was positive in 50% of spleen cells from S27-bearing mice (Fig. 11) and cytoplasmic IgG<sub>2a</sub>, IgG<sub>2b</sub> and IgM were positive only in 3% of each (Figs. 12 and 13). With membrane immunofluorescence, 2% of the spleen cells from S27-bearing mice were stained with anti-IgG<sub>1</sub> antiserum and a few spleen cells with anti-IgG<sub>2a</sub>, -IgG<sub>2b</sub> and IgM-antisera (Fig. 14).

#### DISCUSSION

There have been many reports stating that the tumors originated in the lymphoreticular tissue were frequently associated with autoimmune disease. The relationship between immune disorder and malignant lymphoma has been reported in man (11, 12) and experimental animals (1, 10, 13). Regarding immune abnormality in NZB, natural thymocyte autoantibody appears first in early postnatal months, suppressor T cells are then lost, and B lymphocytes start to proliferate, leading to B cell lymphoma (14). We have demonstrated the qualitative and quantitative changes of Ig, early involution of the thymus and morphological changes of lymphatic tissue relating to the ageing of NZB (10). We have also confirmed a frequent occurrence of B cell lymphoma in aged NZB (15). Therefore, an immune abnormality of NZB may result in S17-lymphoma.

Murine plasma cell leukemia involves the spleen, lymph nodes and other lymphoreticular tissues instead of forming localized tumors, and produces abnormal Ig. Tumor cells can be classified morphologically from Grades I to IV according to cell maturation (16). Grade I is the most differentiated plasma cell type. Grades II and III are plasmacytoid and lymphoid cell types, respectively. Grade IV corresponds to a differentiated reticular type, so-called reticulum cell sarcoma. S27-lymphoma has progressed to plasma cell leukemia as evidenced by its morphologic character, corresponding to Grades II to III.

Most of the plasma cell leukemia has been associated with abnormal Ig (16, -18). Rask-Nielsen *et al.* (18) reported that 45 of 95 BALB/c mice with plasma cell leukemia were associated with paraprotein of IgG<sub>1</sub> in 9%, IgG<sub>a</sub> in 55%, IgG<sub>b</sub> in 34% and IgM in zero. During serial transplantations, plasma cell leukemia tended to revert to reticulum cell sarcoma to lose the capacity to produce Ig. S27-plasma cell leukemia was associated with more than one class of Ig; its productivity was quiescent throughout transplantation. Since para-

protein produced and secreted by B cell lymphoma has antibody activity, the paraprotein of plasmacytoma in BALB/c mouse has been studied. Potter (19) reported that antigen-binding myeloma protein had antibody activity to some chemicals including nitrophenyl, 5-acetyluracil, phosphorylcholin, beta-1-6 linked galactose and beta-D-N-acetyl-glucosamine. The search for unknown antigen reactive to S27-plasma cell leukemia is now in progress.

Concerning the differentiation of B lymphocytes in mouse, the cell initially recognized was that bearing surface IgM and IgD. Thereafter, the first antigenic stimulation lead to the appearance of IgM antibody in the serum, and was followed by IgG antibody. Using indirect immunofluorescence, the tumor cells of S27-plasma cell leukemia possessed intracytoplasmic IgG, IgG<sub>a</sub> and IgG<sub>b</sub> antibodies. Membrane immunofluorescence showed the tumor cells which particularly bore IgG<sub>1</sub> on the surface.

The paramount finding of the present work is the establishment of transplantable murine plasma cell leukemia with more than one class of Ig; only two such tumors have previously been described (20, 21). Several possibilities can be considered to account for the presence of more than one Ig in this tumor; that is, each cell possesses each antibody independently, or one cell produces more than one antibody. In order to clarify this matter, we have made an effort using spleen colony assay (22). According to this study, no difference existed among the sera of the mice transplanted with spleen colonies. They manifested plasma cell leukemia with diffuse hypergamma-globulinemia which was analogous to that of S27-bearing NZB. The tumors have maintained the capacity to secrete polyclonal Ig through more than 20 transplant generations. This suggests that the products have originated from a single clone of plasma cells.

## REFERENCES

1. East, J.: Immunopathology and neoplasms in New Zealand mice and SJL/J mice. *Prog. Exp. Tumor Res.* **13**, 84-134, 1970.
2. Warner, N. L.: Auto-immunity and the pathogenesis of plasma cell tumor induction in NZB inbred and hybrid mice. *Immunogenetics* **2**, 1-20, 1975.
3. Canter, H., Asofsky, R. and Talal, N.: Synergy among lymphoid cells mediating the graft-versus-host response. I. Synergy in graft-versus-host reactions produced by cells from NZB/BI mice. *J. Exp. Med.* **131**, 223-234, 1970.
4. Gelfand, M. C. and Steinberg, A. D.: Mechanism of allograft rejection in New Zealand mice. I. Cell synergy and its age-dependent loss. *J. Immunol.* **110**, 1652-1662, 1973.
5. Howie, J. B. and Helyer, B. J.: The immunology and pathology of NZB mice. *Adv. Immunol.* **9**, 634-639, 1977.
6. Leventhal, B. G. and Talal, N.: Response of NZB and NZB×NZW spleen cells to mitogenic agents. *J. Immunol.* **104**, 918-923, 1970.
7. Yumoto, T., Ando, K., Okamoto, K., Okamoto, S., Yoshida, Y. and Inada, O.: Studies on immunoblastic lymphadenopathy in the New Zealand Black strain mice. *Acta Haematol.*



- Jpn.* **39**, 170-186, 1976 (in Japanese).
8. Yumoto, T. and Okamoto, S.: Transplantable lymphoma producing type K Bence-Jones protein in NZB mouse. *Acta Pathol. Jpn.* **27**, 359-373, 1977.
  9. Yumoto, T., Yoshida, H. and Okamoto, S.: Transplantable plasma cell leukemia with polyclonal gammopathy (short letter). *Igaku no Ayumi* **103**, 866-868, 1977 (in Japanese).
  10. Okamoto, S., Daimaru, O., Ando, K. and Yumoto, T.: Immunological and hematological studies of NZB mice—natural history (abstract). *Acta Haematol. Jpn.* **37**, 507, 1974 (in Japanese).
  11. Cummings, N. A.: Sjögren's syndrome—newer aspects of research, diagnosis and therapy. *Ann. Int. Med.* **75**, 937-950, 1971.
  12. Talal, N. and Bunim, J. J.: The development of malignant lymphoma in the course of Sjögren's syndrome. *Am. J. Med.* **36**, 529-540, 1964.
  13. Mellors, R. C.: Autoimmune and immunoproliferative disease of NZB/Bl mice and hybrids. *Int. Rev. Exp. Pathol.* **5**, 217-252, 1966.
  14. Shirai, J. and Mellors, R. C.: Natural thymocytotoxic autoantibody and reactive antigen in New Zealand Black and other mice. *Proc. Natl. Acad. Sci. USA.* **68**, 1421-1424, 1971.
  15. Yumoto, T., Okamoto, S., Ando, K., Inada, O., Okamoto, K. and Yoshida, Y.: Studies on the New Zealand Black mice. IV. Lymphocytes and immunoglobulin (abstract). *Acta Haematol. Jpn.* **39**, 469, 1976 (in Japanese).
  16. Rask-Nielsen, R. and Gormsen, H.: Spontaneous and induced plasma cell neoplasia in a strain of mice. *Cancer* **4**, 387-397, 1951.
  17. Clausen, J., Rask-Nielsen, R., Christensen, H. E., Lontic, R. and Heremans, J.: Macroglobulinemia in a transplantable mouse leukemia. *Proc. Soc. Exp. Biol. Med.* **103**, 802-804, 1960.
  18. Rask-Nielsen, R., Gormsen, H. and Clausen, J.: A transplantable plasma cell leukemia in mice associated with the production of paraprotein. *J. Natl. Cancer Inst.* **22**, 509-541, 1959.
  19. Potter, M.: Immunoglobulin-producing tumors and myeloma proteins of mice. *Physiol. Rev.* **52**, 631-719, 1972.
  20. Cohn, M.: Natural history of the myeloma. *Cold Spring Harbor Symp. Quant.* **32**, 211-221, 1967.
  21. Morse, H. C., III, Pumphrey, J. G., Potter, M. and Asofsky, R.: Murine plasma cells secreting more than one class of immunoglobulin heavy chain. I. Frequency of two or more M-components in ascitic fluid from 788 primary plasmacytomas. *J. Immunol.* **117**, 541-547, 1976.
  22. Yoshida, H., Ozaki, Y., Takeshige, M. and Yumoto, T.: The study of spleen colony assay of the cells from murine plasma cell leukemia. *Acta Haematol. Jpn.* (in press).

### Legends to Figures

- Fig. 1. Gross appearance of spontaneous hepatosplenomegaly in NZB mouse.
- Fig. 2. The spleen showing replacement of almost an entire follicle by neoplastic plasma cells. HE,  $\times 400$ .
- Fig. 3. The lymph node showing prominent proliferation of neoplastic plasma cells. HE,  $\times 400$ .
- Fig. 4. Agarose-agar electrophoresis and immunoelectrophoresis of serum from the original tumor-bearing mouse.
- Fig. 5. Gross appearance of transplantable S27-plasma cell leukemia-bearing mouse.
- Fig. 6. Agarose-agar electrophoresis and immunoelectrophoresis of serum from S27-plasma cell leukemia-bearing mouse.

Fig. 7. The spleen from S27-plasma cell leukemia-bearing mouse showing replacement of almost entire spleen by neoplastic plasma cells. HE,  $\times 400$ .

Fig. 8. Electron micrograph of the spleen involved by S27-plasma cell leukemia showing plasma cells and large lymphoid cells.  $\times 3,800$ .

Figs. 9-13. Indirect immunofluorescence (mouse anti-IgG antisera and FITC-conjugated goat anti-IgG). Spleen tissue reacting to anti-IgG<sub>1</sub> (Fig. 9) and anti-IgM (Fig. 10), and tumor cells reacting to anti-IgG<sub>1</sub> (Fig. 11), anti-IgG<sub>2a</sub> (Fig. 12) and anti-IgG<sub>2b</sub> (Fig. 13).

Fig. 14. Membrane fluorescence of tumor cells reacting to anti-IgG<sub>1</sub>.

