

Acta Medica Okayama

Volume 49, Issue 4

1995

Article 7

AUGUST 1995

Rotationplasty for patients with osteosarcoma around the knee joint.

Akira Kawai*

Masanori Hamada[†]

Shinsuke Sugihara[‡]

Hiroyuki Hashizume^{**}

Hiroaki Nagashima^{††}

Hajime Inoue^{‡‡}

*Okayama University,

[†]Okayama University,

[‡]Okayama University,

**Okayama University,

^{††}Okayama University,

^{‡‡}Okayama University,

Rotationplasty for patients with osteosarcoma around the knee joint.*

Akira Kawai, Masanori Hamada, Shinsuke Sugihara, Hiroyuki Hashizume,
Hiroaki Nagashima, and Hajime Inoue

Abstract

The results of rotationplasty for patients with osteosarcoma around the knee joint are presented. After an average observation period of 13.3 months, there has been no local recurrence or metastasis. The ankle joints (the new knee joints) of the patients were able to support their body weight with an average range of motion of 75 degrees. All patients could walk well without crutches and without risk of the giving way phenomenon. The average rate of the functional evaluation according to the re-modified system by Enneking was 84.5% (range, 80.0-86.7%). No patient had psychological trouble in accepting the shortened and rotated extremity. The results show that rotationplasty is a useful reconstructive method for the treatment of osteosarcoma around the knee joint.

KEYWORDS: rotationplasty, osteosarcoma, reconstructive new knee joint, function

*PMID: 7502683 [PubMed - indexed for MEDLINE]

Rotationplasty for Patients with Osteosarcoma around the Knee Joint

Akira KAWAI*, Masanori HAMADA, Shinsuke SUGIHARA, Hiroyuki HASHIZUME Hiroaki NAGASHIMA^a
and Hajime INOUE

Departments of Orthopaedic Surgery and Rehabilitation Medicine^a, Okayama University Medical School, Okayama 700, Japan

The results of rotationplasty for patients with osteosarcoma around the knee joint are presented. After an average observation period of 13.3 months, there has been no local recurrence or metastasis. The ankle joints (the new knee joints) of the patients were able to support their body weight with an average range of motion of 75°. All patients could walk well without crutches and without risk of the giving way phenomenon. The average rate of the functional evaluation according to the re-modified system by Enneking was 84.5% (range, 80.0-86.7%). No patient had psychological trouble in accepting the shortened and rotated extremity. The results show that rotationplasty is a useful reconstructive method for the treatment of osteosarcoma around the knee joint.

Key words: rotationplasty, osteosarcoma, reconstructive new knee joint, function

The prognosis for patients with osteosarcoma has improved markedly since the introduction of systemic chemotherapy in the last 2 decades (1). The 5-year overall survival rate for patients with osteosarcoma who received systemic chemotherapy in our institute is 61.5% compared with 28.2% for those without chemotherapy (2). Effective preoperative chemotherapy and establishment of a guideline for a safe surgical procedure for malignant bone tumors (3) have opened the way for limb salvage operations instead of ablative surgery for extremity osteosarcomas. However, it would be meaningless if the preserved limbs could not be put to practical use. This principle is particularly important for patients with tumors around the knee joint where osteosarcoma occurs most frequently. Knee rotationplasty, which was first developed by Borggreve (4) and by Van Nes (5) for a tuberculous or a congenital abnormally shortened lower

limb has several functional advantages. We report herein good functional and oncological results of rotationplasty for patients with osteosarcoma around the knee joint.

Patients and Methods

Patients. From June 1993 to August 1994, we performed knee rotationplasty in 3 cases of osteosarcoma around the knee joint (Table 1). They were all male with an average age at the time of operation of 15.3 years. The primary regions of the tumors were the proximal tibia in 2 and the distal femur in 1. The surgical stages according to Enneking's system were IIB in all cases (6). The follow-up period after the operation averaged 13.3 months. Before surgery, all patients and their families were well informed about the rotationplasty and saw a videotape which demonstrated the appearance and functional activities of patients who had had the operation and all consented to the surgical procedure.

Treatment. At the operation, the tumors and affected bone including the knee joints were resected together with a margin of at least 5 cm of unaffected tissue. In patient Nos. 1 and 2, owing to the close proximity of the vascular bundles to the tumor, we had to resect the vessels with the tumor and then end-to-end anastomose them to get an oncologically sufficient surgical margin (Fig. 1A, B). After resection of the tumor was completed, all structures of the affected limb were discontinuous except the sciatic nerve (patient Nos. 1 and 2) or the sciatic nerve and vascular bundles (patient No. 3) (Fig. 1C). The leg was then externally rotated 180° and the femur and the tibia were joined with a plate and screws (Fig. 1D). The ankle joint was placed at the same level as the opposite knee joint to function as a new "knee joint". In patient No. 2, who was still growing at the time of treatment, the predicted amount of growth was taken into

* To whom correspondence should be addressed.

Table 1 Patients' characteristics

Patient	Age	Sex	Location	Histologic subtype	Size (cm)	Stage	Histologic effect Necrosis (%)	Follow-up (months)
No. 1	19	M	Femur, distal	Fibroblastic	13	IIB	95	22
No. 2	10	M	Tibia, proximal	Osteoblastic	7	IIB	100	10
No. 3	17	M	Tibia, proximal	Osteoblastic	12	IIB	60	8

Table 2 Treatment results

Patient	ROM	Function		Status	Complication
		Knahr <i>et al.</i> (7)	Enneking (8)		
No. 1	90°	Excellent	86.7%	CDF	
No. 2	75°	Excellent	86.7%	CDF	Lymphedema
No. 3	60°	Good	80.0%	CDF	

ROM: Range of motion; CDF: Continuously disease free

consideration so that the level of the joints would be the same when his growing stops. The quadriceps muscles and the calf muscles, and the biceps muscles and the tibialis anterior muscle were sutured respectively. After the operation, a plaster cast was applied in a plantar flexion position of the ankle joint for a few weeks. Postoperative exercises of the ankle joints were started immediately after the wound healed.

Functional evaluation. Function was evaluated according to the modified knee evaluation system of Knahr *et al.* (7) and the re-modified system of Enneking which consisted of 6 examination criteria: pain, function, emotional acceptance, external supports, walking ability, and gait (8).

Results

Postoperative evaluation of the surgical margins was "curative" in all patients (3). No marked wound complication was observed except in 1 patient (No. 2) who had transient lymphedema of the leg after anastomosis of the popliteal vessels and tibialis anterior and posterior vessels (Table 2). The prosthetic training began an average of 8 weeks after the operation. Fourteen weeks after the operation, all patients could stand on the reconstructed limb with full weight bearing. At the time of the last

follow-up, all the patients could walk well without crutches and without risk of the giving way phenomenon (Fig. 2). They did not have pain or any phantom sensations in their affected limb. The ankle joints (the new knee joints) were able to support their body with an average range of motion of 75° (range, 60–90°). Manual muscle testing showed that both the flexion and extension powers of the ankles scored 4 to 5 in all patients (9). Functional evaluations according to the system of Knahr *et al.* (7) were excellent in 2 and good in 1. The average score according to the re-modified functional evaluation system by Enneking (8) was 84.5% (range, 80.0–86.7%). No patient has experienced psychological trouble in accepting the drastically shortened and rotated extremity. Oncological examinations showed that all the patients were free from local recurrence and metastasis.

Discussion

In 1975, Kristen *et al.* first reported rotationplasty as a method of reconstruction after resection of an osteosarcoma of the distal femur (10). For a long period, however, the procedure was not accepted as an alternative reconstructive method for malignant bone tumors, mainly because of the grotesque appearance of the foot turned 180° at the knee joint.

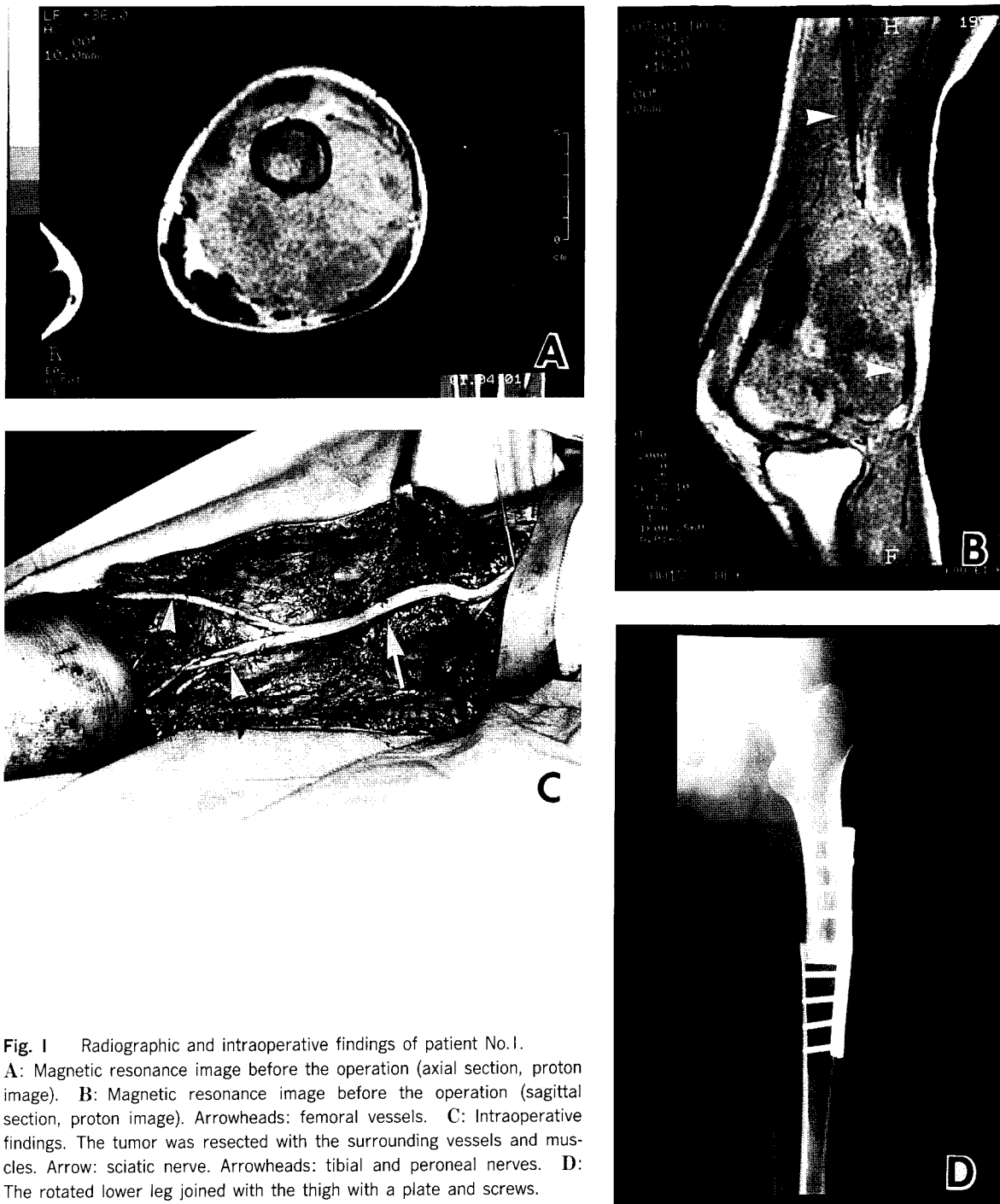


Fig. 1 Radiographic and intraoperative findings of patient No. 1. **A:** Magnetic resonance image before the operation (axial section, proton image). **B:** Magnetic resonance image before the operation (sagittal section, proton image). Arrowheads: femoral vessels. **C:** Intraoperative findings. The tumor was resected with the surrounding vessels and muscles. Arrow: sciatic nerve. Arrowheads: tibial and peroneal nerves. **D:** The rotated lower leg joined with the thigh with a plate and screws.

With regard to osteosarcoma around the knee joint, there are four options in the surgical treatment: above-

knee amputation, wide resection and reconstruction with an endoprosthesis or an allograft, resection arthrodesis,

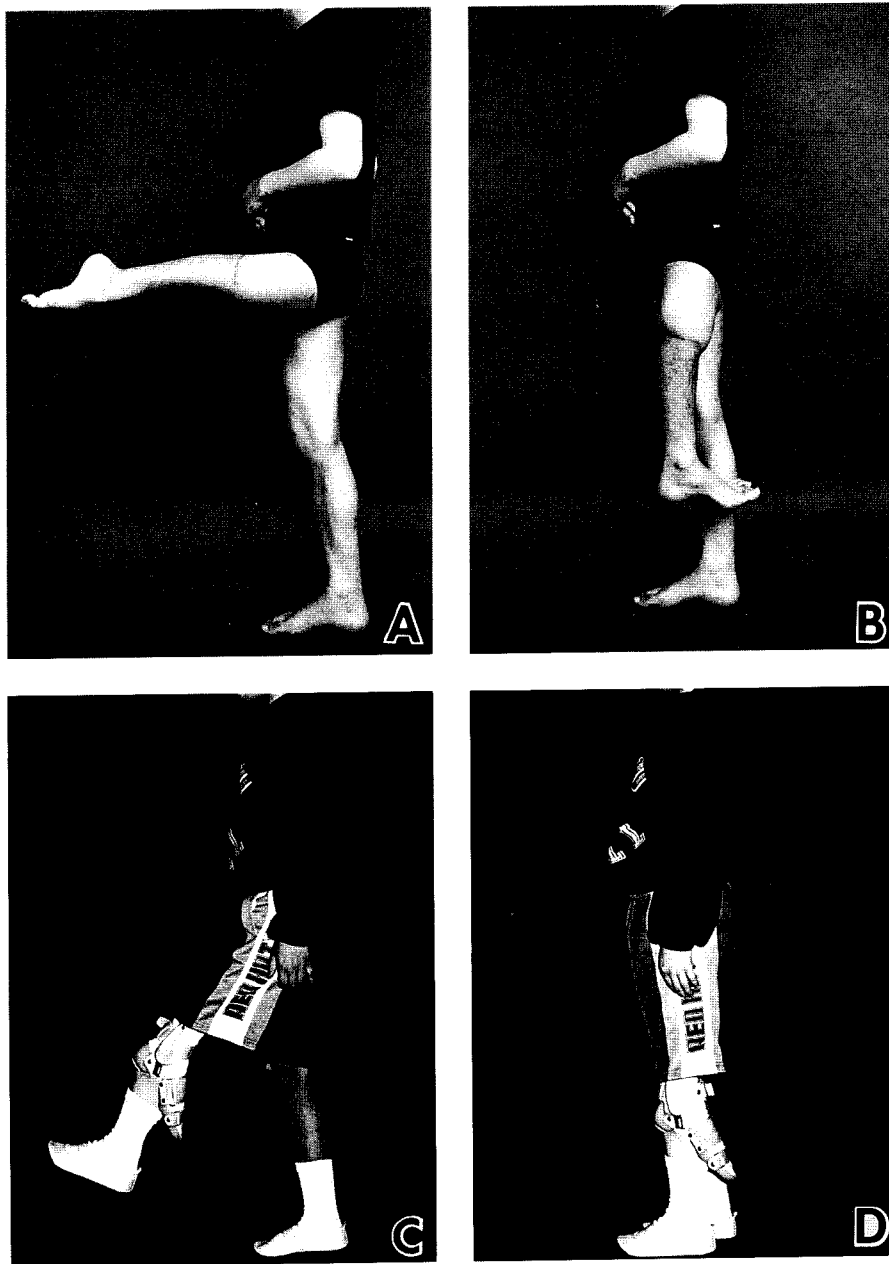


Fig. 2 Postoperative photographs of patients. A, B: Without the prosthesis (patient No. 1) C, D: With the prosthesis (patient No. 2).

and rotationplasty. The incidence of ablative surgery such as above-knee amputation in the treatment of osteosarcoma has decreased with introduction of effective preoperative chemotherapy and the concept of a surgical margin (3). Implantation of an endoprosthesis offers immediate post-

operative stability and active knee motion. However, there is a probability of late complications such as infection, loosening, and breakage of the implant (11, 12). We should consider the endoprosthesis as a temporary spacer, especially for young patients. Implantation of an allograft

has given satisfactory mid-or long-term results in spite of its several shortcomings such as nonunion and/or infection (13). However, it is difficult to obtain a massive allograft that fits with the bone defect, especially in Japan where there is no public bone banking system. Moreover, allografts have problems which are common with organ transplantation, such as immune reactions and risk of viral infection. Resection arthrodesis offers a permanent and stable extremity after incorporation of the grafted bone (14). Nevertheless, there is a significant incidence of emotional dislike and problems in daily life in relation to the stiff knee.

A functional advantage of rotationplasty originates from the ability of the ankle joint to fulfill the function of the original knee joint (15, 16). Patients with knee rotationplasty are expected to have almost the same functions as those who underwent below knee amputations. All patients reported in this paper could walk well without crutches and without risk of the giving way phenomenon. McClenaghan *et al.* reported lower energy cost and higher free-walking speed of patients after rotationplasty compared with those after above knee amputation (17).

From the viewpoint of surgical oncology, rotationplasty is considered a safer procedure than reconstruction with an endoprosthesis. In rotationplasty, it is possible to resect the tumor and surrounding tissues *en bloc*. However, in endoprosthetic replacement surgery, it is necessary to preserve surrounding muscles, soft tissues and skin. Limb salvage surgery except for rotationplasty could not be performed for patients with tumors invading the surrounding tissues as extensively as in patient No. 1. Moreover, rotationplasty can be performed for children who are growing at the time of surgery (such as patient No. 2), for whom reconstruction with an endoprosthesis is not indicated.

Inoue *et al.* stated that rotationplasty is useful as a salvage operation for patients who had some trouble in the preserved limbs: loosening and breakage of the endoprosthesis, infection, or local recurrences (18). However the procedure has not been accepted throughout Japan yet.

Based on our results, we recommend rotationplasty as a valuable therapeutic alternative for treatment of malignant bone tumors around the knee joint, especially for young male patients with active daily living or those who are expected to grow in height after the operation.

Acknowledgments. The authors wish to thank Dr. H. Uchida and Professor S. Sano for angioplastic surgery, and Mr. H. Tsukiyama, RPT and Miss M. Taniwaki, OTR for their cooperation.

References

1. Eilber FR and Rosen G: Adjuvant chemotherapy for osteosarcoma. *Semin Oncol* (1989) **16**, 312-323.
2. Kawai A, Yamane T, Ozaki T, Ito S and Tanabe G: Treatment and results of patients with osteosarcoma, a study of cases in these 25 years. *Cent Jpn J Orthop Surg Traumat* (1990) **33**, 1285-1287 (in Japanese).
3. The JOA Musculo-skeletal Tumor Committee: Evaluation Method of Surgical Margin for Musculo-Skeletal Sarcoma, Kanehara Press, Tokyo (1989) pp 3-19.
4. Borggreve: Kniegelenksersatz durch das in der Beinlängsachse um 180° gedrehte Fussgelenk. *Arch Orthop Unfall-Chir* (1930) **28**, 175-178.
5. Van Nes CP: Rotation-plasty for congenital defects of the femur: Making use of the ankle of the shortened limb to control the knee joint of a prosthesis. *J Bone Jt Surg Br Vol* (1950) **32**, 12-16.
6. Enneking WF: A system of staging musculoskeletal neoplasms. *Clin Orthop* (1986) **204**, 9-24.
7. Knahr K, Sekera J and Salzer M: Functional results of rotationplasty, analysis and commentary of the Enneking evaluation system: in *New Developments for Limb Salvage in Musculoskeletal Tumors*, Yamamura T ed, Springer-Verlag, Tokyo (1989) pp 31-35.
8. Enneking WF: Modification of the system for functional evaluation of surgical management of musculoskeletal tumors; in *Limb Salvage in Musculoskeletal Oncology*, Enneking WF ed, Churchill Livingstone, Ltd., Edinburgh (1987) pp626-639.
9. Daniels L and Worthingham C: *Muscle Testing*, 5th Ed. WB Saunders, Philadelphia (1986) pp 42-98.
10. Kristen H, Knahr K and Salzer M: Atypische amputationsformen bei knochentumoren der unteren extremität. *Arch Orthop Unfall-Chir* (1975) **83**, 91-107.
11. Capanna R, Leonessa C, Bettelli G, Borghi B, De Cristofaro R, Martelli C, Ruggieri P and Campanacci M: Modular Kotz prosthesis, the Rizzoli experience; in *New Developments for Limb Salvage in Musculoskeletal Tumors*, Yamamura T ed, Springer-Verlag, Tokyo (1989) pp37-44.
12. Capanna R, Morris H, Campanacci D, Del Ben M, Gasbarrini A and Campanacci M: Endoprosthetic reconstruction of the distal femur after resection for bone tumours; in *Limb Salvage, Current Trends*. Pho RWH ed, Proceedings of the 7th International Symposium, Singapore (1993) pp321-324.
13. Mankin HJ, Doppelt SH, Sullivan TR and Tomford WW: Osteoarticular and intercalary allograft transplantation in the management of malignant tumors of bone. *Cancer* (1982) **50**, 613-630.
14. Enneking WF, Springfield DS and Present DA: Functional evaluation of resection-arthrodesis for lesions about the knee; in *Limb Salvage in Musculoskeletal Oncology*, Enneking WF ed, Churchill Livingstone, Ltd., Edinburgh (1987) pp389-391.
15. Kotz R and Salzer M: Rotation-plasty for childhood osteosarcoma of the distal part of the femur. *J Bone Jt Surg Am Vol* (1982) **64**, 959-969.
16. Knahr K, Kotz R, Kristen H, Ramach W, Salzer-Kuntschik M, Salzer M and Sekera J: Clinical evaluation of patients with rotationplasty; in *Limb Salvage in Musculoskeletal Oncology*, Enneking WF ed, Churchill Livingstone, Ltd., Edinburgh (1987) pp 429-434.
17. McClenaghan BA, Krajchich JI, Pirone AM, Koheil R and Longmuir P:

Comparative assessment of gait after limb-salvage procedures. *J Bone Jt Surg Am Vol* (1989) **71**, 1178-1182.

18. Inoue O, Shimabukuro H, Arakaki N and Ibaraki K: Experience of knee and hip rotationplasties. *J Jpn Orthop Assoc* (1992) **66**, s977 (in Japanese).

Received April 7, 1995; accepted May 31, 1995.