

Acta Medica Okayama

Volume 50, Issue 6

1996

Article 8

DECEMBER 1996

Cathepsin B in the Growth of Colorectal Cancer: Increased Activity of Cathepsin B in Human Colorectal Cancer

Yasumasa Satoh, *Okayama University*
Toshihiro Higashi, *Okayama University*
Kazuhiro Nouse, *Okayama University*
Tetsuya Shiota, *Okayama University*
Nobuyuki Kinugasa, *Okayama University*
Keigo Yoshida, *Okayama University*
Shuji Uematsu, *Okayama University*
Harushige Nakatsukasa, *Okayama University*
Yukio Nishimura, *Kyushu University*
Takao Tsuji, *Okayama University*

Cathepsin B in the Growth of Colorectal Cancer: Increased Activity of Cathepsin B in Human Colorectal Cancer*

Yasumasa Satoh, Toshihiro Higashi, Kazuhiro Nouse, Tetsuya Shiota, Nobuyuki Kinugasa, Keigo Yoshida, Shuji Uematsu, Harushige Nakatsukasa, Yukio Nishimura, and Takao Tsuji

Abstract

Cathepsin B, a thiol protease, is involved in cancer metastasis. To clarify the role of cathepsin B in tumor progression in human colorectal cancer, the relationship between its activity, immunohistochemical staining, and clinical tumor progression was investigated. Cathepsin B activity in adenocarcinomas was significantly elevated compared with that in the tumor-bearing tissue. Furthermore, the tumor/tumor-bearing tissue (T/Tb) ratio of the activity was significantly higher than that of colorectal adenoma. Immunohistochemical studies demonstrated intense staining in the cancerous tissue. With respect to the clinical stage of tumors, the activity tended to be higher in tumors that had invaded the serosa or subserosa than in those that invaded the proper muscle. The results suggest that cathepsin B participates in the progression of human colorectal cancer, and its increased expression is a sensitive marker of the differentiation between colorectal adenoma and adenocarcinoma.

KEYWORDS: cathepsin B, colorectal cancer, colorectal adenoma

*PMID: 8985467 [PubMed - indexed for MEDLINE]

Copyright (C) OKAYAMA UNIVERSITY MEDICAL SCHOOL

Cathepsin B in the Growth of Colorectal Cancer: Increased Activity of Cathepsin B in Human Colorectal Cancer

Yasumasa SATOH, Toshihiro HIGASHI*, Kazuhiro NOUSO, Tetsuya SHIOTA, Nobuyuki KINUGASA, Keigo YOSHIDA, Shuji UEMATSU, Harushige NAKATSUKASA, Yukio NISHIMURA^a and Takao TSUJI

First Department of Internal Medicine, Okayama University Medical School, Okayama 700 and ^aDepartment of Physiology, Faculty of Pharmaceutical Science, Kyushu University, Fukuoka 812, Japan

Cathepsin B, a thiol protease, is involved in cancer metastasis. To clarify the role of cathepsin B in tumor progression in human colorectal cancer, the relationship between its activity, immunohistochemical staining, and clinical tumor progression was investigated. Cathepsin B activity in adenocarcinomas was significantly elevated compared with that in the tumor-bearing tissue. Furthermore, the tumor/tumor-bearing tissue (T/Tb) ratio of the activity was significantly higher than that of colorectal adenoma. Immunohistochemical studies demonstrated intense staining in the cancerous tissue. With respect to the clinical stage of tumors, the activity tended to be higher in tumors that had invaded the serosa or subserosa than in those that invaded the proper muscle. The results suggest that cathepsin B participates in the progression of human colorectal cancer, and its increased expression is a sensitive marker of the differentiation between colorectal adenoma and adenocarcinoma.

Key words: cathepsin B, colorectal cancer, colorectal adenoma

The thiol protease cathepsin B, a lysosomal enzyme, degrades components of the extracellular matrix, including fibronectin, proteoglycans, elastin, and type IV collagen (1-4). Over the past few decades, a considerable number of studies have addressed the role of cathepsin B in tumor growth and metastasis (5-7). Abnormal expression of cathepsin B mRNA has been reported in human colorectal (8), bladder (9), and lung cancer (10), as well as murine hepatoma and melanoma (11). A positive

correlation with metastatic potential has also been shown in murine melanoma variants (12). Subcellular fractionation and immunohistochemical studies have also demonstrated changes in the cellular localization of cathepsin B, showing it to be enriched in plasma membrane-associated lysosomes in malignant cells (13-15). Furthermore, the release of cathepsin B in a latent 40kDa form has been reported in human breast (16), colorectal (17) and hepatocellular carcinoma cells (18) in culture systems. These lines of evidence indicate that cathepsin B plays an important role in invasiveness and metastasis at the malignant tumor front.

We have reported cathepsin B activity in human gastric cancer in relation to pathological findings; the level of activity was higher in poorly differentiated adenocarcinoma specimens which invaded deeply into surrounding tissue, and in extensively metastasized regional lymph nodes (19, 20). In human colorectal cancer, the relationship between cathepsin B activity and clinical stage of tumors has also been addressed, with conflicting results. Sheahan *et al.* (21) demonstrated an increase in cathepsin B activity in patients classified according to Duke's classification as A and B, and a decrease in patients classified as C and D. However, studies by Shuja *et al.* (22) and by Campo *et al.* (23), in contrast, showed a positive correlation of cathepsin B expression with tumor progression and a negative correlation with patient survival. Further, only a few studies have examined cathepsin B activity in colon adenomas (17, 22, 23), though an adenoma-cancer sequence has been proposed in the development of human colorectal cancer (24). In the present study, therefore, we investigated the enzymatic activity and immunohistochemical staining of cathepsin B in

*To whom correspondence should be addressed.

human colorectal adenoma and adenocarcinoma to clarify its role in the development and progression of colorectal cancer.

Materials and Methods

Materials. We obtained 15 surgically resected adenocarcinoma specimens, 8 endoscopically polypectomized adenoma tissues, and their respective normal tissues which were sampled at least 5 cm away from the lesions. All specimens were histologically examined to confirm the prior diagnosis. Most of the resected colon cancers were in an advanced stage; 3 were in stage I, 6 in stage II and 6 in stage III-IV according to the TNM classification (25). Macroscopic classification outlined by the Japanese Society for Cancer of the Colon and Rectum (26) revealed types 1, 2 and 3 of the classification were 2, 6, and 7 of the specimens, respectively. Histological studies showed that 12 of the cases were well differentiated and 3 were moderately differentiated adenocarcinoma, and that the depth of vertical invasion extended to the proper muscle (pm) in 3 patients and to the subserosa (ss) or serosa (s) in 12 patients (Table 1).

Cathepsin B assay. Leupeptin and benzoyloxycarbonyl-arginyl-arginyl-4-methylcoumaryl-7-amide (Z-Arg-Arg-NMec) were supplied by the Peptide Institute, Inc. (Osaka, Japan). Cathepsin B activity was measured as previously described (19, 27). Briefly, the

colonic mucosal membrane was removed on dry ice, homogenized with 1 ml of saline and diluted to serve as sample tissue. Z-Arg-Arg-NMec was used as the substrate, and the fluorescence intensity of the generated aminomethylcoumarin was measured by Spectrofluorometer at λ_{ex} 340 nm and λ_{em} 433 nm. Concentrations of protein in each sample were determined by the Lowry method (28), and the activity was expressed in mV/mg protein in which 0.05 M aminomethylcoumarin was used as the internal standard of measurement. We calculated the T/Tb ratio of the activity to evaluate the significance of cathepsin B, since the level of cathepsin B may be affected by various factors, including aging and nutritional condition.

Immunohistochemical study. Rabbit serum anti-rat cathepsin B (29, 30) was used in immunohistochemical staining of cathepsin B. Formalin-fixed paraffin-embedded sections were deparaffinized, washed with phosphate buffered saline (PBS), treated with 3% hydrogen peroxide for 30 min, and further treated with 10% normal goat serum. The sections were then incubated with the anti-sera ($\times 100$) overnight. Avidin-biotin complex was used for staining.

Statistical analyses. The significance of differences was determined by Paired *t*-test and Welch test. Probability values less than 5% were considered significant.

Table 1 Human colon cancer subjects

Cases	Age	Sex	Size (mm)	Portion	Macroscopy	Histology	TNM	T	N	M	V.I.
1)	64	F	47×47	T	3	Mod	II	3	0	0	—
2)	56	F	40×20	R	2	Wel	I	2	0	0	—
3)	78	M	65×50	S	3	Wel	II	3	0	0	+
4)	73	M	40×40	S	1	Wel	I	2	0	0	—
5)	64	F	45×35	R	2	Wel	I	2	0	0	+
6)	75	M	60×50	A	3	Wel	III	3	1	0	+
7)	81	M	110×68	A	3	Wel	III	3	1	0	+
8)	62	M	40×35	S	3	Wel	IV	3	2	1	+
9)	70	F	40×30	R	3	Wel	II	3	0	0	+
10)	66	M	70×60	S	1	Wel	III	3	1	0	+
11)	74	M	55×45	T	2	Wel	II	3	0	0	n.d.
12)	61	M	27×25	S	3	Mod	III	3	1	0	+
13)	59	M	44×35	S	2	Wel	II	3	0	0	+
14)	71	M	50×25	S	3	Wel	III	3	1	0	+
15)	84	F	75×45	A	2	Mod	II	3	0	0	n.d.

A: Ascending colon; T: Transverse colon; S: Sigmoid colon; R: Rectum; TNM: TNM classification of colorectal cancer; Macroscopy: Macroscopic classification; Wel: Well differentiated adenocarcinoma; Mod: Moderately differentiated adenocarcinoma; V.I.: Vascular invasion; n.d.: not determined.

Results

The cathepsin B activities of the tumor-bearing tissue (Tb) were not different among the various regions examined; *i. e.*, the ascending, transverse, and sigmoid colon, and the rectum. The average of the activity in the cancerous portion (T) (252.9 ± 153.9 , mean \pm SD) was significantly higher than that in the tumor bearing tissue (Tb) (125.9 ± 72.2 , $P = 0.001$, paired *t*-test). In 13 of the 15 cases, the activity in T was greater than that in the respective Tb (Fig. 1). The T/Tb ratio in the adenocarcinomas (2.7 ± 3.0 , mean \pm SD) was significantly higher than that in the adenomas (0.8 ± 0.4) ($P = 0.024$, Welch test), and a T/Tb ratio slightly higher than 1.0 was observed in only 3 of 8 adenomas (Fig. 2).

Immunohistochemical studies of cathepsin B demonstrated intense staining in the cytoplasm of the adenocarcinoma cells, and not in the adjacent normal mucosal cells (Fig. 3). The clump of tumor cells invading the submucosal tissue exhibited intense staining, and a positive reaction was also obtained in the macrophage-like cells in the area surrounding the tumor clump (Fig. 4).

With respect to cancer progression, we investigated the relationship between the T/Tb ratio and the stage of the disease, the depth of vertical invasion and the vascular invasion of the colon cancer. The T/Tb ratio tended to be higher, but not significantly, in tumors that had invaded

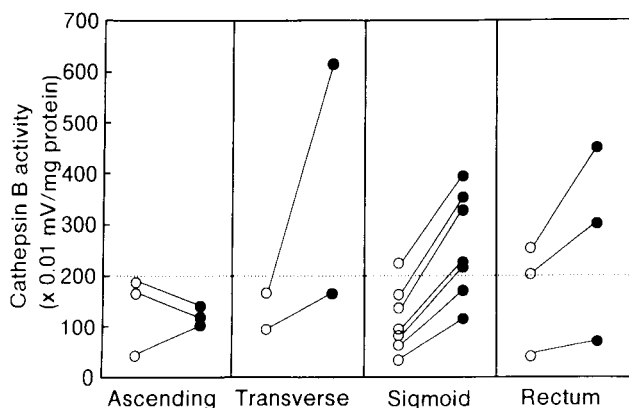


Fig. 1 Cathepsin B activity of tumor-bearing and adenocarcinoma tissues in various portions of the colon. The average of the activity in adenocarcinomas (T, ●) (252.9 ± 153.9 , mean \pm SD) was significantly higher than that in the tumor-bearing tissues (Tb, ○) (125.9 ± 72.2 , $P = 0.0005$, paired *t*-test), and in 13 of 15 cases, the activity in T was greater than that of the respective Tb.

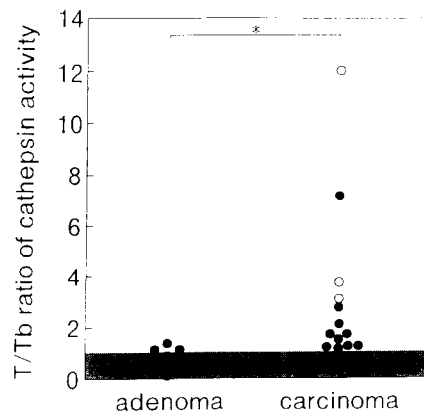


Fig. 2 T/Tb ratios of cathepsin B in adenoma and adenocarcinoma of the human colon. The ratio was significantly higher in the adenocarcinoma (2.7 ± 3.0 , mean \pm SD) than in adenoma (0.8 ± 0.4) ($P = 0.024$, Welch test). Well differentiated (●) and moderately differentiated adenocarcinoma (○).

to the serosa or subserosa (3.2 ± 3.3 , mean \pm SD) than in those that had invaded to the proper muscle (1.6 ± 0.2) ($P = 0.070$, Welch test). However, no correlation was observed between the T/Tb ratio and the disease stage of TNM classification or vascular invasion. Although macroscopic classification of the colon cancer is not related with tumor progression, the T/Tb ratio tended to be higher, but not significantly, in type 2 and 3 patients (3.2 ± 3.2 , mean \pm SD) than that in type 1 patients (1.4 ± 0.2) ($P = 0.116$, Welch test). Furthermore, the ratio in moderately differentiated adenocarcinoma of 3 patients was particularly high. These patients were in advanced stage with regard to TNM classification and vertical invasion (Fig. 5).

Discussion

Cathepsin B activity in normal mucosa did not differ in the various regions of the human colon. Although immunohistochemical techniques allow only a gross estimation of the relative levels of the cathepsin B protein, the finding that the intense staining of cathepsin B accompanied by the elevated activity was recognized in the cancerous portions alone strongly indicates the involvement of cathepsin B in the progression of colorectal cancer.

The activity tended to be higher in tumors that had invaded to the serosa or subserosa. The results were

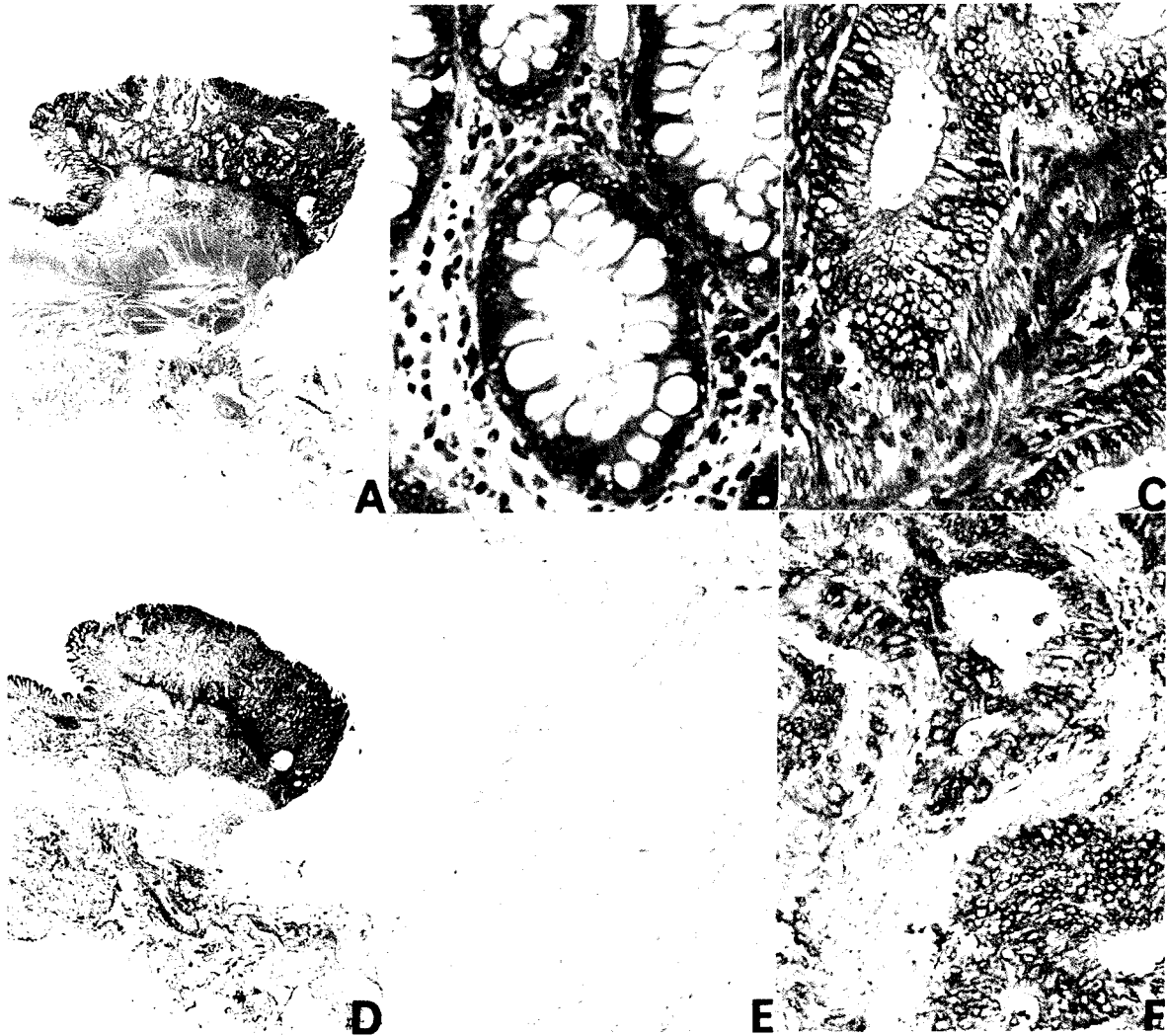


Fig. 3 Immunohistochemical examination of cathepsin B in human colon cancer. Intense staining was observed in the adenocarcinoma portion (C & F) compared to the adjacent normal mucosa (B & E). A & D: Microscopic pictures of the resected colonic cancer; A, B, C: hematoxylin-eosin staining; D, E, F: Immunohistochemical staining.

similar to those which we observed in human gastric cancer (19, 20). Cathepsin B activity was correlated with neither the TNM stage of cancer nor with the presence of vascular invasion, findings similar to those reported by Shuja, who found that the activity was inversely correlated with Duke's stage (22). These results suggest that cathepsin B may play a more significant role in local tumor invasion than in distant metastasis.

The activity in moderately differentiated adenocarcinoma of 3 patients, who were in advanced stage of TNM classification and vertical invasion, was higher than that in well differentiated adenocarcinoma. Although this

result is interesting because the moderately differentiated adenocarcinoma seems to progress more rapidly, the sample number was too small to draw any conclusions. The relationship between morphological features and the activity of cathepsin B must be investigated in future studies.

Concerning cathepsin B activity in human pre-malignant colorectal tumors, a study by Maciewicz *et al.* (17) showed that both pre-malignant and adenocarcinoma-derived colon cell lines secrete a cathepsin B precursor, while the mature form is secreted only by the carcinoma-derived cell line. These investigators concluded that the

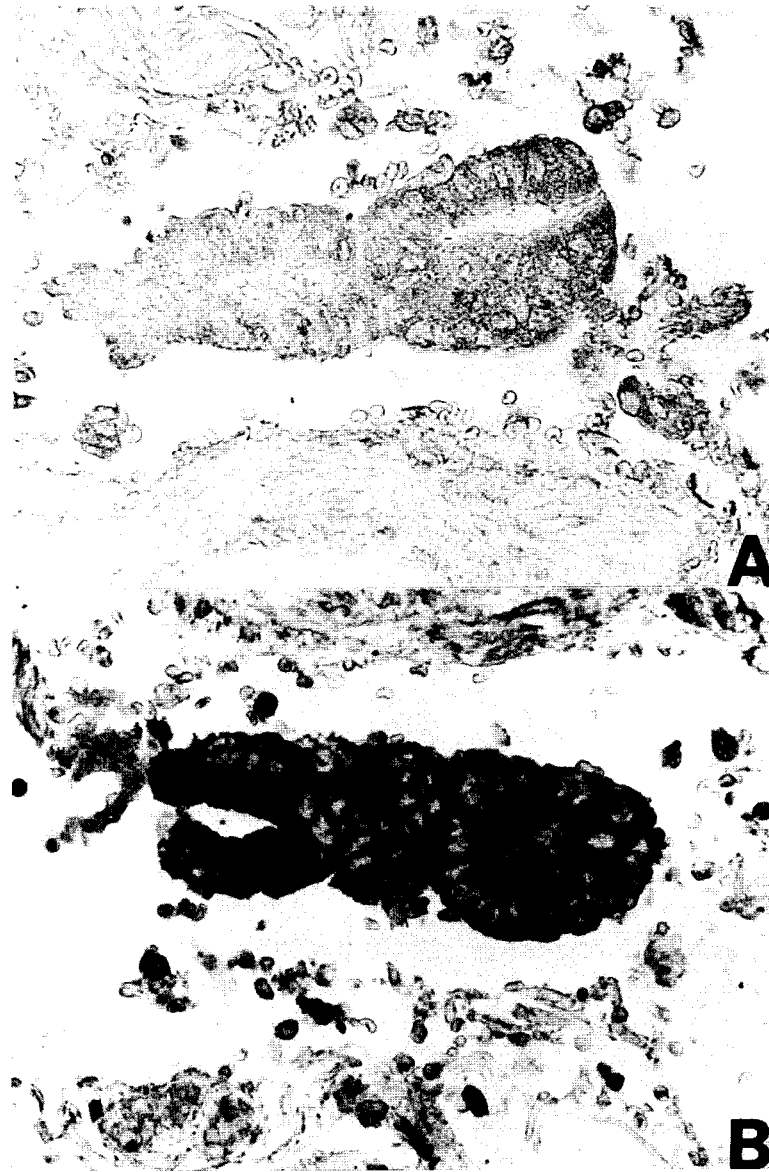

Fig. 4 Immunohistochemical staining of cathepsin B in tumor cells invading the submucosal tissue. Positive reactions were obtained on tumor cell clumps and on macrophage-like cells in the area surrounding tumors ($\times 120$). Normal rat serum (A) and rabbit anti-rat cathepsin B antiserum (B) were used as the first antibody.

invasive potential of a tumor may be related to its capacity to process extracellularly-secreted precursor into a mature form rather than to the amount of cathepsin B synthesized and/or secreted. Shuja *et al.* (22) and Campo *et al.* (23) reported, however, that adenomas from colorectal cancer patients had normal levels of cathepsin B activity, and they concluded that the increase in cathepsin B expression was a sensitive marker for progression from the pre-malignant to the malignant state in the development of

colorectal cancer. Although in the present study we did not determine which form of cathepsin B was secreted by the adenocarcinomas and adenomas, the significantly higher cathepsin B activity in the adenocarcinomas than in the adenomas support the latter two studies hypothesis.

In conclusion, our findings in human colorectal adenoma and adenocarcinoma indicate that cathepsin B is a sensitive marker of colon cancer, and participates in its progression.

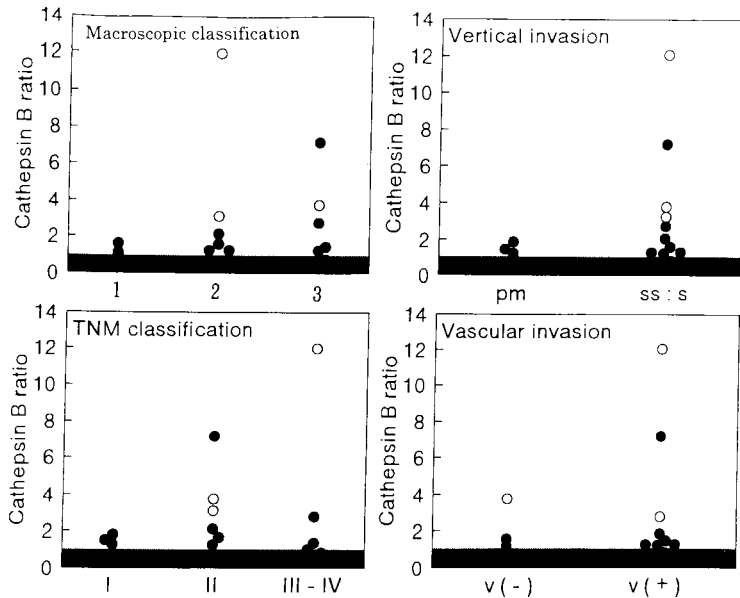


Fig. 5 T/Tb ratios of cathepsin B activity in tumor progression and macroscopic classification of the colon cancer. The ratio tended to be higher in tumors that had invaded to the serosa or subserosa than in those that had invaded to the proper muscle ($P = 0.070$, Welch test), as well as being greater in the macroscopic type 2 and 3 patients than in type 1 patients ($P = 0.116$, Welch test). The ratio correlated with neither the disease stage of TNM classification nor with vascular invasion. Well differentiated (●) and moderately differentiated adenocarcinoma (○). T, Tb: See Fig. 1.

Acknowledgment. We are grateful to Miss Ryoko Mitani for her skillful preparation of tissue sections for immunohistochemical and hematoxylin-eosin staining.

References

- Burleigh MC, Barrett AJ and Lazarus GS: Cathepsin B1: A lysosomal enzyme that degrades native collagen. *Biochem J* (1974) **137**, 387-398.
- Etherington DJ and Evans PJ: The action of cathepsin B and collagenolytic cathepsin in the degradation of collagen. *Acta Biol Med Germ* (1977) **36**, 1555-1563.
- Guy Morrison RI, Barrett AJ, Dingle JT and Prior D: Cathepsin B1 and D action on human cartilage proteoglycan. *Biochim Biophys Acta* (1973) **302**, 411-419.
- Mason RW, Johnson DA, Barrett AJ and Chapman HA: Elastinolytic activity of human cathepsin L. *Biochem J* (1986) **233**, 925-927.
- Sloane BF, Dunn JR and Honn KV: Lysosomal cathepsin B: Correlation with metastatic potential. *Science* (1981) **212**, 1151-1153.
- Sloane BF, Moin K, Krepela E and Rozhin J: Cathepsin B and its endogenous inhibitors: The role in tumor malignancy. *Cancer Metastasis Rev* (1990) **9**, 333-352.
- Rempel SA, Mikkelsen RML, Yan P-S, Ellis KD, Golembieski WA, Sameni M, Rozhin J, Ziegler G and Sloane BF: Cathepsin B expression and localization in glioma progression and invasion. *Cancer Res* (1994) **54**, 6027-6031.
- Murnane MJ, Sheahan K, Ozdemir M and Shuja S: Stage-specific increases in cathepsin B messenger RNA content in human colorectal carcinoma. *Cancer Res* (1991) **51**, 1137-1142.
- Weiss RE, Liu BCS, Ahlering T, Dubeau L and Droller MJ: Mechanisms of human bladder tumor invasion: Role of proteases cathepsin B. *J Urol* (1990) **144**, 798-804.
- Inoue T, Sugio K and Sugimachi K: Cathepsin B expression and laminin degradation as factors influencing prognosis of surgically treated patients with lung adenocarcinoma. *Cancer Res* (1994) **54**, 6133-6136.
- Moin K, Rozhin J, McKernan TB, Sanders VJ, Fong D, Honn KV and Sloane BF: Enhanced levels of cathepsin B mRNA in murine tumors. *FEBS Lett* (1989) **244**, 61-64.
- Qian F, Bajkowski AS, Steiner DF, Chan SJ and Frankfater A: Expression of five cathepsins in murine melanomas of varying metastatic potential and normal tissues. *Cancer Res* (1989) **49**, 4870-4875.
- Pietras RJ and Roberts JA: Cathepsin B-like enzymes. *J Biol Chem* (1981) **256**, 8536-8544.
- Pietras RJ, Szego CM, Roberts JA and Seeler BJ: Lysosomal cathepsin B-like activity: Mobilization in prereplicative and neoplastic epithelial cells. *J Histochem Cytochem* (1981) **29**, 440-450.
- Sloane BF, Rozhin J, Hatfield JS, Crissman JD and Honn KV: Plasma membrane-associated cysteine proteases in human and animal tumors. *Exp Cell Biol* (1987) **55**, 209-224.
- Mort JS and Recklies AD: Interrelationship of active and latent secreted human cathepsin B precursors. *Biochem J* (1986) **233**, 57-63.
- Maciewicz RA, Wardale RJ, Etherington DJ and Paraskeva C: Immunodetection of cathepsin B and L present in and secreted from human pre-malignant and malignant colorectal tumour cell lines. *Int J Cancer* (1989) **43**, 478-486.
- Ohsawa T, Higashi T and Tsuji T: The secretion of high molecular weight cathepsin B from cultured human liver cancer. *Acta Med Okayama* (1989) **43**, 9-15.
- Watanabe N, Higashi T, Hashimoto M, Tomoda I, Tominaga S, Hashimoto N, Morimoto S, Yamauchi Y, Nakatsukasa H, Kobayashi M, Watanaba A and Nagashima H: Elevation of tissue cathepsin B and L activities in gastric cancer. *Hepato-Gastroenterology* (1987) **34**, 120-122.
- Watanabe M, Higashi T, Watanabe A, Osawa T, Sato Y, Kimura Y, Tominaga S, Hashimoto N, Yoshida Y, Morimoto S, Shiota T, Hashimoto M, Kobayashi M, Tomoda J and Tsuji T: Cathepsin B and L activities in gastric cancer: Correlation with histological findings. *Biochem Med Metabol Biol* (1989) **42**, 21-29.

21. Sheahan K, Shuja S and Murnane MJ: Cystein protease activities and tumor development in human colorectal carcinoma. *Cancer Res* (1989) **49**, 3809-3814.
22. Shuja S, Sheahan K and Murnane MJ: Cysteine endopeptidase activity levels in normal human tissues, colorectal adenomas and carcinomas. *Int J Cancer* (1991) **49**, 341-346.
23. Campo E, Munoz J, Miquel R, Palacin A, Cardesa A, Sloane BF and Emmer-Buck MR: Cathepsin B expression in colorectal carcinoma correlates with tumor progression and shortened patient survival. *Am J Pathol* (1994) **145**, 301-309.
24. Fearon ER and Vogelstein B: A genetic model for colorectal cancer. *Cell* (1990) **61**, 759-767.
25. Cancer AJCo: Colon and rectum; in *Manual for Staging of Cancer*, 3rd ED, Lippincott, Philadelphia (1988) pp 75-80.
26. Japanese Society for Cancer of the Colon and Rectum: General rules for clinical and pathological studies on cancer of the colon, rectum and anus, 5th ED, Kanahara Press, Tokyo (1994).
27. Higashi T, Hashimoto M, Watanabe M, Yamauchi Y, Fujiwara M, Nakatsukasa H, Kobayashi M, Watanabe A and Nagashima H: Assay procedures for cathepsin B, H and L activities in rat tissue homogenates. *Acta Med Okayama* (1986) **40**, 27-32.
28. Lowry OH, Rosenbrough NJ and Fare AL: Protein measurement with the folin phenol reagent. *J Biol Chem* (1951) **193**, 265-275.
29. Nishimura Y, Kawabata T and Kato K: Identification of latent procathepsins B and L in microsomal lumen: Characterization of enzymatic activation and proteolytic processing *in vitro*. *Arch Biochem Biophys* (1988) **261**, 64-71.
30. Nishimura Y, Amano J, Sato H, Tsuji H and Kato K: Biosynthesis of lysosomal cathepsins B and H in cultured rat hepatocytes. *Arch Biochem Biophys* (1988) **1988**, 159-170.

Received April 18, 1996; accepted September 9, 1996.