

Acta Medica Okayama

Volume 34, Issue 2

1980

Article 9

APRIL 1980

8-14 translocation in a Japanese Burkitt's lymphoma.

Kanji Miyamoto* Jiro Sato[†] Isao Miyoshi[‡]
Ryuji Nishihara** Seiya Terao^{††}
Masamichi Hara^{‡‡} Ikuro Kimura[§]

*Okayama University,

[†]Okayama University,

[‡]Okayama University,

**Okayama University,

^{††}Okayama University,

^{‡‡}Okayama University,

[§]Okayama University,

8-14 translocation in a Japanese Burkitt's lymphoma.*

Kanji Miyamoto, Jiro Sato, Isao Miyoshi, Ryuji Nishihara, Seiya Terao,
Masamichi Hara, and Ikuro Kimura

Abstract

Chromosome analysis was performed on cells obtained from the pleural effusion of a Japanese patient with Burkitt's lymphoma. Two modal chromosomal numbers were found: 45 and 46. Five different karyotypes were present, all having a t(8q-;14q+) translocation. This case illustrates that Burkitt's lymphomas of Japanese are no exception to the frequent association of this chromosomal abnormality with Burkitt's lymphomas.

KEYWORDS: Japanese Burkitt's lymphoma, 8-14 translocation, chromosome analysis.

— BRIEF NOTE —

8-14 TRANSLOCATION IN A JAPANESE BURKITT'S LYMPHOMA

Kanji MIYAMOTO, Jiro SATO, Isao MIYOSHI*, Ryuji NISHIHARA*,
Seiya TERAOKA*, Masamichi HARA* and Ikuro KIMURA*

*Department of Pathology, Cancer Institute and *Department of Medicine,
Okayama University Medical School, Okayama 700, Japan*

(Director: Prof. J. Sato)

** (Director: Prof. I. Kimura)*

Received March 4, 1980

Abstract. Chromosome analysis was performed on cells obtained from the pleural effusion of a Japanese patient with Burkitt's lymphoma. Two modal chromosomal numbers were found: 45 and 46. Five different karyotypes were present, all having a t(8q-; 14q+) translocation. This case illustrates that Burkitt's lymphomas of Japanese are no exception to the frequent association of this chromosomal abnormality with Burkitt's lymphomas.

Key words: Japanese Burkitt's lymphoma, 8-14 translocation, chromosome analysis.

Cytogenetic studies on African, North American and European Burkitt's lymphomas disclosed the presence of a specific t(8q-; 14q+) translocation (1-4). Recently, we reported on the Burkitt's lymphoma of a Japanese, in which a 14q+ marker chromosome was found but the origin of the extra chromosomal material attached distally to the long arm of #14 chromosome could not be determined (5). We describe here the t(8q-; 14q+) translocation in another Japanese patient with Epstein-Barr virus negative Burkitt's lymphoma.

A 17-year-old boy was in good health until mid-May 1979, when he developed abdominal distention. This was followed in mid-June by fatigue, anorexia and vomiting. Abdominal masses were palpated by his family physician. A gastrointestinal series demonstrated multiple intra-abdominal tumors displacing the intestinal loops. The patient was referred to Okayama University Hospital, where an exploratory laparotomy on July 17 revealed a massive tumor involving the retroperitoneum and mesentery and an unresectable intestinal narrowing. Biopsy material tumor was not submitted for pathological examination due to a mishap. However, surface marker analysis of the tumor cell suspension indicated 90% surface immunoglobulinpositive cells. There was no lymph-

adenopathy or hepatosplenomegaly. Laboratory tests on admission were all normal. Several courses of chemotherapy with various combinations of drugs induced partial tumor regression each time, but tumor regrowth was rapid. Eventually, the disease became refractory to chemotherapy and the patient died of intestinal obstruction on December 25, 1979. Serum antibody titers against Epstein-Barr virus capsid antigen and nuclear antigen were 1:40 and 1:80, respectively, but antibodies against early antigen were not detectable at a titer of 1:10. Tumor cells from the pleural effusion were negative for EBNA. Autopsy material from the abdominal tumor revealed undifferentiated lymphoma with a starry sky pattern.

Chromosomes were analyzed on tumor cells from the pleural effusion aspirated four days prior to death. The cells were separated on a Ficoll-Conray gradient, incubated at 37°C for 15 h in McCoy 5a medium containing 20% fetal calf serum and then treated for two h with Colcemid (0.5 µg/ml). Cells in metaphase were swollen with 0.075 M KCl for 13 min at 37°C and fixed in a methyl alcohol:acetic acid (3:1) solution. Chromosome preparations were air-dried and banded with quinacrine mustard (6).

As shown in Table 1, two modal chromosomal numbers, 45 and 46, were found. Variations found in the karyotyped cells are summarized in Table 2.

TABLE 1. CHROMOSOME NUMBER DISTRIBUTION FOUND IN TUMOR CELLS FROM PLEURAL EFFUSION

Chromosome number				
45	46	90	92	Total
19 (3)	29 (8)	1	1	50 (11)

Number in parentheses=number of banded cells examined.

TABLE 2. VARIATION FOUND IN THE KARYOTYPED CELLS FROM PLEURAL EFFUSION

46, XY, t (8; 14) (q24; q32), 17p-	5
46, Xp+, Yq+, t (8; 14) (q24; q32), 17q+, 17p-	3
45, XY, t (8; 14) (q24; q32), 17p-, -18, 18q+	1
45, XY, t (8; 14) (q24; q32), -13, 17p-	1
45, X, -Y, t (8; 14) (q24; q32), 17p-	1

Five different karyotypes were present, all having a t (8q-; 14q+) translocation. Of the 11 karyotyped metaphase cells, 5 showed a karyotype of 46, XY, t (8; 14) (q24; q32), 17p-, 3 a karyotype of 46, Xp+, Yq+, t (8; 14) (q24; q32), 17q+, 17p-, (Fig. 1) and the remaining 3 each a different karyotype. Extra chromosomal bands were observed on the short arm of chromosome X (Xp+)

and on the long arms chromosomes #17, #18 and Y (17q+, 18q+ and Yq+) but their origin could not be determined. The short arm of chromosome #17 appeared to have a deletion at band 17p11.

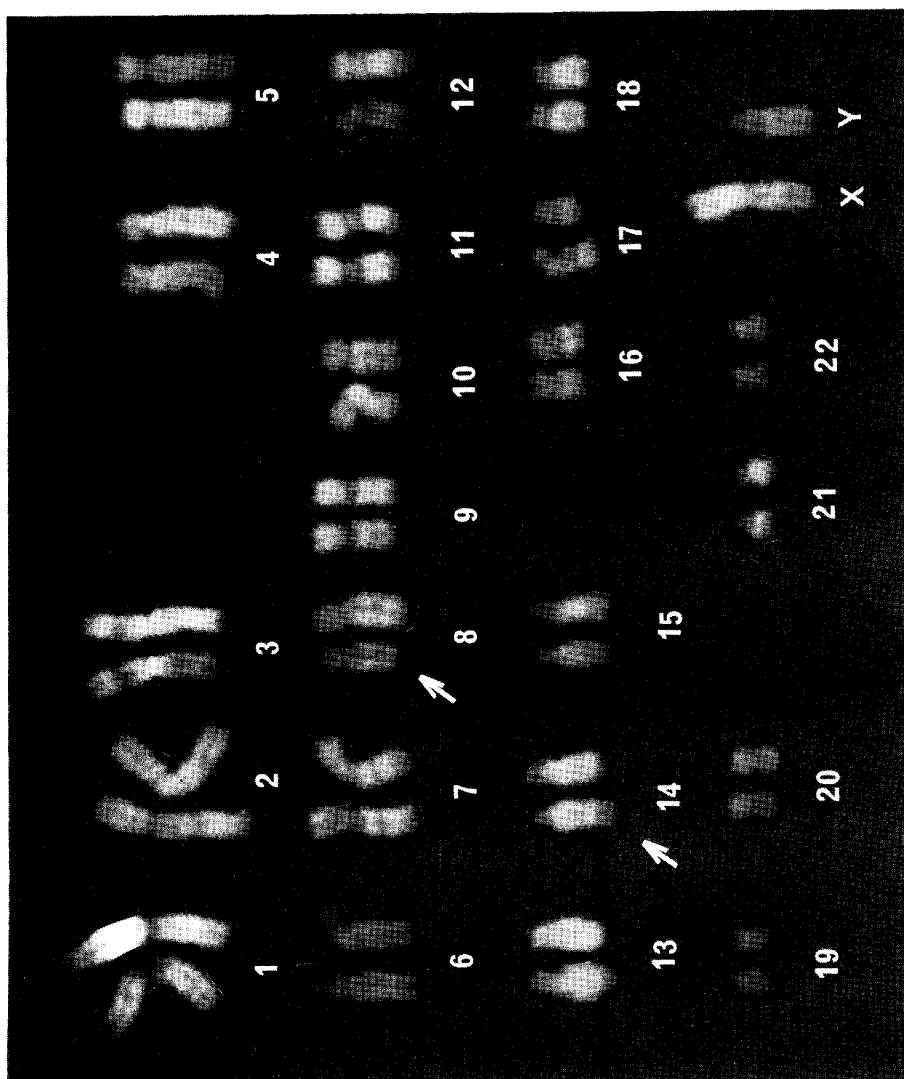


Fig. 1. Karyotype found in tumor cells from plural effusion: 46, Xp+, Yq+, t(8;14)(q24;q32), 17q+, 17p--. Arrows indicate the chromosomes involved in the t(8q-;14q+) translocation.

In the present study, we have described a typical t(8q-;14q+) translocation in a Japanese boy with Burkitt's lymphoma. The same translocation has recently been detected in a 6-year-old Japanese boy with Burkitt's lymphoma

admitted to the Department of Pediatrics (personal communication, 1979 by Kei Nagase). These two cases along with the one previously reported by us (5) strongly suggest that the 14q+ abnormality may be a frequent occurrence in Burkitt's lymphomas of Japanese as with those of African, North American, and European origin.

Acknowledgment. We thank Dr. Makoto Motoi of the Department of Pathology for information on autopsy materials.

REFERENCES

1. Manolow, G. and Manolova, Y.: Marker band in one chromosome 14 from Burkitt lymphomas. *Nature (Lond)* **237**, 33-34, 1972.
2. Zeck, L., Haglund, U., Nilsson, K. and Klein, G.: Characteristic chromosomal abnormalities in biopsies and lymphoid cell lines from patients with Burkitt and non-Burkitt lymphomas. *Int. J. Cancer* **17**, 47-56, 1976.
3. McCaw, B. K., Epstein, A. L., Kaplan, H. S. and Hecht, F.: Chromosome 14 translocation in African and North American Burkitt's lymphoma. *Int. J. Cancer* **19**, 482-486, 1977.
4. Berger, R., Bernheim, A., Fellous, M. and Brouet, J. C.: Cytogenetic study of a European Burkitt's lymphoma cell line. *J. Natl. Cancer Inst.* **62**, 1187-1192, 1979.
5. Miyamoto, K., Miyano, K., Miyoshi, I., Hamasaki, K., Nishihara, R., Terao, S., Kimura, I., Maeda, K., Matumura, K., Nishijima, K. and Tanaka, T.: Chromosome 14q+ in a Japanese patient with Burkitt's lymphoma. *Acta Med. Okayama* (in press).
6. Caspersson, T., Zech, L. and Johansson, C.: Differential binding of alkylating fluorochromes in human chromosomes. *Exp. Cell Res.* **60**, 315-319, 1970.