

# *Acta Medica Okayama*

---

*Volume 43, Issue 5*

1989

*Article 3*

OCTOBER 1989

---

## Early stages of development of rat brain tumors induced by JC virus: a sequential histological and immunohistochemical study.

Yasushi Horie\*

Makoto Motoi†

Katsuo Ogawa‡

\*Okayama University,

†Shikoku National Cancer Hospital,

‡Okayama University,

# Early stages of development of rat brain tumors induced by JC virus: a sequential histological and immunohistochemical study.\*

Yasushi Horie, Makoto Motoi, and Katsuo Ogawa

## Abstract

In order to clarify the origin of JC virus-induced brain tumors in rats, the development of tumors was sequentially analyzed histologically and immunohistochemically. Twenty-two of 30 rats (73%), which were intracerebrally inoculated with JC virus within 24 h of birth (group 1), developed, as a group, 45 brain tumors after 12 to 26 weeks. Seventeen of 27 rats (63%), which were inoculated on the 7th day after birth (group 2), developed 37 brain tumors as a group after a time 12 to 40 weeks. The tumors were found exclusively in the cerebrum. The microtumors, which were defined as tumors less than 2 mm in diameter, were located in the subependymal plate around the ventricular system. The microtumors and most part of the macrotumors consisted of cells of undifferentiated neuroectodermal nature, showing nuclear palisades and Homer-Wright-pseudorosette-like structures. Some tumor cells of macrotumors had an astrocytic nature and were positive for glial fibrillary acidic protein, S-100, Leu 7, and vimentin. In conclusion, the target cells of JC virus in rats may be undifferentiated subependymal cells of the cerebrum. The tumor cells show partial glial differentiation as they grow.

**KEYWORDS:** JC virus, brain tumor, cell differentiation, immunohistochemistry

---

\*PMID: 2558501 [PubMed - indexed for MEDLINE]

Copyright (C) OKAYAMA UNIVERSITY MEDICAL SCHOOL

## Early Stages of Development of Rat Brain Tumors Induced by JC Virus: A Sequential Histological and Immunohistochemical Study

Yasushi Horie\*, Makoto Motoi<sup>a</sup> and Katsuo Ogawa<sup>b</sup>

*Department of Pathology, Okayama University Hospital, Okayama 700, <sup>o</sup>Department of Clinical Research, Shikoku National Cancer Hospital, Matsuyama 790 and <sup>b</sup>Second Department of Pathology, Okayama University Medical School, Okayama 700, Japan*

In order to clarify the origin of JC virus-induced brain tumors in rats, the development of tumors was sequentially analyzed histologically and immunohistochemically. Twenty-two of 30 rats (73%), which were intracerebrally inoculated with JC virus within 24 h of birth (group 1), developed, as a group, 45 brain tumors after 12 to 26 weeks. Seventeen of 27 rats (63%), which were inoculated on the 7th day after birth (group 2), developed 37 brain tumors as a group after a time 12 to 40 weeks. The tumors were found exclusively in the cerebrum. The microtumors, which were defined as tumors less than 2 mm in diameter, were located in the subependymal plate around the ventricular system. The microtumors and most part of the macrotumors consisted of cells of undifferentiated neuroectodermal nature, showing nuclear palisades and Homer-Wright-pseudorosette-like structures. Some tumor cells of macrotumors had an astrocytic nature and were positive for glial fibrillary acidic protein, S-100, Leu 7, and vimentin. In conclusion, the target cells of JC virus in rats may be undifferentiated subependymal cells of the cerebrum. The tumor cells show partial glial differentiation as they grow.

*Key word:* JC virus, brain tumor, cell differentiation, immunohistochemistry

In 1973, Walker *et al.* reported the induction of brain tumors in Syrian hamsters with JC virus (JCV), a human polyoma virus, which was originally isolated from a patient with progressive multifocal leucoencephalopathy (PML) (1, 2). Since then, it has been reported that JCV also induced brain tumors in Sprague-Dawley (SD) rats and owl and squirrel monkeys (3-5). The histological types of brain tumors included medulloblastomas, glioblastomas, neuroblastomas, and

pineoblastomas (6-9). Among these tumors, cerebellar medulloblastomas, which were most frequently encountered, have been considered a useful experimental model of human medulloblastomas. In Japan, Nagashima *et al.* isolated the Tokyo-1 strain of JCV from the autopsied brain tissue of a patient with PML in 1981 (10). This virus has induced medulloblastomas in Syrian hamsters and SD rats (3, 11).

However, the early process of tumor development and the histogenesis of JCV have

\*To whom correspondence should be addressed.

not sufficiently been studied.

The present study was performed to elucidate the incidence, site, and histological and immunohistochemical nature of brain tumors, especially of the microtumors in SD rats with special reference to the histogenesis of the tumors.

## Materials and Methods

*Virus.* JCV, Tokyo-1 strain, was provided by the courtesy of Dr. K. Nagashima, Department of Pathology, Hokkaido University School of Medicine, Sapporo, Japan and Dr. K. Yasui, Department of Microbiology, Tokyo Metropolitan Institute for Neuroscience, Tokyo, Japan. The titer of virus fluid was  $10 \times 2^9$  hemagglutination units.

*Animals.* Pregnant SD rats were purchased from Nippon Charles River Co., Ltd., Hino, Japan.

*Experimental designs.* The animals were divided into two experimental groups and one control group.

*Group 1.* Fifty-five offspring from 6 pregnant rats were inoculated with 0.02 ml of the virus fluid into the right hemisphere of the brain within 24 h of birth. After 4 weeks, 25 rats had died and 30 rats survived.

*Group 2.* Thirty-two offspring from 4 pregnant rats were inoculated with 0.02 ml of the virus fluid on the 7th day after birth. Twenty-seven rats survived more than 4 weeks.

*Control group.* Five newborn rats were intracerebrally injected with 0.02 ml saline in the same manner as Group 1.

The rats of each group were consecutively sacrificed from 12 to 40 weeks after the virus inoculation. Rats were anesthetized with ether and perfused with 10% buffered formalin solution.

*Histological examination.* The whole brain tissues of each rat were fixed in 10% buffered formalin and embedded in paraffin and cut into semi-serial sections of 50  $\mu$ m thickness, from which were made several specimens of 5  $\mu$ m thickness. The specimens were stained with hematoxylin and eosin and examined for microtumors, which were defined as tumors less than 2 mm in diameter.

*Immunohistochemical examination.* Dewaxed specimens were stained by the peroxidase anti-

peroxidase (PAP) method (12) using rabbit antibodies against glial fibrillary acidic protein (GFAP) (DAKOPATTS, Denmark) (diluted 1:100) and S-100 (provided by Dr. T. Nakajima, School of Medicine, Gunma University, Maebashi Japan) (diluted 1:100) and by the avidin-biotin-peroxidase complex (ABC) method (13) using monoclonal antibodies to vimentin (Becton Dickinson Immunocytometry Systems, California, USA) (diluted 1:20), Leu 7 (Becton Dickinson) (diluted 1:20), and neurofilament protein (NFP) of 68 kilodaltons (provided by Dr. Y. Nakazato, School of Medicine, Gunma University, Maebashi, Japan) (diluted 1:100).

## Results

*Development of JC virus-induced rat brain tumors.* All the tumors developed exclusively in the cerebrum. No tumors were found in the cerebellum or brain stem (Table 3). In the control group, no tumorous lesions developed in the brain.

In group 1, 22 of 30 rats inoculated with JCV (73%) developed brain tumors between 12 and 26 weeks after the virus inoculation. The total number of tumors was 45, and the average number of tumors was 2.0 per rat. Of these 45 tumors, 31 were microtumors and 14 were macrotumors. The macrotumors varied from 2 mm to 9 mm in diameter (Table 1).

In group 2, 17 of 27 rats (63%) developed a total of 37 brain tumors between 12 and 40 weeks after the virus inoculation. The average number of tumors was 2.2 per rat.

The smallest microtumors were histologically detected in the 12th week after the virus inoculation in both experimental groups. The number of tumors per rat was largest from 16 to 19 weeks after the virus inoculation (Table 2).

*Characteristics of microtumors.* The microtumors in groups 1 and 2 showed similar distribution and histological findings. Although the incidence in group 2 was 10% less than that in group 1, this numeral dif-

ference is not significant according to a chi-square contingency test. The microtumors distributed beneath or near the ventricular system, including closed spaces such as the

**Table 1** Incidence of JC virus-induced brain tumors in rats

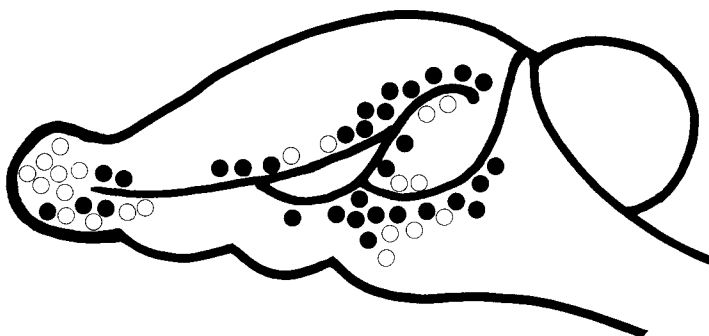
Group	No. of rats with tumors	Incidence (%)	Total no. of tumor	No. of microtumors	No. of macrotumor
	No. of rats examined				
1 <sup>a</sup>	22/30	73	45	31	14
2 <sup>b</sup>	17/27	63	37	21	16

a : Inoculated with virus within 24 h of birth.  
 b : Inoculated with virus on the 7 th day after birth.

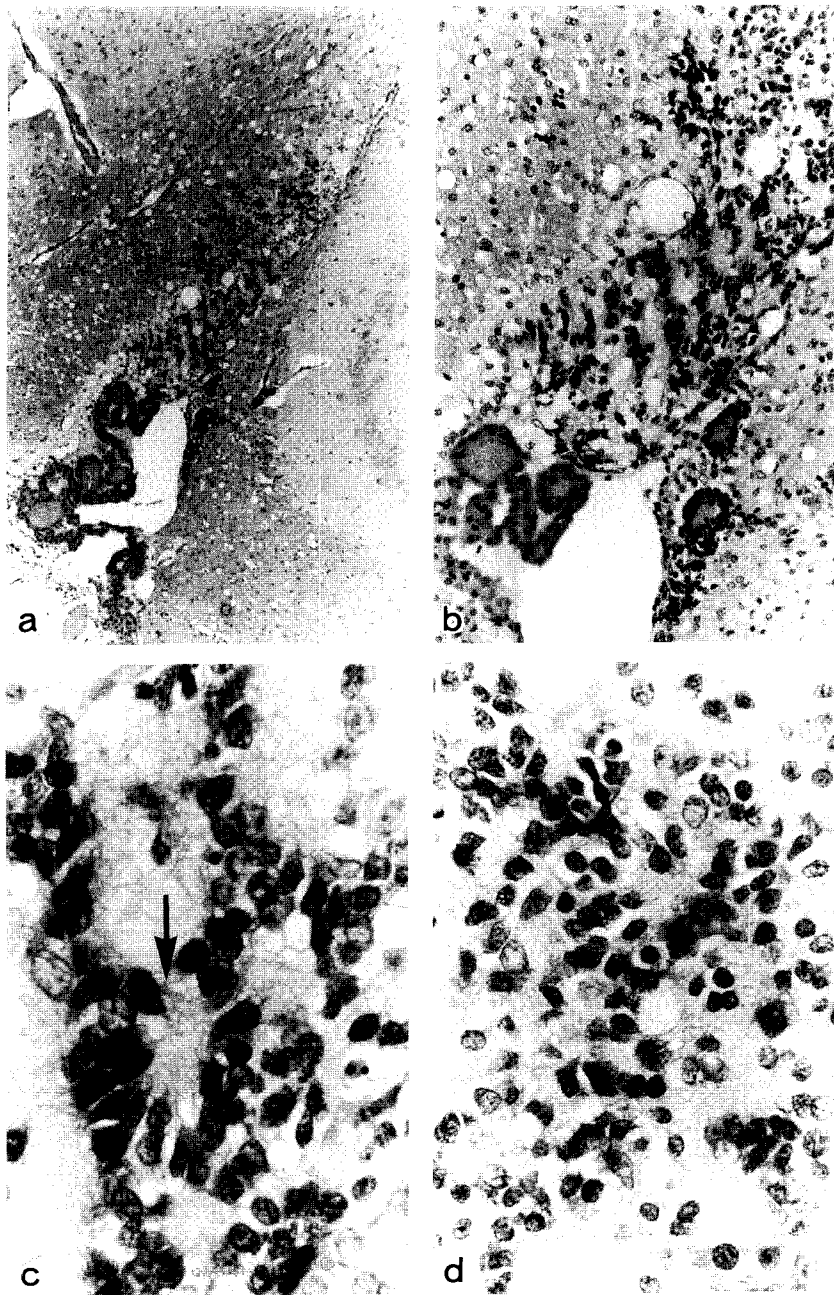
**Table 2** Development of JC virus-induced brain tumors in rats

Weeks after virus inoculation	Group 1 <sup>a</sup>						Group 2 <sup>b</sup>					
	Size <sup>c</sup> and no. of tumors					No. of tumors No. of rats	Size <sup>c</sup> and no. of tumors					No. of tumors No. of rats
	T1	T2	T3	T4	T5		T1	T2	T3	T4	T5	
12-15		3	1			4/2		1	1			2/2
16-19	3	6	3		4	16/5	9	4	3	1		17/2
20-23	2	3	4	2	4	15/11			1		4	5/8
24-27	2	2	2		4	10/12			2	4	3	9/8
28-										1	3	4/7
Total	7	14	10	2	12	45/30	9	5	7	6	10	37/27

a : Inoculated with virus within 24 h of birth.  
 b : Inoculated with virus on the 7 th day after birth.  
 c : Tumor size; T1 < 500 μm, 500 μm ≤ T2 < 1 mm, 1 mm ≤ T3 < 2 mm, 2 mm ≤ T4 < 5 mm, 5 mm ≤ T5.



**Fig. 1** Distribution of microtumors, which are less than 2 mm in diameter, induced by JC virus (Tokyo-1) in rat brains (viewed from the left lateral side). ●, Microtumors in group 1 (virus was inoculated within 24 h of birth); ○, microtumors in group 2 (virus was inoculated on the 7 th day after birth). All of the microtumor were located beneath or near the ventricular system in the cerebrum. No microtumors were detected in the brain stem or cerebellum.



**Fig. 2** Microtumor (800  $\mu\text{m}$  in diameter) in the beneath the posterior horn of the lateral ventricle. a: Stained with hematoxylin and eosin.  $\times 40$ . b: Note the rhythmic arrangement of tumor cells, showing nuclear palisades. No necrotic foci are visible in the microtumor. Stained with hematoxylin and eosin.  $\times 100$ . c: Homer-Wright-pseudorosette-like structure is seen (arrow). Tumor cells had round or oval hyperchromatic nuclei and scant cytoplasm. Stained with hematoxylin and eosin.  $\times 400$ . d: Slightly smaller tumor cells than those in Fig. 2c distributed in a diffuse fashion, forming aggregates in places. These tumor cells were observed mainly in the tumor peripheral parts. Stained with hematoxylin and eosin.  $\times 400$ .

tapetum and olfactory bulb, which are open system areas in the early developmental stage before birth in rats. No microtumors were observed in the cortical areas (Fig. 1). With regard to the location of microtumors, 7 were in the frontal lobe, 9 in the parietal lobe, 10 in the temporal lobe, 10 in the basal ganglia areas, and 16 in the olfactory bulb. No microtumors were detected in the brain stem or cerebellum (Table 3).

The histological findings of both groups were similar. The cells of microtumors had round or oval hyperchromatic nuclei and scant cytoplasm. In the most parts, a rhythmic arrangement such as nuclear palisades and Homer-Wright-pseudorosette-like structures was observed (Figs. 2a-2c). Mitotic figures were sometimes present, and small necrotic foci and vascular proliferation were

only exceptionally found. In some places, the tumor cells were slightly smaller, and the tumor cells were distributed in a diffuse fashion, forming aggregates in places (Fig. 2d). Such neuroglial proteins as GFAP, S-100, Leu 7, vimentin, and NFP were not

Table 3 Sites of microtumors

Site	No. of microtumors		
	Group 1 <sup>a</sup>	Group 2 <sup>b</sup>	Total
Cerebrum			
Frontal lobe	5	2	7
Parietal lobe	7	2	9
Temporal lobe	7	3	10
Basal ganglia	7	3	10
Olfactory bulb	5	11	16
Brain stem	0	0	0
Cerebellum	0	0	0
Total	31	21	52

a: Inoculated with virus within 24 h of birth.

b: Inoculated with virus on the 7 th day after birth.

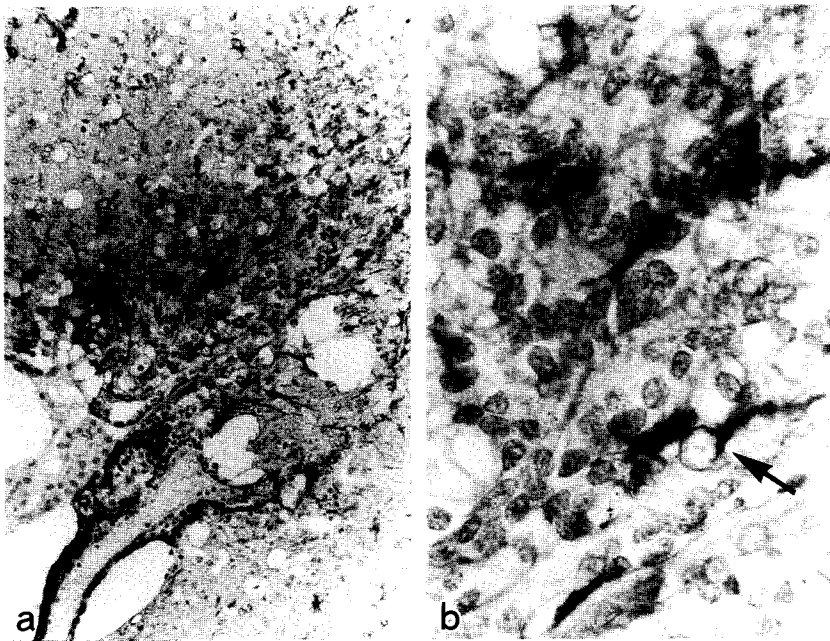


Fig. 3a Ependymal cells of the lateral ventricle and intermingling reactive non-neoplastic astrocytes are positive for glial fibrillary acidic protein. Stained by peroxidase antiperoxidase method.  $\times 100$ .

Fig. 3b Cytoplasm of intermingling reactive non-neoplastic astrocytes (arrow) is positive for glial fibrillary acidic protein, but the tumor cells are negative. Stained by peroxidase antiperoxidase method.  $\times 400$ .

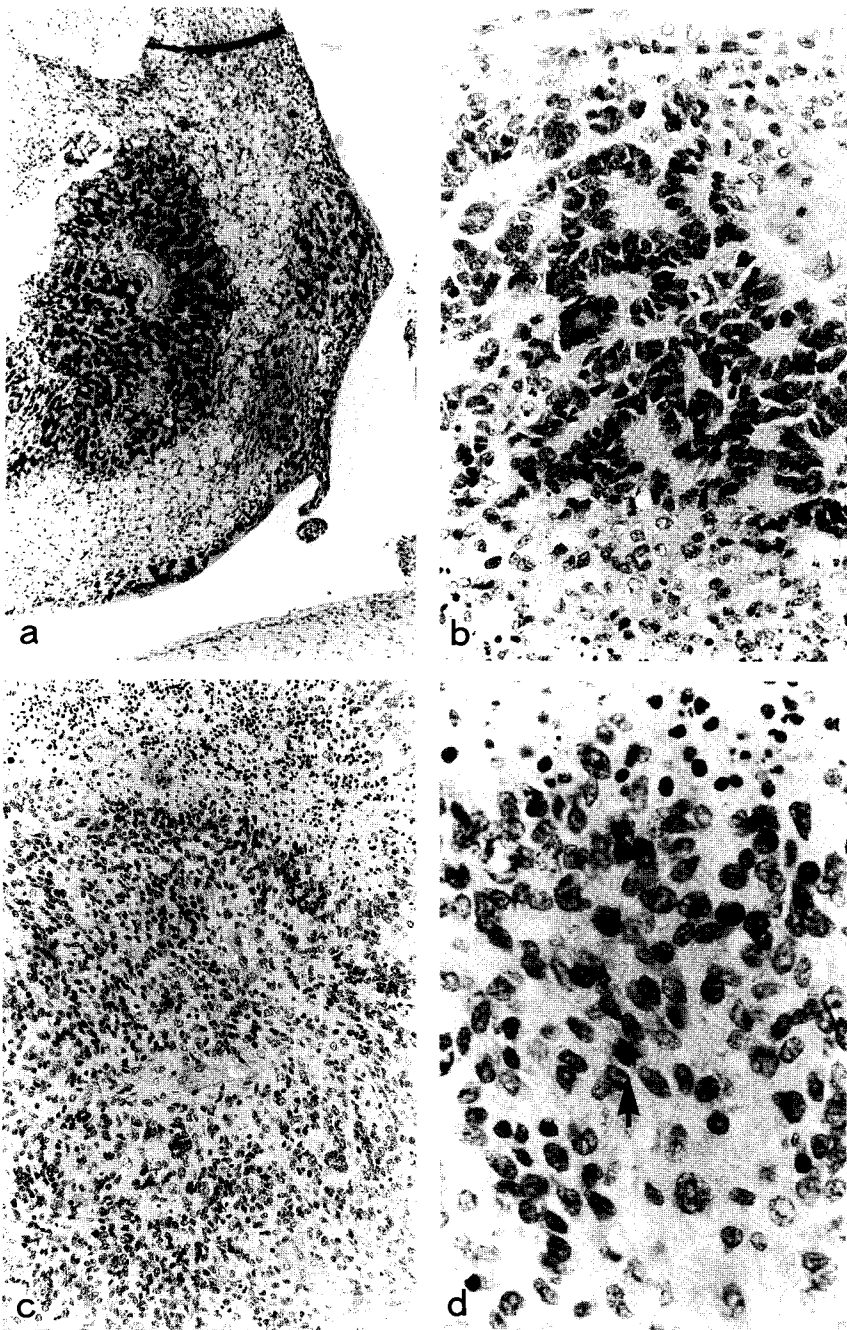


Fig. 4 Macrotumor (8 mm in diameter). a: Macrotumor occupies the surrounding large spaces of the lateral ventricle. Note the presence of necrotic foci in the tumor. Stained with hematoxylin and eosin.  $\times 40$ . b: Nuclear palisades with a rhythmic arrangement can be seen. Tumor cells are similar with those of the microtumor. Stained with hematoxylin and eosin.  $\times 200$ . c: Tumor cells near the necrotic area show a non-rhythmic arrangement. Stained with hematoxylin and eosin.  $\times 100$ . d: Differentiated tumor cells. Note the slightly hypocromatic nuclei and the spindle-shaped tumor cells. Mitotic figure (arrow) is seen in the center field. Stained with hematoxylin and eosin.  $\times 400$ .



**Table 4** Histological and immunohistochemical characteristics of JC virus-induced rat brain tumors

	Microtumors	Macrotumors
Histology	Undifferentiated neuroectodermal tumor without glial differentiation	Undifferentiated neuroectodermal tumor with glial differentiation
Nuclear palisade	Present	Present
Necrosis	Rare	Frequent
Neuroglial proteins		
GFAP <sup>a</sup>	Negative	Partially positive
S-100	Negative	Partially positive
Leu 7	Negative	Partially positive
Vimentin	Negative	Partially positive
NFP <sup>b</sup>	Negative	Negative

*a* : Glial fibrillary acidic protein.

*b* : Neurofilament protein.

detected immunohistochemically in the tumor cells of microtumors (Figs. 3a and 3b).

*Characteristics of macrotumors.* It was difficult to determine the precise site of macrotumors because these tumors occupied large areas. However, the macrotumors were presumably formed from enlargement and fusion of microtumors because the areas of the both tumors overlapped in the rat brains.

The tumor cells of most macrotumors were essentially the same as those of the microtumors. Nuclear palisades and Homer-Wright-pseudorosette-like structures were frequently seen, and mitotic activities, necrotic foci, and vascular proliferation were prominent (Figs. 4a and 4b). The histological feature of macrotumors which differed from that of microtumors was the presence of the areas where the tumor cells had differentiated cellular characters. These parts were mainly in the center of the macrotumors, particularly near the necrotic foci. In such areas, the tumor cells lost the rhythmic arrangement and were slightly spindle in shape with slightly hypochromatic nuclei (Figs. 4c and 4d). These cells were positive for GFAP, S-100, Leu 7 and vimentin,

but negative for NFP (Table 4).

## Discussion

Since Walker *et al.* (1) first reported that JCV was oncogenic in Syrian hamsters, a wide range of tumors, such as medulloblastomas, glioblastomas, undifferentiated primitive brain tumors and papillary ependymomas have been reported to be induced by JCV (6-9). Subsequent studies revealed that JCV could also induce astrocytomas in owl and squirrel monkeys (4, 5). In 1985, Ohsumi *et al.* demonstrated the oncogenicity of JCV in the cerebrum of rats (3). The rat tumor cells were of undifferentiated neuroectodermal nature with small areas showing a glial differentiation. However, the early stages of the tumor development remained obscure.

In the present study, the sequential development of brain tumors induced by JCV in rats were sequentially analyzed. Like the other experimental brain tumors, JCV-induced rat brain tumors were detected first as small neoplastic nodules. We began our examination 12 weeks after the virus inoculation, so nothing is known of lesions which developed before that time. The microtumors were located beneath or near the ventricular system of the cerebrum. The neoplastic nature of these microtumors was indicated by the following findings: the absence of similar lesions in the control group and the presence of cellular atypia, high cellular density, frequent mitotic figures, and transition between the microtumors and macrotumors.

The microtumors and most parts of macrotumors showed undifferentiated neuroectodermal features. Although nuclear palisades and Homer-Wright-pseudorosettes-like structures were frequently seen, the tumor cells were negative for NFP. The electron microscopic study of Osumi *et al.* revealed no

definite neuronal differentiation in the Homer-Wright-pseudorosette-like structures of JCV-induced brain tumors (14). It seems to the authors that this structure is an obliquely cut feature of nuclear palisades with a rhythmic arrangement and not always an indicator of neuronal differentiation of brain tumors. As the tumors grew, differentiated areas appeared, in which the tumor cells showed a non-rhythmic arrangement and were positive for GFAP, S-100, Leu 7, and vimentin. Neuronal differentiation was never seen in any of the tumors. From these findings, JCV may transform subependymal undifferentiated cells which in turn differentiate into glial cells in some areas, as the tumors grow.

We demonstrated the tumorigenicity of JCV in 7-day-old rats (group 2) as well as in the newborn rats (group 1). There was no apparent histological difference between group 1 and group 2. The difference of incidence of tumor development between group 1 and group 2 was not statistically significant.

It is interesting that, in the present study, the tumor cells showed a glial differentiation as the tumors grew. The tumor cell of microtumors had an undifferentiated neuroectodermal nature, simulating human medulloblastoma or spongioblastoma-like cells. As the tumors enlarged, some tumor cells with glial cell nature appeared, simulating human poorly differentiated astrocytoma. In this connection, it is interesting that Ikehara found that tumor cells of JCV-induced brain tumor changed in stainability for GFAP from negative to positive on cultivation (15).

The early development of other experimental brain tumors including human adenovirus type 12 (Ad 12)- and ethylnitrosourea (ENU)-induced brain tumors in rats have been analyzed, using methods similar to those in the present study (16-20). Ad 12 and ENU also transformed subependymal cells

and induced microtumors in the subependymal layers. However, Ad 12 induced brain tumors with a less differentiated appearance than those induced by JCV. On the other hand, ENU induced tumors with a more differentiated appearance. The distinctive differences in the tumor induction among these three oncogenic agents are the length of latent periods and the maturity of the tumor cells. The latent period is shortest in Ad 12, the longest in ENU, and intermediate in JCV, and the tumor cells are more undifferentiated in Ad 12-, JCV-, and ENU-induced tumors in that order (15). Undifferentiated subependymal cells may be equally transformed by several oncogenic agents, but the degree of neuroglial differentiation of the tumor cells differs among the respective tumors. The length of the latent periods may be the critical factor in the direction of tumor maturity.

**Acknowledgment.** The authors wish to thank Prof. Tadaatsu Akagi, Second Department of Pathology, Okayama University Medical School for his continuing guidance and encouragement.

## References

1. Walker DL, Padgett BL, ZuRhein GM, Albert AE and Marsh RF: Human papovavirus (JC): Induction of brain tumors in hamsters. *Science* (1973) **181**, 674-676.
2. Padgett BL, Walker DL, ZuRhein GM, Eckroade RJ and Dessel BH: Cultivation of papova-like virus from human brain with progressive multifocal leukoencephalopathy. *Lancet* (1971) **1**, 1257-1260.
3. Ohsumi S, Ikehara I, Motoi M, Ogawa K, Nagashima K and Yasui K: Induction of undifferentiated brain tumors in rats by a human polyomavirus (JC virus). *Jpn J Cancer Res* (1985) **76**, 429-431.
4. London WT, Houff SA, Madden DL, Fuccillo DA, Gravell M, Wallen WC, Palmer AE, Sever JL, Padgett BL, Walker DL, ZuRhein GM and Ohashi T: Brain tumors in owl monkeys inoculated with a human polyomavirus (JC virus). *Science* (1978) **201**, 1246-1249.
5. London WT, Houff SA, McKeever PE, Wallen WC, Sever JL, Padgett BL and Walker DL: Viral-induced astrocytomas in squirrel monkeys; in Poly-

- omaviruses and Human Neurological Diseases, Sever and Madden eds, Alan R. Liss Inc., New York (1983) pp 227-237.
6. Varakis JN and ZuRhein GM: Experimental pineocytoma of the Syrian hamster induced by a human papovavirus (JC). *Acta Neuropathol* (1976) **35**, 243-264.
  7. Varakis J, ZuRhein GM, Padgett BL and Walker DL: Induction of peripheral neuroblastomas in Syrian hamsters after injection as neonates with JC virus, a human polyoma virus. *Cancer Res* (1978) **38**, 1718-1722.
  8. ZuRhein GM and Varakis JN: Perinatal induction of medulloblastomas in Syrian golden hamsters by a human polyoma virus (JC). *Natl Cancer Inst Monogr* (1979) **51**, 205-208.
  9. ZuRhein GM: Studies of JC virus-induced nervous system tumors in the Syrian hamsters: A review; in *Polyomaviruses and Human Neurological Diseases*, Sever and Madden eds, Alan R. Liss, Inc., New York (1983) pp 205-221.
  10. Nagashima K, Yamaguchi K, Yasui K and Ogiwara H: Progressive multifocal leukoencephalopathy. Neuro-pathology and virus isolation. *Acta Pathol Jpn* (1981) **31**, 953-961.
  11. Nagashima K, Yasui K, Kimura J, Washizu M, Yamaguchi K and Mori W: Induction of brain tumors by a newly isolated JC virus (Tokyo-1 strain). *Am J Pathol* (1984) **116**, 455-463.
  12. Sternberger LA, Hardy PH, Cuculis JJ and Meyer HG: The unlabeled antibody enzyme method of immunohistochemistry. Preparation and properties of soluble antigen-antibody complex (horseradish peroxidase-antihorseradish peroxidase) and its use in identifica-  
tion of spirochetes. *J Histochem Cytochem* (1970) **18**, 315-333.
  13. Hsu SM, Raine L and Fanger H: Use of avidin-biotin-peroxidase complex (ABC) in immunoperoxidase techniques: A comparison between ABC and unlabeled antibody (PAP) procedures. *J Histochem Cytochem* (1981), **29**, 577-580.
  14. Ohsumi S, Motoi M and Ogawa K: Induction of undifferentiated tumors by JC virus in the cerebrum of rats. *Acta Pathol Jpn* (1986) **36**, 815-825.
  15. Ikehara I: Morphological characteristics of JC virus-induced rat cerebral tumor cells *in vitro* *Neuropathology* (1985) **6**, 367-377 (in Japanese).
  16. Shinozaki Y: Distribution and life history of rat brain tumors induced by human Adenovirus type 12 in their early stages of the oncogenesis. *Pathol Res Pract* (1981) **172**, 330-348.
  17. Ogawa K: Adenovirus type 12-induced tumors; An approach for experimental brain tumors. *Tr Soc Pathol Jpn* (1979) **68**, 35-78 (in Japanese).
  18. Koestner A, Swenberg JA and Weckslers W: Trans-placental production with ethylnitrosourea of neoplasms of the nervous system in Sprague-Dawley rats. *Am J Pathol* (1971) **63**, 27-56.
  19. Motoi M, Hayashi K, Kawabata K, Shinozaki Y and Ogawa K: Brain tumor induction by intravenous injection of ENU to early pregnant rats. *Proc Jpn Cancer Assoc* (1982) **29**, 44 (in Japanese).
  20. Yoshino T, Motoi M and Ogawa K: Morphological maturation of tumor cells induced by ethylnitrosourea (ENU) in the rat brains. 1. On the tumors by administration of ENU in the late gestational stage. *Acta Pathol Jpn* (1985) **35**, 1385-1396.

Received June 8, 1989; accepted August 1, 1989