

Acta Medica Okayama

Volume 49, Issue 3

1995

Article 8

JUNE 1995

Mechanical left ventricular support in patients with Marfan's syndrome: a report of two cases.

Kozo Ishino*
Shunji Kawakami**

Taiji Murakami†
Yoshimasa Senoo††

Hiroyuki Irie‡
Shigeru Teramoto‡‡

*Okayama University,

†Okayama University,

‡Okayama University,

**Okayama University,

††Okayama University,

‡‡Okayama University,

Mechanical left ventricular support in patients with Marfan's syndrome: a report of two cases.*

Kozo Ishino, Taiji Murakami, Hiroyuki Irie, Shunji Kawakami, Yoshimasa Senoo, and Shigeru Teramoto

Abstract

Left ventricular assist device (LVAD) was utilized for the treatment of postcardiotomy heart failure in two patients with Marfan's syndrome. Patient 1 (a 22-year-old) with annuloaortic ectasia (AAE) and DeBakey type II dissection had been supported by LVAD for 87h after composite graft replacement of the ascending aorta and aortic valve. Patient 2 (a 52-year-old) with AAE and DeBakey type I dissection had been supported by LVAD for 91 h after aortic valve replacement. During the assist, both patients complicated bleeding from the fragile left atria near the sites of cannulation. Patient 1 died of multiple organ failure on the 62nd postoperative day, but patient 2 returned to work after surgery.

KEYWORDS: ventricular assist device, Marfan's syndrome, aortic dissection

*PMID: 7676848 [PubMed - indexed for MEDLINE]

Brief Note

Mechanical Left Ventricular Support in Patients with Marfan's Syndrome: A Report of Two Cases

Kozo ISHINO*, Taiji MURAKAMI, Hiroyuki IRIE, Shunji KAWAKAMI, Yoshimasa SENOO and Shigeru TERAMOTO

Second Department of Surgery, Okayama University Medical School, Okayama 700, Japan

Left ventricular assist device (LVAD) was utilized for the treatment of postcardiotomy heart failure in two patients with Marfan's syndrome. Patient 1 (a 22-year-old) with annuloaortic ectasia (AAE) and DeBakey type II dissection had been supported by LVAD for 87h after composite graft replacement of the ascending aorta and aortic valve. Patient 2 (a 52-year-old) with AAE and DeBakey type I dissection had been supported by LVAD for 91h after aortic valve replacement. During the assist, both patients complicated bleeding from the fragile left atria near the sites of cannulation. Patient 1 died of multiple organ failure on the 62nd postoperative day, but patient 2 returned to work after surgery.

Key words: ventricular assist device, Marfan's syndrome, aortic dissection

The cardiovascular complications associated with Marfan's syndrome are primarily responsible for the reduced life expectancy in patients with this hereditary disorder (1). Since the introduction of aortic root replacement using a composite graft by Bentall and DeBono in 1968 (2), the results of surgery in this syndrome have improved (3, 4). Crawford reported that 63% of Marfan's patients who underwent cardiovascular operations had dissections or aneurysms in the descending aorta (5). Therefore, once Marfan's patients develop severe left ventricular failure refractory to medical treatment, it is often difficult to use an intra-aortic balloon pump (IABP) and another strategy for circulatory support would be necessary.

We herein report two patients with Marfan's syndrome with aortic lesions, who were treated with left ventricular assist devices (LVADs) after open heart operations, and discuss problems and complications of the LVAD support associated with this syndrome.

Patient 1

A 22-year-old man was admitted as an emergency because of progressive dyspnea. At catheterization, the cardiac index was 1.8 l/min/m². Angiocardiology demonstrated an isolated aortic regurgitation (Grade 4/4), an aneurysm in the ascending aorta, and a DeBakey type II aortic dissection. The echocardiogram revealed a left ventricular ejection fraction of 0.25, an aortic annulus of 50mm and an aneurysm of 85mm in diameter. A chest X-ray showed a cardiothoracic ratio of 0.75. The patient became oliguric with an increase in serum creatinine to 3.3 mg/dl, and an IABP was inserted the day before operation.

The patient was intubated in the sitting position. Immediately after sternotomy, cardiac stillstand occurred and cardiopulmonary bypass (CPB) was initiated at once. The aortic root was replaced using a composite graft with a St. Jude Medical valve according to the Cabrol procedure (6). The cross-clamping time was 229min. Attempts were made to discontinue CPB, but arterial pressure was lower than 80mmHg under IABP support. Therefore, an LVAD using a centrifugal pump (Bio-Pump, Biomedicus, Minneapolis, MN, USA) was established between the left atrium and the ascending aorta by the following maneuver: a Dacron graft forming the end of the outflow cannula was anastomosed to the

* To whom correspondence should be addressed.

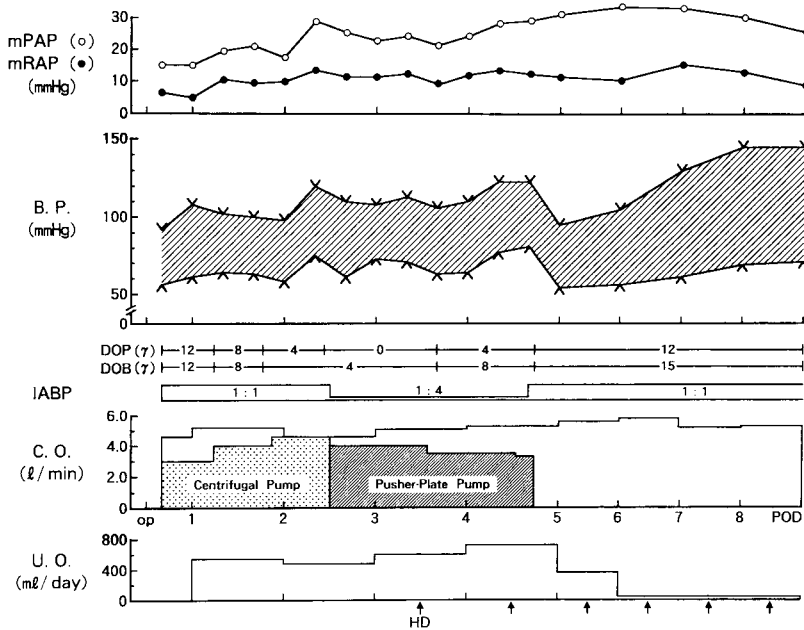


Fig. 1 Postoperative course in patient 1. mPAP: mean pulmonary artery pressure, mRAP: mean right atrial pressure, B.P.: blood pressure, DOP: dopamine, DOB: dobutamine, IABP: intra-aortic balloon pump, op: operation, POD: postoperative day, C.O.: cardiac output, U.O.: urine output, HD: hemodialysis.

composite graft and the inflow cannula was inserted into the left atrium through a Dacron atrial cuff which was sutured to the right pulmonary vein near the origin. CPB could be discontinued with the LVAD flow of 3.0 l/min.

The postoperative course is illustrated in Fig. 1. The patient's hemodynamics remained stable with IABP and LVAD on the intensive care unit. However, drainage from the chest tubes increased followed by a drop in arterial pressure to 80 mmHg 16 h postoperatively. At reoperation, bleeding from a tear of the left atrium was identified near the suture line of the Dacron cuff. After closure of the tear, arterial pressure increased up to 120 mmHg with a cardiac index of 2.2 l/min/m². On the 2nd postoperative day (POD) creatine phosphokinase was 1422 IU/l and ECG revealed ST elevation in leads V₂-V₅. Because of these ischemic changes, the need for long-term LVAD support was suspected. Thus, the centrifugal pump was converted to an air-driven, pusher plate (PP) type pump with a stroke volume of 40 ml which was coated with nonthrombogenic material at the blood-contacting surfaces (National Cardiovascular Center, Osaka, Japan) (7). The PP pump was operated in a fill-to-empty condition, variable rate (VR) mode which could automatically attain maximal bypass flow (8); the LVAD flow was 90 % of the cardiac output at 110 beats/min. Since the cardiac index remained at 2.5 l/min/m² on the 3rd POD, the VR mode was changed to a fixed rate (FR) mode at 90 beats/min for the purpose of

weaning from the LVAD. On the 4th POD, arterial pressure with the pump off stayed over 100 mmHg with a cardiac index of 2.6 l/min/m², and the LVAD support was uneventfully terminated after 87 h. A chest X-ray on the 7th POD showed a cardiothoracic ratio of 0.5. Despite the recovery of cardiac function, the patient developed mediastinitis followed by septicemia and died of multiple organ failure on the 62nd POD.

Patient 2

A 52-year-old man with a history of a graft replacement of an abdominal aortic aneurysm at the age of 49 and an entry closure of DeBakey type I dissection in the ascending aorta at the age of 50 was admitted for aortic valve surgery. On admission, the patient had orthopnea and hepatomegaly with a total bilirubin level of 3.5 mg/dl. The cardiac index by catheterization was 2.1 l/min/m². Angiocardiography demonstrated grade 4 aortic regurgitation and aneurysmal dilatation just above the aortic annulus. Echocardiogram showed moderate mitral and tricuspid regurgitation and a left ventricular ejection fraction of 0.33; the aortic annulus was 30 mm and the ascending aorta was 46 mm in diameter.

On account of the patient's poor condition and severely impaired left ventricular function, aortic valve replacement using a St. Jude Medical valve and tricuspid annuloplasty were performed. The cross-clamping time was 169 min. Although arterial pressure at the time of weaning

June 1995

Ventricular Support in Marfan's Syndrome 171

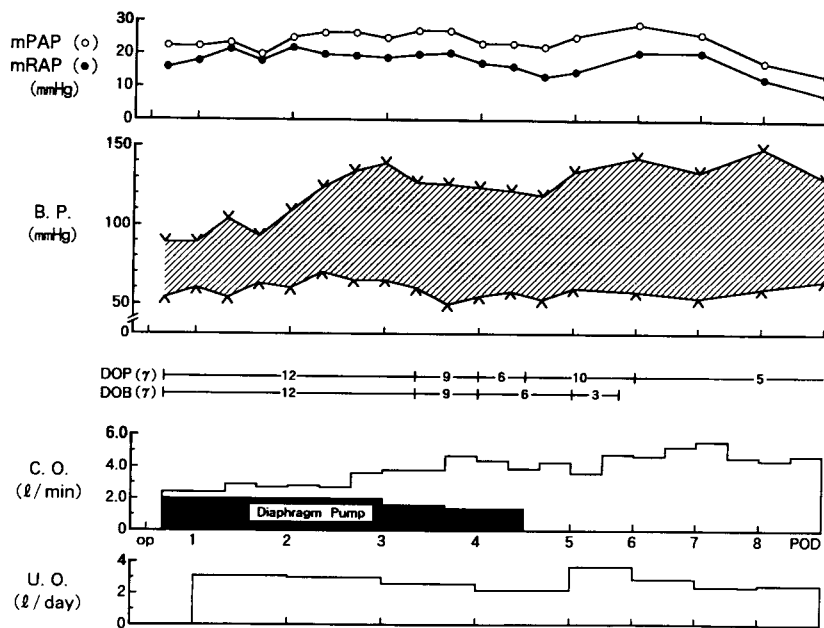


Fig. 2 Postoperative course in patient 2. mPAP: mean pulmonary artery pressure, mRAP: mean right atrial pressure, B.P.: blood pressure, DOP: dopamine, DOB: dobutamine, op: operation, C.O.: cardiac output, U.O.: urine output.

from CPB was lower than 70 mmHg under maximal inotropic support, an IABP could not be used because of the dissection in the descending aorta. Hence, an LVAD using an air-driven, diaphragm type pump with a stroke volume of 70 ml (National Cardiovascular Center, Osaka, Japan) (9) was inserted between the left atrium and the ascending aorta in a similar fashion. Despite the high pump-driving pressure, the aortic wall which was thickened through the dissection caused resistance at the anastomosis of the outflow cannula, thus making a complete ejection of the pump impossible. Finally, the LVAD flow of 2.0 l/min at 50 beats/min could be achieved and CPB was discontinued.

The postoperative course is shown in Fig. 2. On the 1st POD, the cardiac index was 1.6 l/min/m². Although chest drainage decreased to 45 ml/h on the 2nd POD, arterial oxygen tension fell to 70 mmHg with the inspiratory fraction of oxygen at 1.0. A chest X-ray revealed an enlargement of the mediastinal shadow around the inflow cannula. At reexploration, a bleeding point was found at the dehiscence of the Dacron atrial cuff. After the repair, arterial pressure rose to above 100 mmHg, while the cardiac index stayed low at 1.7 l/min/m². On the 3rd POD, the cardiac index increased to 2.3 l/min/m² and then weaning of the LVAD was begun; the pumping rate was reduced to 45 beats/min. The patient's hemodynamics on the 4th POD were stable with a minimum LVAD support at 40 beats/min and were not



Fig. 3 Membranous thrombus formed on the blood chamber after 91 h of pumping.

changed by turning the pump off. The LVAD support was then terminated after 91 h of pumping. In the explanted pump, a membranous thrombus was found which formed in accordance with systolic position of the diaphragm movement (Fig. 3). The patient was uncomplicated thereafter and discharged from the hospital on the 63rd POD.

Discussion

Among currently available circulatory support systems, ventricular assist device (VAD) is the most

effective method to unload the depressed myocardium and to maintain organ circulation. Although the use of VADs in 965 patients were registered as of 1990 (10), an application of VAD in patients with Marfan's syndrome has not been reported. As shown in our two patients, the feasibility of mechanical support in Marfan's patients depends on the existence of the aortic lesion. Because of a high incidence of dissections or aneurysms in the descending aorta which prohibit IABP placement, sometimes LVAD is the only lifesaving alternative after cardiovascular surgery.

Bleeding from the left atria near the site of cannulation, which occurred in both patients reported herein, is one of the serious problems associated with VAD utilization. The cause of the left atrial tears was not evident. For the placement of the LVAD inflow cannula, we used a Dacron atrial cuff, according to the procedure of Takano *et al.* (11), to prevent air-sucking and to fix it fast. Although LVADs have been implanted by the same maneuver in another 7 patients with valvular heart disease, such complication did not occur in any other instance. Therefore, considering the incidence of atrial septal defect (12), atrial arrhythmias (13) and the prevalence of left heart lesions such as mitral annular enlargement (14, 15) associated with Marfan's syndrome, we suspect that the left atrial wall might be also affected by connective tissue degeneration. Hence, in patients with Marfan's syndrome, insertion of the inflow cannula into the left ventricle from the apex, as shown by Ban *et al.* (16), might be a better way to avoid the complication of bleeding than inserting it into the left atrium through a Dacron cuff or a purse-string suture (17, 18).

Our method of using a pulsatile VAD is to run a pump in the VR or FR mode in the fill-to-empty condition. The purpose of this pump operation is to prevent thrombus formation through a good wash-out of the pump surface. In patient 2, however, the pump did not eject to the end-systolic position because of the high resistance at the anastomosis of the outflow cannula. This limitation of the diaphragm movement resulted in thrombus formation. In Marfan's patients, the variety of possible changes in the aortic wall such as thinness, thickness, hardening, and dissection can make it difficult to achieve optimal pump operation.

Preoperative left ventricular dysfunction is one of the factors which increase mortality after cardiovascular surgery in Marfan's syndrome (19). Our patients were both functional class IV of the New York Heart Association

(NYHA) before the operation. They also were complicated by liver or renal dysfunction. Gott *et al.* achieved a hospital mortality of 1% in 100 Marfan's patients who had repair with composite graft, of whom 71% were in NYHA class I or II preoperatively. He recommended elective operation when the aneurysm reaches 6 cm, even if the patient is free of symptoms (4). Therefore, prophylactic surgery may be favorable for prolonging the life-expectancy of Marfan's patients. Our results indicate that in such patients, once they develop postoperative profound heart failure, LVAD is a feasible and useful method to support the circulation.

References

1. Murdoch JL, Walker BA, Halpern BL, Kuzma JW and McKusick VA: Life expectancy and causes of death in the Marfan syndrome. *N Engl J Med* (1972) **286**, 804-808.
2. Bentall H and DeBono A: A technique for complete replacement of the ascending aorta. *Thorax* (1968) **23**, 338-339.
3. Kouchoukos NT, Marshall WG Jr and Wedige-Streicher TA: Eleven-year experience with composite graft replacement of the ascending aorta and aortic valve. *J Thorac Cardiovasc Surg* (1986) **92**, 691-705.
4. Gott VL, Pyeritz RE, Magovern GJ Jr, Cameron DE, Greene PS and McKusick VA: Composite graft repair of Marfan aneurysm of the ascending aorta: Results in 100 patients. *Ann Thorac Surg* (1991) **52**, 38-45.
5. Crawford ES: Marfan's syndrome: Broad spectral surgical treatment of cardiovascular manifestations. *Ann Surg* (1983) **198**, 487-505.
6. Cabrol C, Pavie A, Gandjbakhch I, Villemot JP, Guiraudon G, Laughlin L, Etievent P and Cham B: Complete replacement of the ascending aorta with reimplantation of the coronary arteries. *J Thorac Cardiovasc Surg* (1981) **81**, 309-315.
7. Takatani S, Tanaka T, Takano H, Nakatani T, Taenaka Y, Umezumi M, Matsuda T, Iwata H, Noda H, Nakamura T, Seki J, Hayashi K and Akutsu T: Development of a high performance implantable total artificial heart. *Life Support Syst* (1984) **2** (Suppl) 249-251.
8. Takatani S, Harasaki H, Suwa S, Murabayashi S, Sukalac R, Jacobs G, Kiraly R and Nose Y: Pusher-plate type TAH system operated in the left and right free-running variable rate mode. *Artif Organs* (1981) **5**, 132-142.
9. Takano H, Taenaka Y, Nakatani T, Akutsu T and Manabe H: Successful treatment of profound left ventricular failure by automatic left ventricular assist system. *World J Surg* (1985) **9**, 78-88.
10. Pae WE Jr, Miller CA, Matthews Y and Pierce WS: Ventricular assist devices for postcardiotomy cardiogenic shock. *J Thorac Cardiovasc Surg* (1992) **104**, 541-553.
11. Takano H, Taenaka Y, Nakatani T, Noda H, Kinoshita M, Matsuda T, Akutsu T and Manabe H: Development and evaluation of ventricular assist blood pump to salvage patients with profound heart failure. *J Jpn Assoc Thorac Surg* (1989) **37**, 2072-2081 (in Japanese).
12. McKusick VA: The cardiovascular aspects of Marfan's syndrome: A heritable disorder of connective tissue. *Circulation* (1955) **11**, 321-342.
13. Phornphutkui C, Rosenthal A and Nadas AS: Cardiac manifestations of Marfan syndrome in infancy and childhood. *Circulation* (1973) **47**, 587-596.

June 1995

Ventricular Support in Marfan's Syndrome 173

14. Roberts WC and Honig HS: The spectrum of cardiovascular disease in the Marfan syndrome: A clinico-morphologic study of 18 necropsy patients and comparison to 151 previously reported necropsy patients. *Am Heart J* (1982) **104**, 115-135.
15. Pyeritz RE and Wappel MA: Mitral valve dysfunction in the Marfan syndrome. *Am J Med* (1983) **74**, 797-807.
16. Ban T, Fukumasa H, Soneda J, Iwaya F, Hoshino S and Yuasa S: Clinical application of left ventricular assist device. *J Cardiac Surg* (1987) **2**, 21-30.
17. Pierce WS, Parr GV, Myers JL, Pae WE. Jr, Bull AP and Waldhausen JA: Ventricular-assist pumping in patients with cardiogenic shock after cardiac operations. *N Engl J Med* (1981) **305**, 1606-1610.
18. Pennington DG, Kanter KR, McBride LR, Kaiser GC, Barner HB, Miller LW, Naunheim KS, Fiore AC and Willman V: Seven years' experience with the Pierce-Donachy ventricular assist device. *J Thorac Cardiovasc Surg* (1988) **96**, 901-911.
19. Lewis CTP, Cooley DA, Murphy MG, Talledo O and Vega D: Surgical repair of aortic root aneurysms in 280 patients. *Ann Thorac Surg* (1992) **53**, 38-46.

Received January 7, 1994; accepted January 10, 1995.