

# *Acta Medica Okayama*

---

*Volume 34, Issue 2*

1980

*Article 2*

APRIL 1980

---

Laboratory and histological similarities  
between Wilson's disease and rats with copper  
toxicity.

Mikio Narasaki\*

\*Okayama University,

Copyright ©1999 OKAYAMA UNIVERSITY MEDICAL SCHOOL. All rights reserved.

# Laboratory and histological similarities between Wilson's disease and rats with copper toxicity.\*

Mikio Narasaki

## Abstract

Rats were injected intraperitoneally with copper-lactate daily for over 160 days (total dose of 30 mg copper in each animal). At 120 to 160 days of copper administration, animals developed symptoms similar to those of Wilson's disease, i.e., kidney functional disturbances, proteinuria, aminoaciduria, decreased blood ceruloplasmin oxidase activity and increased urinary copper excretion. Cirrhosis was found in some animals. Tubular necrosis of the kidneys, liver fibrosis and tigrolysis of thalamic nerve cells were also found. Copper depositions were observed in liver parenchymal cells, renal tubular epithels, thalamus glia cells and on the Descemet's membrane of the cornea. The similarities between induced copper- intoxication in rats and Wilson's disease are discussed.

**KEYWORDS:** copper-intoxication, Wilson's disease, coppre-complex, heavy copper deposition.

---

\*PMID: 6450519 [PubMed - indexed for MEDLINE]

Acta Med. Okayama 34, (2), 81—90 (1980)

## LABORATORY AND HISTOLOGICAL SIMILARITIES BETWEEN WILSON'S DISEASE AND RATS WITH COPPER TOXICITY

Mikio NARASAKI

*Department of Pathology, First Division, Okayama University Medical School,  
Okayama 700, Japan (Director: Prof. S. Seno)*

*Received November 21, 1979*

*Abstract.* Rats were injected intraperitoneally with copper-lactate daily for over 160 days (total dose of 30 mg copper in each animal). At 120 to 160 days of copper administration, animals developed symptoms similar to those of Wilson's disease, *i.e.*, kidney functional disturbances, proteinuria, aminoaciduria, decreased blood ceruloplasmin oxidase activity and increased urinary copper excretion. Cirrhosis was found in some animals. Tubular necrosis of the kidneys, liver fibrosis and tigrolysis of thalamic nerve cells were also found. Copper depositions were observed in liver parenchymal cells, renal tubular epithels, thalamus glia cells and on the Descemet's membrane of the cornea. The similarities between induced copper-intoxication in rats and Wilson's disease are discussed.

*Key words:* copper-intoxication, Wilson's disease, copper-complex, heavy copper deposition.

Wilson's disease is characterized by progressive lenticular degeneration and liver cirrhosis, with specific changes in the cornea Kayser-Fleischer ring (1). Patients with this disease are occasionally found in this country and it is generally believed that the disease is an inherited disorder of copper metabolism. It is estimated that about 1-2 per 500 Japanese have this gene. The disease is closely related to disturbances in copper-metabolism. Heavy copper depositions in various organs are essentially responsible for the degenerative changes in the organs and to related dysfunctions, *e.g.*, liver cirrhosis, tubular necrosis of kidneys and aminoaciduria, lenticular damage and related nervous system symptoms.

Experiments to induce the disease in animals by loading a large dose of copper have not succeeded (2). The serum copper-level is often low in Wilson's disease, and the situation is somewhat similar to that in the newborn, *i.e.*, high copper content in liver with low serum copper levels. Such specific copper metabolism in the newborn may be related to high serum lactic acid levels (3). Lactic acid may serve as a copper-carrier to tissues because the lactic acid-copper complex has a low  $p^K$  (around 2 to 3). The author induced copper intoxication in

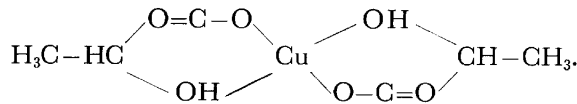
rats by intraperitoneal administration of copper-lactate over a period of 160 days. This paper reports that these animals developed symptoms comparable to Wilson's disease.

#### MATERIALS AND METHODS

Eighty-nine male, inbred Wistar strain rats were used, starting at three weeks of age. The animals were fed Oriental Rat Chow and water *ad libitum*. They were divided into three groups.

Animals in group 1 (N=36) received an intraperitoneal injection of copper-lactate solution (0.15 mg Cu/100g B.W.) daily for over 160 days. Animals in group 2 (N=28) received an injection of isotonic sodium chloride solution daily and were the controls. Animals in group 3 (N=25) were given sodium lactate solution in the same way as copper-lactate was administered in group 1.

Sodium lactate solution was prepared by dissolving 100 ml of 75% lactic acid (Nakarai Chemicals, Co.) in 100 ml of isotonic sodium chloride solution (Fuso Yakuhin Kogyo, Co.) and pH was adjusted to 7.4 with sodium carbonate. The copper-lactate solution was prepared by using lactic acid (Nakarai Chemicals, Co.) and copper chloride (Nakarai Chemicals, Co.): 10 ml of 0.17%  $\text{CuCl}_2 \cdot 2\text{H}_2\text{O}$  solution in 0.15 M HCl was combined with 3.3 ml of 75% lactic acid (4). The pH of the mixture was adjusted to 7.4 with sodium carbonate. Copper combines with lactic acid to form a chelate compound which has the structure of 1 molecule of copper to 2 molecules of lactic acid,



This was found by the continuous variation method. In this experiment, 1 copper molecule to 250 lactic acid molecules was used to suppress free  $\text{Cu}^{2+}$ .

During the experiment, serum copper levels, serum activities of GOT, GPT and ceruloplasmin oxidase, copper-associated serum protein and urinary copper and aminoacids were measured in the morning at 10 day intervals.

The serum was separated from blood obtained by a retrobulbar blood vessel stab with a glass capillary.

The serum copper contents were measured by the Bathocuproine direct method (Sinotest Kenkyugyo, Tokyo, Co.). Ceruloplasmin oxidase activity was measured by Ravin's method (5). GOT and GPT activities were measured by the Sinotest (Sinotest Kenkyugyo, Tokyo, Co.). At 160 days of injection, 10 rats from each group were killed and used for estimation of copper content. The brain, liver and kidney were removed, and the copper contents in these organs were measured by flame photometer. Analysis of copper-associated serum protein was by electrophoresis with cellulose acetate membrane (Separax, Joko Sangyo Co.) using barbital buffer (pH 8.6) at 0.8 mA/cm for 180 min. After electrophoresis the cellulose membrane was cut into halves longitudinally. One half was stained with Ponsow 3R for protein and the other half stained with  $\alpha$ -Benzoin-oxime for copper.

Urine was obtained by the stimulating the abdominal wall with a tweezer. About 0.5-1.0 ml urine was obtained per animal by this method and the urine from each group was collected into a single beaker, with about 30 ml being collected for each group. Urinary copper contents were estimated by the Bathocuproine direct method (Sinotest Kenkyugyo, Co.). For amino acid analysis, urine was centrifuged at 3,000 rpm for 5 min; the pH of the supernatant was adjusted to 6.0-6.5 with diluted acetic acid and boiled at 100°C for 25 min. After cooling, the urine was filtered, and the filtrate was developed at room temperature by the ascending method with butanol-water-acetic acid (4:2:1) for 4 h and the filter paper (Toyo Roshi, Co.) was sprayed with Ninhidrin-n-butanol solution (0.1%) to color.

At the end of the experiment, 20 rats each from group 1, group 2 and group 3 were sacrificed and autopsied. Small pieces of liver, kidney, pancreas, stomach, duodenum, adrenal gland, testis, thyroid gland, brain with pituitary gland, cornea and skin were fixed in phosphate buffered 10% formol (pH 7.0) or pure ethanol. After fixation, the tissues were embedded in paraffin and sectioned. The sections of formol-fixed tissues were stained with H. E. for routine microscope observations. Besides, Perl's reaction for iron, Weigert's stain for elastic fibers and Van Gieson's stain for collagen fibers were also utilized with formol-fixed tissues. Luxol fast blue stain and P.T.A.H. for myelin were also used with formol-fixed brains. Sections of ethanol-fixed tissues were stained with p-dimethylaminobenzylidenerhodanine for copper (rhodanine method) being post-stained with hematoxylin (6). Ethanol-fixed brain tissues were also used for Nissl's staining of nerve cells.

#### RESULTS

Young animals injected daily with copper-lactate solution showed in body weight a lower rate of growth compared to controls injected with saline (Fig. 1.).

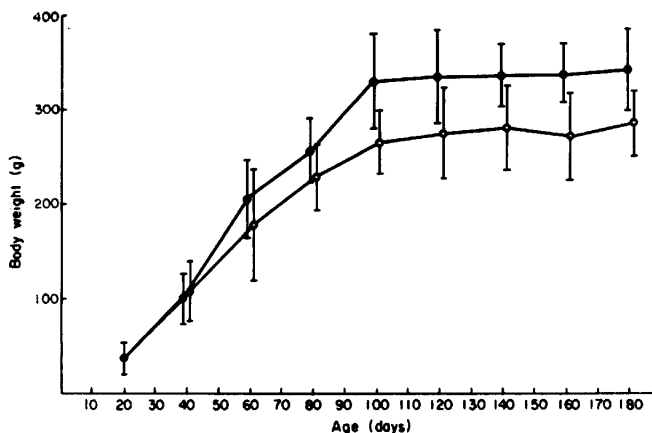


Fig. 1. Body weight ( $M \pm S. D.$ ) of rats treated with copper-lactate (open circles) or saline (solid circles). Each curve is based up on 10 animals. Copper-lactate-treated animals showed suppressed growth.

The serum copper level increased gradually for the first 30 days, but was somewhat lower for the next 30 days until the animals stopped growth at 80–90 days of age (after 60–70 days of copper administration). After full animal growth, the serum copper level began to increase again and reached an extremely high level 500  $\mu\text{g}$  dl after 160 days of copper-administration (Fig. 2). The serum GOT level increased with longer copper-administration (Fig. 3b) and serum GPT

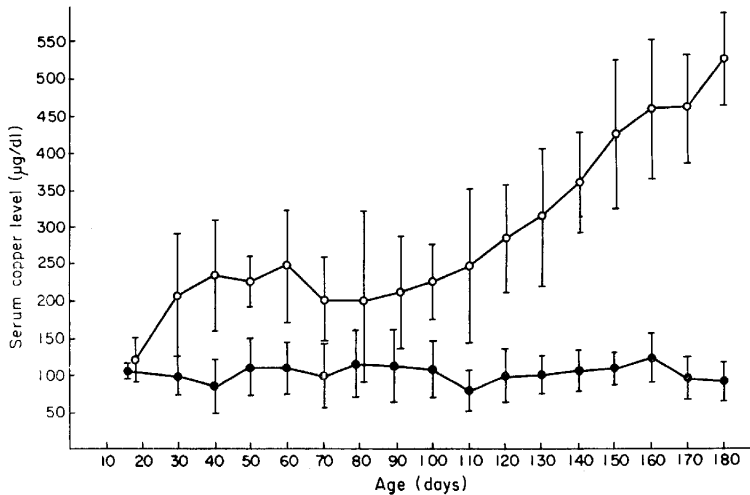


Fig. 2. Serum copper-level ( $M \pm S. D.$ ) in copper-lactate treated rats (open circles,  $N=10$ ) and saline-treated controls (solid circles,  $N=10$ ).

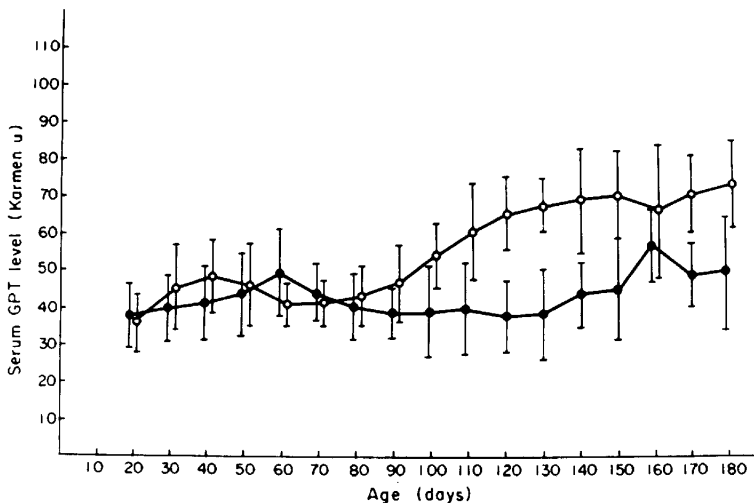


Fig. 3a. Serum GPT activities ( $M \pm S. D.$ ) of rats treated with copper-lactate (open circles,  $N=10$ ) or saline (solid circles,  $N=10$ )

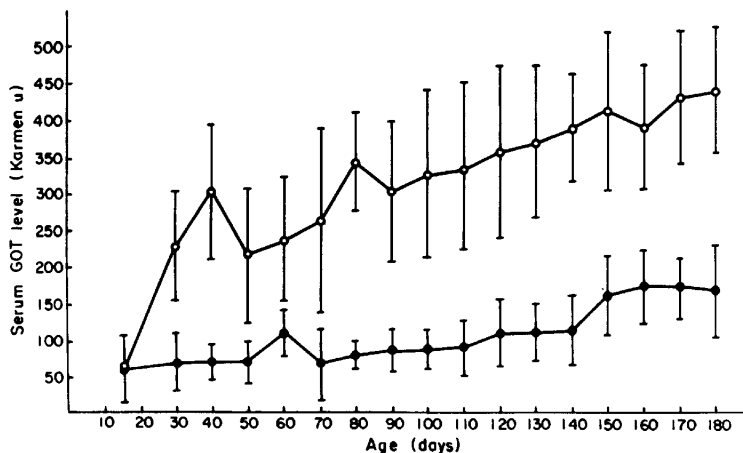


Fig. 3b. Serum GOT activities ( $M \pm S. D.$ ) of rats treated with copper-lactate (open circles,  $N=10$ ) and saline (solid circles,  $N=10$ ).

showed a similar trend although not as clear (Fig. 3a). Observations on hourly serum copper changes after a single intraperitoneal injection of copper-lactate (2.6 mg Cu/100 g B.W.) revealed an increase in the copper-level at one hour after injection to about 6 times the normal level which then decreased gradually reaching the original level 6 h after injection. Animals that received repeated copper-administration for long periods showed high serum copper levels. The injection of copper-lactate into these animals also resulted in a temporary increase in the serum copper level that decreased later. An equilibrium level was reached several hours after injection, but the level was as high as the original level before injection (Fig. 4). Serum electrophoretic pattern from normal and copper-lactate treated rats revealed that copper moved together with albumin (Fig. 5). Paper chromatography of urine after 160 days of copper-administration revealed aminoaciduria with spots for proline, tyrosine, valine,  $\alpha$ -amino- $n_1$ -butyric acid, methionine, phenylalanine, isoleucine and leucine. The urine contained protein at 30 mg/dl.

The autopsies revealed fibrotic peritonitis, cirrhotic liver and slight cloudy swelling in the kidney of animals intraperitoneally injected copper lactate for 160 days. In estimations of copper in various organs, these animals showed more than 100 mg/g, or nearly 40 times the normal level, in liver. Serum, brain and kidney also showed high copper level at about 7 times the control levels. Copper was excreted in urine at 460  $\mu$ g/dl in copper treated animals and at 23  $\mu$ g/dl in controls. The urine test also showed marked proteinuria (30 mg/dl) and aminoaciduria in copper-lactate treated animals. With increased serum copper-levels, the serum ceruloplasmin diamine oxidase activity was

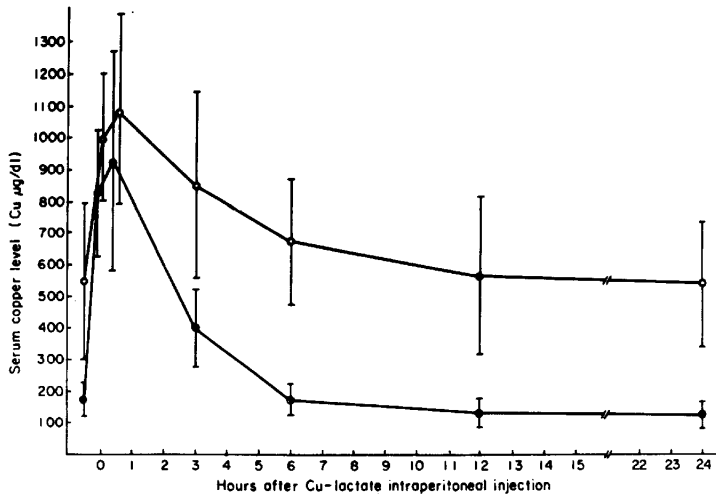


Fig. 4. Hourly changes in serum copper level ( $M \pm S. D.$ ) of rats after intraperitoneal injection of copper-lactate (Cu 2.6 mg/100 g B. W.). Solid circles, after a single intraperitoneal injection, based upon 8 animals. Open circles, after about 160 days of copper-lactate injection, based upon 6 animals.

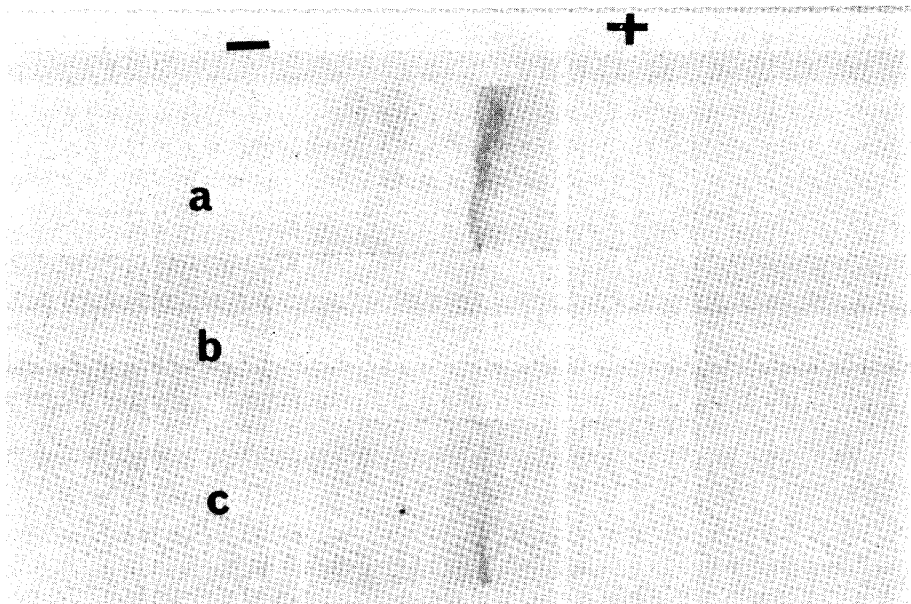


Fig. 5. Serum electrophoretic pattern from normal and copper-lactate treated rats. Serum was obtained 30 min after a single injection of copper-lactate (Cu 2.6 mg/100 g B. W. intraperitoneally). Note that copper moved together with albumin. a. Serum electrophoretic pattern of normal rats. Protein staining with Ponsow 3R. b. Serum electrophoretic pattern from a group 2 rat 30 min after copper-lactate injection, copper-staining with  $\alpha$ -Benzoinoxim (cupron). c. Electrophoretic pattern of the same serum as in "b" but protein staining was with Ponsow 3R.



distinctly reduced in copper-lactate treated animals.

These data are shown in Table 1. Light microscope observations of tissue

TABLE 1. COPPER CONTENTS IN SERUM, BRAIN, LIVER, KIDNEY AND URINE, SERUM CERULOPLASMIN DIAMINE OXIDASE ACTIVITY AND URINARY PROTEIN IN RATS INJECTED DAILY WITH COPPER-LACTATE, SALINE OR SODIUM-LACTATE INTRAPERITONEALLY FOR 160 DAYS.

Treatment	N	Mean copper contents ( $\mu\text{g/g}$ )					Serum ceruloplasmin diamine oxidase activity (Extinction coefficient/dl)	Proteinuria (mg/dl) (Mean)
		Serum (M $\pm$ S.D.)	Brain (Mean)	Liver (Mean)	Kidney (Mean)	Urine $\mu\text{g/dl}$ (Mean)		
Cu-lactate injected	10	580 $\pm$ 96	5.78	109.38	30.05	460	0~18	30
Saline injected	10	124 $\pm$ 14	1.52	2.54	3.62	31.5	20~40	0
Na-lactate injected	10	142 $\pm$ 64	1.40	2.69	4.47	23	20~35	0

*a* Number of rats

sections with H.E. stain (Photos. 1 and 3) disclosed degenerations of liver parenchymal cells with marked fibrosis, tubular necrosis of the kidney, nerve cell degeneration, trigolysis and swelling of brain stem cells (Photo. 5). Histochemical reaction with p-dimethylaminobenzylidenerhodanine (Photos. 2, 4, 6 and 7) revealed granular copper deposition in liver parenchymal cells, in glia cells of the central nervous system and in degenerated tubular epithelial cells of kidneys. The copper in the liver did not show any marked regional density difference, being distributed evenly in the central, intermediate and peripheral areas of the azinus. Kupffer cells had few granules. Descemet's membranes of the eye showed distinct copper deposition, being stained reddish-violet.

Control animals treated with sodium lactate and saline showed no abnormalities in the liver, kidney, pancreas, stomach, duodenum, adrenal gland, testis, thyroid gland, brain, pituitary gland, cornea and skin, in both gross and microscopic observations. The spleens of rats treated with copper-lactate was enlarged slightly from congestion but did not show other specific histologic or histochemical changes. Other organs of rats treated with copper-lactate did not show specific histological or histochemical change.

#### DISCUSSION

This study demonstrated that rats injected intraperitoneally with copper-lactate (total dose of 30 mg copper) during 23 weeks of growth period develop symptoms and histologic changes similar to Wilson's disease in man. Copper was deposited in the liver, kidney, brain stem and cornea. Fibrotic changes in

the liver were distinct, and the animals showed aminoaciduria and proteinuria with increased urinary copper-excretions. This study further suggests that the developmental mechanism of Wilson's disease is closely related to copper-deposition in various organs and tissues. A hereditary defective factor, or factors, may be involved in the abnormal copper metabolism. In this experiment massive copper-introduction of lactate induced Wilson's disease-like symptoms in rats, whereas past animal experiments to induce Wilson's disease by heavy loading of copper have not been successful. Howell loaded copper to rats for over a period of 16 months adding 0.5% copper acetate to diet, but he did not find any copper depositions in the brain or cornea, though the liver and kidney showed heavy depositions of copper (2). It seems that introduction of copper in the form of copper-lactate may be essential for the induction of these symptoms. In the present experiment, however, the copper-intoxication induced by copper-lactate showed one distinct difference from Wilson's disease in that the former has a high serum copper-level but the latter has a strikingly low serum copper-level, though urinary copper excretion is high and serum ceruloplasmin paraphenylene diamine oxidase activity is low in both cases. Similarities to Wilson's disease included low serum copper-level, increased urinary copper excretion and copper accumulation in liver, as in the newborn. The newborn has a high serum lactate level probably because of immature carbohydrate metabolism.

All these observations seem to indicate that some hereditary metabolic abnormality for accumulating lactate or similar substances in serum exists in Wilson's disease and is related to copper-deposition in the liver, as in the fetus.

When copper-complexes with low  $p^k$  (around 2 to 3) are introduced into blood, copper associated with serum albumin, as in the case of copper-lactate injected rats. This keeps copper in serum for a certain period without passage into urine, and makes it easy to pass copper effectively to cells having receptors, as is the case of iron-depositions in the liver of animals injected with ferric nitri-  
lotriacetic acid complex (7).

*Acknowledgment.* The author is much indebted to Professor Satimaru Seno for aid in planning this research and painstaking revision of the paper. Thanks are also due to Dr. M. Awai, Dr. Chao Hui Fang, Dr. M. Mori, Dr. S. Setu, Dr. Y. Yamanoi and Y. Arashima for helpful suggestions and discussion throughout this work.

#### REFERENCES

1. Wilson, S. A. K.: Progressive lenticular degeneration. A familiar nervous disease associated with cirrhosis of the liver. *Brain* **34**, 295-509, 1912.
2. Howell, J. S.: Histochemical demonstration of copper in copper-fed rats and in hepatolenticular degeneration. *J. Pathol. Bacteriol.* **77**, 473-484, 1959.
3. Low, J. A., Pangham, S. R., Worthington, D. and Boston, R. W.: Acid base, lactate, and pyruvate characteristics of the normal obstetric patient and fetus during the intrapartum period. *Am. J. Obstetr. Gynecol.* **120**, 862-867, 1974.

4. Cefola, M., Tompa, A. S., Celiano, A. V. and Gentile, D. S.: Coördination compound, II. Trends in the stability of some rare earth chelates 1. *Inorganic Chem.* **1**, 290-293, 1962.
5. Ravin, H. A.: Rapid test for hepatolenticular degeneration. *Lancet* **1**, 726, 1956.
6. Okinaka, S., Yoshikawa, M., Toyoda, M., Mozai, T., Toyokura, Y. and Kaneyama, M.: Pathogenesis of hepatocerebral disease, II. Histochemical study of copper of liver and brain in Wilson's disease. *A. M. A. Arch. Neurol. Psychiatr.* **72**, 573-578, 1954.
7. Awai, M., Narasaki, M., Yamanoi, Y. and Seno, S.: Induction of diabetes in animals by parenternal administration of ferric Nitritoltriacetate. A model of experiment hemochromatosis. *Am. J. Pathol.* **95**, 663-674, 1979.

### Legends to Photos

Photo. 1. Photomicrograph of a liver section of an animal treated with copper-lactate for 160 days. Fibrosis with lymphocyte infiltration is seen. Note some degenerative damage of parenchymal cells. Hematoxylin-eosin stain.  $\times 100$ .

Photo. 2. Photomicrograph of a liver section of a rat loaded copper-lactate for 160 days, showing heavy copper deposition. Copper is reddish-brown. Note the heavy copper deposition in parenchymal cells located mainly at the pericanalicular-area. Rhodanine method.  $\times 400$ .

Photo. 3. Photomicrograph of a kidney section of a rat loaded with copper-lactate for 160 days. Note the nephrotic changes in tubular epithelial cells. Hematoxlin-eosin stain.  $\times 100$ .

Photo. 4. Photomicrograph of a kidney section of a rat loaded copper-lactate, as in Photo. 3. Copper granules are seen in the tubular epithelial cell, and are stained reddish-brown. Rhodanine method.  $\times 400$ .

Photo. 5. Thalamic nerve cells, showing picnotic changes and swelling with tigrolysis. Rat loaded with copper-lactate for 160 days. Nissl's stain.  $\times 400$ .

Photo. 6. Copper depositions in glia cells of brain stem of a rat loaded with copper-lactate for 160 days. Rhodanine stain.  $\times 400$ .

Photo. 7. Photomicrograph of cornea showing Kayser-Fleischer rings in the same rat as in Photo. 6. Descemet's membrane shows copper depositions being stained diffusely reddish-brown by Rhodanine stain.  $\times 100$ .

