

Acta Medica Okayama

Volume 49, Issue 6

1995

Article 3

DECEMBER 1995

Localization of the glycosaminoglycans in the synovial tissues from osteoarthritic knees.

Keiichiro Nishida*

Hajime Inoue†

Kazukiyo Toda‡

Takuro Murakami**

*Okayama University,

†Okayama University,

‡Okayama University,

**Okayama University,

Localization of the glycosaminoglycans in the synovial tissues from osteoarthritic knees.*

Keiichiro Nishida, Hajime Inoue, Kazukiyo Toda, and Takuro Murakami

Abstract

Localization of the glycosaminoglycans (GAG) was examined in the synovial membranes of patients with osteoarthritis under light microscopy using a fine cationic colloidal iron staining method combined with enzymatic digestion. Our staining method was very useful for demonstrating the difference in the localization of GAG in regions of the inflammatory site in the osteoarthritic synovial membrane. Hyaluronic acid was mainly located in connective tissues in the surface intercellular and perivascular spaces, chondroitin sulfate A/C in the highly fibrous part of and connective tissue around blood vessels, dermatan sulfate (chondroitin sulfate B) in the subsurface interstitium and vascular endothelial cells and heparan sulfate in part of vascular endothelial cells. No keratan sulfate was detected. GAG is reported to have an important role in cell movement, adherence and aggregation in the inflammatory sites. These findings should be useful for understanding the role of GAG in physiological and pathologic processes of secondary synovitis.

KEYWORDS: glycosaminoglycan, synovial tissue, osteoarthritis, fine cationic colloidal iron

*PMID: 8770237 [PubMed - indexed for MEDLINE]

Copyright (C) OKAYAMA UNIVERSITY MEDICAL SCHOOL

Localization of the Glycosaminoglycans in the Synovial Tissues from Osteoarthritic Knees

Keiichiro NISHIDA*, Hajime INOUE, Kazukiyo TODA and Takuro MURAKAMI^a

Department of Orthopaedic Surgery and ^aDepartment of Anatomy, Okayama University Medical School, Okayama 700, Japan

Localization of the glycosaminoglycans (GAG) was examined in the synovial membranes of patients with osteoarthritis under light microscopy using a fine cationic colloidal iron staining method combined with enzymatic digestion. Our staining method was very useful for demonstrating the difference in the localization of GAG in regions of the inflammatory site in the osteoarthritic synovial membrane. Hyaluronic acid was mainly located in connective tissues in the surface intercellular and perivascular spaces, chondroitin sulfate A/C in the highly fibrous part of and connective tissue around blood vessels, dermatan sulfate (chondroitin sulfate B) in the sub-surface interstitium and vascular endothelial cells and heparan sulfate in part of vascular endothelial cells. No keratan sulfate was detected. GAG is reported to have an important role in cell movement, adherence and aggregation in the inflammatory sites. These findings should be useful for understanding the role of GAG in physiological and pathologic processes of secondary synovitis.

Key words: glycosaminoglycan, synovial tissue, osteoarthritis, fine cationic colloidal iron

In osteoarthritis (OA), initial non-inflammatory changes in the articular cartilage precede cartilage destruction at the weight bearing area and it extends to the surrounding cartilage. Damaged cartilage fractions cause secondary synovitis which result in the production of proteases and cytokines and their release into the synovial fluid which contributes to further destruction of the cartilage. Secondary synovitis varies in degree from very mild to severe enough to resemble chronic rheumatoid arthritis (RA). The secondary synovitis often causes

other clinical symptoms to develop such as increased temperature in the joint, hydroarthrosis and restricted range of motion.

Most of the extracellular matrix in the synovial tissue is composed by proteoglycans. Although there are several studies have been done on the localization of glycosaminoglycans (GAG) in RA synovium, few immunohistochemical and moleculo-biological studies have reported on histochemical localization of proteoglycans in the inflammatory synovial membranes (1-3). Wells (2) reported the localization of increased level of hyaluronic acid (HA) in the synovium of patients with arthritis. Recently, Okuda *et al.* (4) reported the distribution of GAG in RA synovium using high and low diamine staining. However, to our knowledge, the distribution of GAG in OA synovial membrane has not been previously reported.

In the present study, the localization of GAG in OA synovium of the knee joint was examined in detail by light microscopy, using a fine cationic colloidal iron staining method combined with various enzyme digestion tests.

Materials and Methods

OA synovium of the knee joint was obtained from 18 patients (3 men and 15 women aged 62-86 years, average 72 years) at operations (14 knees at total knee arthroplasty, 4 knees under knee arthroscopy). As control specimens, normal (non-inflammatory) synovial tissues were obtained from 3 patients at operations (1-year-old man, leiomyosarcoma; 1-year-old girl, clubfoot; 35-year-old woman, anterior cruciate ligament injury). Then they were fixed for about 6 h with 0.1 M cacodylate-buffered 1 % glutaraldehyde and 4 % paraformaldehyde (pH 7.2-7.4). The blocks were embedded in paraffin for light microscopy, and cut into sections 3-4 μ m in thickness.

* To whom correspondence should be addressed.

The sections were dehydrated in a graded series of xylol and ethanol (50 %, 70 %, 95 %, 100 %), and washed in

Table 1 Standard conditions of enzymic digestion

	Buffer	Conc. (U/ml)	Temp (C°)	Time (h)
<i>Streptomyces</i> hyaluronidase	Acetate	100	60	3
Testicular hyaluronidase	K-phosphate buffer	1.0mg/ml	37	3
Chondroitinase ABC	Tris HCl-buffer	1.0	37	2
Chondroitinase B	Tris HCl-buffer	1.0	37	2
Heparitinase	K-phosphate buffer	0.5	37	2
Heparinase	K-phosphate buffer	0.5	37	2
Keratanase	Tris HCl-buffer	1.0	37	2

Conc: Concentration of enzyme solution

Temp: Temperature

distilled water, treated with either routine digestion using degrading enzymes for various GAG, or a double enzymic digestion method (Table 1). The sections were then stained with fine cationic colloidal iron, prepared in advance according to the method of Murakami *et al.* (1986) (5), for 30min or longer at room temperature at pH values of 1.5 or 2.5. After this staining, the sections were rinsed in distilled water, immersed for 10min or longer in a mixture of 1 % $K_4Fe(CN)_6$ and 1 % HCl for the Prussian blue reaction, rinsed in distilled water, post-stained with 0.1 % nuclear fast red in 5 % aluminium sulfate, embedded in balsam, and observed with a light microscope.

Results

Colloidal iron particles were seen as a diffuse blue substance or granules under a light microscope due to positive reaction to Prussian blue. In control specimens, pretreatment with *Streptomyces* hyaluronidase (St-hylase) removed the iron staining almost entirely in the superficial intercellular space, the interstitium below the surface and perivascular regions, suggesting extensive distribution of HA in these areas (Fig. 1).

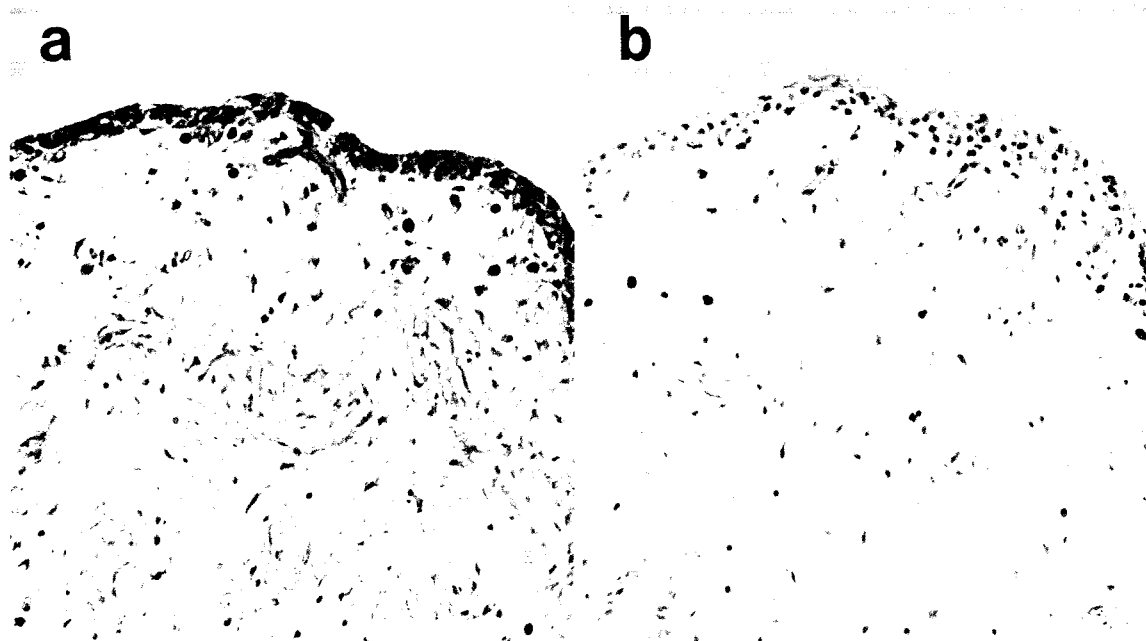


Fig. 1 Normal synovial membrane stained with fine cationic colloidal iron (pH 2.8). (a) Buffer control and (b) *Streptomyces* hyaluronidase digestion.

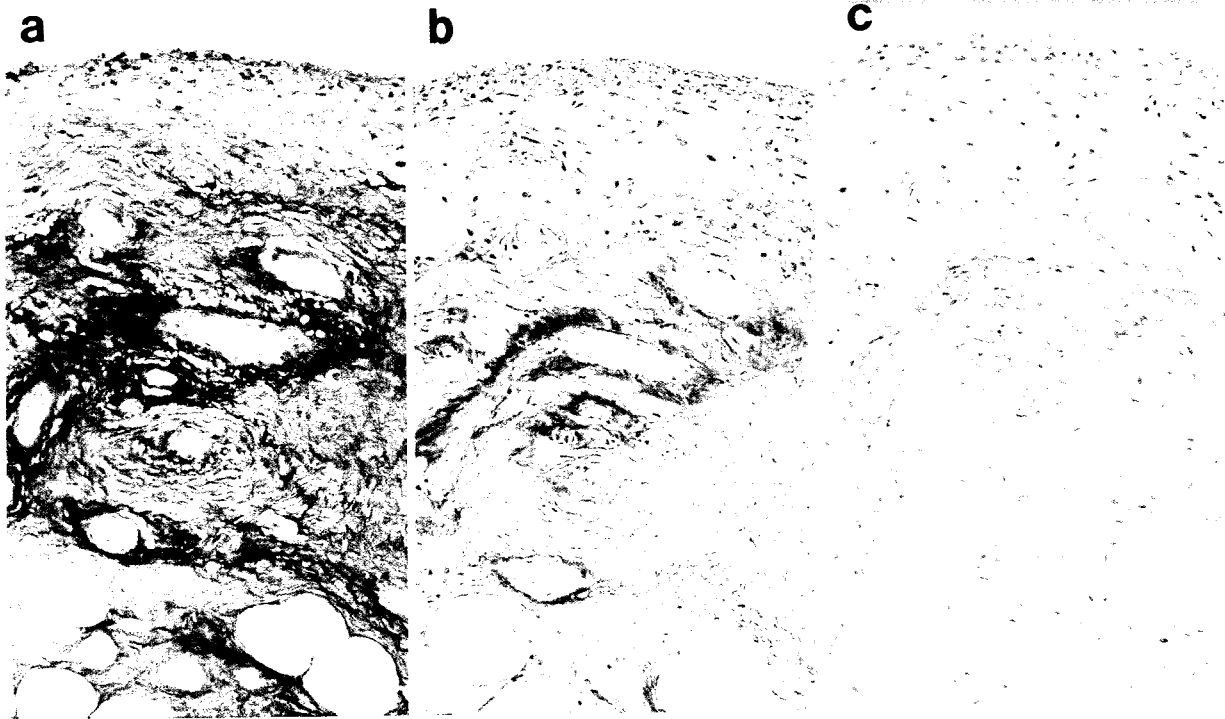


Fig. 2 Staining reactions with fine cationic colloidal iron at different pH values (**a**, 5.0, **b**, 2.8, and **c**, 1.5). Most of the positive reactions observed in the extracellular matrix of the synovial lining cell layer, small vessels and their surrounding matrix, the interstitium of fat tissue and the edematous region below the surface at pH 2.8 were thought to be hyaluronic acid. They do not show positive reactions at pH 1.5.

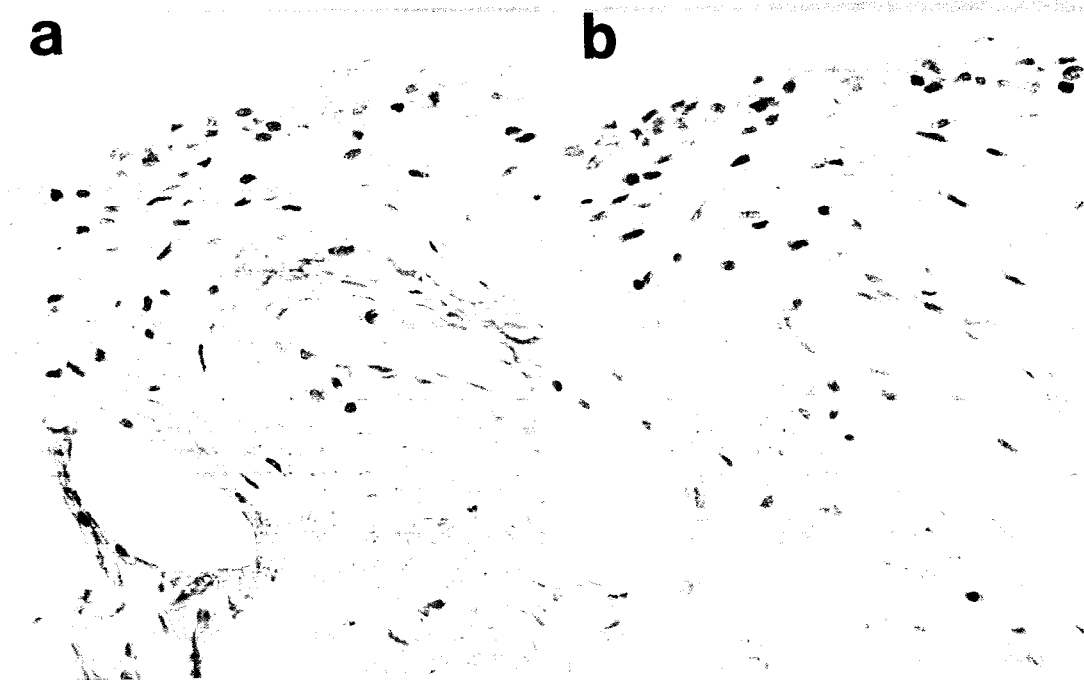


Fig. 3 Synovial membrane with fine cationic colloidal iron (pH 1.5). At pH 1.5, only sulfate groups in glycosaminoglycans (GAG) dissociated and show a positive reaction. (**a**) Buffer control and (**b**) Chondroitinase ABC digestion. The positive reactions observed in the perivascular spaces and the other fibrous areas were lighter than in the buffer control.

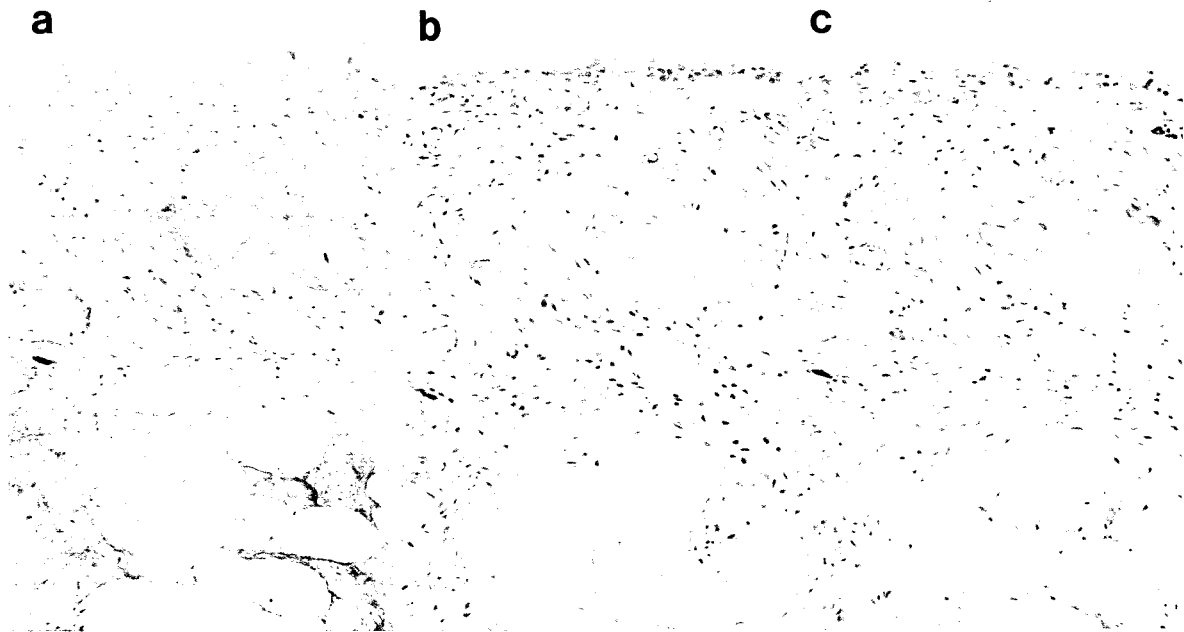


Fig. 4




Fig. 5

Similarly, in OA synovial membranes, diffuse and granular iron stains were observed in the extracellular matrix of the synovial lining cell layer, the interstitium of fat tissue, the edematous region below the surface and perivascular multiple-layered basement membranes at pH value 2.8, and stained much less following the digestion with St-hylase or stained at pH 1.5 (Fig. 2). Compared to the control, the iron staining in the interstitial space below the lining cell layer was less weakened by the enzyme digestion, indicating an increased level of St-hylase-resistant GAG such as CHS-A/C, DS HS which show a positive reaction at pH 1.5.

After treatment with chondroitinase ABC (Chase ABC), the synovial tissue did not react to the colloidal iron staining except for some parts of perivascular regions, indicating the presence of HA, CHS-A/C and DS (Fig. 3).

When the specimens were pretreated with St-hylase and then with Chase B for digestion of DS, the diffuse staining in the subsurface interstitial space and the perivascular staining decreased markedly (Fig. 4). Indications of the presence of CHS-A/C remained only in the highly fibrous part and the perivascular space.

GAG resistant to testicular hyaluronidase (T-hylase) was detected partly on and around vascular endothelial cells. This iron staining was lost to some degree following digestion with Chase B and heparitinase, indicating the presence of DS and HS in this region (Fig. 5).

Discussion

To our knowledge, this is the first report that demonstrate the localization of GAG in OA synovium with use of fine cationic colloidal iron-staining method. Ferric chloride, when boiled with hydrate and cacodylic acid, is converted into a fine cationic iron (ferric hydroxide) colloid which consists of 0.5- to 1.5-nm electron-dense granules, and produces a distinctive Prussian blue reaction. This colloid allows both light and electron microscopic detec-

tion of ionized anionic sites in tissues, including GAG, at a wide pH range of 0.8-7.6 (Murakami *et al.* 1986) (5). The pH value of the staining solution is a very important factor in forming ion bonds between cationic irons and acidic groups of GAG molecules. According to Arnold (1968) (6), most acidic groups are dissociated in tissue proteins, nucleic acids, acid saccharides such as GAG, acid glycoproteins and acid glycolipids at pH 5.0 under histochemical conditions. At pH 2.8, however, carboxyl groups in protein molecules are difficult to dissociate and only acidic groups in nucleic acids and acid saccharides are dissociated. At pH 1.5, only sulfate groups in acid saccharides remain dissociated (Fig. 6). The pH for staining reactions was set at 2.5 for hyaluronic acid and 1.5 for other sulfated GAG.

Iron ions are not absolutely specific to the acid groups in GAG but react also to other acid groups present in the tissue. We resolved this problem by using several mucopolysaccharases before staining. As is generally known, there are a few GAG in the synovial membrane. Although previous studies using human umbilical cord or hyaline cartilage determined the conditions for each enzyme reaction (7-9), relatively shorter enzyme reaction time was appropriate for the small amount of proteoglycans in the synovium. Though the degradability of each enzyme for GAG is well understood, we combined T-hylase plus Chase B and St-hylase plus Chase ABC, B and heparitinase to make the distribution of CHS-A/C, DS and HS, respectively.

Recently, Okuda *et al.* (4) reported the distribution of GAG in RA synovium using high and low diamine staining. RA synovial membrane contained various amounts of each GAG molecular species such as HA, CHS-A/C, DS and HS. From our results, OA synovium also contained various amounts of HA, CHS-A/C, DS and HS. The distribution of GAG in OA synovial tissues were summarized in Table 2. These results that demonstrated the difference in the localization of GAG in regions of the inflammatory site can explain

Fig. 4 Synovial membrane stained with fine cationic colloidal iron (pH 2.8). (a) Buffer control; (b) *Streptomyces* hyaluronidase (St-hylase) digestion; and (c) St-hylase/Chondroitinase B (Chase-B) digestion. The positive reactions remaining after St-hylase digestion in the extracellular matrix of the synovial membrane and small vessels and their surrounding matrix were decreased by Chase-B digestion.

Fig. 5 Synovial membrane stained with fine cationic colloidal iron (pH 1.5). (a) There are a few small vessels that show the positive reactions after testicular hyaluronidase digestion. (b) These reactions were not completely eliminated by Chase-B digestion. (d) Heparitinase digestion. The positive reactions on the endothelial cells were weaker than those of buffer control (c) suggesting the existence of heparan sulfate proteoglycans.

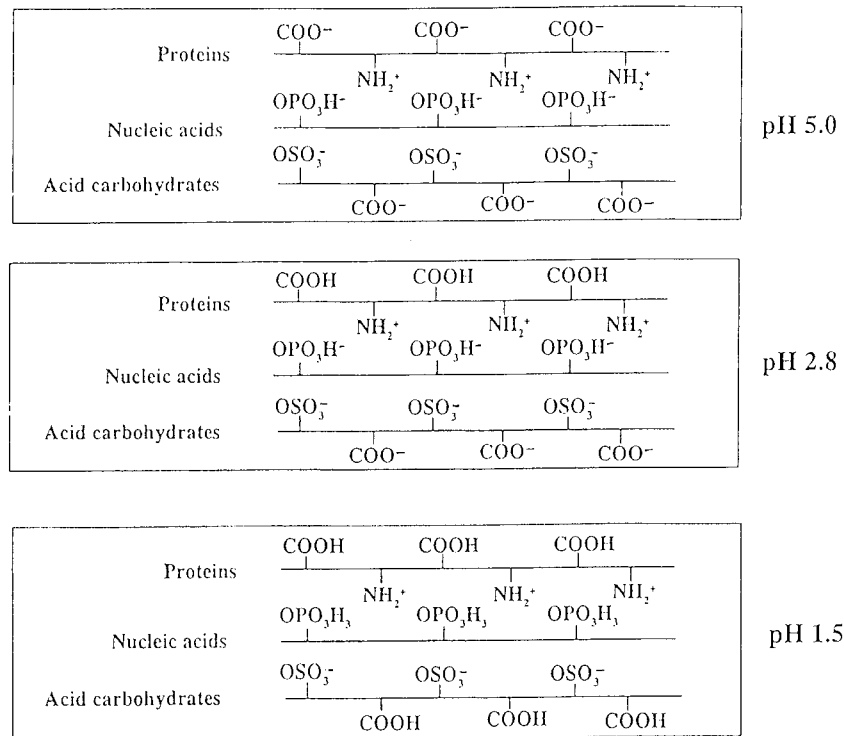


Fig. 6 Dissociation of acidic groups of tissue proteins, nucleic acids, and acid saccharides according to the pH values. Most acidic groups are dissociated in tissue proteins, nucleic acids, acid saccharides such as glycosaminoglycans (GAG), acid glycoproteins and glycolipids at pH 5.0 under histochemical conditions. At pH 2.8, however, carboxyl groups in protein molecules are difficult to dissociate and only acidic groups in nucleic acids and acid saccharides are dissociated. At pH 1.5, only sulfate groups in acid saccharides remain dissociated. The pH for staining reactions was set at 2.8 for hyaluronic acid and 1.5 for other sulfated GAG. Modified from Arnold M (1968) (6).

Table 2 Localization of GAG in osteoarthritic synovial membrane

	Lining cell layer	Extracellular matrix below the surface	Small vessels and its surrounding matrix	Fibrous area
HA	+++	++	++	±
CHS-A/C	-	+	++	++
DS	-	+	±	±
HS	-	-	±~+	-
Hep	-	-	-	-
KS	-	-	-	-

GAG: glycosaminoglycans; HA: hyaluronic acid; CHS-A/C: chondroitin sulfate A/C; DS: dermatan sulfate; Hep-S: heparan sulfate; KS: keratan sulfate; Hep: heparin

one aspect of the pathogenesis of secondary synovitis in osteoarthritis (OA) through immunological and biochemical characteristics of various GAG.

Hyaluronic Acid (HA)

The staining method used in this study can detect anionic sites easily. The results were the same as those of Sawai *et al.* (1994) (10) in which they used immunohistochemical methods. They demonstrated by using HA binding protein that the protein was present in the lining cell layer of the synovium and on fibers in fat tissue of the controls, while the protein was diffusely distributed in OA synovium. However, high concentrations of HA were demonstrated in the intercellular spaces in early RA synovial tissues, suggesting accelerated synthesis of HA. HA became restricted to the surface of the synovium as inflammation progressed and it was almost undetectable in association with fibrosis of the entire region.

HA is generally understood to be produced by synovial B cells in the layer of cells which line the synovial membranes and in the filtered plasma fluid in synovial fluid (11). The concentration of HA in synovial fluid decreases as the severity of the inflammation increases. The

decrease or degradation of HA may cause the destruction of the articular cartilage. In the control specimens, the distribution of HA was diffuse. On the other hand, synovial membranes from OA patients with hydrarthrosis seemed to stain lighter for HA, whereas the heavier staining occurred on and around vascular endothelial cells and basement membranes. This suggests that increased levels of HA might change vascular permeability in hydrate molecular forms, especially through physico-chemical mechanisms. Clinically, the increase of permeability will cause the hydrarthrosis.

Asari *et al.* (1994) (12) reported a decreased concentration of HA in the synovial fluid but the total amount of HA was higher in patients with hydrarthrosis associated with traumatic arthritis (TA) than in healthy controls and TA patients with no hydrarthrosis. They further suggested that destruction of the articular cartilage and the associated release of proteoglycans may cause synovial B cells to produce excess HA, which would increase colloidal osmotic pressure in the joint cavity. Then HA may collect water from plasma and lymph of water when vascular permeability is increased.

Matsubara *et al.* (1987) (13) confirmed that oligosaccharide HA, the product of restricted decomposition of high molecular HA by hyaluronidase, stimulated chemotaxis of endothelial cells *in vitro*. This suggests the possibility that, in the process of inflammation, HA degradation may be restricted to lower molecules and may trigger formation of neovascularization.

Heparan Sulfate Proteoglycan (HSPG)

Many cell proliferating factors recently have been determined to have proteoglycan-binding capacity, and to be involved deeply in both metabolism and active expression of proteoglycans. Basic fibroblast growth factor (bFGF) is known as a potent neovascularization stimulator and it shows high affinity to heparin and binds to HSPG in the extracellular spaces. Takahashi *et al.* (14) found that cultured synovial cells from RA patients produced a greater volume of bFGF than did vascular endothelial cells (15) or inflammatory cells. Since this production was stimulated by IL-1 and TNF-alpha, it was strongly suggested that bFGF may be deeply involved in neovascularization found in synovitis.

Once inflammation or vascular damage occurs, stored bFGF may be released from HSPG in the intercellular matrix around endothelial cells and the released bFGF may induce rapid endothelial cell proliferation and neovascularization.

HSPG are divided into two types: one is found on the cell surface and the other is present in the basement membrane and intercellular matrix. HSPG on the surface of vascular endothelial cells binds MIP-1 beta at its heparin-binding sites and presents it to the MIP-1 beta receptors on T cells. This tethering activates T cell integrin, which further promotes inflammation by attachment to the ligand VCAM-1 on endothelial cells, and migration of the T cells into the tissue (14).

HSPG in the basement membrane of the endothelial cells and on the inner surface of the endothelial cells may be important for neovascularization or inflammatory cell infiltration.

Chondroitin Sulphate Group (CHS A/C and CHS B)

In OA synovium, inflammation is not as severe compared with RA synovium. Recently, Okuda *et al.* (4) reported that, in the inflammatory areas of RA synovium, the molecular species of GAGs was primarily DS and it was CHS-A/C in the fibrotic areas. Kimata *et al.* (1986) (16) isolated PG-M for the first time from mesenchymatous tissue of a limb bud of chicken embryos in the stage immediately before the start of cartilage differentiation. This large proteoglycan is equivalent to versican, which is synthesized by human fibroblasts and has been demonstrated to have an inhibiting effect on cell adhesion. According to Kimata *et al.* (16), GAG chains, such as CHS-A/C and D may have cell adhesion inhibiting action but can express such activity only in the molecular mold of proteoglycans. Diffuse CHS A/C detected in the synovial membrane may be produced by mesenchymal cells of vascular origin, and seems to help inflammatory cells to migrate or move easily in the matrix via cell-adhesion inhibitory action.

Iizuka (1971) (17) reported a qualitative increase of DS in cerebral arteriosclerotic sites and a relative increase of DS in the aorta. DS detected in perivascular spaces and vascular endothelial cells in the surface of the synovial membrane may exert its anti-coagulation activity, and help to stimulate fibrosis of blood vessels in the late stage of inflammation.

Other Anionic Sites in the Synovial Membrane

The nucleus of synovial lining cells and other inflammatory cells appeared to be stained, indicating the possible presence of phosphates. The granules in mast cells showed strongly positive Prussian blue reaction and they were not digested in any enzyme tests that we used

in this study, suggesting that mast cell granules largely contain heparins.

In conclusions, fine cationic colloidal iron staining was useful to detect anionic sites in the synovial membrane by light microscopy. HA, CHS-A/C, DS and HS were in the OA synovial membrane. HA was mainly located in connective tissues in surface intercellular and perivascular spaces. CHS-A/C was found mainly in the highly fibrous parts and connective tissue around blood vessels, DS was in the subsurface interstitium and vascular endothelial cells, and HS was confined to parts of vascular endothelial cells. Keratan sulphate was not detected.

References

1. Shinmei M: Biochemical studies of acidic glycosaminoglycans in rheumatoid arthritis. *J Jpn Orthop Assoc* (1972) **46**, 1139-1156 (in Japanese).
2. Wells AF, Klareskog L, Lindblad S and Laurent TC: Correlation between increased hyaluronan localize in arthritic synovium and the presence of proliferating cells: A role for macrophage-derived factors. *Arthritis Rheum* (1992) **35**, 391-396.
3. Worrall JG, Bayliss MT and Edwards JCW: Morphological localization of hyaluronan in normal and diseased synovium. *J Rheumatol* (1991) **18**, 1466-1472.
4. Okuda T: A histochemical study on the acidic glycoconjugates of the synovial membrane in rheumatoid arthritis. *J Jpn Orthop Assoc* (1994) **68**, 196-206 (in Japanese).
5. Murakami T, Taguchi T, Ohotsuka A, Sano K, Kaneshige T, Owen RL and Jones AL: A modified method of fine-granular cationic iron colloid preparation: Its use in light and electron microscopic detection of anionic sites in the rat kidney glomerulus and certain other tissues. *Arch Histol Jpn* (1986) **49**, 13-23.
6. Arnold M: *Histochemie*, Springer-Verlag, Heidelberg, New York (1968) p36.
7. Kanazawa K and Hirabayashi Y: Histochemical differentiation of acid mucopolysaccharides: Using AMPS-degrading enzymes and sialidase. *Connect Tissue* (1974) **6**, 17-37 (in Japanese).
8. Yamada K and Hoshino M: A reliable method for the electron microscopic demonstration of connective tissue acid mucosaccharides. *Connect Tissue* (1973) **5**, 15-28 (in Japanese).
9. Yamada K: The effect of digestion with *Streptomyces hyaluronidase* upon certain histochemical reactions of hyaluronic acid-containing tissues. *Histochem Cytochem* (1973) **21**, 794-803.
10. Sawai T and Uzuki M: Histopathological analysis of rheumatoid arthritis developing from beginning to joint destruction. *Clin Exp Med (Igaku no Ayumi)* (1992) **161**, 575-579 (in Japanese).
11. Gardner DL: Cells and matrix; in *Pathological Basis of the Connective Tissue Diseases*. Edward Arnold, London (1992) pp35-99.
12. Asari A, Miyauchi S, Sekiguchi T, Machida A, Kuriyama S, Miyazaki K and Namiki O: Hyaluronan, cartilage destruction and hydrarthrosis in traumatic arthritis. *Osteoarthritis Cartilage* (1994) **2**, 79-89.
13. Matsubara M and Ziff M: Basement membrane thickening of postcapillary venules and capillaries in rheumatoid synovium. *Arthritis Rheum* (1987) **30**, 18-30.
14. Takahashi N, Marui T and Matsubara T: Inflammation and angiogenesis. *Blood Vessel Endothel* (1992) **2**, 456-462 (in Japanese).
15. Schweigerer L, Neufeld G, Friedmen J, Abraham JA, Fiddes JC and Gospodarowicz D: Capillary endothelial cells express basic fibroblast growth factor, a mitogen that promotes their own growth. *Nature* (1987) **325**, 257-259.
16. Kimata K, Oike Y, Tani K, Shinomura T, Yamagata M, Uritani M and Suzuki S: A large chondroitin sulphate proteoglycan (PG-M) synthesized before chondrogenesis in the limb bud of chick embryo. *J Biol Chem* (1986) **261**, 13517-13525.
17. Iizuka K: Effects of acid mucopolysaccharides extracted from vascular connective tissue on thrombus formation. *Connect Tissue* (1971) **3**, 15-29 (in Japanese).

Received September 11, 1995; accepted October 9, 1995.