

# *Acta Medica Okayama*

---

*Volume 60, Issue 3*

2006

*Article 9*

JUNE 2006

---

## Disappearance of diabetic macular hard exudates after hemodialysis introduction.

Toshihiko Matsuo\*

\*Okayama University,

Copyright ©1999 OKAYAMA UNIVERSITY MEDICAL SCHOOL. All rights reserved.

# Disappearance of diabetic macular hard exudates after hemodialysis introduction.\*

Toshihiko Matsuo

## Abstract

We report herein the disappearance of macular hard exudates after the introduction of hemodialysis in diabetic patients. A 62-year-old woman and a 52-year-old man with diabetes mellitus showed hard exudates in the macula of the left eyes. Both patients had previously undergone panretinal photocoagulation in both eyes. During the follow-up, hemodialysis was introduced for deteriorating chronic renal failure caused by diabetic nephropathy. Half a year later, macular hard exudates in the left eyes disappeared dramatically in both patients, but the visual acuity remained the same. No additional laser treatment was done during the observation period. Hemodialysis is considered to have accelerated the resolution of macular hard exudates in both patients. The deposition of macular hard exudates in diabetic patients is due in part to concurrent poor renal function.

**KEYWORDS:** hemodialysis, diabetic retinopathy, hard exudates, macular edema

---

\*PMID: 16838050 [PubMed - indexed for MEDLINE]

Copyright (C) OKAYAMA UNIVERSITY MEDICAL SCHOOL

Case Report

## Disappearance of Diabetic Macular Hard Exudates after Hemodialysis Introduction

Toshihiko Matsuo\*

*Department of Ophthalmology, Okayama University Graduate School of Medicine, Dentistry and Pharmaceutical Sciences, Okayama 700-8558, Japan*

We report herein the disappearance of macular hard exudates after the introduction of hemodialysis in diabetic patients. A 62-year-old woman and a 52-year-old man with diabetes mellitus showed hard exudates in the macula of the left eyes. Both patients had previously undergone panretinal photocoagulation in both eyes. During the follow-up, hemodialysis was introduced for deteriorating chronic renal failure caused by diabetic nephropathy. Half a year later, macular hard exudates in the left eyes disappeared dramatically in both patients, but the visual acuity remained the same. No additional laser treatment was done during the observation period. Hemodialysis is considered to have accelerated the resolution of macular hard exudates in both patients. The deposition of macular hard exudates in diabetic patients is due in part to concurrent poor renal function.

**Key words:** hemodialysis, diabetic retinopathy, hard exudates, macular edema

Macular hard exudate deposition is a sight-threatening consequence of macular edema in patients with diabetes mellitus [1]. In this study, macular hard exudates disappeared in 2 patients with diabetes mellitus after the introduction of hemodialysis.

### Case Report

**Case 1.** A 59-year-old woman with a 10-year history of diabetes mellitus was first seen at Okayama University Hospital in December 1997. Diabetes was controlled with oral glibenclamide 1.25 mg daily, and hypertension was controlled with temocapril 2 mg daily. The patient underwent pan-

retinal photocoagulation in both eyes at another hospital in May 1997. Her best-corrected visual acuity was 0.2 in the right eye and 0.05 in the left eye. She had diffuse macular edema in the right eye and massive hard exudates in the macula of the left eye. In March 1998, she underwent vitrectomy combined with cataract surgery for diffuse macular edema in the right eye and then cataract surgery alone in the left eye. Her best-corrected visual acuity was 0.7 in the right eye and 0.1 in the left eye. In November 2000, the patient began to undergo hemodialysis twice a week for chronic renal failure resulting from diabetic nephropathy (Table 1). Recombinant human erythropoietin (epoetin beta) was used. In May 2001, half a year after the start of hemodialysis, she showed no hard exudates in the macula of the left eye (Fig. 1). The visual acuity in the left eye remained the same. No additional laser treatment was performed after the start of hemodialysis.

Received October 17, 2005; accepted January 17, 2006.

\*Corresponding author. Phone: +81-86-235-7297; Fax: +81-86-222-5059  
E-mail: matsuo@cc.okayama-u.ac.jp (T. Matsuo)

Table 1 Laboratory data in two patients before and after the introduction of hemodialysis

	Case 1		Case 2	
	August 2000#	May 2001 (under hemodialysis)	January 1999#	October 1999 (under hemodialysis)
Total protein (g/dL)	4.88	5.28	5.20	5.57
Albumin (g/dL)	2.65	2.85	2.96	3.10
Total cholesterol (mg/dL)	219	229	229	201
Creatinine (mg/dL)	5.1	N.A.	4.36	N.A.
Urea nitrogen (mg/dL)	36.3	N.A.	40.0	N.A.
24-hour creatinine clearance (L/day)	9.1	N.A.	9.4	N.A.
Red blood cells ( $\times 10^6$ /microL)	2.95	3.33	2.84	3.74
Hemoglobin (g/dL)	9.9	10.7	9.0	10.9
Hemoglobin A1c (%)	6.6	6.3	6.3	6.5
Blood pressure (mmHg)	154/94	160/90	162/100	176/90

#Before the introduction of hemodialysis. N.A., not applicable under hemodialysis.

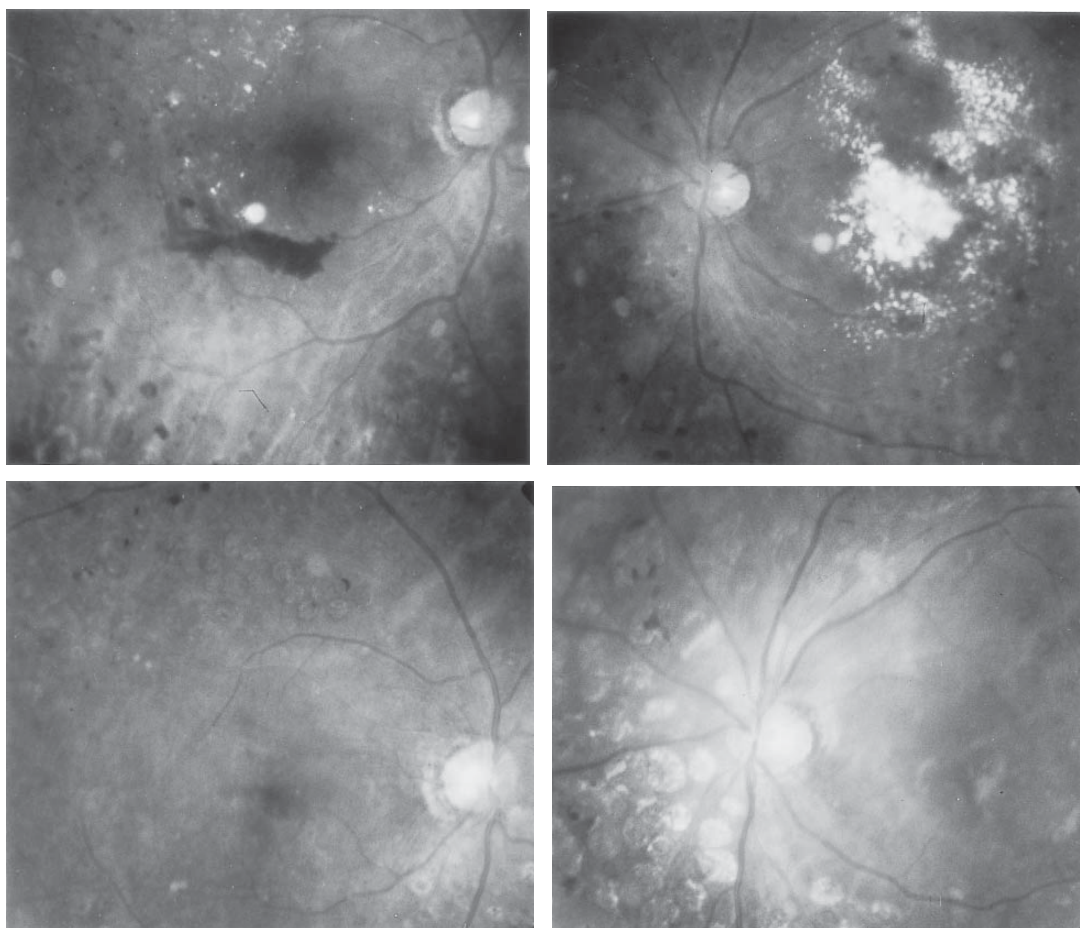


Fig. 1 Case 1. Fundus photographs in the right eye (left column) and left eye (right column) before the introduction of hemodialysis (top, November 2000) and half a year after the start of hemodialysis (bottom, May 2001). The macular hard exudates in the left eye have almost disappeared after half a year, even with no laser treatment.

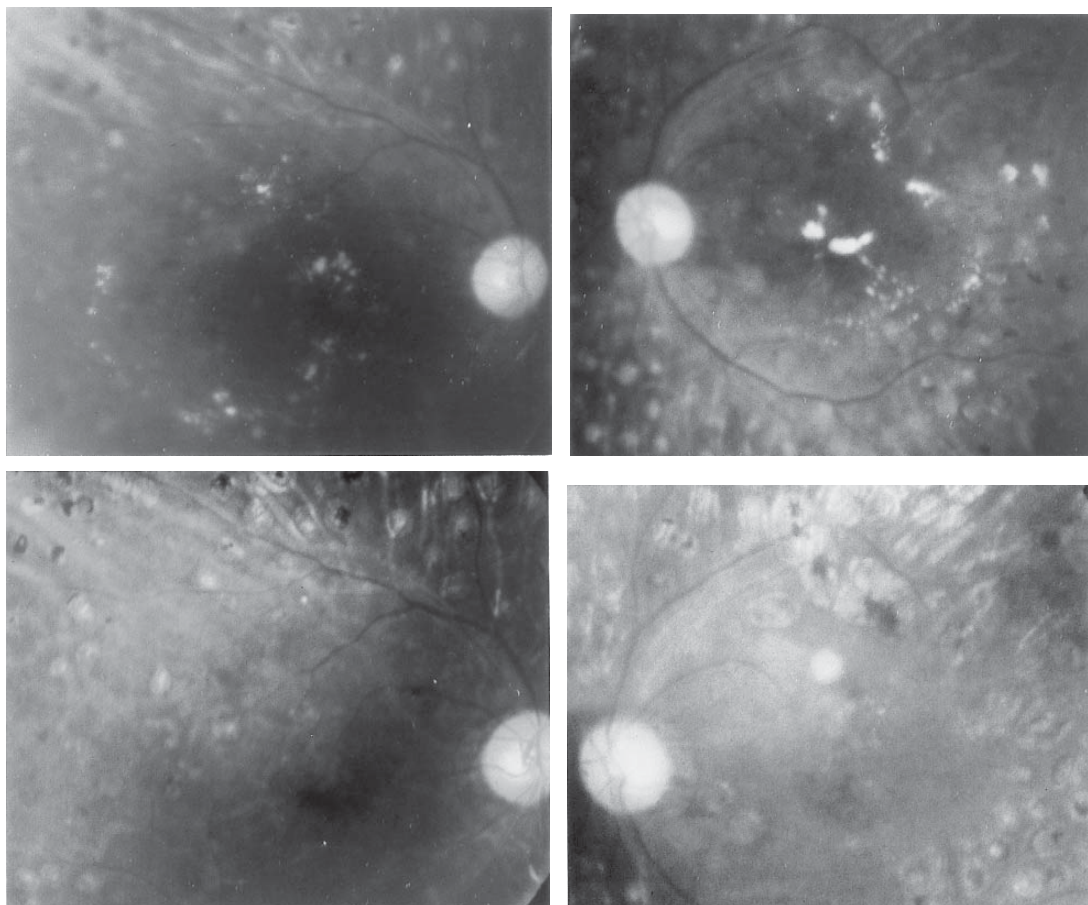


Fig. 2 Case 2. Fundus photographs in the right eye (left column) and left eye (right column) before the introduction of hemodialysis (top, April 1999) and half a year after the start of hemodialysis (bottom, October 1999). The macular hard exudates in the left eye have almost disappeared after half a year, even with no laser treatment.

**Case 2.** A 51-year-old man with a 15-year history of diabetes mellitus was first seen at Okayama University Hospital in June 1998. Diabetes was controlled well with diet, and hypertension was controlled with amlodipine besilate 5 mg daily and temocapril 2 mg daily. The patient underwent panretinal photocoagulation in both eyes in 1996, and underwent vitrectomy combined with cataract surgery for vitreous hemorrhage in the left eye in January 1998 at another hospital. His best-corrected visual acuity was hand movement in the right eye and 0.1 in the left eye. Vitreous hemorrhage prevented visualization of the right fundus, while the left eye had macular hard exudates. In July 1998, the patient underwent vitrectomy combined with cataract surgery, and he gained visual acuity of 1.0 in the right eye. In

April 1999, he began undergoing hemodialysis 3 times a week for chronic renal failure caused by diabetic nephropathy (Table 1). Recombinant human erythropoietin (epoetin beta) was used. The macular hard exudates in the left eye apparently decreased in October 1999, half a year after the start of hemodialysis (Fig. 2). The visual acuity in the left eye remained the same. No additional laser treatment was applied to the macular area in the left eye during follow-up.

### Discussion

Serum lipid-lowering has been known to reduce hard exudates in diabetic retinopathy [2-5]. Treatment with cholesterol synthesis inhibitors [2,



4, 5], heparin-induced extracorporeal LDL-precipitation [3], and plasmapheresis [4] have been reported to induce the resolution of hard exudates. In the present study, the 2 patients were followed in a 3-month to 6-month interval, and macular hard exudates in the left eyes of both patients disappeared dramatically in half a year after the introduction of hemodialysis.

Both patients had received panretinal photocoagulation about 3 years previous to the introduction of hemodialysis and had not undergone additional laser applications. For the right eyes, both patients had undergone vitrectomy relatively recently. In contrast, for the left eyes, Case 1 had cataract surgery only while Case 2 had previously undergone vitrectomy. In general, macular edema and hard exudates do regress spontaneously, particularly in eyes which have had panretinal photocoagulation [6] and/or vitrectomy [7-12]. The resolution of macular hard exudates in the right eyes of both patients might, therefore, have been the consequence of recent vitrectomy. Other factors, however, must be considered as a cause of hard exudate resolution, especially in the left eye of Case 1, which had not undergone vitrectomy. Furthermore, macular hard exudate regression in the left eye of Case 2 could not necessarily be attributed to vitrectomy alone, which had been performed almost 2 years previously.

Before the start of hemodialysis, the patients were in a state of chronic renal failure and in the lower threshold of renal function, as evidenced by 24-hour endogenous creatinine clearance of less than 10 L/day (Table 1). They had high levels of serum creatinine and urea nitrogen as well as abnormal levels of electrolytes (Table 1). Diabetes mellitus was relatively well controlled in both patients, as indicated by the 6% levels of hemoglobin A1c (Table 1), although the index is not completely reliable in the presence of anemia and with the use of erythropoetin. The patients neither took oral lipid-lowering drugs nor showed higher levels of serum cholesterol before and after the introduction of hemodialysis (Table 1). The regression of macular hard exudates in these patients could, therefore, be attributed in part to the normalization of blood constituents after the introduction of hemodialysis rather than to the lipid-lowering effect, as described in previous studies [2, 4, 5]. Another mechanism for macular hard exudate

resolution is the improved function of retinal vascular cells and retinal pigment epithelial cells in response to hemodialysis, contributing to normalization of the blood-retinal barrier. Such changes, in turn, might lead to better control of vascular permeability and then to the regression of macular hard exudates.

Until now, hemodialysis has been thought to improve diabetic macular edema in a few selected cases [13, 14]. More recently, however, hemodialysis has been shown to be ineffective in improving macular leakage on fluorescein angiography 4 weeks after the beginning of hemodialysis in a prospective study involving 22 diabetic patients [15]. These studies have attempted to record the change in macular edema, but not in macular hard exudates. Macular hard exudates are the consequence of macular edema, but are not necessarily in temporal association with macular edema. Macular hard exudates would remain even after the resolution of macular edema, as shown in the present series of patients. One reason for the failure in improving macular edema in the previous study [15] would be the short, 4-week observation period after the beginning of hemodialysis. In contrast, the 2 patients in this study showed the resolution of macular hard exudates half a year after the beginning of hemodialysis. Unfortunately, the course of the resolution remains unknown in the present patients since they were not seen during the half-year period after the introduction of hemodialysis.

In conclusion, the deposition of macular hard exudates in diabetic patients is due in part to concurrent poor renal function. Other systemic factors such as renal hypertension and nephrotic hypoproteinemia must also be considered as underlying causes. Because of the multifactorial nature of the condition, further observation with additional cases is necessary to establish a causal relationship between hemodialysis and hard exudate resolution.

## References

1. Ferris FL III and Patz A: Macular edema: a complication of diabetic retinopathy. *Surv Ophthalmol* (1984) 28 (Suppl): 452-461.
2. Gordon B, Chang S, Kavanagh M, Berrocal M, Yannuzzi L, Robertson C and Drexler A: The effects of lipid lowering on diabetic retinopathy. *Am J Ophthalmol* (1991) 112: 385-391.
3. Janknecht P, Schumann M and Hansen LL: Reduction of retinal

- exudates in diabetic retinopathy after heparin-induced extracorporeal LDL-precipitation (HELP). A case report. *Eur J Ophthalmol* (1996) 6: 340-342.
4. Cusick M, Chew EY, Chan CC, Kruth HS, Murphy RP and Ferris FL III: Histopathology and regression of retinal hard exudates in diabetic retinopathy after reduction of elevated serum lipid levels. *Ophthalmology* (2003) 110: 2126-2133.
  5. Gupta A, Gupta V, Thapar S and Bhansali A: Lipid-lowering drug atorvastatin as an adjunct in the management of diabetic macular edema. *Am J Ophthalmol* (2004) 137: 675-682.
  6. Rohrschneider K, Bultmann S, Gluck R, Kruse FE, Fendrich T and Volcker HE: Scanning laser ophthalmoscope fundus perimetry before and after laser photocoagulation for clinically significant diabetic macular edema. *Am J Ophthalmol* (2000) 129: 27-32.
  7. Ikeda T, Sato K, Katano T and Hayashi Y: Vitrectomy for cystoid macular oedema with attached posterior hyaloid membrane in patients with diabetes. *Br J Ophthalmol* (1999) 83: 12-14.
  8. Pendergast SD, Hassan TS, Williams GA, Cox MS, Margherio RR, Ferrone PJ, Garretson BR and Trese MT: Vitrectomy for diffuse diabetic macular edema associated with a taut premacular posterior hyaloid. *Am J Ophthalmol* (2000) 130: 178-186.
  9. Yamamoto T, Akabane N and Takeuchi S: Vitrectomy for diabetic macular edema: the role of posterior vitreous detachment and epimacular membrane. *Am J Ophthalmol* (2001) 132: 369-377.
  10. Otani T and Kishi S: A controlled study of vitrectomy for diabetic macular edema. *Am J Ophthalmol* (2002) 134: 214-219.
  11. Sato Y, Lee Z and Shimada H: Vitrectomy for diabetic cystoid macular edema. *Jpn J Ophthalmol* (2002) 46: 315-322.
  12. Massin P, Duguid G, Erginay A, Haouchine B and Gaudric A: Optical coherence tomography for evaluating diabetic macular edema before and after vitrectomy. *Am J Ophthalmol* (2003) 135: 169-177.
  13. Bresnick GH: Diabetic maculopathy. A critical review highlighting diffuse macular edema. *Ophthalmology* (1983) 90: 1301-1317.
  14. Perkovich BT and Meyers SM: Systemic factors affecting diabetic macular edema. *Am J Ophthalmol* (1988) 105: 211-212.
  15. Tokuyama T, Ikeda T and Sato K: Effects of haemodialysis on diabetic macular leakage. *Br J Ophthalmol* (2000) 84: 1397-1400.