

Acta Medica Okayama

Volume 49, Issue 1

1995

Article 3

FEBRUARY 1995

Immunohistochemical studies of PIVKA-II in hepatocellular carcinoma by indirect immunofluorescence

Naoaki Kuwahara*

Toshihiro Higashi†

Kazuhiro Nouso‡

Toshio Ito**

Takao Tsuji††

*Okayama University,

†Okayama University,

‡Okayama University,

**Okayama University,

††Okayama University,

Immunohistochemical studies of PIVKA-II in hepatocellular carcinoma by indirect immunofluorescence*

Naoaki Kuwahara, Toshihiro Higashi, Kazuhiro Nouse, Toshio Ito, and Takao Tsuji

Abstract

Tissue PIVKA-II was examined in 32 hepatocellular carcinomas and 2 metastatic liver tumors using indirect immunofluorescence, and the results were compared with the size, histological grading and serum PIVKA-II level. The specificity of this method was confirmed by the disappearance of reactivity in PLC/PRF/5 cells after the addition of vitamin K to the culture medium. Positive PIVKA-II staining was observed as a clustered or a single cell pattern only in the HCC nodules, but not in the surrounding cirrhotic tissue. PIVKA-II staining was observed in all HCC groups regardless of histological grade. There was no relationship between PIVKA-II staining and the size of HCC. PIVKA-II was detected immunohistochemically even in small HCC of patients whose plasma PIVKA-II levels were below the detection limit. These results suggest that PIVKA-II production is a specific phenotype of HCC regardless of its histological grading and demonstrate that this immunofluorescent PIVKA-II staining is more sensitive and useful than plasma PIVKA-II assay for the diagnosis of HCC.

KEYWORDS: hepatocellular carcinoma, PIVKA-II immunofluorescent staining, tumor marker

*PMID: 7762405 [PubMed - indexed for MEDLINE]

Copyright (C) OKAYAMA UNIVERSITY MEDICAL SCHOOL

Immunohistochemical Studies of PIVKA-II in Hepatocellular Carcinoma by Indirect Immunofluorescence

Naoaki KUWAHARA, Toshihiro HIGASHI*, Kazuhiro NOUSO, Toshio ITO and Takao TSUJI

First Department of Internal Medicine, Okayama University Medical School, Okayama 700, Japan

Tissue PIVKA-II was examined in 32 hepatocellular carcinomas and 2 metastatic liver tumors using indirect immunofluorescence, and the results were compared with the size, histological grading and serum PIVKA-II level. The specificity of this method was confirmed by the disappearance of reactivity in PLC/PRF/5 cells after the addition of vitamin K to the culture medium. Positive PIVKA-II staining was observed as a clustered or a single cell pattern only in the HCC nodules, but not in the surrounding cirrhotic tissue. PIVKA-II staining was observed in all HCC groups regardless of histological grade. There was no relationship between PIVKA-II staining and the size of HCC. PIVKA-II was detected immunohistochemically even in small HCC of patients whose plasma PIVKA-II levels were below the detection limit. These results suggest that PIVKA-II production is a specific phenotype of HCC regardless of its histological grading and demonstrate that this immunofluorescent PIVKA-II staining is more sensitive and useful than plasma PIVKA-II assay for the diagnosis of HCC.

Key words: hepatocellular carcinoma, PIVKA-II, immunofluorescent staining, tumor marker

In 1968, Hemker and Muller (1) reported an abnormal prothrombin in the plasma of patients treated with anticoagulation drugs such as warfarin. After this report, the abnormal prothrombin produced by the absence of vitamin K was referred to as PIVKA (protein induced by vitamin K absence or antagonists). In 1974, Stenflo and Suttie (2) reported that the coagulation factors dependent on vitamin K were synthesized in the liver.

Pre-prothrombin has 10 glutamic acid (Glu) residues. These residues are converted to γ -carboxylglutamic acid

(Gla) residues by carboxylation under normal conditions, and vitamin K acts as a cofactor in the carboxylation process. When anti-vitamin K drugs or dysfunction of liver cells produce a deficiency of vitamin K, the carboxylation process of pre-prothrombin is disturbed and abnormal prothrombin accumulates in the plasma.

In 1983, Liebman HA *et al.* (3) first reported that PIVKA-II was a new tumor marker for hepatocellular carcinoma (HCC). They measured plasma abnormal prothrombin in 76 patients with HCC, and found that 67 (91%) showed plasma des- γ -carboxy prothrombin, while this prothrombin was not detected in patients with chronic hepatitis, liver cirrhosis or metastatic liver cancers. PIVKA-II was thereafter confirmed as a tumor marker for HCC (4-6) and was widely used to assess the effectiveness of various treatments, such as surgery, transcatheter arterial embolization, or percutaneous ethanol injection therapy. Furthermore, no relationship between the plasma levels of PIVKA-II and α -fetoprotein (AFP) has been confirmed (7-9). Therefore, the diagnostic rate for HCC is increased after both tumor markers are examined routinely (10).

Staining of PIVKA-II in HCC tissues has been reported in several investigations, in each of which the following results were observed: PIVKA-II positive cells were observed in not only HCC nodules but also the surrounding cirrhotic tissue (11); PIVKA-II was more strongly stained in well differentiated HCC than in poorly differentiated HCC (12). In another report, paradoxically, there was no relationship between positive staining for PIVKA-II and the histological grade of HCC (13).

To clarify the relationship between histological grade of HCC and PIVKA-II positivity, we analyzed PIVKA-II production using freshly frozen samples by indirect immunofluorescent staining.

* To whom correspondence should be addressed.

Materials and Methods

Anti-PIVKA-II mouse monoclonal antibody (anti-PIVKA-II) was supplied by Eisai Co. Ltd., (Tokyo, Japan). Fluorescein isothiocyanate (FITC)-labeled rabbit anti-mouse IgG was purchased from DAKO (Copenhagen, Denmark). Two cultured HCC cell lines, PLC/PRF/5 and huH-7, were obtained from the Japanese Cancer Resources Bank (JCRB). PLC/PRF/5 cells were cultured in Dulbecco's modified Eagle's minimal essential medium containing 10% fetal bovine serum until they became confluent. To suppress PIVKA-II production, vitamin K (1 μ g/ml) was added to the medium, and the cells were cultured for 1 week until they became confluent. PIVKA-II staining was performed in monolayer cultured cells on covered glasses before and after the vitamin K addition to confirm the specificity. The huH-7 cells were cultured in the same way.

Autopsy specimens were obtained within 2-3h after death, embedded in the Tissue-Tek O.C.T., frozen in dry iced-acetone solution, and were preserved at -80°C until use. Specimens obtained by the ultrasound-guided tumor biopsy with a 21-gauge needle (Majima needle, Top, Japan) were stored under the same conditions.

The tested materials included 16 autopsy specimens (15 HCC and 1 liver metastasis of colon cancer), 15 specimens obtained by the ultrasound-guided tumor biopsy (14 HCC and 1 liver metastasis of gastrinoma), and 3 operated HCC specimens. The subjects of this investigation consisted of 2 patients with well differentiated, 18 moderately, 12 poorly differentiated HCCs, and 2 patients with metastatic liver cancers (colon cancer and gastrinoma). The histological classification was determined based on the criteria outlined by the Japan Hepatoma Research Group (14). We tested three fixative solutions, paraformaldehyde, acetone and formalin, to determine the most reliable fixing method.

Tissue sections (4 μ m) were cut in a cryostat at -18°C , then were allowed to air-dry for 30min. Mono-

layer cultured cells on covered glass were washed with phosphate-buffered saline (PBS) and air-dried for 30min. These samples were at first fixed with saturated ammonium sulfate solution for 30min. Then, 1% paraformaldehyde solution in cooled saturated ammonium sulfate solution was applied for 5min for further fixation. Paraformaldehyde was substituted for 10% formalin fixation (30min) or cold acetone fixation (15min) to compare these fixation methods. Anti-PIVKA-II diluted to 10 times with 0.01 M Tris-HCl buffer was used for the first antibody and the specimens were incubated overnight at 4°C in a moist chamber. After being washed with PBS three times, the specimens were reacted with the second antibody (FITC-conjugated rabbit anti-mouse IgG) overnight at 4°C . The samples were then washed with PBS 3 times, and observed by fluorescent microscopy.

Plasma levels of PIVKA-II were measured with an enzymeimmunoassay (Eitest Mono P-II, Eisai Co. Ltd.).


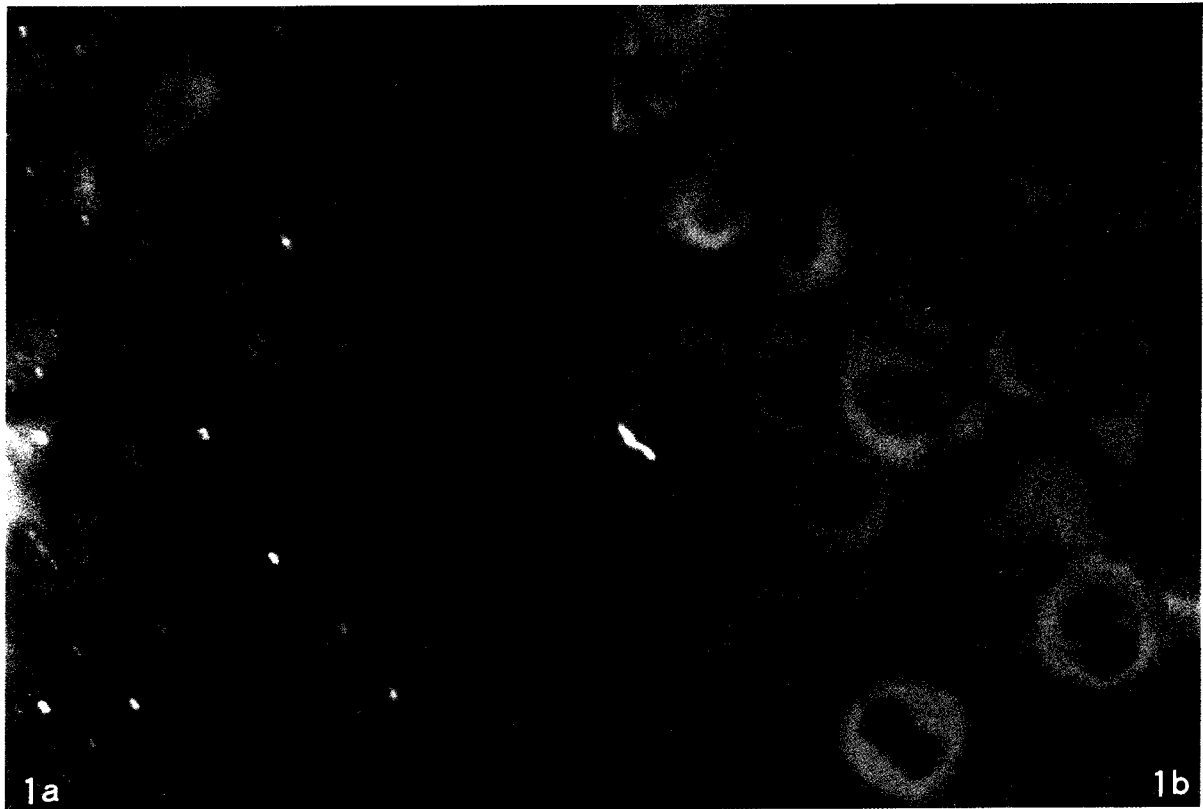
Results

PIVKA-II staining was performed at first using 2 cultured human hepatoma cell lines to determine the optimum fixation method and the specificity of the PIVKA-II staining. The PIVKA-II level in the medium of PLC/PRF/5 cells at confluent growth was 2.6 AU/ml, and was undetectable 1 week after the addition of vitamin K. The level of PIVKA-II in huH-7 cultured medium was under the detection limit.

The cytoplasm of PLC/PRF/5 cells was positive for PIVKA-II staining when the cells were fixed with paraformaldehyde. PIVKA-II-positive cells were not seen after the addition of vitamin K (Fig. 1). No immunofluorescent product was observed when the cells were fixed with formalin or acetone (data not shown). The huH-7 cells were not stained in all cases examined. These results indicate that paraformaldehyde is the optimum fixative solution for the detection of tissue PIVKA-II. Therefore, we used paraformaldehyde fixation for the following experiments.

Fig. 1 Immunohistochemical staining of PIVKA-II. PIVKA-II staining of PLC/PRF/5 cells fixed with 1% paraformaldehyde solution. PIVKA-II specific immunofluorescence was observed in the cytoplasm only when cells were fixed with paraformaldehyde (a). PIVKA-II staining was negative after the addition of vitamin K (b). The PIVKA-II level in the medium was 2.6AU/ml, but PIVKA-II was not detected after vitamin K addition (1 μ g/ml of the medium).

Fig. 2 PIVKA-II staining in human HCC tissues. Liver specimen from an autopsy patient with replacing type well differentiated HCC. PIVKA-II-positive cells were observed only in the HCC portion (right upper portion, indicated with arrowheads) and not in the cirrhotic tissue. PIVKA-II-positive cells form clusters.



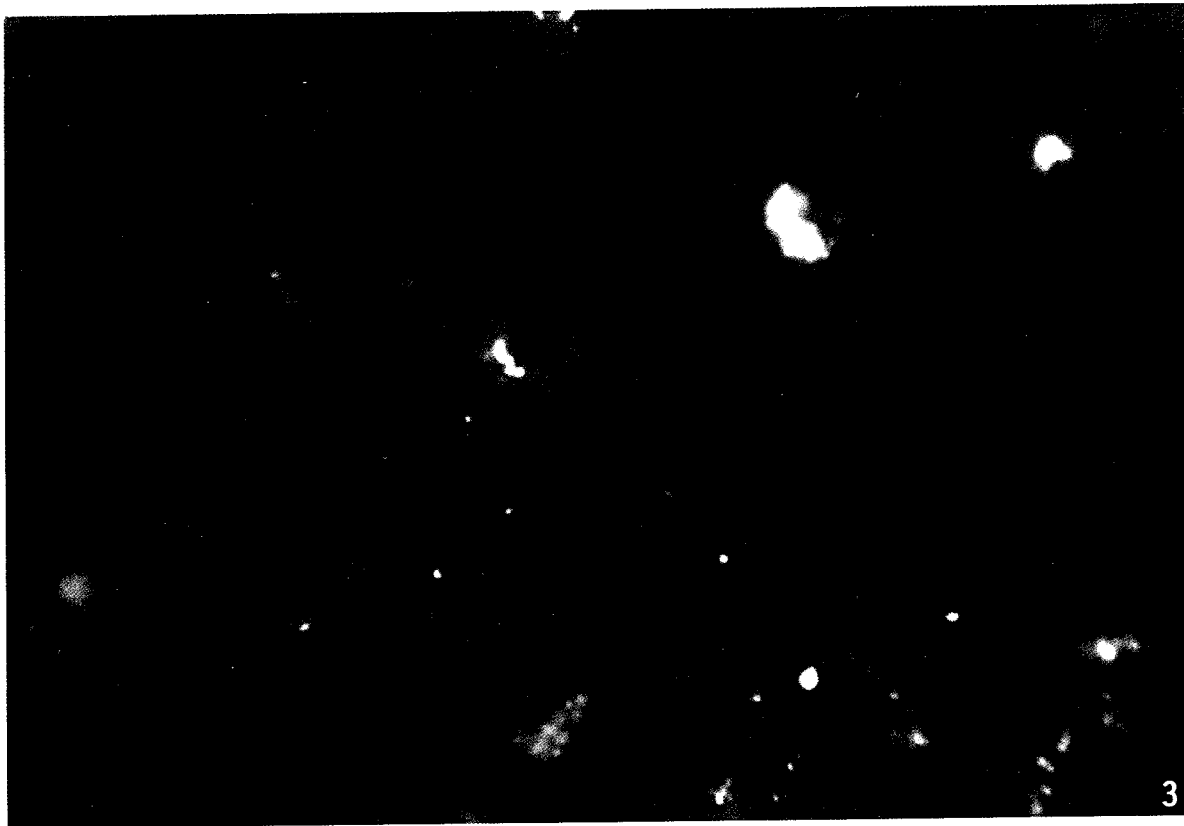


Fig 3 Solitary cell pattern of PIVKA-II staining in human hepatoma nodule. A single PIVKA-II-positive cell is shown. The cell was located apart from the clustered area in the HCC nodule shown in Fig. 2.

Table 1 Relationship between plasma PIVKA-II level and immunohistochemical staining of PIVKA-II

Plasma PIVKA-II (AU/ml)	Number of patients	Staining of PIVKA-II	
		Positive	Negative
< 0.1	16	6	10
0.1-1.0	7	6	1
1.0 <	11	11	0
Total	34	23	11

Human HCC tissues with positive staining for PIVKA-II are shown in Figs. 2 and 3. PIVKA-II-positive cells were observed only in the HCC portion and not in the surrounding cirrhotic tissue. PIVKA-II-positive cells formed clusters and occupied approximately 30% of the total area in HCC nodules (Fig. 2). On the other hand, a few solitary single positive cells were also

seen in the same nodules (Fig. 3). We observed that the positive staining rate of PIVKA-II increased with the plasma PIVKA-II level. However, even in 16 patients who showed undetectable plasma PIVKA-II level (cut off value, 0.1 AU/ml), PIVKA-II-positive cells were recognized in 6 cases (Table 1).

We measured the plasma PIVKA-II level of 93 patients with HCC in the other series of the study. The plasma PIVKA-II value was greater than or equal to 0.1 AU/ml in 3 (6%) of the 50 patients with a tumor size less than 20 mm, 4 (16%) of the 25 patients with tumor, 20 to 30 mm in diameter and 7 (39%) of the 18 patients with tumors greater than 30 mm in diameter (Table 2). This result indicates that the plasma PIVKA-II level of HCC patients increases with tumor size, especially when it is more than 30 mm in diameter.

In the histochemical investigation, however, PIVKA-II-positive cells in HCC nodules were recognized in 6 (60

Table 2 Relationship between tumor diameter and plasma PIVKA-II Level

Tumor diameter (mm)	Number of patients	Plasma PIVKA-II (AU/ml)		
		< 0.1	0.1-1.0	1.0<
< 20	50	47	1	2
20-30	25	21	2	2
30 <	18	11	3	4
Total	93	79	6	8

Table 3 Tumor diameter and immunohistochemical staining of PIVKA-II

Tumor diameter (mm)	Number of patients	Staining of PIVKA-II	
		Positive	Negative
< 20	10	6	4
20-30	14	10	4
30 <	10	7	3
Total	34	23	11

Table 4 Histological grading and immunohistochemical staining of PIVKA-II

Histological grade of HCC	Number of patients	Staining of PIVKA-II	
		Positive	Negative
Well	2	2	0
Moderately	18	13	5
Poorly	12	8	4
Metastatic (Colon cancer, Gastrinoma)	2	0	2
Total	34	23	11

%) of 10 patients, 10 (71%) of 14, and 7 (70%) of 10 patients whose tumor sizes were < 20mm, 20-30mm, and > 30mm in diameter, respectively (Table 3). PIVKA-II positive cells were identified in 100% (2 in 2), 72% (13 in 18) and 67% (8 in 12) of the patients with well, moderately, and poorly differentiated HCCs, respectively. PIVKA-II positive cells were not recognized in metastatic lesions in the 2 patients with metastatic liver cancer (Table 4).

These data suggest that PIVKA-II production has no

correlation with the histological grade or the size of HCC.

Discussion

In the present study, we used the indirect immunofluorescent staining method. This method has an advantage in that the effect of endogenous peroxidase can be eliminated and a highly contrasted specific staining can be obtained.

By this method, PIVKA-II positive cells were seen only in hepatoma nodules, and not in the cirrhotic portions, although it has been reported that PIVKA-II was also stained in the surrounding cirrhotic tissues (11). The difference in PIVKA-II production by non-cancerous tissues may be due to differences in the vitamin K concentration or in the specificity of the staining method. In the present study, we used many freshly frozen needle biopsy specimens. They had an advantage in terms of minimizing the effect of vitamin K deficiency which might occur in patients at the terminal stage. Furthermore, we did not detect any positive PIVKA-II staining in non-cancer tissue. Therefore, the possibility of positive PIVKA-II staining caused by vitamin K deficiency in these biopsy specimens is low.

However, the mechanism of PIVKA-II production by HCC remains unclear. Sakon M *et al.* (15) reported that elevated PIVKA-II levels were not due to vitamin K deficiency, but might result from the unavailability of vitamin K as a cofactor of prothrombin production in the tumor cells. In contrast, Okuno M *et al.* (16) found that the vitamin K level was decreased in HCC tissues where PIVKA-II levels were high, although they found no relationship between the plasma levels of PIVKA-II and vitamin K. In our study, the distribution pattern of PIVKA-II-positive cells in HCC nodules showed both a clustered and a single-cell pattern, indicating polymorphism of HCC cells for abnormal prothrombin formation. It is more likely that this polymorphism of each cancer cell is responsible for the variable production of PIVKA-II in HCC rather than the plasma vitamin K deficiency because a systemic phenomenon such as the plasma vitamin K deficiency would cause PIVKA-II production in all cells.

No relationship was identified between the histological grade of HCC and the frequency of PIVKA-II staining in the present study. Furthermore, the size of the tumor was not correlated with the positive rate of PIVKA-II. In other words, PIVKA-II can be stained even in small and well differentiated HCCs. Therefore, PIVKA-II

production could be considered as a marker of the early phenotypic change of HCC.

In this study, plasma PIVKA-II was detected in only 3 (6%) of 50 patients with small HCC diagnosed by ultrasound-guided tumor biopsy, whereas 6 (60%) of 10 patients with small HCC showed PIVKA-II-positive cells. This result also indicates that immunohistochemical PIVKA-II staining is useful in the diagnosis of early HCC. Hence, the utility of plasma PIVKA-II measurement in the detection of small HCC may increase if a sensitive assay for plasma PIVKA-II is developed.

Acknowledgments. The authors express gratitude to Professor Masayoshi Namba of Department of Cell Biology, Institute of Molecular and Cellular Biology, Okayama University Medical School and to Eisai Co. Ltd., for their kind cooperation during the course of this study. This work was supported by grants from the Japanese Ministry of Welfare (Intractable Hepatitis Research Committee and ten years strategy for cancer treatment).

References

- Hemker HC and Muller AD: Kinetic aspects of the interaction of blood-clotting enzyme IV: Localization of the site of blood coagulation inhibition by the protein induced by vitamin K absence (PIVKA). *Thromb Diath Haemorrh* (1968) **20**, 78-87.
- Stenflo J and Suttie JW: Vitamin K-dependent formation of γ -carboxyglutamic acid. *Annu Rev Biochem* (1977) **46**, 157-75.
- Liebman HA, Furie BC, Tong MJ, Blanchard RA, Lo KJ, Lee SD, Coleman MS and Furie B: Des- γ -carboxy (abnormal) prothrombin as a marker of primary hepatocellular carcinoma. *N Engl J Med* (1984) **310**, 1427-31.
- Tanabe Y, Ohnishi K, Nomura F and Iida S: Plasma abnormal prothrombin levels in patients with small hepatocellular carcinoma. *Am J Gastroenterol* (1988) **310**, 1386-89.
- Tsai SL, Huang GT, Yang PM, Sheu JC, Sung JL and Chen DS: Plasma des- γ -carboxy-prothrombin in the early stage of hepatocellular carcinoma. *Cancer* (1988) **61**, 1621-28.
- Fujiyama S, Morishita T, Hashiguchi O and Sato T: Plasma abnormal prothrombin (des- γ -carboxy prothrombin) as a marker of hepatocellular carcinoma. *Cancer* (1988) **61**, 1621-28.
- Hattori N, Ohmizo R, Unoura M, Tanaka N, Kobayashi K and PIVKA-II collaborative working group: Abnormal prothrombin measurements in hepatocellular carcinoma. *J Tumor Marker Oncol* (1988) **3**, 207-16.
- Kodama T, Yokoi T, Arima K, Suga M, Imai K, Akira A, Takahashi A and Shimamura Y: Clinical significance of abnormal prothrombin (PIVKA-II) in the plasma of patients with hepatocellular carcinoma. *Tumor Res* (1987) **22**, 63-70.
- Nakao A, Suzuki Y, Isshiki K, Kimura Y, Takeda S, Kishimoto W, Nonami T, Harada A and Takagi A: Clinical evaluation of plasma abnormal prothrombin (des- γ -carboxy prothrombin) in hepatobiliary malignancies and other diseases. *Am J Gastroenterol* (1991) **89**, 62-66.
- Sue K, Ito T, Higashi T, Okamoto T, Kuwahara N, Noso K, Yamada G and Tsuji T: Significance of PIVKA-II: As a marker to judgment of diagnosis and treatment for hepatocellular carcinoma. *Jpn J Clin Exp Med* (1990) **67**, 1554-60 (in Japanese).
- Nadano S, Tanimoto K, Onji M, Horike N and Ohta Y: Immunohistochemical study of PIVKA-II in hepatocellular carcinoma. *Acta Hepatol Jpn* (1990) **31**, 475-476.
- Tanaka M, Hutakawa S and Fujisawa S: Immunohistochemical study of PIVKA-II in hepatocellular carcinoma by paraffin embedded tissue. *Acta Hepatol Jpn* (1990) **31**, 830.
- Nohno R: Immunohistochemical study for PIVKA-II in hepatocellular carcinoma. *Acta Hepatol Jpn* (1991) **31**, 775-81.
- Liver cancer study group of Japan: The general rules for the clinical and pathological study of primary liver cancer (1992) **3**, 35-36.
- Sakon M, Monden M, Gotoh M, Kobayashi K, Kanai T, Umeshita K, Endoh W and Mori T: The effect of vitamin K on the generation of des- γ -carboxy prothrombin (PIVKA-II) in patients with hepatocellular carcinoma. *Am J Gastroenterol* (1991) **86**, 339-45.
- Okuno M, Fukutomi Y, Shimazaki M, Yamada T, Murakami N, Kawai K, Muto Y and Omori M: Tissue levels of PIVKA-II and vitamin K in patients with hepatocellular carcinoma-studies on the mechanism of the production of PIVKA-II. *Acta Hepatol Jpn* (1988) **29**, 699-700.

Received July 4, 1994; accepted October 28, 1994.