

Acta Medica Okayama

Volume 36, Issue 4

1982

Article 11

AUGUST 1982

Unilateral cystic inner ear anomalies in siblings.

Keiko Nishioka*

Yu Masuda†

Kazunori Nishizaki‡

Yoshio Ogura**

*Okayama University,

†Okayama University,

‡Okayama University,

**Okayama University,

Unilateral cystic inner ear anomalies in siblings.*

Keiko Nishioka, Yu Masuda, Kazunori Nishizaki, and Yoshio Ogura

Abstract

Unilateral cystic inner ear anomalies were diagnosed in two siblings, a 9 year old boy and a 6 year old girl. X-ray examination of the temporal bone was performed, together with audiological examinations and vestibular function tests. The common tomographic X-ray findings consisted of an enlarged solitary sac type deformity of the vestibule with narrowing of the internal auditory canal, severe hypoplasia of the anterior semicircular canal and no visualized cochlea. Pure-tone audiometry revealed severe mixed type of hearing loss in the right ear in both children. The test for vestibular function showed no response to caloric testing.

KEYWORDS: inner ear, anomaly, siblings

Acta Med. Okayama 36, (4), 321-324 (1982)

— BRIEF NOTE —

UNILATERAL CYSTIC INNER EAR ANOMALIES IN SIBLINGS

Keiko NISHIOKA, Yu MASUDA, Kazunori NISHIZAKI and Yoshio OGURA

Department of Otolaryngology, Okayama University Medical School, Okayama 700, Japan

Received April 6, 1982

Abstract. Unilateral cystic inner ear anomalies were diagnosed in two siblings, a 9 year old boy and a 6 year old girl. X-ray examination of the temporal bone was performed, together with audiological examinations and vestibular function tests. The common tomographic X-ray findings consisted of an enlarged solitary sac type deformity of the vestibule with narrowing of the internal auditory canal, severe hypoplasia of the anterior semicircular canal and no visualized cochlea. Pure-tone audiometry revealed severe mixed type of hearing loss in the right ear in both children. The test for vestibular function showed no response to caloric testing.

Key words : inner ear, anomaly, siblings.

Cystic inner ear anomalies, accompanied by severe monaural hearing loss, are rare. The authors describe such cases in siblings who had similar X-ray findings showing a solitary sac type deformity of the inner ear and narrowness of the internal auditory meatus.

Case report. *Case 1.* A 9-year-old boy presented at the Okayama University Hospital for detailed investigation of hearing loss in the right ear found during a physical examination for pre-school children. Although a ganglioneuroma of the chest had been excised when he was seven years old, there was no other relevant past history. Except for poor mobility of the right tympanic membrane, there were no pathological findings in either the tympanic membrane or the external auditory meatus.

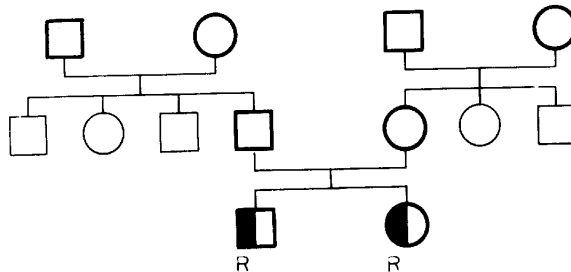


Fig. 1. The family line of the patients. Bold line was examined by author. \bullet : right side profound deafness.

Case 2. A 6-year-old girl, the sister of Case 1, was also noted to have hearing loss in the right ear during a physical examination for pre-school children.

There was no relevant past history. No abnormalities were observed in the tympanic membranes or external auditory meatus. There was no unusual prenatal, perinatal, or postnatal history in either cases. The parents had no subjective symptoms such as dizziness or tinnitus. A survey of the family line showed neither consanguineous marriage nor juvenile hearing loss (Fig. 1.).

Examination. Fine audiological examinations, vestibular tests and X-ray examination of the temporal bone were performed. Anteroposterior and sagittal projections were made using a polytome.

Results. Pure-tone audiometry revealed a severe mixed type of hearing loss in the right ear in both children. Tests for vestibular function showed neither spontaneous nor gaze nystagmus, but showed positional and positioning nystagmus. Caloric tests showed no reaction on the right side and an almost normal reaction on the left for both children.

Tomographic X-ray examination of the temporal bone revealed findings such as enlarged solitary sac type deformity in the vestibule, absence of the lateral semicircular canal, and severe hypoplasia of the anterior semicircular canal

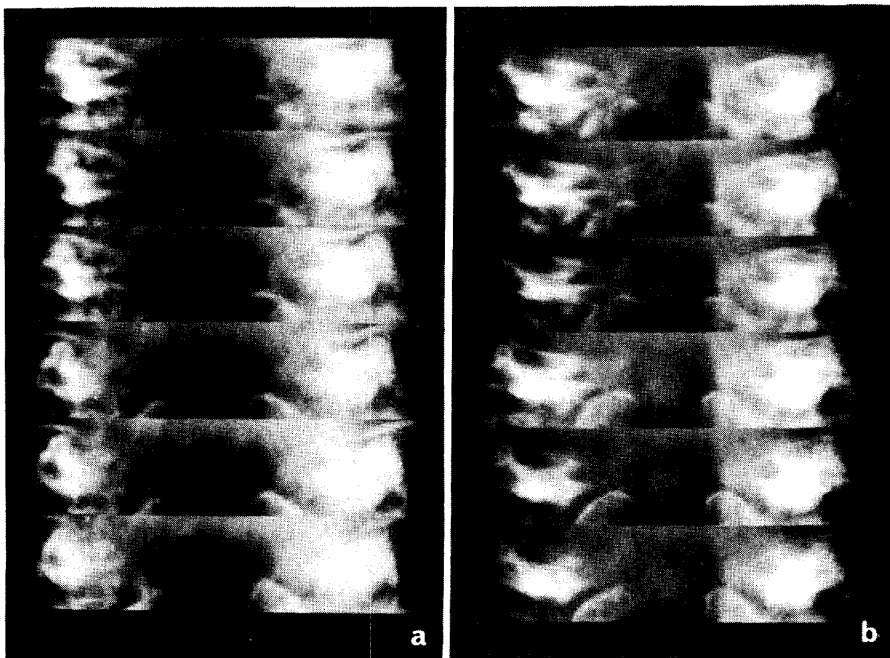


Fig. 2. Anteroposterior tomograms on both patients showing unilateral cystic enlargement of the vestibule, and shorter and rudimentary superior semicircular canal on the right ear. The lateral semicircular canal and cochlea are absent and the right internal auditory meatus showed narrowing toward its periphery on the affected side. a: Case 1. (elder brother) b: Case 2. (sister)

(Fig. 2.). These findings were common to both children. Furthermore, the bony part of the cochlea was not visualized. The internal auditory meatus became narrower toward its periphery, although the internal auditory porus was almost normal in shape. The crista falciformis was undefined. A reduction in height of the pyramidal crest was observed, accompanied by hypoplasia of the petrous pyramid on the anomalous side.

Discussion. Everberg (1) surveyed 200 children who had unilateral deafness out of 183,000 children from municipal schools in Copenhagen, and found abnormalities in X-ray films of the labyrinth in 22 children. However, there were only two cases with anomalous findings of cystic inner ear among these 22 children. Everberg's survey suggests that cystic inner ear anomaly is extremely rare. It has previously been reported as a solitary sac type deformity or a cystic anomaly in the labyrinth by Michel (1863) quoted from (2), Valvassori (2) and others (1, 3, 4-6). However, their cases were observed only sporadically. To the best of the authors' knowledge, these common inner ear anomalies in siblings constitute an original report.

A few investigators (2, 3, 6, 7) have attempted to classify cystic inner ear anomalies morphologically using roentgenography. Phelps (6) categorized a solitary sac type deformity as a severe deformity with an absence of cochlear function. He described, however, this type of inner ear anomaly as morphologically specific and accompanied by a narrow internal auditory meatus and absence of the cochlea.

Tomography in such cases only shows abnormal bony structure and does not give any information on membranous lesions of the labyrinth.

In the present cases, the caloric test elicited no response, suggesting disturbance of vestibular function. It is also known from the literature that vestibular dysfunction is frequently accompanied roentgenologically by a narrow internal auditory canal, together with an anomalous vestibule and semicircular canals (8).

Cystic inner ear anomalies are occasionally observed in patients with multiple deformities caused by teratogenic agents such as drugs, especially thalidomide (5). There is little possibility that extrinsic teratogenic factors were involved in the early stage of the development of the inner ear in either of these cases. Therefore, as Everberg *et al.* (1) insisted, genetic factors are probably responsible. Pathogenic factors, especially heredity inner ear anomalies, should be evaluated using a larger number of cases.

REFERENCES

1. Everberg, G.: Investigations into unilateral total deafness and absence of vestibular function with a particular view to the X-ray appearances in the inner ear. Polytomography of inner ear abnormalities. *Acta Otolaryngol.* 52, 47-62, 1960.
2. Valvassori, G.E., Naunton, R.F., Lindsay, J.R.: Inner ear anomalies; clinical and histopatho-

- logical considerations. *Ann. Oto-Rhino-Laryngol.* **78**, 929-938, 1969.
3. Reisner, K.: Tomography in inner ear and middle ear malformations. *Radiology* **92**, 11-12, 1969.
 4. Jensen, J.: Congenital anomalies of the inner ear. *Radiol. Clin. North Am.* **12**, 473-482, 1974.
 5. Lagundoye, S.B., Martinson, F.D., Fajemisin, A.A.: The syndrome of enlarged vestibule and dysplasia of the lateral semicircular canal in congenital deafness. *Radiology* **115**, 377-378, 1975.
 6. Phelps, P.D., Lloyd, G.A.S., Sheldon, P.W.E.: Deformity of the labyrinth and internal auditory meatus in congenital deafness. *Br. J. Radiol.* **48**, 973-978, 1975.
 7. Phelps, P.D.: Congenital lesions of the inner ear, demonstrated by tomography. *Arch. Otolaryngol.* **100**, 11-18, 1974.
 8. Everberg, G.: Unilateral total deafness in children clinical problems with a special view to vestibular function. *Acta Otolaryngol.* **52**, 253-269, 1960.