

# *Acta Medica Okayama*

---

*Volume 10, Issue 3*

1956

*Article 3*

JULY 1956

---

## Diagnosis of leukemia and aplastic anemia by the bone marrow culture

Kiyoshi Hiraki\*

Tadashi Ofuji†

Yoshiyuki Hattori‡

\*Okayama University,

†Okayama University,

‡Okayama University,

# Diagnosis of leukemia and aplastic anemia by the bone marrow culture\*

Kiyoshi Hiraki, Tadashi Ofuji, and Yoshiyuki Hattori

## Abstract

1) As the boundary of the outgrowth zone of the bone marrow culture is sharply defined from the surrounding area and the cellular density becomes very high in leukemia, diagnosis can be made with ease and certainty. 2) The differential diagnosis between aleukemic leukemia and aplastic anemia becomes easy by application of the tissue culture method. 3) The vital observation of blood cells were used in classification of leukemia by cellular systems, and it was discovered that there were a lot of patients with monocytic leukemia and relatively many with acute lymphatic leukemia. 4) Because the cellular growth in the bone marrow culture of aplastic anemia declines extremely and abundant fat cells are observed, the diagnosis of this disease is easily made by employment of this method.

Acta Med. Okayama 10, 3, 130—150 (1956)

## DIAGNOSIS OF LEUKEMIA AND APLASTIC ANEMIA BY THE BONE MARROW CULTURE

By

Kiyoshi HIRAKI, M.D. Tadashi OFUJI, M.D.  
and Yoshiyuki HATTORI, M.D.

*Department of Internal Medicine, Okayama University Medical School  
(Director : Prof. Dr. K. Hiraki)  
Okayama, Japan*

*Received for Publication June 30, 1956.*

By the application of bone marrow tissue culture methods we were able to diagnose the patients with anemia such as leukemia or hypoplastic anemia, without any confusing, in comparison with previous methods. Since there was the close relation between the classification of leukemias and the morphology of blood cells, we were, also, able to decide the reversion of leukemic cells and to assume a new phase of the classification of leukemias due to the observation of living blood cells.

Methods: refer to previous articles  
Observations;

### A. Leukemia

Since about more than 100 years ago, when *Virchow*<sup>(30)</sup> (1845) distinguished leukemia, several great hematologists (*Neumann*<sup>(28)</sup>, *Ehrlich*<sup>(9)</sup>, *Pappenheim*<sup>(30)</sup>, *Naegeli*<sup>(27)</sup> and others) have reported it. But many questions still remain unanswered.

As stated above, tissue culture of the bone marrow was performed in these cases and we were able to disclose various hitherto unknown facts. We believe that, on the basis of our findings, a new solution has been obtained to leukemia.

#### 1. *Growth in the bone marrow culture for leukemia*

The leukemic bone marrow has such peculiar aspects in cultivation, that diagnosis of leukemia is easily possible through observations ranging from a few hours to 24 hours. Classification of leukemia can be clearly made from the kinds of immature and mature leucocytes. During our two-year study, we have distinguished a total of 41 cases of leukemia, since January 1954, mainly through our method, and many matters, hitherto

unsolved, have been settled. The systematic differential diagnosis of leukemia by various ordinary methods such as post-mortal staining, oxydase reaction and supravital staining etc., was proved to be unsatisfactory. In the leukemic bone marrow, an excess outgrowth of leucocytes occurs, many of which are the immobile and immature type. Also the function of mature cells declines and their wandering velocity falls, thus enabling us to diagnose leukemia easily at a glance, due to the fact that density in the growth zone becomes comparatively high and a distinct edge of them is recognized under even a weak magnification (fig. 1 and 2) (fig. 3 and 4).

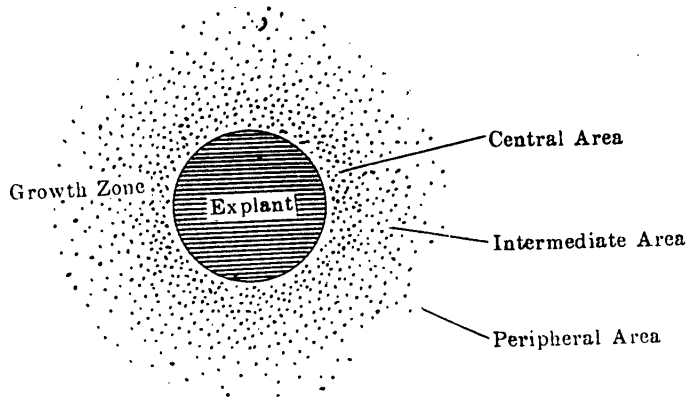


Fig. 1. Normal Bone Marrow Outgrowth

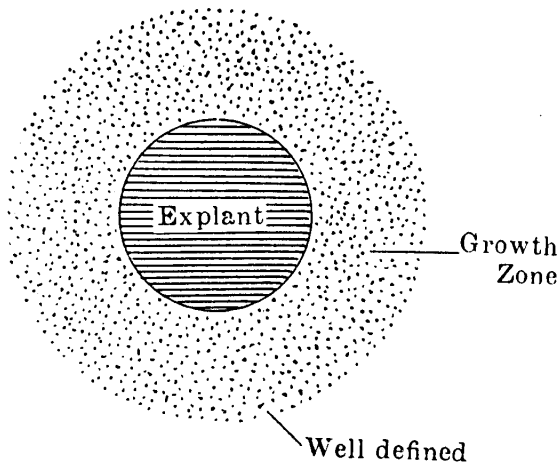


Fig. 2. Leukemic Bone Marrow Outgrowth




Fig. 3. Normal bone marrow outgrowth.

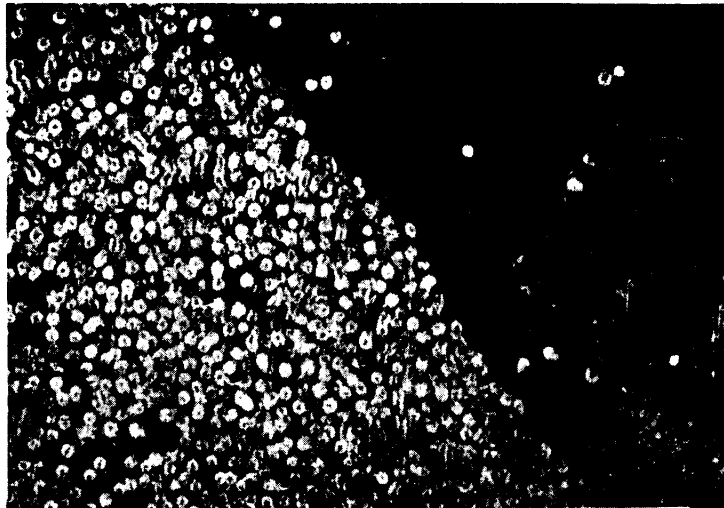


Fig. 4. Leukemic bone marrow outgrowth.

This is a common and important characteristic finding in tissue culture of the bone marrow of all leukemias, whether leukemic or aleukemic disease, and never observed in other diseases except in leukemia, for example, leukemoid disease, hypoplastic anemia, etc. .

2. *Myelogenous leukemia (neutrophilic leukemia).*

In the outgrowth zone, at first, the mature neutrophils appeared, but one hour later abundant immature neutrophils

began to appear and about 3 hours later cell density increased. Thus the margin of growth zone became sharply bordered and possessed characteristics of leukemia. This was observed to be similar in acute or chronic and leukemic or aleukemic states but tissue growth was worse in the acute state, while in the, chronic state it rather resembled the normal.

In the immature leukocytes, the movement, phagocytosis and staining were similar to those of above mentioned normal immature cells; the myeloblasts and promyelocytes moved by pseudopodium. The phagocytosis was not seen in the myeloblasts and promyelocytes, but sometimes was seen slightly in the myelocytes and markedly in the later state than in the metamyelocytes. *Rich*<sup>32)</sup> and others observed a movement like maggots in the myeloblasts by cultivation of the peripheral blood and the bone marrow. But we found no distinct movement in immature cells except monocytic series (basophilic immature cells moved weakly). It was characteristic that there were abundant megakaryocytes especially in the chronic myelogenous leukemia. Many of them were immature. Their nuclei were indistinctly lobulated and sometimes they seemed quite round while the granules in the cytoplasm were fine. The appearance of many immature megakaryocytes in this disease was also observed by *Takigawa*<sup>37)</sup> in his study with *Giemsa* staining.

It is emphasized recently that acute leukemia has been increasing more rapidly than the chronic. Of the ten cases observed by this method, we have diagnosed 4 chronic and 6 acute cases of myelogenous leukemia.

As in the past, diagnosis of the chronic myelogenous leukemia can be made without difficulty, but many difficulties and troubles have been encountered in the diagnosis of acute leukemia, especially *Naegeli's*<sup>27)</sup> paramyeloblastic and monocytic leukemia. These problems are, however, instantly cleared by tissue culture method of the bone marrow. This will be explained, in detail, in the chapter on monocytic leukemia. *Amano* disproved *Watanabe's*<sup>12)</sup> idea to consider myeloblasts with negative oxydase reaction as paramyeloblasts. Most of the cases of acute myelogenous leukemia, often reported as paramyeloblastic leukemia after *Moeschlin* and *Rohr* (according to a lately acquired publication by *Heilmeyer*<sup>16)</sup>), are found, as asserted by *Amano*<sup>1)</sup>,

to be a different and separate kind of monocytic leukemia, consequently proving that *Naegeli's*<sup>27)</sup> theory was in fault. Of course, we do not go so far as to say that, all of *Naegeli's* paramyeloblastic leukemia is separated from myelogenous leukemia and an independent monocytic leukemia. We have experienced a case of acute myelogenous leukemia regarded to be the paramyeloblastic and it was certainly diagnosed to be the acute myelogenous leukemia by the tissue culture. There was also an interesting case of typical chronic myelogenous leukemia, which changed its nature by appendectomy, altered to the acute form and died. In this case we found, turning to acute state, many immature cells, which were called paramyeloblasts. In other words, most of the monocytoid cells with indentation or segmentation of the nucleus which are called paramyeloblasts are true monocytic series, but some of them can be neutrophilic cells.

### 3. *Hypereosinophilia*

Since we have not yet experienced any cases of eosinophilic leukemia, findings of tissue culture of the bone marrow from an interesting case of hypereosinophilia are described, in accordance with our recent experiences.

The eosinophilic leukemia was first described by *Stillman*<sup>36)</sup> in 1912. Since then it has been reported by many authors as a rarely acute and mostly chronic fatal disease with swelling of spleen, lymphnodes and liver. In our country as reported by *Ichimura*<sup>17)</sup> in 1950, *Kageyama*<sup>18)</sup> and others in 1951, *Asanaga*<sup>2)</sup> in 1953, *Okazaki*<sup>29)</sup> in 1954, *Yuki*<sup>44)</sup> in 1954, *Hasegawa*<sup>14)</sup> in 1955 etc., the number of these cases are increasing gradually. But of a number of these cases which were discovered, a considerable amount were regarded to be leukemoid reaction or hypereosinophilia. Without autopsy, the differential diagnosis of eosinophilic leukemoid reaction, or simple hypereosinophilia, from true eosinophilic leukemia is very difficult. Except our method of tissue culture, no other clinical method exists which defines whether or not the bone marrow is leukemia. Our case was a 20 years old male with ankylostomiasis, who had a little enlargement of the liver but no enlargement of the spleen or lymphnodes. He was pointed out as leucocytosis. During one year following the appendectomy, the count of leucocytes was 30,000—70,000 and the eosinophils occupied 50—90% of it

(all of them were mature eosinophils) and showed no returning to normal hemogram inspite of the therapy for ankylostomiasis. By application of the tissue culture of the bone marrow, we were able to clarify the fact, that this was not a leukemia case. The tissue outgrowth was identical with that of the normal human bone marrow; with the lapse of time, the immature cell zone did not show such high density as in leukemia, although the wandering zone was filled almost by eosinophils

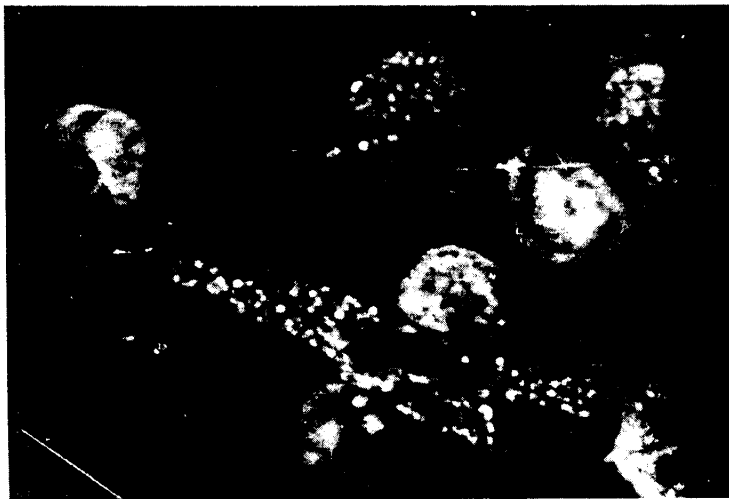


Fig. 5-a. Grouping eosinophils in hypereosinophilia.

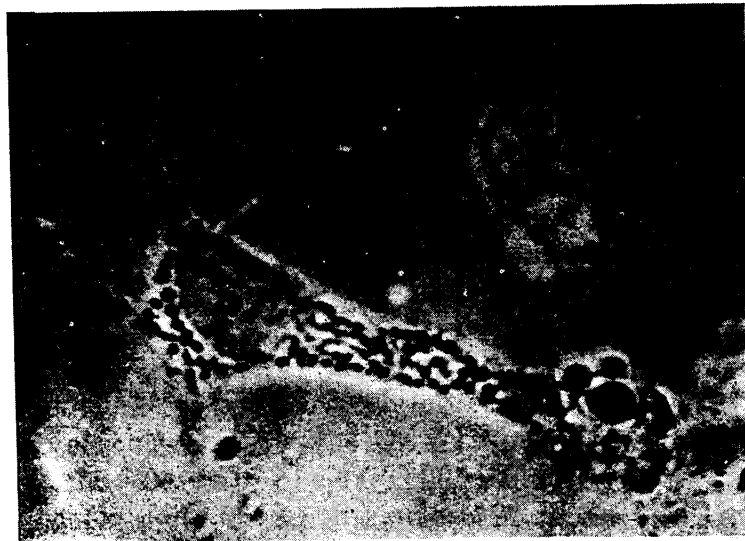

Fig. 5-b. Eosinophil. Hypereosinophilia. Phase contrast. 1500 $\times$ .



(fig. 5, a, b), but eosinophilic myelocytes were hardly to be seen which appeared very rarely in the neighbourhood of the original tissue. The cell density in the outgrowth zone was within the normal, its margin was diffused and never sharply bordered. Thus we could differentiate it from leukemia at first glance.

The number of the mature eosinophils was over one-half of all wandering cells and showed active movement in the state of accelerated function. Even after 12 hours of culture, we could observe the pathological formation of pseudopodia and cauda still in the declining stadium of motility. Furthermore, the size of the granules was irregular and frequently lacking uniformity. In the degeneration state extracellularly scattered granules showed molecular movement at places, and they appeared to be a little larger than those of the normal. On the other hand, we found no phagocytosis of the carbon particles in these cells. And the function (wandering and phagocytosis) of the neutrophils existing in less number was quite normal and showed no hypofunction as seen in leukemia.

In this case, we found eosinophiloblasts in the staining of the bone marrow, described by *Undritz*<sup>38)</sup> of about 1%. *Undritz* has described that cytoplasm was very much basophilic and similar to that of proerythroblasts or basophilic megalocerythroblasts, and that their nuclei had 2—4 nucleoli, one of which was often very large and covered with such abundant chromatin that it presented violet appearance.

#### 4. *Basophilic leukemia*

As it is already known, in the progress of the chronic myelogenous leukemia, the basophilic cells often increase, more or less. The case, in which they increase to a remarkable degree and white blood cells are occupied mainly by these cells, is reported as chronic basophilic leukemia (mast cell leukemia) by *Lazarus*<sup>24)</sup> (1906). However, it seems more appropriate to call it a chronic myelogenous leukemia with hyperbasophilic reaction. In acute basophilic leukemia reported by *Groat*<sup>11)</sup> and others (1936), there were only few immature basophilic cells. But our case was a ten-year old boy with pure acute basophilic leukemia, with 200,000—400,000 leukocytes, 80—85% of basophiloblasts and about 10% of mature basophils. Such case was never seen in the medical literature.

The bone marrow from this patient displayed peculiar outgrowth in cultivation. It was interesting that the basophiloblasts showed a weak movement similar to that of monoblasts, and we considered that they were to be separated from the almost nonactive neutrophiloblasts. Of course, we found many mature basophils migrating out and in peculiar movement like the monocytes at a glance. The coverslip culture of the leucocytes of the peripheral blood was also performed and it showed a similar result. The leukocytes in the peripheral blood of the patient were cultured with *Warburg's* apparatus, by shaking, and we were able to clarify the following facts; the basophilic myeloblasts and mature basophils increased in direct proportion to the increase of the leukocytes, while, on the other hand, the basophiloblasts decreased. Moreover, the neutrophils, eosinophils, lymphocytes and monocytes remained constant. Also with these results we were able to understand more clearly the indifference of basophiloblasts or basophilic series.

The basophiloblasts in the smeared specimens of the bone marrow and peripheral blood were relatively small cells with average diameter of  $12.6 \mu$ , smaller than other immature basophils (average diameter  $14.3 \mu$ ) and larger than mature basophils (average diameter  $11.1 \mu$ ). The cytoplasm appeared relatively narrow and showed a rather heavier basic colour than that of myeloblasts (neutrophiloblasts), and was more heavily stained at the peripheral part of cytoplasm. Characteristically almost all of them stretched out wart- or tongue-shaped irregular forms and clearly displayed their motility. The nuclei were formed round or indented, the chromatin net works were rather coarse and appeared like fine granules. A great number of the nucleoli were indistinct and did not form distinctive rings. Through our study of the basophils we found them to be slightly different from the so-called myeloblasts (neutrophiloblasts); they resembled more to the lymphoblasts designated by *Undritz*<sup>38)</sup> than those of *Iwao*<sup>18)</sup>.

##### 5. Monocytic leukemia

The monocytic leukemia was reported in 1913 by *Reshad* and *V. Schilling*<sup>31)</sup> as "Übergangsformenleukämie" (Splenoctenleukämie) and in 1916, *Fleischmann*<sup>10)</sup> gave its first name of "Monocytenleukämie". Since then, many contradicting opi-

nions concerning the diagnosis of this disease (reverting of cells, and especially, the relation with *Naegeli's*<sup>27)</sup> "Paramyeloblasten", hence its independency) have been debated.

The main and common opinions concerning the position of this monocytic leukemia are classified schematically as follows: (the schema abridged)

- a) The monocytic leukemia originated in the reticuloendothelial system (*Schilling* and others).
- b) It is merely a type of myelogenous leukemia (*Naegeli* and others).
- c) It is an independent leukemia existing together with myelogenous and lymphatic leukemia (*Amano* and others).
- d) Compromising theory between a) (*Schilling*-type) and b) (*Naegeli*-type).

By applying the tissue culture of the bone marrow, we have been able to easily clarify some of the problems hitherto in dispute in diagnosis of monocytic leukemia. We subscribed to *Amano's*<sup>1)</sup> opinion; the majority of cases that had been reported as paramyeloblastic leukemia belonged to the monocytic leukemia and we could clarify that incidence of this disease was far more frequent than had been hitherto considered. In the tissue culture of the bone marrow, the cell density of the outgrowth zone was very high and its boundary was distinct in weak magnification.

But as the monocytic series, even in their immature type, had a large motility, its boundary appeared a little more nebulous than that of the other kinds of leukemia.

The group of monoblasts and promonocytes near the original tissue were different from other immature cells, striking each other and characteristically trembling actively. All of the peculiar appearances, form of the movement, phagocytosis of the carbon particles and character in vital staining of the migrated mature monocytes were identical with those of normal subjects described in other article (fig. 6, a, b).

In this time, we have experienced 41 cases leukemias in the past 2 years and 5 months. About half of them, 21 cases, were monocytic leukemia, and after acute or subacute course, they terminated fatally within 1 year except one of 1 year and 3 months.

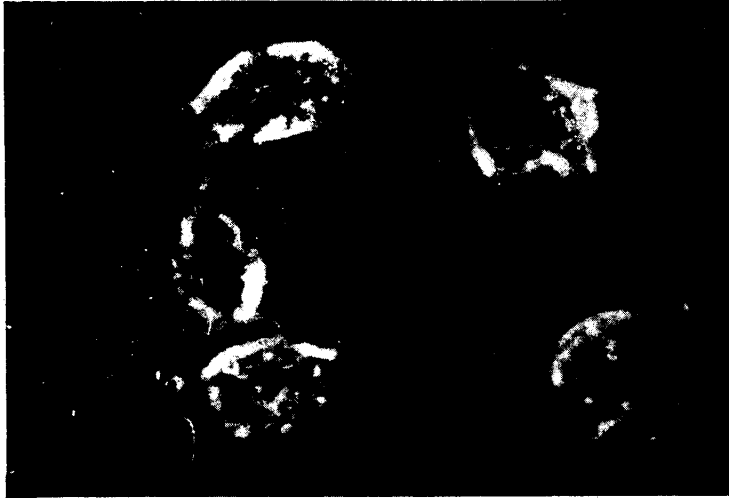

Fig. 6-a. Grouping monocytes in monocytic leukemia.

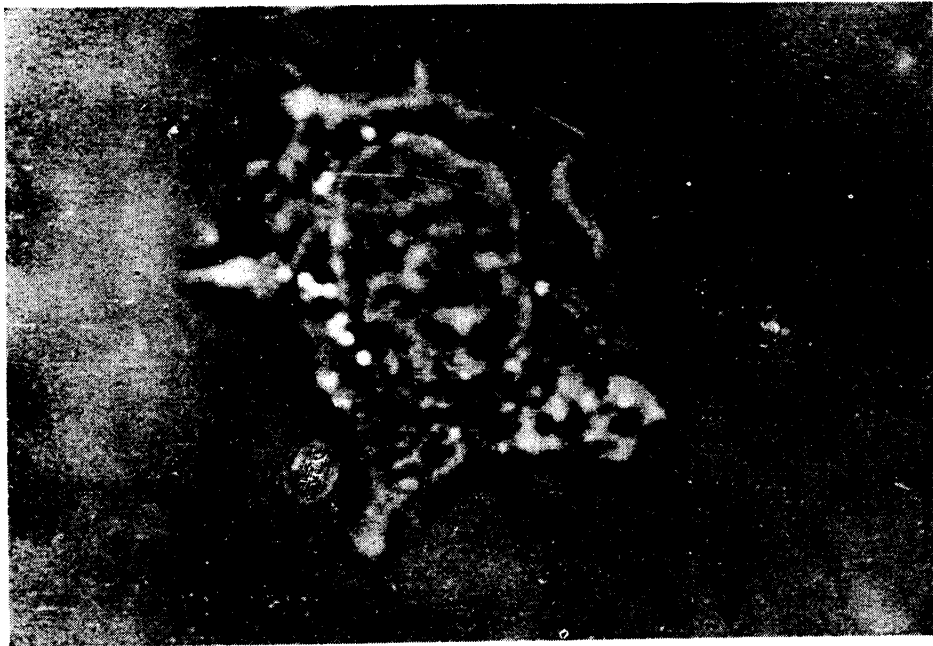

Fig. 6-b. Monocyte. Monocytic leukemia. Phase contrast. 1500 $\times$ .

### Supplement

#### *Azurophilic myelogenous leukemia*

Leukemia, in which the cytoplasm of the myelocytes was filled chiefly by azurecoloured small granules after *Giemsa* stain,

was designated by *Sato*<sup>33)</sup> especially as azurophile myelogenous leukemia. He himself regarded it as a kind of myelogenous leukemia, but also he described that some scholars regarded it as a kind of monocytic leukemia. We also experienced such a case, applied the bone marrow culture and recognized that it belongs to the monocytic leukemia. In this disease the outgrowth zone showed natural leukemic outgrowth. At first glance, almost all of the cells which appeared were filled by small granules, similar to those of myelogenous series. But the shape of their nuclei and specific movements etc. demonstrated, that they belonged to the monocytic series.

#### 6. *Lymphatic leukemia.*

The lymphatic leukemia has long been one of the two categories of leukemia. Oxydase reaction by *Winkler*<sup>43)</sup> (1907), *Schultz*<sup>44)</sup> (1909) has been used widely in clinical hematology and the lymphatic leukemia, accordingly, has become to be regarded as a fairly rare disease. In majority of cases that have been reported, lymphatic leukemia belongs to acute myelogenous leukemia, and the occurrence of acute leukemia in adults is rather widely doubted (*Naegeli*<sup>27)</sup>, *Katsunuma*<sup>21)</sup>, *Watanabe*<sup>42)</sup> and others). Through employment of tissue cultures of the bone marrow and peripheral blood, in the past two years we have experienced 5 cases of acute lymphatic leukemia (15, 28, 18, 5 and 20 years old) and, having been able to establish its certain existence, we consider that it might be not rare.

In the bone marrow culture in this disease we found the same character as those in other acute leukemia; the appearance, movement and vital staining of wandering mature lymphocytes, were the same as those in normal, but no phagocytosis was observed.

#### 7. *Chloroleukemia (chloroma)*

Chloroma (chloromatic leukemia, chloroleukemia) presents a leukemic hemogram and makes a green tumor on the skull especially in the orbit, occurs frequently in adolescences and takes an acute or subacute course. But there are a few of them that demonstrate only diffuse green leukemic infiltration and no tumor. According to *Lehndorff*'s<sup>26)</sup> statistics it is seen in one-fifth, and in *Watanabe*'s<sup>41)</sup> 106 cases in our country in less than 10 cases.

This disease was first described by *Burns*<sup>6)</sup> (1823), designated as chloroma by *King*<sup>22)</sup> (1853) and classified into leukemia by *Waldstein*<sup>40)</sup> (1883), *Dock*<sup>7)</sup> (1893) and others. Until recently, its pathogenesis has been the object of numerous contradicting discussions; in old days it was considered to be a lymphatic nature, but *Sternberg*<sup>35)</sup> (1905) reported some myelogenous ones. Since *Burgess*<sup>6)</sup> (1912) and *Askanazy*<sup>33)</sup> (1916), majority of these cases has been regarded to be myelogenous. This opinion seems to be generally accepted in Japan as well. Many scholars regard the chloroma as a partial phenomenon of leukemia. On the other hand, however, (according to *Amano* and others) it must be considered separated from general leukemia. Thus many questions about its relation to the monocytic leukemia have not yet been settled.

*Amano*<sup>1)</sup> has confirmed, that the pigment of chloroma depends upon existence of porphyrin at abnormal composing of cytochrome in *Nadi*'s reaction. According to him, both myelogenous and monocytic cells are theoretically capable of producing chloroma pigments, while in more than 20 cases reported by him, all cells were of monocytic nature, they should be called chloromonocytoma, and interpreted equally as plasmocytic leukemia in the broad sense of leukemia.

He has stated also, "in all cases, so far as we experienced, it might be concluded that there was no chloroma independent of the growth of the monocytes. As we have not predicted such limitations, we hope further investigation should be continued."

We have recently experienced 2 cases of acute myelogenous chloroleukemia lacking tumor formation; a case of 30 years old female diagnosed by autopsy and of 18 years old male diagnosed in his lifetime by the green section of an excised lymphnode.

The bone marrow tissue culture showed a typical leukemic outgrowth in both cases and in the observation of each leucocyte, the outgrowth zone was occupied almost by neutrophilic cells. In their vital staining we found no neutral red rosette and the phagocytosis of the carbon particles was also different from that of monocytes. In other words, the outgrowth of the tissue and the findings of each cell showed no difference from the usual acute myelogenous leukemia. It was identical in case of the leucocytes in the peripheral blood.

Concerning the genesis of this disease, there were hitherto various theories. The fact that the majority of chloroleukemia shows a systematic tumor formation with predilection site, and is accompanied by leukemic cells, supports the general view regarding the genesis of leukemia as a tumor of haematopoietic organs. It seems appropriate, therefore, to place this disease in the category of leukemia. Our views were further confirmed, since in both of 2 cases, experienced by us, pathological leucocytes showed no difference in the postmortal stained specimen and in the observation of movement in the culture of neutrophilic cells from usual myelogenous leukemia. Of course we are not able to come to definite conclusions from only 2 cases as mentioned here. It may be assumed that chloroleukemia with tumor formation belongs to the monocytic system, while those lacking tumor formation are composed of myelogenous cells. We hope to find a definite conclusion after further research through the vital observation of blood corpuscles in many cases.

#### 8. *Classification of leukemia by cellular system.*

Leukemia can be classified by various views like other diseases, but the classification by kinds of leucocytes dominating in blood may be more appropriate. As *Hamaguchi*<sup>12)</sup> has described, it is impossible to make a list of leukemic classification which will not be subject to contradiction, even though such classifications have been attempted by many scholars. This is because it has an indivisible relation with hitherto disputable hematogenealogy. In classifying leukemia by cellular systems, the following points are the subject to argument:

- 1) Existence of lymphatic leukemia, especially its acute type.
- 2) Independence or relation of monocytic leukemia to paramyeloblastic leukemia (*Naegeli*)<sup>27)</sup>.
- 3) Participation of reticuloendothelial system in leukemia.
- 4) Position of chloroleukemia and plasmocytic leukemia.
- 5) Existence or role of stem cell leukemia.
- 6) Differential diagnosis of various stem cell in leukemia, especially in acute type.

*Naegeli*<sup>27)</sup> named the common stem cells of granulocytes and monocytes as myeloblasts, and stressed the positive oxydase and peroxydase reaction. This *Naegeli*'s<sup>27)</sup> theory has elicited

great sensation in haematologists of his day, and has been accepted as the golden rule. However, *Iwao*<sup>18)</sup> who investigated chronic myelogenous leukemia and other diseases accompanying specific increase of each granuloblastic cells, named the neutrophiloganies as neutrophiloleukocytoblasts, the eosinophiloganies as basophiloleukocytoblasts and advocated excessive polygenesis. Similarly, *Kato*<sup>20)</sup> (in his new monogenesis) described the neutrophilic, basophilic and eosinophilic blastocic cells etc. . Furthermore, in previous studies, *Undritz*<sup>35)</sup> advocated a polygenesis, used the nomenclature of the neutrophiloblast, basophiloblast and eosinophiloblast and described the characteristic findings of these on stained specimens. However, since the differential diagnosis of postmortal staining is very difficult, his doctrine has been supported by only few peoples. We used the vital observation of blood cells, especially the bone marrow tissue culture freely and applied them to differential diagnosis of various types of leukemia. This observation resulted in the settling of some of numerous points hitherto discussed. In addition, after further investigation by ordinary postmortal and ultravital staining, we obtained a classification of leukemias. Thus the 41 cases of leukemia diagnosed by us in the past 2 years and 5 months (January, 1954—March, 1956) were classified as indicated in the table. We have accepted not only the monocytic series as an independent one derived from monoblasts, but further classified the myeloblasts (*Naegeli*)<sup>27)</sup> into three groups of neutrophiloblasts, eosinophiloblasts and basophiloblasts as *Undritz*<sup>35)</sup>, *Iwao*<sup>18)</sup> and others did. That each of them was to be placed in the same position of lymphoblasts and monoblasts, was recognized and the kinds of leukemias were expressed by the name of their dominating blood corpuscle system, thus standardizing the hitherto divergent names.

As we have not yet experienced sufficient cases of leukemia in the two years, we must correct and complete the classification by further and more detailed investigation. We firmly believe, however, that we can promote further classification of leukemia in blood systems, which has been planned hitherto by many researchers.



Table. 1. Classification of the patients with leukemia in our Clinic from Jan. 1954 to May 1956.

	Acute	Chronic	Total
Neutrophilic Leukemia	8	4	12
(2 Chloromas inclusively)			
Eosinophilic Leukemia	0	0	0
Basophilic Leukemia	1	0	1
Monocytic Leukemia	20	1	21
Lymphocytic Leukemia	5	0	5
Leukemic Reticuloendotheliosis	1	0	1
Others	1	0	1
Total	36	5	41

### B. Aplastic anemia (panmyelogenous disease)

The treatment of anemia has advanced with rapid strides. For instance, *Castle* has already established a theory about the genesis of pernicious anemia, which is rarely found in our country and frequently in Europe and America. Therapy with liver, folic acid and V. B<sub>12</sub> has been discovered and the word "pernicious" has become unsuitable. On the other hand, no classification of the genesis and therapy concerning the idiopathic aplastic anemia, which is found rarely in Europe and America and relatively frequently in our country, has been discovered by us. We sincerely hope our hematologists will find a solution which is urgently needed. We ourselves have experienced up to 10 cases of this disease every year, and there are indications of increased recurrence of the disease.

Some cases of aplastic anemia are caused by medicaments, such as, benzole, sulfamin preparations or by haematopoietic disturbance of the bone marrow with radiations of X-ray, radium, atomic or hydrogen bombs and others are idiopathic of unknown origin. As a rule, the name of hypoplastic anemia (panmyelopathia) means the latter.

*Ehrlich*<sup>8)</sup>, in 1888, dissected a female patient who had died from high degree anemia and massive uterine haemorrhage,

and designated the case as an aplastic anemia. Although a general conception has been formed concerning this disease, even today, 60 years after its initial report, the diagnosis is considerably difficult. Even with the finding of peripheral blood, investigation of the bone marrow, and also postmortal dissection, the diagnosis of this disease from the closely related idiopathic purpura (*Werlhof's* disease), hypogranulocytosis, leukemia, particularly aleukemic leukemia or leukemoid reactions, as seen in *Bock's*<sup>21)</sup> schema, is very difficult.

These facts have been pointed out by many scholars.

*Hasegawa*<sup>13)</sup> has reported at the proceeding of the Japan Haematological Society, "It is an idiopathic progressive anemia with a decrease of the granulocytes and thrombocytes and without swelling of the liver, spleen and lymphnodes, as a rule, and does not react to usual haematopoetics. The majority of it shows aplasia or hypoplasia in the bone marrow specimen." Also *Komiya*<sup>23)</sup> has described in his book, "In this disease the bone marrow shows no regenerative phenomenon in spite of severe anemia. Not only the physiologically fatty degenerating parts do not change into the red marrow, but the physiologically haematopoietic bone marrow falls in severe atrophy. In consequence, the erythrocytes, leukocytes and platelets decrease in the blood and especially the erythrocytes lose their young type completely." But in many cases there are not only these with severe bone marrow disturbances but those, in which the erythrocytes, leukocytes and platelets decrease severely, in spite of a slight bone marrow disturbance. Such cases also belong to this category. Therefore, we can understand why the diagnosis of this disease is not easy.

We classified the bone marrow disturbances into three groups: the cellular detaining in the bone marrow, the inhibition of cellular growth and the disturbance of formation. Thus we classified this disease, on the basis of the finding of the bone marrow puncture, into following 5 types:

- I. Chiefly the type of cellular detaining in the bone marrow.
- II. Chiefly the type of inhibition of growth.
- III. Chiefly the type of disturbance of formation.
- IV. Mixed type.

#### V. Panmyelopathic type (aplastic anemia).

Of course also in this disease the red and white corpuscles and platelets are not always affected simultaneously and equally, but clinically the disease may be confirmed to one of these types. Every bone marrow disturbance in this disease is mixed, more or less, with three of the above mentioned types and no pure type is considerable. Conditions will change later to the panmyelopathic type (aplastic type), but many of the patients die of severe anemia or other causes before they reach Type V stage. 23 cases experienced by us were classified as follows: (type I, 7. type II, 2. type III, 3. type IV, 8. and type V, 3.) Especially in the cases of type I, and sometimes of type II, the bone marrow often showed red appearance and the number of nucleated cells in the bone marrow showed a normal rate or sometimes more. Also the number of the reticuloerythrocytes was normal or more than normal in the peripheral blood, and it was designated as pseudoaplastic anemia (*Luzzato*) or progressive hypocythemia (*Thompson*) etc.. Even if the bone marrow shows a red marrow, and no change seems to be in the bone marrow puncture, haematopoietic function of the bone marrow must be certainly disturbed. In this sense, as *Hattori* has described, the establishing of a method estimating the function of the bone marrow is strongly in demand, as that of *Thorn's* test on the function of adrenal cortex. But by the application of the bone marrow tissue culture which we are now using, diagnosis of this disease has become very easy from its characteristic findings in cultivation. Thus a prominent foundation is offered in favor of differentiating it from the other various diseases mentioned above. It will also develop new phases in the field of therapy and in the judging of prognosis. At the same time, it has become clear that it can meet the demand for a method of examination of the bone marrow function.

In the bone marrow culture of aplastic anemia, the relative growth rate was extremely lower than that in the normal (fig. 7). The growth index during 12 hours was only 0.28. The out-growth zone was very coarse and density index decreased unusually. Time of cessation of all cellular movement was only 60 hours, while it was 120 hours in the normal. Concerning the cellular function, the wandering velocity of neutrophils was

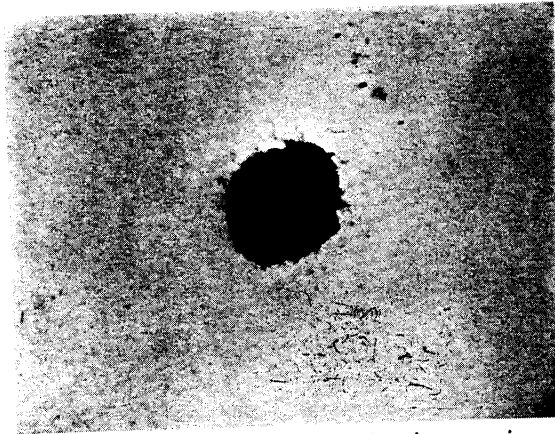


Fig. 7. Growth zone in aplastic anemia.

markedly worse; it was only  $1.3 \mu/\text{min}$  after 12 hours ( $10.8 \mu/\text{min}$  in the normal). The phagocytosis of carbon particles also dropped and the mean degree of phagocytosis was 0.7 after 3 hours (1.95 in the normal). The neutral red staining was also pathologic, and early and heavy staining was observed and with early fading. In the fluid culture, the increase of the erythrocytes and haemoglobin was less than normal. Thus, in the bone marrow of this disease, the tissue growth as well as the cellular function declined remarkably as never seen in others.

It was the characteristic in the outgrowth zone, that the erythrocytes were very few in the central area and the fat cells were abundant at first glance (fig. 8). We found a relative lymphocytosis, and the wandering velocity of lymphocytes was seen to be much more active, since the wandering velocity of neutrophils declined.

As the above mentioned findings are very distinct, they play an important role in the diagnosis of this disease. Therefore, this disease may be diagnosed early by this method with the examination of serum iron, *Heinz* body and others.

In the therapy of this disease, we found usually no further recovery of the bone marrow findings beyond a certain degree, in spite of remarkable recovery of findings of the peripheral blood especially after repeated blood transfusion and other procedures. In such cases, if therapy is discontinued, anemia becomes worse and finally the patient dies. Also in this sense, our method is most significant in judgement of therapeutic results

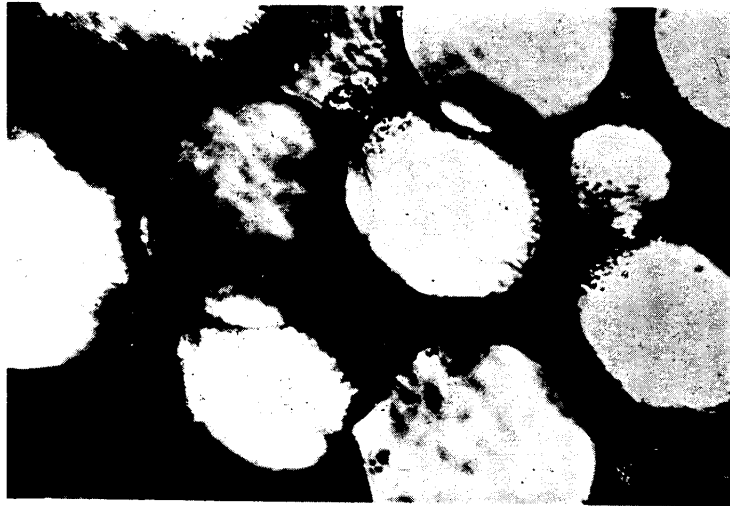

Fig. 8. Fat cells in aplastic anemia.

and prognosis. Furthermore, even in the same aplastic anemia, cellular density of detaining type is rather high; the cellular function declines at less degree and the findings in cultivation are slightly better than those in the other types. But also in this case, findings in cultivation present the characteristics of aplastic anemia and therefore, diagnosis can be made easily.

### Summary

1) As the boundary of the outgrowth zone of the bone marrow culture is sharply defined from the surrounding area and the cellular density becomes very high in leukemia, diagnosis can be made with ease and certainty.

2) The differential diagnosis between aleukemic leukemia and aplastic anemia becomes easy by application of the tissue culture method.

3) The vital observation of blood cells were used in classification of leukemia by cellular systems, and it was discovered that there were a lot of patients with monocytic leukemia and relatively many with acute lymphatic leukemia.

4) Because the cellular growth in the bone marrow culture of aplastic anemia declines extremely and abundant fat cells are observed, the diagnosis of this disease is easily made by employment of this method.

## References

- 1) *Shigeyasu Amano*: Shinryo-to-Keiken, **5**, 103, 1941. Shinryo-to-Keiken, **6**, 500, 1942. Acta Haematologica Japonica, **6**, 269, 1942. Ketsuekigaku-no-Kiso (Fundamental Hematology), Vol. 1, Maruzen, 1948. — 2) *M. Asanaga*: The Japanese Journal of Clinical and Experimental Medicine, **30**, 263, 1953. — 3) *Askanazy, M.*: Personal research on the nature of chloroma, Internat. Clin., **1**, 67, 1917. — 4) *Bozk, H. E.*: Über Agranulozytose, Aleukie, Amyelähämie und andere Hämozytotoxischen, Folia Haemat., **42**, 7, 1930. — 5) *Burgess, A. M.*: Chloroma, a report of two cases, J. Med. Research, **27**, 133, 1912—13. — 6) *Burns, A.*: Anatomy of the head and neck, Ist. Am. Ed., **386**, Baltimore, 1823. — 7) *Dock, G.*: Chloroma and its relation to leukemia, Amer. Jour. of the Med. Sci., **106**, 152, 1893. — 8) *Ehrlich, P.*: Über einen Fall von Anämie, mit Bemerkungen über regenerative Veränderungen des Knochenmarks, Chartiti Ann., **13**, 300, 1888. — 9) *Ehrlich, P.*: Farbenanalytische Untersuchungen zur Histologie und Klinik des Blutes, Berlin, 1891. — 10) *Fleischmann, P.*: Der zweite Fall von Monozytenleukämie, Fol. Haemat., **20**, 17, 1916. — 11) *Groat, W. A., T. C. Wyatt, S. M. Zimmer, R. E. Field*: Acute basophilic Leukemia, Amer. Jour. Med. Sci., **191**, 457, 1936. — 12) *Ichiro Hamaguchi, Akira Nagano*: Leukemia, Kensyu-Shobo, 1946. — 13) *Mitsuto Hasegawa*: Clinical Chemistry of Aplastic Anemia, Symposium on Haematology, Vol. VII 248, 1954, *Mitsuto Hasegawa*; Saisin Igaku, **9**, 546, 1954. — 14) *Y. Hasegawa, Y. Yokoyama, Y. Kotoshi*: Diagnosis and Treatment, **43**, 842, 1955. — 15) *Kenichi Hattori*: Haemomyelogram in aplastic Anemia, Symposium on Haematology, Vol. VII, 260, 1954. — 16) *Heilmeyer, L., H. Begemann*: Atlas der klinischen Hämatologie und Cytologie, Springer-Verlag, Berlin, Göttingen, Heidelberg, 1955. — 17) *Toshio Ichimura*: Journal of the Nagasaki Medical Association, **25**, 149, 1950. — 18) *T. Iwao*: Acta Haematologica Japonica **7**, 195, 1943. — 19) *Keizi Kageyama, H. Oonuki*: Acta Haematologica Japonica, **14**, 235, 1951. — 20) *Katsuzi Kato*: Atlas of Haematology, Vol. I, Erythrocytic Series, Kanehara Publishing Co. 1955. — 21) *Seizo Katsunuma*: The Journal of Japanese Society of Internal Medicine, **23**, 1, 1935. — 22) *King, A.*: A case of Chloroma, Monthly. J. Med., **17**, 97, 1853. — 23) *Etsuzo Komiya*: Clinical Haematology. — 24) *Lazarus*: git. n. G. Joachim; Über Mastzellenleukämie, Dtsch. Arch. klin. Med., **87**, 437, 1906. — 25) *Lehndorff, H.*: Chlorom, Ergeb. d. inn. Med. u. Kinderh., **4**, 221, 1910. — 26) *Hisao Morita*: Classification of aplastic Anemia, Symposium on Haematology, Vol. VII, 224, 1954. — 27) *Naegeli, O.*: Blutkrankheiten und Blutdiagnostik, **5** Aufl, Berlin, 1931. — 28) *Neumann, E.*: Ein Fall von Leukämie mit Erkrankung des Knochenmarkes, Arch. Heilk., 1870. — 29) *Ichiro Okasaki*: The Journal of the Wakayama Medical Society, **5**, 225, 1954. — 30) *Pappenheim, A.*: Morphologische Hämatologie, Leipzig, 1919. — 31) *Reschad, H., V. Schilling*: Über eine neue Leukämie durch echte Übergangsformen (Splenozyten Leukämie) und ihre Bedeutung für die Selbstständigkeit dieser Zellen, Münch. Med. Wschr. **60**, 1981, 1913. — 32) *Rich, A. R., M. M. Wintrobe, M. R. Lewis*: The differentiation of myeloblasts from lymphoblasts by their manner of locomotion, Bull. Johns Hopkins Hospital, **65**, 291, 1939. — 33) *Kiyoshi Sato*: Hematology, Ed. V, **270**, Nankodo, 1940. — 34) *Schultze, W. H.*: Die Oxydasereaktion an Gewebsschnitte und ihre Bedeutung für die Pathologie, Beitr. Path. Anat., **45**, 127, 1909. — 35) *Sternberg, C.*: Chloroma, zur Kenntnis des Chloroma (Chloromyelosarcoma), Beitr. z. Path. Anat. u. z. allg.

Path., **37**, 347, 1905. — <sup>36)</sup> *Stillman, R.*: Myeloid leukemia with predominance of eosinophilic cells, *Med. Rec.*, **81**, 594, 1912. — <sup>37)</sup> *K. Takigawa*: Symposium on Hematology, Vol. IV, 176, 1951. — <sup>38)</sup> *Undritz, E.*: Sandoz atlas of hematology, Basle, 1953. — <sup>39)</sup> *Virchow, R.*: Weisses Blut, *Forstner's Notizen*, **33**, 151, 1845. — <sup>40)</sup> *Waldstein, L.*: Ein Fall von progressiver Anämie u. darauffolgender Leukocythämie mit Knochenmarkserkrankung u. einem sog. Chlorom, *Virchows Arch.*, **91**, 12, 1883. — <sup>41)</sup> *Kakuta Watanabe*: *Acta Medica Hokkaidonensia*, **XX**, 801, 1942. — <sup>42)</sup> *Z. Watanabe*: *Acta Haematologica Japonica*, **4**, 119, 1940. **5**, 663, 1941. — <sup>43)</sup> *Winkler, F.*: Der Nachweis der Oxydase in den Leukozyten mittels der Dimethyl-p-Phenylendiamin  $\alpha$  Naphtol Reaktion, *Fol. Haemat.*, **4**, 323, 1907. — <sup>44)</sup> *Y. Yuki, K. Kai*: A case of eosinophilic leukemia, *The Journal of the Hiroshima Medical Association*, **7**, 317, 1954.

---