

# *Acta Medica Okayama*

---

*Volume 44, Issue 1*

1990

*Article 4*

FEBRUARY 1990

---

## Ultrastructural Localization of Endogenous Peroxidase Activity in Hashimoto's Thyroiditis

Nobuharu Yamamoto\*

Shinya Suzuki†

Zensuke Ota‡

\*Okayama University,

†Okayama University,

‡Okayama University,

# Ultrastructural Localization of Endogenous Peroxidase Activity in Hashimoto's Thyroiditis\*

Nobuharu Yamamoto, Shinya Suzuki, and Zensuke Ota

## Abstract

Ultrastructural localization and intensity of endogenous thyroid peroxidase (TPO) in Hashimoto's thyroiditis were examined in relation to the serum thyroid hormone level, thyroid-stimulating hormone (TSH) concentration and anti-thyroid autoantibody titer. In Hashimoto's thyroiditis, TPO activity on the microvilli of follicular cells was more intense than that of normal thyroid tissue, but the intensity of the intracytoplasmic peroxidase reaction was generally weaker than that of Graves' or normal thyroid tissue. Microvillar TPO reaction products were positive in all thyroid follicular cells in patients with increased TSH levels, but no TPO activity was observed on the microvilli of patients with normal or low TSH levels, irrespective of their histological type or serum anti-microsomal antibody titer. It is suggested that TPO activity on the surface of microvilli of thyroid follicular cells in Hashimoto's thyroid gland is modulated by thyrotropin but is not affected by anti-thyroid autoantibodies.

**KEYWORDS:** Hashimoto's thyroiditis, thyroid peroxidase, anti-thyroid microsome antibody, thyroid-stimulating hormone

---

\*PMID: 2330843 [PubMed - indexed for MEDLINE]

Copyright (C) OKAYAMA UNIVERSITY MEDICAL SCHOOL

## Ultrastructural Localization of Endogenous Peroxidase Activity in Hashimoto's Thyroiditis

Nobuharu Yamamoto\*, Shinya Suzuki and Zensuke Ota

*Third Department of Internal Medicine, Okayama University Medical School, Okayama 700, Japan*

Ultrastructural localization and intensity of endogenous thyroid peroxidase (TPO) in Hashimoto's thyroiditis were examined in relation to the serum thyroid hormone level, thyroid-stimulating hormone (TSH) concentration and anti-thyroid autoantibody titer. In Hashimoto's thyroiditis, TPO activity on the microvilli of follicular cells was more intense than that of normal thyroid tissue, but the intensity of the intracytoplasmic peroxidase reaction was generally weaker than that of Graves' or normal thyroid tissue. Microvillar TPO reaction products were positive in all thyroid follicular cells in patients with increased TSH levels, but no TPO activity was observed on the microvilli of patients with normal or low TSH levels, irrespective of their histological type or serum anti-microsomal antibody titer. It is suggested that TPO activity on the surface of microvilli of thyroid follicular cells in Hashimoto's thyroid gland is modulated by thyrotropin but is not affected by anti-thyroid autoantibodies.

**Key words :** Hashimoto's thyroiditis, thyroid peroxidase, anti-thyroid microsome antibody, thyroid-stimulating hormone

Thyroid peroxidase (TPO) is an essential enzyme for thyroid hormone synthesis. The enzyme catalyzes the oxidation of iodide, iodination of thyroglobulin (Tg) and coupling of iodotyrosines (1, 2). TPO is firmly bound to subcellular membranes and is found mostly in the microsomal fraction after homogenization and fractionation of thyroid tissues (3, 4). Studies on the ultrastructural distribution of TPO in normal rat thyroid using 3, 3'-diaminobenzidine as a substrate revealed that the enzyme is present in perinuclear cisternae (PC), rough-surfaced endoplasmic reticulum (ER), Golgi apparatus, lateral vesicles, apical vesicles and the apical cell surface (5, 6).

TPO activity was studied biochemically in relation to some thyroid disorders such as thyroid adenoma (7, 8), Graves' disease, thyroid carcinoma (4, 9-11), Hashimoto's thyroiditis and familial nontoxic goiter (12). It is evident that, as measured by the guaiacol method (4, 9) or by iodide assay (8, 12), thyroid peroxidase activity is high in Graves' disease, normal in thyroid adenoma and low in thyroid carcinoma as compared with the activity in normal thyroid glands.

This paper describes the localization of endogenous peroxidase in thyroid gland tissue obtained from patients with Hashimoto's thyroiditis in relation to the thyroid hormone level, serum thyroid-stimulating hormone (TSH) concentration and anti-thyroid antibody titer of respective patients.

---

\*To whom correspondence should be addressed.

## Materials and Methods

**Thyroid tissue.** Thyroid tissue was obtained by means of a needle biopsy from 12 patients with Hashimoto's thyroiditis ranging in age 28 to 65 (mean 48 years). As controls, we also examined normal thyroid tissue obtained from 6 patients during the removal of benign thyroid adenomas, and also examined thyroid tissue obtained from 10 patients surgically treated for Graves' disease. Because of tissue heterogeneity, several fragments of each specimen were analyzed.

**Primary fixation of thyroid glands.** The tissue was cut into small pieces immediately after its removal and fixed for 1 h in periodate-lysine-paraform-aldehyde (PLP) fixative (13) at 4°C. As previously described, PLP fixation preserved the thyroid peroxidase activity very well (14). After fixation, tissue blocks were washed three times in Tris-HCl buffer, (pH7.6) and transferred to a modified Karnovsky's peroxidase medium (10) containing 0.5 mg per ml of 3, 3'-diaminobenzidine in 0.05 M Tris-HCl buffer, (pH7.6) and 0.2 mM hydrogen peroxide. The blocks were incubated by shaking in darkness at room temperature for 2 h and then were washed three times in the same Tris-HCl buffer. Blocks of tissues serving as controls were incubated in media without hydrogen peroxide.

**Post fixation and electron microscopic observation.** The incubated tissues were postfixed for 2 h in 2% osmium tetroxide adjusted to pH7.6 with Tris-HCl buffer, dehydrated in a series of graded ethanol and embedded in Epon. Semithin sections were cut and observed microscopically to confirm the cytochemical reaction of the tissue. Ultrathin sections from selected portions of the blocks were cut with a diamond knife on a Reichert-Nissei Ultracut N microtome, and TPO reaction products were examined under a Hitachi H-300 electron microscope without counterstaining. Confirmation of the intensity and distribution of TPO reaction products was made comparing with those of normal thyroid tissues.

**Measurement of anti-thyroid autoantibodies, thyroid hormones and TSH.** Autoantibodies to thyroglobulin and microsomal antigen were measured by the passive hemagglutination method using a commercial kit, Fujizoki Co., Ltd., Tokyo, Japan. Serum TSH was measured in each sample using a highly sensitive TSH RIA kit, Dainabot Co., Ltd., Tokyo, Japan. Serum free T<sub>3</sub> and serum free T<sub>4</sub> were measured using a commercially available kit, Amerlex FT<sub>4</sub> and FT<sub>3</sub>, Amersham International, Little Chalfont, Buckinghamshire, England.

## Results

**TPO activity in normal and Graves' thyroid.** Figs. 1 and 2 show the ultrastructural localization of peroxidase activity in the thyroid follicular cells in normal thyroid gland and Graves' thyroid tissue, respectively. In both cases, the reaction products were present in the perinuclear cisternae (PC) and on the inner surface of endoplasmic reticulum (ER). In Graves' thyroid tissue, the reaction products were found on the external surface of many well-developed microvilli (MV), whereas normal thyroid follicular cells had no reaction product on the microvillous or apical cellular border.

**Ultrastructural localization of TPO activity in tissue of Hashimoto's thyroiditis patients with high serum TSH levels.** Fig. 3a is a light micrograph of thyroid tissue obtained from a patient (Y.U. in Table 1) with Hashimoto's thyroiditis whose serum TSH level was 69.4 μU/ml. The semithin section (Fig. 3a) shows follicles with apical borders stained for peroxidase and moderate lymphocyte infiltration.

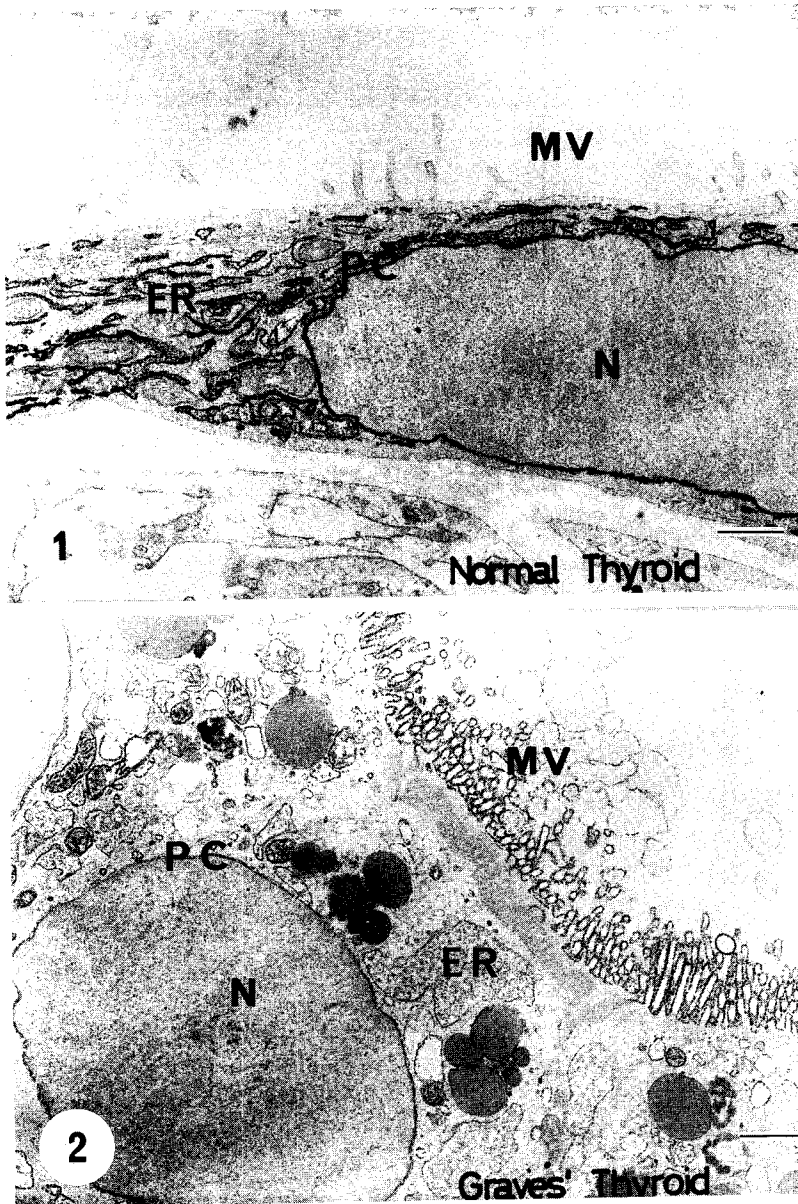
Fig. 3b shows the ultrastructural localization of endogenous peroxidase in the same thyroid follicular cells shown in Fig. 3a. The TPO reaction products were intense on the surface of microvilli, but intracytoplasmic peroxidase activity was relatively weak in intensity, compared with normal thyroid follicular cells.

Fig. 4a shows a semithin section of the thyroid gland from the same patient as in Fig. 3 a, b. Degenerative thyroid follicular cells are surrounded by many infiltrating lymphocytes. Ultrastructural localization of peroxidase in this follicular cell is shown in Fig. 4b. The reaction product of peroxidase was prominent on the microvillar border of these thyrocytes despite lymphocyte infiltration into the thyroid follicle and mitochondrial degeneration of the thyrocytes. Note that peroxidase reaction product was found on neither the nuclear membrane nor the ER.

Fig. 5a shows a semithin section of a patient (M. M.) with Hashimoto's thyroiditis whose

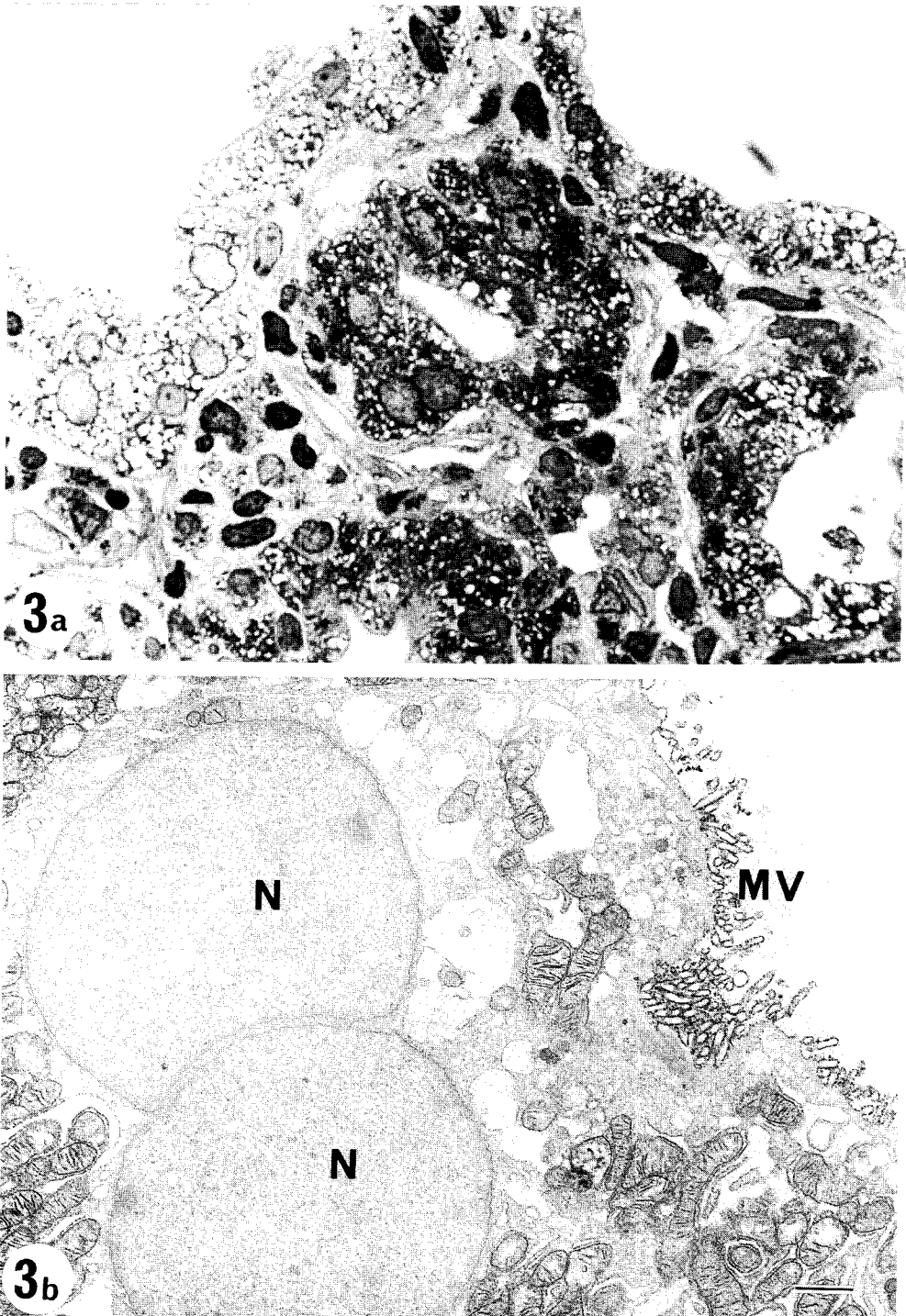
serum TSH was  $179.5\mu\text{U}/\text{ml}$ , and whose histological findings indicated diffuse thyroiditis. Even a light microscopic observation of the

semithin sections stained for peroxidase revealed intense reaction products on apical/microvillar surfaces of the thyroid follicular cells. Fig. 5b

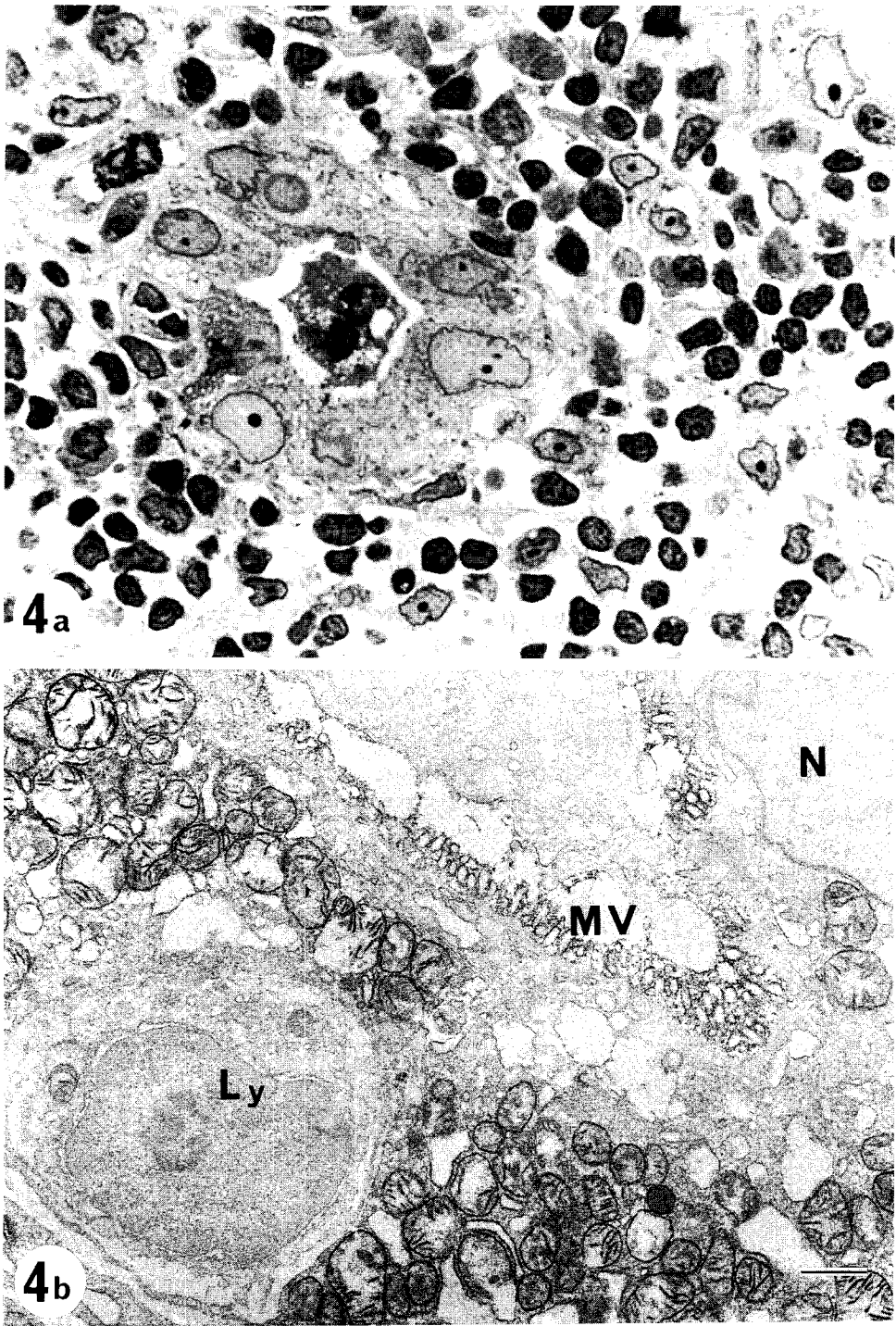


**Fig. 1** Normal thyroid follicular cell with thyroid peroxidase cytochemical reaction. Cytochemical reaction products were observed on the inner surface of endoplasmic reticulum (ER) and perinuclear cisternae (PC). No reaction products were observed on microvilli (MV). Not counterstained. (Horizontal bar indicates  $1\mu\text{m}$ ). N, nucleus.  $\times 10,000$ .

**Fig. 2** Thyroid peroxidase (TPO) cytochemical reaction of Graves' thyroid follicular cells. TPO activity was observed on ER, apical and lateral small vesicles, PC and intensely on MV. No reaction product was observed on the basal or lateral cell membrane, nor in the mitochondria. Abbreviations: ER, endoplasmic reticulum; PC, perinuclear cisternae; MV, microvilli; N, nucleus.  $\times 10,000$ .



**Fig. 3** Thyroid peroxidase (TPO) cytochemical reaction of Hashimoto's thyroid cells (patient Y.U. in Table 1). The patient's serum TSH concentration was 69.4  $\mu$ U/ml. Light microscopic view in Fig. 3a ( $\times 400$ ). Ultrastructural TPO activity is shown in Fig. 3b ( $\times 12,000$ ). Strong TPO reaction products are seen on microvilli (MV). N ; nucleus.



**Fig. 4** Thyroid peroxidase (TPO) cytochemical reaction of Hashimoto's thyroid cells. The thyroid gland from the same patient is shown in Fig. 3. Marked lymphocyte infiltration is seen surrounding a degenerated follicle (Fig. 4a) ( $\times 400$ ). Strong TPO activity is observed on the microvilli (MV) of these degenerated thyrocytes. Ultrastructural localization of TPO is shown in Fig. 4b. Note the emperiopolesis of a lymphocyte (Ly) (Fig. 4b) ( $\times 12,000$ ). N ; nucleus.

**Table 1** Ultrastructural localization of thyroid peroxidase in tissue of Hashimoto's thyroiditis patients with high serum thyroid-stimulating hormone (TSH) levels

Case		Age	Sex	Histology	McAb	TGAb	TSH ( $\mu$ U/ml)	TPO activity			
No.	IL.							ER	PC	MV	
1	T. K.	65	F	Diffuse Fibrous	$\times 26,214,400$	$\times 26,214,400$	110.37	(+)	(+)	(+)	
2	Y. U.	50	M	Focal	$\times 25,600$	(-)	69.40	(-)	(-)	(+++)	
3	M. M.	35	F	Focal	$\times 1,600$	(-)	179.5	(+)	(+)	(+)	
4	H. K.	30	M	Diffuse Fibrous	$\times 26,214,400$	$\times 26,214,400$	83.93	(+)	(+)	(+++)	
5	K. K.	28	F	Diffuse Fibrous	(-)	(-)	53.48	(+)	(+)	(+++)	
6	S. Y.	56	F	Diffuse Oxyphillic	$\times 409,600$	$\times 102,400$	8.37	(+)	(+)	(+)	
7	M. K.	40	F	Focal	(-)	(-)	210-85.70	(+++)	(++)	(++)	
8	Basedow's thyroid								(++)	(++)	(+++)
9	Normal thyroid								(+)	(++)	(-)

Abbreviations : IL, patient's initial ; McAb, microsome antibody ; TGAb, anti-thyroglobulin antibody ; TSH, thyroid stimulating hormone ; ER, endoplasmic reticulum ; PC, perinuclear cisternae ; MV, microvilli ; (+++), strongly positive ; (+), weakly positive ; (-), negative.

**Table 2** Ultrastructural localization of thyroid peroxidase in tissue of Hashimoto's thyroiditis patients with normal serum thyroid-stimulating hormone (TSH) levels

Case		Age	Sex	Histology	McAb	TGAb	TSH ( $\mu$ U/ml)	TPO activity			
No.	IL.							ER	PC	MV	
1	H. T.	51	F	Diffuse Oxyphillic	$\times 26,214,400$	$\times 1,600$	2.72	(+)	(+)	(-)	
2	Y. O.	56	F	Diffuse	$\times 102,400$	(-)	5.50	(-)	(-)	(-)	
3	F. G.	60	F	Diffuse Oxyphillic	$\times 400$	$\times 655,640$	1.68	(-)	(-)	(-)	
4	T. N.	65	F	Diffuse	$\times 6,400$	$\times 26,214,400$	2.20	(+)	(+)	(-)	
5	S. T.	43	F	Diffuse	$\times 1,600$	$\times 1,600$	2.28	(+)	(+)	(p+)	
6	Basedow's thyroid								(++)	(++)	(+++)
7	Normal thyroid								(+)	(++)	(-)

Abbreviations : (p+), weakly positive in part of follicular cells ; for others, see the legend to Table 1.

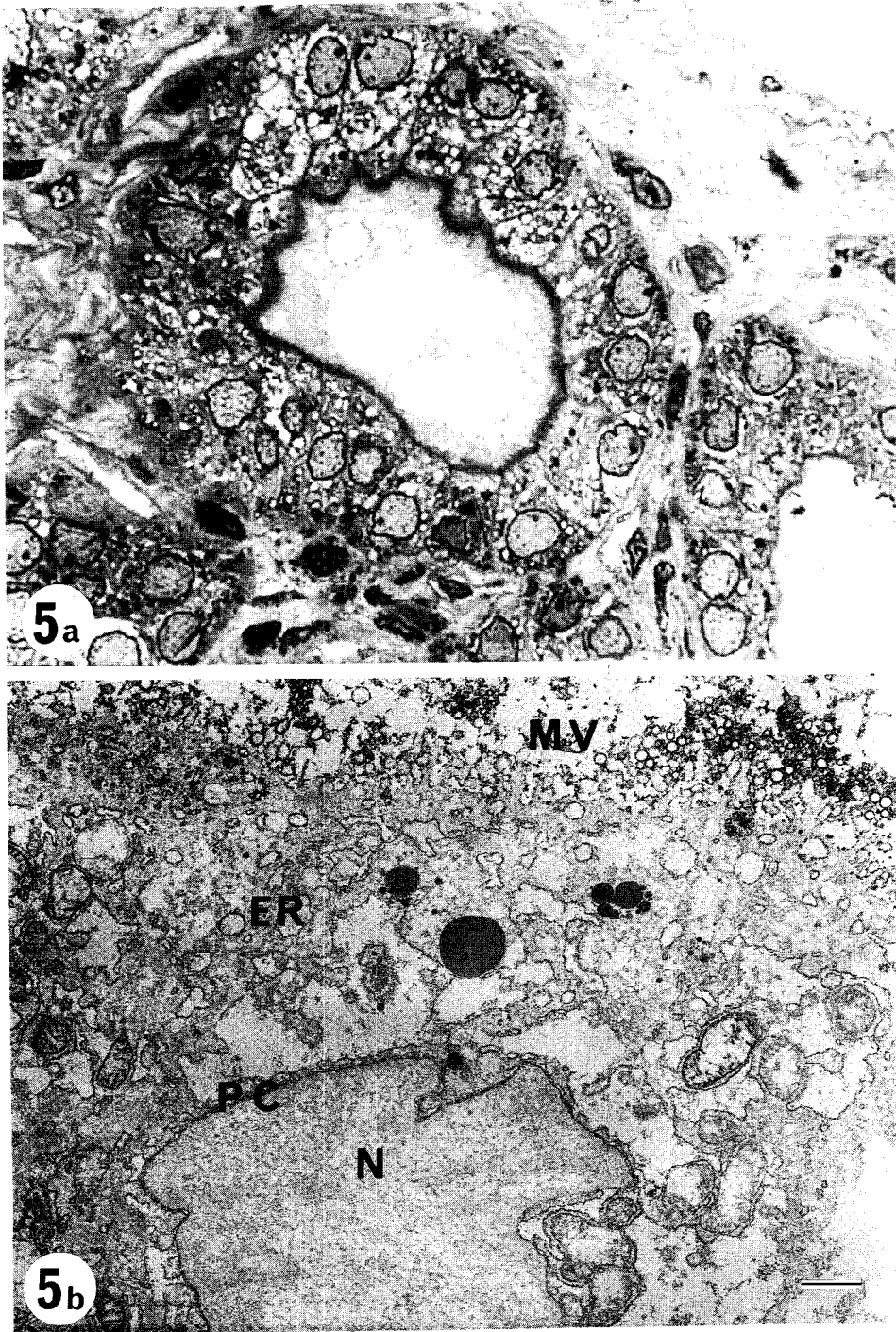
shows the ultrastructural localization of peroxidase activity in a thyrocyte of the same follicle shown in Fig. 5a. The reaction products were observed on the ER and PC, and somewhat more intensely on microvilli.

Fig. 6a shows a light microscopic view of the thyroid gland of a patient (H. K. in Table 1) with severe hypothyroidism. A small degenerative follicle surrounded by massive lymphoid infiltra-

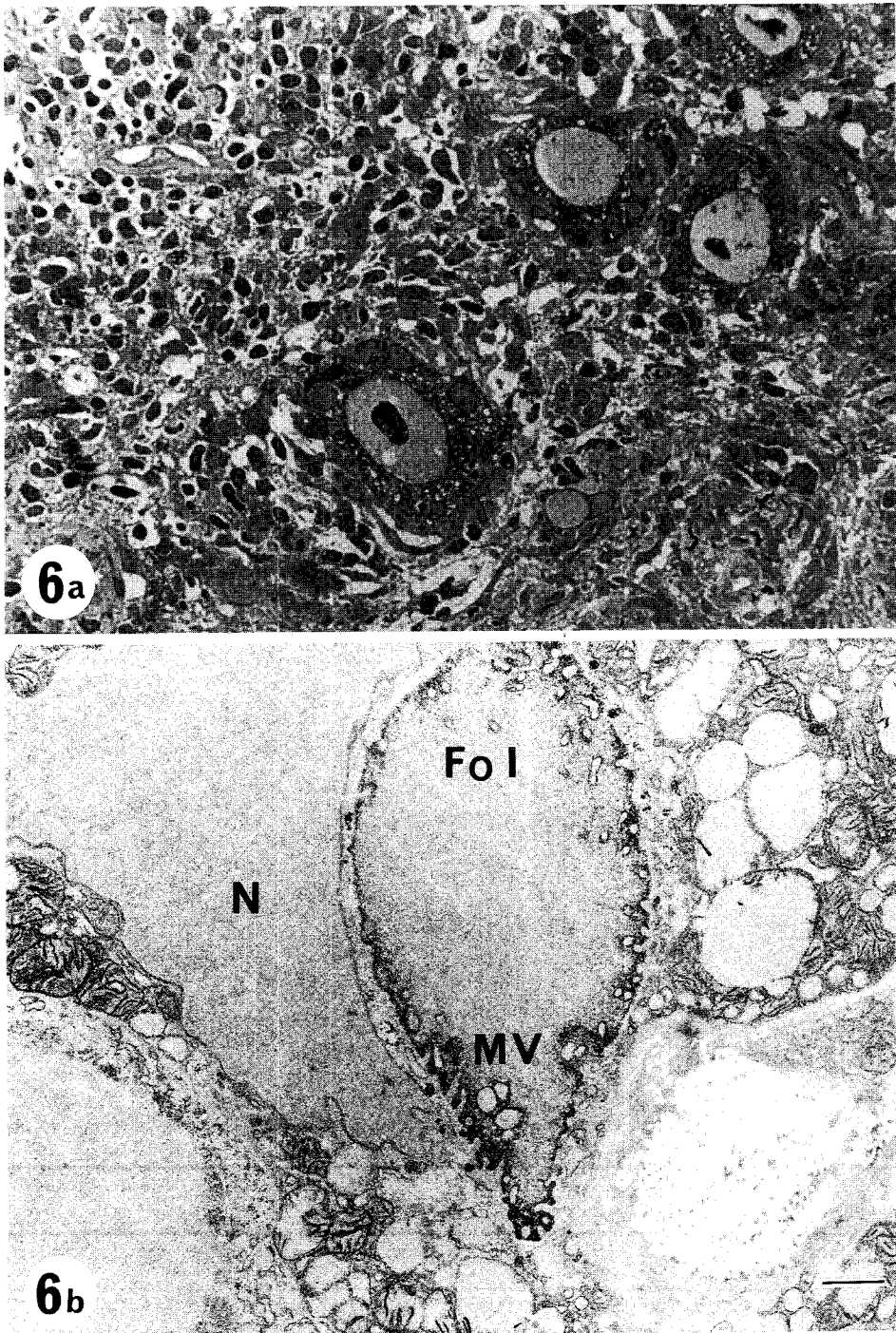
tion and interstitial fibrosis is shown in this figure. Electronmicroscopic (EM) cytochemistry of the follicular cells showed intense TPO reaction on the apical surfaces (Fig. 6b). Table 1 summarizes the clinical data and the results of TPO cytochemical reaction of the thyroid follicular cells in patients with raised TSH levels.

Intense peroxidase activity was observed in all cases of this group on the surface of microvilli.

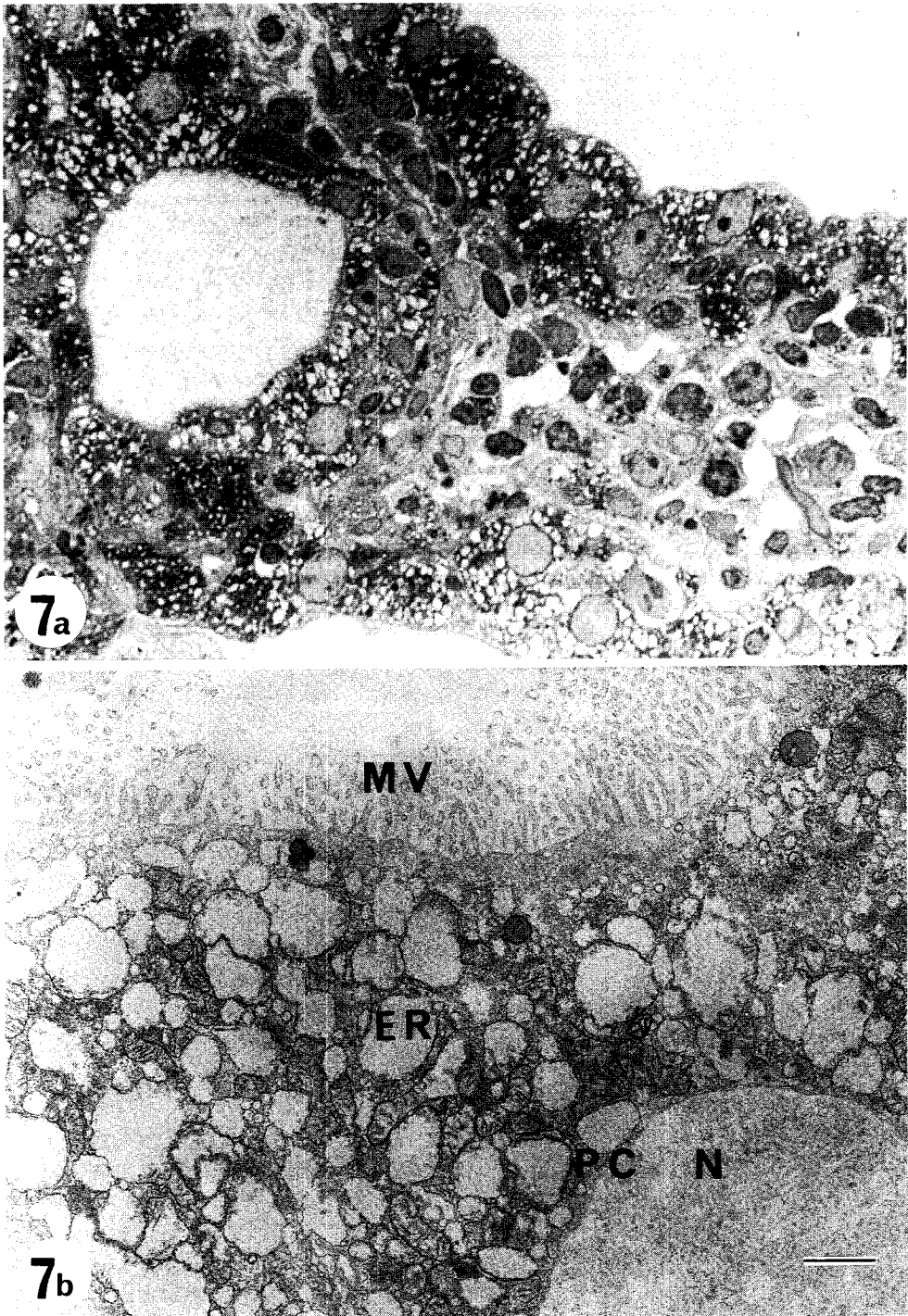




**Fig. 5** Thyroid peroxidase (TPO) cytochemical reaction of Hashimoto's thyroid cells (patient M.M. in Table 1). The patient's serum TSH concentration was  $179.5 \mu\text{U/ml}$ . TPO reaction products on the apical surface are seen even light microscopically in Fig. 5a ( $\times 400$ ). Ultrastructural micrograph shows intense TPO activity on microvilli (MV), inner surfaces of endoplasmic reticulum (ER) and perinuclear cisternae. (Fig. 5b) ( $\times 12,000$ ). N ; nucleus.



**Fig. 6** Micrograph of thyroid peroxidase (TPO) cytochemical reaction of Hashimoto's thyroid cells (patient H.K. in Table 1). The patient's serum thyroid-stimulating hormone level was  $83.9 \mu\text{U/ml}$ . Fibrosis and lymphocyte infiltration are seen in Fig. 6a ( $\times 200$ ). Intense microvillous TPO reaction products are seen ultrastructurally in these severely degenerated thyroid cells (Fig. 6b) ( $\times 12,000$ ). N, nucleus ; MV, microvilli ; Fol, follicle.



**Fig. 7** Thyroid peroxidase (TPO) cytochemical reaction of Hashimoto's thyroid cells (patient Y. O. in Table 2). The patient's serum thyroid-stimulating hormone concentration was normal. Light micrograph shows typical Hashimoto's lesion (Fig. 7a) ( $\times 400$ ). Even ultrastructurally, TPO reaction product was not seen on endoplasmic reticulum (ER), perinuclear cisternae (PC) or even well-developed microvilli (MV) (Fig. 7b) ( $\times 14,000$ ). N, nucleus.

But the TPO activities on the ER and PC were variable, and generally not so prominent as compared with normal thyroid gland.

*Ultrastructural localization of TPO activity in tissue of patients with normal serum TSH levels.* Table 2 shows five patients with Hashimoto's thyroiditis who had normal serum TSH levels. Only one (case S.T.) out of the five patients showed weak TPO activity on the surface of MV. The others did not show any TPO activity on the MV of their thyroid follicular cells.

Fig. 7a shows a light microscopic view of thyroid tissue of a patient with normal serum TSH levels (case Y.O. in Table 2). The follicles are small in size, and epithelial cells are enlarged, with vacuolation of the cytoplasm and distortion of nuclei. Marked interstitial infiltration by lymphoid cells is seen. These histopathological findings are typical of the diffuse type of chronic thyroiditis. The EM cytochemical reaction for TPO of a thyroid follicular cell in the same follicle as shown in Fig. 7a is shown in Fig. 7b. Reaction product of thyroid peroxidase was found neither on the PC, ER nor well-developed MV. This finding is distinctly different from the findings of the group with high serum TSH.

Two out of these five patients (F.G. and Y.O.) were treated for hypothyroidism, with L-thyroxin (0.005 mg/day) and the other (T.N.) with desiccated thyroid (100 mg/day). Both of them were hypothyroid initially with high serum TSH levels and became euthyroid after treatment when the needle biopsy was performed.

We could not find any correlation between anti-microsome/anti-thyroglobulin antibody and TPO activity anywhere in thyroid follicular cells.

## Discussion

In this study, the ultrastructural distribution of thyroid peroxidase activity in the follicular cells of patients with Hashimoto's thyroiditis was analyzed with special references to their serum autoantibodies and TSH levels. Hashimoto's

thyroid follicular cells from patients with high serum TSH levels showed intense TPO activity on MV irrespective of their serum autoantibody titer. The intensity of TPO activity on MV was as strong as that of Graves' thyroid follicular cells.

Autoantibodies, such as anti-Tg antibodies (Ab) and Ab to other colloid components, anti-microsome Ab, and Ab to nuclear components, have been noted in patients with Hashimoto's thyroiditis (16). The microsomal antigen on the cell surface is involved in the complement-mediated cytotoxic effect of sera from autoimmune thyroid disease (17). Banga *et al.* showed by immunoprecipitation studies that the thyroid microsome antigen is a polypeptide of Mr = 105,000 under reducing conditions, and a polypeptide of Mr = 117,000 under non-reducing conditions (18). Other studies have confirmed and extended the knowledge of the biochemical nature of thyroid microsome antigen with the use of autoantibodies (19) and monoclonal antibodies (20, 21). Since then considerable evidence has accumulated to indicate that the thyroid microsome antigen is antigenically related to human TPO (21-24).

The iodination of tyrosyl residues in thyroglobulin and the generation of the thyroid hormones are mediated by a membrane-bound, heme-containing enzyme called TPO. This peroxidase has been shown to possess catalytic sites for two substrates. *In vivo*, the first substrate site is involved in utilizing hydrogen peroxide, while the second substrate site can bind and oxidize ingested iodide to free iodine and/or catalyze the iodination and coupling of selected tyrosyl residues of Tg to generate the hormones (2).

Strum and Karnovsky first demonstrated the fine structural localization of peroxidase in the rat thyroid gland (25). Since then many authors have reported EM cytochemical localization of TPO. The overall conclusion of these studies is that TPO is located largely on ER, apical vesicles and perinuclear cisternae. Under some cytochemical conditions, peroxidase reaction products were

demonstrable on the apical/microvillar surface (25, 26), but such localization of the enzyme has been found neither in normal rat thyroid (27) nor in normal human thyroid gland (28). Most degenerated mitochondria are with peroxidase positive as shown in Figs. 3b and 4b, but these electron dense deposits are thought to originate from nonspecific catalase activity existing in the degenerated mitochondria (15).

In rat thyroid gland treated with TSH or propylthiouracil (PTU), it was shown that peroxidase was newly developed on the microvillar/apical cell border (15, 27). It is also known that peroxidase is strongly positive on the apical/microvillar surface of the follicular cells of thyroid glands obtained from hyperthyroid patients with Graves' disease (28). Using primary cultures of human thyroid cells, Chiovato *et al.* showed that the expression of microsomal/TPO antigen in human thyroid cells is dependent on TSH stimulation, through pathways which involve cAMP production and protein synthesis. They also showed that thyroid stimulating antibody reproduces this effect of TSH (29). These data indicate that the peroxidase activity on the microvilli of thyroid follicular cells is affected by TSH or thyroid stimulating immunoglobulins.

As shown in Tables 1 and 2, the TPO activity on microvilli is obviously affected by the serum TSH level, but there is no relationship between the anti-microsome/Tg Ab titer and TPO activity. Recently, anti-TPO Ab has been detected by immunoprecipitation (22), microenzyme-linked immunosorbent assay (30), competitive radioassay (23), and immunoradiometric assay (23). These reports suggest that TPO possesses almost all of the antigenic determinants reacting with anti-microsomal Ab.

It has also been reported that autoantibodies to TPO are present in sera from most patients with chronic thyroiditis, and that the antibodies are capable of inhibiting the catalytic activity of TPO (31). Okamoto *et al.* measured TPO activity-inhibiting immunoglobulin (TPII) in patients with Graves' or Hashimoto's disease

(32). They reported that the mean TPII index in patients with Hashimoto's thyroiditis was significantly higher than that in Graves' disease, and that the mean serum free T<sub>4</sub> concentration was significantly lower in those patients with Hashimoto's thyroiditis who had positive TPII index values than in those with negative TPII index values. They concluded that TPII appears to inhibit thyroid function in some patients, but no simple relationship between TPII and thyroid function in autoimmune thyroid disease was demonstrated.

According to Tables 1 and 2, the TPO activity in the cytoplasm of thyroid follicular cells of patients with Hashimoto's thyroiditis is rather weak compared with that of normal thyroid. However, it is difficult to assume that TPII inhibits the activity of the enzyme, because of its inaccessibility to the cytoplasm of thyroid follicular cells (33).

Considering that most patients with Hashimoto's thyroiditis express HLA-DR antigens in the thyroid epithelial cells (34), and that TSH enhances the INF- $\gamma$ -induced HLA-DR expression in cultured normal human thyrocytes (35), TSH might play some role in the expression and/or maintenance of thyroid immune responses in Hashimoto's thyroiditis by developing thyroid microsomal antigens.

## References

1. Taurog A: Thyroid peroxidase thyroxine biosynthesis. *Recent Progr Horm Res* (1970) **26**, 189-247.
2. Nunez J and Pommier J: Formation of thyroid hormones. *Vitam Horm* (1982) **39**, 175-229.
3. Hosoya T, Matsukawa S and Nagai Y: Localization of peroxidase and other microsomal enzymes in thyroid cells. *Biochemistry* (1971) **10**, 3086-3092.
4. Valenta LJ, Valenta V, Wang CA, Vickery AL Jr, Caulfield J and Maloof F: Subcellular distribution of peroxidase activity in human thyroid tissue. *J Clin Endocrinol Metab* (1973) **37**, 560-569.
5. Strum JM and Karnovsky MJ: Cytochemical localization of endogenous peroxidase in thyroid follicular cells. *J Cell Biol* (1970) **44**, 655-666.
6. Tice LW and Wollmann SH: Ultrastructural localization of

- peroxidase on pseudopods and other structures of the typical thyroid epithelial cell. *Endocrinology* (1984) **94**, 1555-1567.
7. Regard E, Fragu P, Beaumont A and Nataf BM : Peroxidase activity in human benign thyroid disorders : Measure and localization ; in *Thyroid Research VII, Proceedings of the 7th International Thyroid Conference (Boston)*, Excerpta Medica, Amsterdam (1975) pp 474-476.
  8. Nakashima T and Taurog A : Improved assay procedures for thyroid peroxidase : Application to normal and adenomatous human thyroid tissue. *Clin Chim Acta* (1978) **83**, 129-140.
  9. Nagasaka A, Hidaka H and Ishizuki Y : Studies on human iodide peroxidase : Its activity in various thyroid disorders. *Clin Chim Acta* (1975) **62**, 1-4.
  10. Fragu P and Nataf BM : Human thyroid peroxidase activity in benign and malignant thyroid disorders. *J Clin Endocrinol* (1977) **45**, 1089-1096.
  11. Fragu P and Nataf BM : Thyroid peroxidase activity in human differentiated carcinoma. *Ann Radiol* (1977) **20**, 728-730.
  12. Hosoya T, Sato I, Hiyama Y, Yoshimura H, Niimi H and Tarutani O : An improved assay method for thyroid peroxidase for a few milligram of abnormal human thyroid tissues. *J Biochem* (1978) **83**, 129-140.
  13. McLean IW and Nakane PK : Periodate-lysine-paraformaldehyde fixative : A new fixative for immunoelectron microscopy. *J Histochem Cytochem* (1974) **22**, 1077-1083.
  14. Nishii T : Electron microscopic studies on subcellular localization of human thyroid microsomal antigen and its relation to thyroid peroxidase. *J Clin Electron Microsc* (1989) **22**, 127-139 (in Japanese).
  15. Mizukami Y, Matsubara F and Matsukawa S : Cytochemical localization of peroxidase and hydrogen-peroxide-producing NAD (P) H-oxidase in thyroid follicular cells of propylthiouracil-treated rats. *Histochemistry* (1985) **82**, 263-268.
  16. Pincera A, Fenzi GF, Vitti P, Chiovato L, Macchia E and Mariotti S : Significance of thyroid autoantibodies in autoimmune thyroid diseases ; in *Autoimmunity and the Thyroid*, Walfish, Wall and Volpe eds, Academic Press, Orland (1985) pp 139-152.
  17. Khoury EL, Hammond L, Bottazzo GF and Doniach D : Presence of microsomal antigens on the surface of human thyroid cells in culture : Its involvement in complement-mediated cytotoxicity. *Clin Exp Immunol* (1981) **45**, 316-328.
  18. Banga P, Pryce G, Hammond L and Roitt IM : Structural features of the autoantigens involved in thyroid autoimmune disease : The thyroid microsomal/microvillar antigen. *Mol Immunol* (1985) **22**, 629-642.
  19. Hamada N, Grimm C, Mori H and De Groot LJ : Identification of a thyroid microsomal antigen by western blot and immunoprecipitation. *J Clin Endocrinol Metab* (1985) **61**, 61-128.
  20. Banga JP, Mirakian R, Hammond L, Pryce D, Bidey S, Bottazzo F, Weetman AP, McGregor AM and Roitt IM : Characterization of monoclonal antibodies directed towards the microsomal/microvillar thyroid autoantigen recognized by Hashimoto autoantibodies. *Clin Exp Immunol* (1986) **64**, 544-554.
  21. Czarnocka B, Ruf J, Ferrand M, Carayon P and Lissitzky S : Purification of the human thyroid peroxidase and its identification as the microsomal antigen involved in autoimmune thyroid disease. *FEBS (Fed Eur Biochem Soc) Lett* (1985) **190**, 147-152.
  22. Portmann L, Hamada N, Heinrich G and DeGroot LJ : Antithyroid peroxidase antibody in patients with autoimmune thyroid disease : Possible identity with anti-microsomal antibody. *J Clin Endocrinol Metab* (1985) **61**, 1001-1003.
  23. Mariotti S, Anelli S, Ruf J, Bechi R, Czarnocka B, Lombardi A, Carayon P and Pinchera A : Comparison of serum microsomal and thyroid peroxidase autoantibodies in thyroid disease. *Clin Endocrinol Metab* (1987) **65**, 987-993.
  24. Czarnocka B, Ruf J, Ferrand M, Lissitzky S and Carayon P : Interaction of highly purified peroxidase with antimicrosomal antibodies in autoimmune thyroid diseases. *J Endocrinol Invest* (1986) **9**, 135-138.
  25. Strum JM and Karnovsky V : Cytochemical localization of endogenous peroxidase in thyroid follicular cells. *J Cell Biol* (1970) **44**, 655-666.
  26. Tice LW and Wollman SH : Ultrastructural localization of peroxidase activity on some membranes of the typical thyroid epithelial cell. *Lab Invest* (1972) **26**, 63-73.
  27. Matsukawa S, Mihara S and Hosoya T : Thyrotropin-dependence of the distribution of peroxidase in rat thyroid gland. *Tohoku J Exp Med* (1981) **133**, 431-443.
  28. Yamashita H, Noguchi S, Murakami N, Moriuchi A, Hodo M, Yokoyama S, Mochizuki Y, Noguchi A and Nakayama I : Ultrastructural localization of endogenous peroxidase in the human thyroid gland under normal and hyperfunctioning conditions. *Acta Pathol Jpn* (1984) **34**, 553-561.
  29. Chiovato L, Vitti P, Cuchi P, Mammoli C, Carajon P and Pinchera A : The expression of the microsomal/peroxidase autoantigen in human thyroid cells is thyrotrophin dependent. *Clin Exp Immunol* (1989) **76**, 47-53.
  30. Kotani T, Umeki K, Matsunaga S, Kato E and Ohtaki S : Detection of autoantibodies to thyroid peroxidase in autoimmune thyroid diseases by micro-ELISA and immunoblotting. *J Clin Endocrinol Metab* (1986) **62**, 928-933.
  31. Kohno Y, Hiyama Y, Shimojyo N, Niimi H, Nakajima H and Hosoya T : Autoantibodies to thyroid peroxidase in patients with chronic thyroiditis : Effect of antibody binding on enzyme activities. *Clin Exp Immunol* (1986) **65**, 534-541.
  32. Okamoto Y, Hamada N, Saito H, Ohno M, Noh J, Ito K and Morii H : Thyroid peroxidase activity-inhibiting immunoglobulins in patients with autoimmune thyroid disease. *J Clin Endocrinol Metab* (1989) **68**, 730-734.
  33. Yamamoto N, Nishii T, Suzuki S, Hirakawa S, Yamahara S and Ota Z : Inhibition of the endogenous thyroid peroxidase activity of Graves' thyroid by the thyroid microsomal antibody : A histochemical electron microscopic study. *J Clin Electron Microsc* (1989) **22** (in press).

- Electron Microsc (1989) **22** (in press).
34. Lloyd RV, Johnson TL, Blaivas M, Sisson JC and Wilson B : Detection of HLA-DR antigens in paraffin embedded thyroid epithelial cells with a monoclonal antibody. *Am J Pathol* (1985) **120**, 106-111.
35. Aguayo J, Itaka M, Row VV and Volpe R : Studies of HLA-DR expression on cultured human thyrocytes: Effect of antithyroid drugs and other agents on interferon- $\gamma$ -induced HLA-DR expression. *J Clin Endocrinol Metab* (1988) **66**, 903-908.
- Received October 5, 1989; accepted December 5, 1989.