

Acta Medica Okayama

Volume 60, Issue 1

2006

Article 8

FEBRUARY 2006

Surgical results of sacral perineural (Tarlov) cysts.

Masato Tanaka* Shinnosuke Nakahara[†] Yauo Ito[‡]
Kazuo Nakanishi** Yoshihisa Sugimoto^{††}
Hisanori Ikuma^{‡‡} Toshifumi Ozaki[§]

*Okayama University,

[†]National Okayama Medical Center,

[‡]Kobe Red Cross Hospital,

**Okayama University,

^{††}Okayama University,

^{‡‡}Okayama University,

[§]Okayama University,

Surgical results of sacral perineural (Tarlov) cysts.*

Masato Tanaka, Shinnosuke Nakahara, Yauo Ito, Kazuo Nakanishi, Yoshihisa Sugimoto, Hisanori Ikuma, and Toshifumi Ozaki

Abstract

The purpose of this study was to investigate the surgical outcomes and to determine indicators of the necessity of surgical intervention. Twelve consecutive patients harboring symptomatic sacral perineural cysts were treated between 1995 and 2003. All patients were assessed for neurological deficits and pain by neurological examination. Magnetic resonance of imaging, computerized tomography, and myelography were performed to detect signs of delayed filling of the cysts. We performed a release of the valve and imbrication of the sacral cysts with laminectomies in 8 cases or recapping laminectomies in 4 cases. After surgery, symptoms improved in 10 (83%) of 12 patients, with an average follow-up of 27 months. Ten patients had sacral perineural cysts with signs of positive filling defect. Two (17%) of 12 patients experienced no significant improvement. In one of these patients, the filling defect was negative. In conclusion, a positive filling defect may become an indicator of good treatment outcomes.

KEYWORDS: Tarlov cyst, sacral perineural cyst, meningeal cyst, meningeal diverticulum, sacral radiculopathy

*PMID: 16508691 [PubMed - indexed for MEDLINE]

Copyright (C) OKAYAMA UNIVERSITY MEDICAL SCHOOL

Case Report

Surgical Results of Sacral Perineural (Tarlov) Cysts

Masato Tanaka^{a*}, Shinnosuke Nakahara^b, Yasuo Ito^c, Kazuo Nakanishi^a,
Yoshihisa Sugimoto^a, Hisanori Ikuma^a, and Toshifumi Ozaki^d

^aDepartment of Orthopaedic Surgery, Okayama University Hospital, Okayama 700-8558, Japan,

^bDepartment of Orthopaedic Surgery, National Okayama Medical Center, Okayama 701-1192, Japan,

^cDepartment of Orthopaedic Surgery, Kobe Red Cross Hospital, Kobe 651-0073, Japan, and

^dDepartment of Orthopaedic Surgery, Okayama University Graduate School of Medicine,
Dentistry and Pharmaceutical Sciences, Okayama 700-8558, Japan

The purpose of this study was to investigate the surgical outcomes and to determine indicators of the necessity of surgical intervention. Twelve consecutive patients harboring symptomatic sacral perineural cysts were treated between 1995 and 2003. All patients were assessed for neurological deficits and pain by neurological examination. Magnetic resonance of imaging, computerized tomography, and myelography were performed to detect signs of delayed filling of the cysts. We performed a release of the valve and imbrication of the sacral cysts with laminectomies in 8 cases or recapping laminectomies in 4 cases. After surgery, symptoms improved in 10 (83%) of 12 patients, with an average follow-up of 27 months. Ten patients had sacral perineural cysts with signs of positive filling defect. Two (17%) of 12 patients experienced no significant improvement. In one of these patients, the filling defect was negative. In conclusion, a positive filling defect may become an indicator of good treatment outcomes.

Key words: Tarlov cyst, sacral perineural cyst, meningeal cyst, meningeal diverticulum, sacral radiculopathy

Tarlov or sacral perineural cysts are lesions of the nerve root that are most often found in the sacral region. They were first described by Tarlov [1] during his autopsy studies of the filum terminale. Since then, fewer than 100 cases of symptomatic Tarlov cysts have been reported in the literature [2-13]. Asymptomatic sacral perineural cysts are quite often a coincidental finding when lumbar magnetic resonance (MR) imaging is performed for other reasons [1]. Asymptomatic sacral perineural cysts have

been found in approximately 1% of lumbar MR imaging cases [14]. Nevertheless, sacral perineural cysts may cause local pain or radicular symptoms. The symptoms are most frequently exacerbated by standing, sitting, walking, and coughing, all of which elevate the cerebrospinal fluid (CSF) pressure.

There is no consensus on the appropriate surgical indications and treatment of symptomatic sacral perineural cysts. Some authors recommend that larger (< 1.5 cm) cysts and/or large bony destruction be used to determine if surgery or radiologic evaluation is necessary [15], but there is no other clear indicator. In the present study, we examined the difference between a meningeal diverticulum and a menin-

Received May 6, 2005; accepted September 21, 2005.

*Corresponding author. Phone: +81-86-235-7273; Fax: +81-86-223-9227
E-mail: tanakam@md.okayama-u.ac.jp (M. Tanaka)

geal cyst. The former fills immediately with dye during a myelographic study, collapses when compressed intraoperatively, and subsequently refills. Conversely, the latter does not fill with dye (positive filling defect sign), and compression fails to obliterate its contents. This study analyzes the outcomes of 12 consecutive patients harboring symptomatic sacral perineural cysts. We emphasize that symptomatic sacral perineural cysts usually have a valve mechanism, which engrosses the cyst, causes bony erosion, and results in neural compression (Figs. 1, 2). We suggest that the filling defect sign might be a useful

surgical indicator.

Patients and Methods

Patient Selection. In this retrospective study examining cases between 1996 and 2003, 12 patients (5 women and 7 men) aged 21 to 72 years (mean 50.6 years) harboring symptomatic sacral perineural cysts underwent sacral recapping laminectomy (or simple laminectomy) with resection (or imbrication) of the cyst or cysts. Every patient experienced progressively worsening symptoms, even though intensive

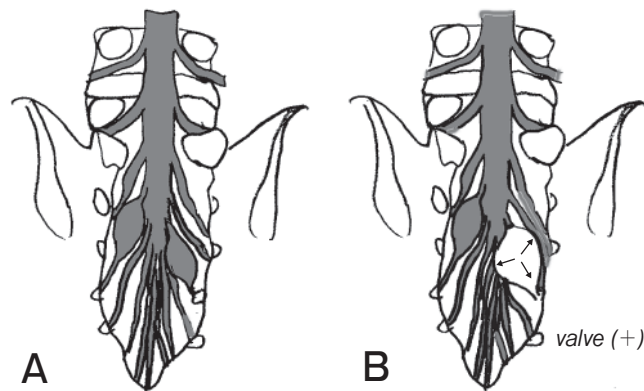


Fig. 1 Filling defect sign. **A**, The figure shows the negative filling defect sign, which means that the cyst fills with dye in myelography; **B**, The figure shows the positive filling defect sign, which means that the cyst does not fill with dye and compresses the other roots (arrows) in myelography.

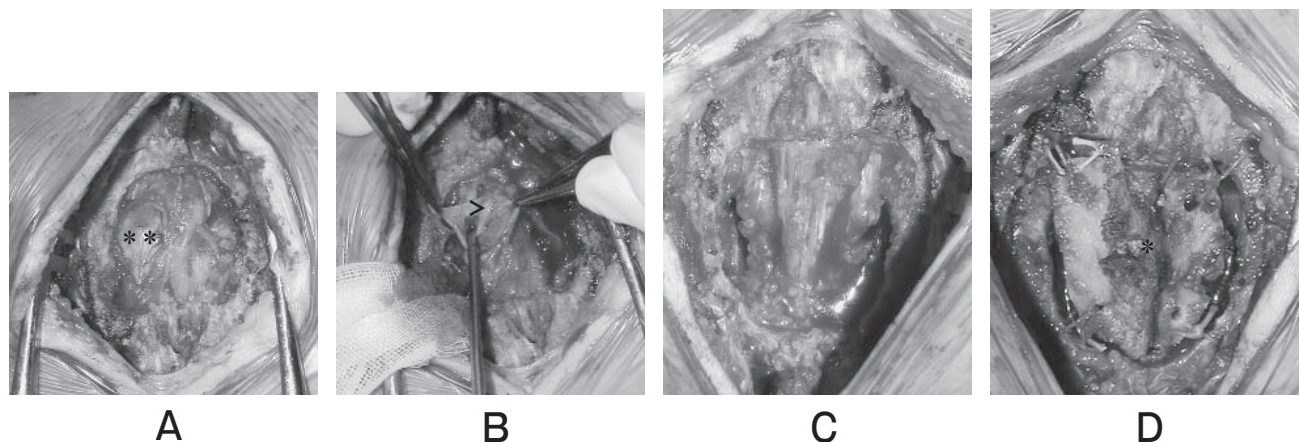


Fig. 2 Operative method. **A**, Sacral recapping laminectomy revealed that the cysts (***) originating from the both S-3 nerve root (>) were compressing both the S-2 nerve root sleeves; **B**, The sacral perineural cysts were cut down; **C**, The cysts were imbricated; **D**, The lamina (*) was recapped at the original place (Recapping laminectomy).

conservative treatments were performed. Patients were included in the study if they met the following inclusion criteria: 1) radiological findings consistent with sacral perineural cysts and 2) neurological symptoms attributable to sacral perineural cysts. The average follow-up time obtained from return visits to the hospital was 31.7 months (range 6–52 months).

Neurological and Pain Assessment. All patients had a complete direct neurological examination performed. We examined deep tendon reflex, pathological reflex, sensory deficits, muscle weakness, bowel/bladder symptoms, leg weakness, and sensory disturbance. Pain was classified into radicular pain, coccydynia, and buttock pain, and the grade of pain was classified as mild, moderate, or severe.

Surgical Technique (Fig. 2). An incision was made from L-5 to S-3, and the involved sacral laminae were entirely exposed. Recapping laminectomy (last 4 cases) or simple laminectomy was performed with surgairtome, with care being taken to preserve the integrity of the underlying sacral perineural cysts. Each sacral perineural cyst was dissected from the surrounding structures. The cysts

appeared initially to be adhesive to the surrounding structures; however, the cyst wall was dissected away from the adjoining root sleeves and sacrum with which the diaphanous cyst was closely approximated. A small neck and valve mechanism was demonstrated in 7 cases.

Care was taken to avoid large neural elements that lie along the ventral aspect of the cyst wall. The cyst wall was cut down and sutured to narrow (imbricate) and release the valve. Lumbar drains were used, and the wound was closed in water-tight layers.

Pathological Examination. Resected material from 10 of the 12 patients was submitted for pathological evaluation. The specimens were formalin-fixed and paraffin embedded. Hematoxylin and eosin-stained sections in all 8 cases were available for independent review by a pathologist.

Results

Patient Characteristics. Patient characteristics and findings are presented in Table 1.

Radiologic Findings. The levels of the cysts according to vertebra were S1–2, 3 cases; S2, 3 cases; S2–3, 4 cases; S3–4, 2 cases. Bony erosion

Table 1 Clinical Characteristics and Outcome of Patients

Case No.	Age (yrs), Sex	Main symptom	Filling defect sign	Operative method	Origin root	cyst size (cm)	Follow up (months)	Post op course	Complication
1	66, M	coccydynia, dysuria	+	laminectomy, res of ltS5, imb of rtS3,4	ltS5, rtS3,4	3.0	18	improve	prostitis
2	43, M	sciatica, lumbago	+	laminectomy, imb of bS3, rtS2	bS3, rtS2	2.0	17	improve	
3	64, F	buttock pain, pollikisuria	+	laminectomy, imb of ltS3	rtS3	4.2	6	improve	cerebellar bleeding
4	50, F	coccydynia, dysuria	–	laminectomy, res of rtS5, imb of bS4	bS4, rtS5	1.6	24	no change	
5	21, F	buttock pain	+	laminectomy, res of ltS3	bS3	2.0	60	improve	
6	50, M	buttock pain	+	laminectomy, imb of bS3, rtS4	bS3, rtS4	1.5	24	improve	
7	55, M	leg dysesthesia	+	laminectomy, imb of bS2	bS2	1.6	16	no change	
8	29, F	buttock pain, sciatica	+	laminectomy, res of rtS4	rtS2,3,4, ltS3	2.0	48	improve	
9	32, M	coccydynia, dysuria	+	recapping, ltS3, rtS4	rtS3, ltS3,4	2.1	12	improve	
10	72, M	pollikisuria, sciatica	+	recapping, imb of ltS3, rtS4	ltS3, rtS4	1.7	11	improve	
11	57, M	urinary incontinence	NA	recapping, imb of bS3	bS4	2.1	6	improve	
12	68, F	coccydynia	+	recapping, imb of ltS4	ltS4	2.4	8	improve	

imb = imbrication, res = resection

was identified in 10/12 cases in CT or radiography. MR imaging showed that all cysts were iso intense to CSF on both T1-weighted and T2-weighted images (Fig. 3). Myelography and CT were performed in all but 1 patient, and 10 patients had a positive filling defect (Fig. 4), while 1 had a negative filling defect.

Clinical Findings. Preoperative symptoms were lumbosacral pain in 8 cases, urinary distur-

bance in 8 cases, perianal pain in 5 cases, leg pain in 2 cases, sensory disturbance in 8 cases, and leg weakness in 1 case.

The distribution of symptoms in the patients in our series is presented in Table 1. Two (17%) of 12 patients experienced no significant improvement. In 1 patient, the filling defect was negative (Table 1).

The sacral pain of recapping laminectomy cases

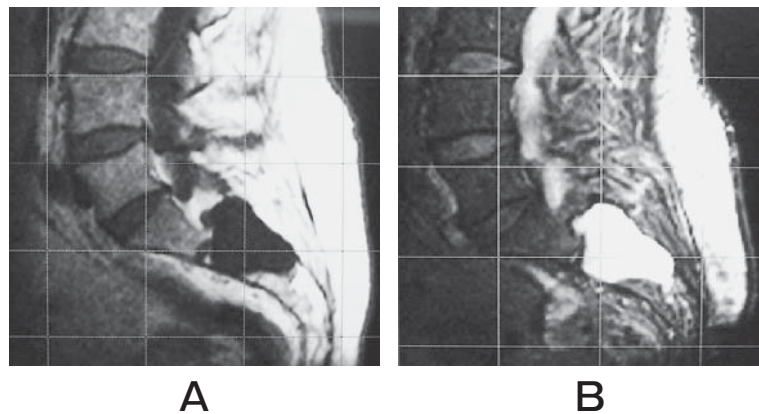


Fig. 3 MRI of the sacral perineural cyst. **A**, 64-year-old female, sacral perineural cyst occurring from the S3 root. Magnetic resonance imaging demonstrated two 5 × 2-cm cystic masses occupying the sacral canal (S2), and compression of the sacral nerve roots. The figure shows a T1-weighted image; **B**, The figure shows a T2-weighted image.

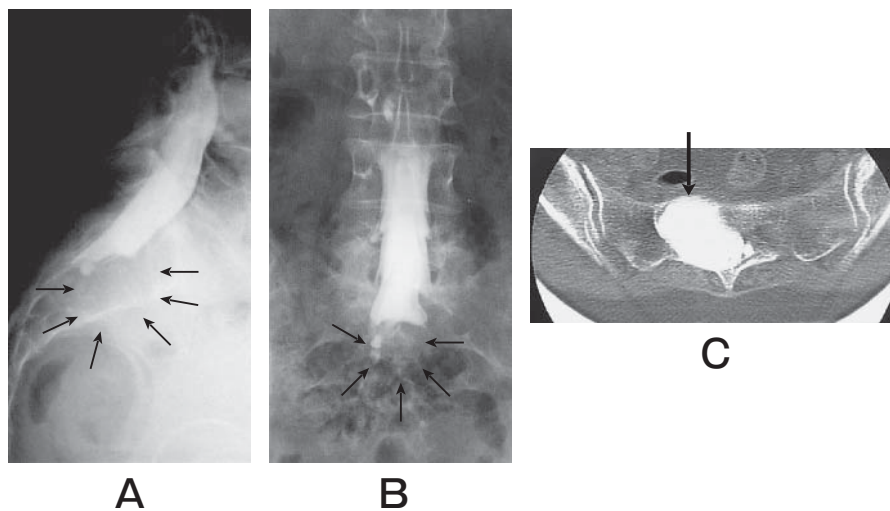


Fig. 4 Myelography and CT of the sacral perineural cyst. **A**, The figure shows a lateral myelogram. The cyst was not immediately filled with dye (small arrow); **B**, The figure shows an anteroposterior Myelogram; **C**, CT-myelography shows that the cyst was filled with dye at 6 h post-myelography, which means that there was communication between the cyst and the arachnoid space (big arrow).

was lower than that of simple laminectomy cases.

Operative Findings. Ten (83%) of 12 patients harbored multiple perineural cysts. Two (16%) of the 12 cysts were located at the S-2 root, 7 (58%) at the S-3, 7 (58%) at the S-4, and 2 (16%) at the S-5 root. The average cyst diameter was 2.4 cm.

Postoperative Findings. Ten (83%) of 12 patients experienced complete or substantial resolution of their symptoms. Two (17%) of 12 patients experienced no significant improvement, with an average follow-up of 23 months. Postoperative pain relief was obtained in 4 of 8 cases; recovery of urinary disturbance was obtained in 5 of 7 cases. Perianal pain disappeared in all cases (out of 4 cases), and no leg pain relief was obtained. Postoperatively, 1 patient suffered from cerebral bleeding, and another patient suffered from prostatitis. The remaining 10 patients had no postoperative complications. The postoperative course and complications of all patients are summarized in Table 1.

Pathological Findings. Hematoxylin and eosin-stained sections from 8 of 10 cases were available for independent review by a pathologist. As determined by light microscopy, the cyst walls were mostly composed of dense, paucicellular collagenous bundles along with variable amounts of well-vascularized loose fibrous tissue. Nerve fibers were present in eight (80%) of 10 cases.

Discussion

Pathogenesis of sacral perineural cyst.

The cause of sacral perineural cysts remains unclear, but several theories have been proposed. Tarlov [10] has postulated that sacral perineural cysts occur because of breakage of venous drainage in the perineural and epineuria secondary to hemosiderin deposition after trauma. Fortuna *et al.* [16] have considered sacral perineural cysts to be the result of congenital arachnoidal proliferation along the exiting sacral nerve roots. Paulsen *et al.* [14] suggest that the cysts enlarge because of a ball-valve effect, whereby CSF enters the cyst with systolic pulsation but is unable to exit through the same portal during diastole. In this theory, the filling defect sign is postulated to indicate the existence of a valve mechanism of the cyst (Fig. 1).

Tarlov [10] has noted that these cysts are often

multiple, extending around the circumference of the nerve, and can enlarge to impinge on neighboring nerve roots and cause significant bone erosions. These characteristics clearly distinguish these cysts from meningeal diverticula. In our series, all cysts were located at the junction of the posterior nerve root and the dorsal root ganglion and were found intraoperatively to be noncompressible.

Operative indication. Successful surgical treatment of sacral perineural cysts is dependent on appropriate patient selection. Asymptomatic sacral perineural cysts account for approximately 1% of a coincidental finding when lumbar MRI is performed for other reasons [14]. For this reason, whether or not a patient's chief complaints are due to the cysts is an important problem for surgeons. Anecdotal evidence suggests that patients do not benefit from surgery because of recurrence of symptoms or surgical complications [17].

The specific/curable symptoms are coccydynia and dyspareunia sacral/perianal pain and urinary disturbance. In our series, post operative sacral/perianal pain relief was obtained in all of 4 cases, and recovery of urinary disturbance was obtained in 5 of 7 cases.

On the other hand, sciatica and vague lumbago are nonspecific/residual symptoms. Tarlov [18] has postulated that these cysts could cause sacral radiculopathy and has documented a case in which removal of the cyst relieved sciatica. However, sciatica is not a typical symptom, so in explaining the surgical benefits to patients, this fact should be kept in mind.

Voyadzis *et al.* [15] suggest that patients with neurological deficits that are anatomically related to Tarlov cysts greater than 1.5 cm in diameter enjoy substantial improvement following cyst resection.

In our series, 2 patients experienced no resolution of symptoms. One of these (case 4) indicated a negative filling defect sign, and the cyst may not have compressed adjacent roots. Positive results were not achieved in another patient (case 7), despite the positive filling defect sign. The size of the cyst was 1.3 cm and smaller than the average size. In addition, his symptom was leg dysesthesia, which is a nonspecific/residual symptom of sacral cysts. A positive filling defect and large cyst size may therefore be indicators of good treatment outcomes.

Operative method. There has been a great

deal of controversy regarding the means of treatment of symptomatic sacral perineural cysts and the efficacy of the treatments available.

1. Lumbar drainage

The efficacy of permanent CSF drainage as provided by a lumboperitoneal shunt has been reported [8, 19]. Paulsen *et al.* [14] have reported the results of a CT-guided method for percutaneous drainage of sacral perineural cysts. Five patients experienced instant pain relief lasting from 3 weeks to 6 months, but 4 of the five patients suffered a recurrence of symptoms. On the other hand, Voyadzis *et al.* [15] do not recommend percutaneous drainage because one of their three patients for whom percutaneous drainage was utilized experienced a worsening of symptoms due to nerve root injury. Furthermore, there have been some reports that percutaneous drainage can lead to a temporary worsening of previous symptoms [3, 7, 8].

2. Cyst imbrication

We recommend microsurgical treatment consisting of cyst excision combined with direct closure of the dura or placcation of the cyst wall, which has been reported by some authors [3, 15]. There is neural tissue in the cyst wall and the cyst itself; simple resection is a hazard to the sacral nerve.

Conclusions. The valve mechanism of the cyst may play an important role in the pathogenesis of sacral perineural cysts. Our theory is that a positive filling defect sign is a good indicator to assess the valve mechanism of the cyst and may become an operative indicator.

References

1. Tarlov IM: Perineural cysts of the spinal nerve roots. *Arch Neurol Psychiatry* (1938) 40: 1067-1074.
2. Davis DH, Wilkinson JT, Teaford AK and Smigiel MR: Sciatica produced by a sacral perineural cyst. *Texas Med* (1987) 83: 55-56.
3. Mummaneni PV, Pitts LH, McCormack BM, Corro JM and Weinstein PR: Microsurgical treatment of symptomatic Tarlov cysts. *Neurosurgery* (2000) 47: 74-79.
4. Nabors MW, Pait TG, Byrd EB, Karim NO, Davis DO, Koblina AI and Rizzoli HV: Updated assessment and current classification of spinal meningeal cysts. *J Neurosurg* (1988) 68: 366-377.
5. Schreiber F and Haddad B: Lumbar and sacral cysts causing pain. *J Neurosurg* (1951) 8: 504-509.
6. Seaman WB and Furlow LT: The myelographic appearance of sacral cysts. *J Neurosurg* (1956) 13: 88-94.
7. SPhonela L, Gambardella A and Maiuri F: Giant sacral perineural cyst. A case report. *Clin Neurol Neurosurg* (1989) 91: 343-346.
8. Strully K and Heiser S: Lumbar and sacral cysts of meningeal origin. *Radiology* (1954) 62: 544-549.
9. Taheri ZE, Riemenschneider P and Ecker A: Case reports and technical notes: myelographic diagnosis of sacral perineural cyst. *J Neurosurg* (1952) 9: 93-95.
10. Tarlov IM: Spinal perineural and meningeal cysts. *J Neurol Neurosurg Psychiatry* (1970) 33: 833-843.
11. Tarlov IM: Sacral Nerve-Root Cysts: Another Cause of the Sciatic or Cauda Equina Syndrome, Charles C Thomas eds, Springfield (1953) pp 56-116.
12. Wilkins RH: Intraspinal cysts; in *Neurosurgery*, Wilkins RH and Rengachary SS eds, McGraw-Hill, New York (1996) pp 2061-2070.
13. Willinsky RA and Fazl M: Computed tomography of a sacral perineural cyst. *J Comput Assist Tomogr* (1985) 9: 599-601.
14. Paulsen RD, Call GA and Murtagh FR: Prevalence and percutaneous drainage of cysts of the sacral nerve root sheath (Tarlov cysts). *Am J Neuroradiol* (1994) 15: 293-299.
15. Voyadzis JM, Bhargava P and Henderson FC: Tarlov cysts: a study of 10 cases with review of the literature. *J Neurosurg* (2001) 95: 25-32.
16. Fortuna A, La Torre E and Ciappetta P: Arachnoid diverticula: a unitary approach to spinal cysts communicating with the subarachnoid space. *Acta Neurochir* (1977) 39: 259-268.
17. Tarlov E: Occult, bilateral anterior sacral and intrasacral meningeal and perineural cysts: case report and review of the literature. *Neurosurgery* (1990) 27: 986.
18. Tarlov IM: Cysts (perineural) of the sacral roots: another cause (removable) of sciatic pain. *JAMA* (1948) 138: 740-744.
19. BarPhones RH and van Overbeeke JJ: Lumbar cerebrospinal fluid drainage for symptomatic sacral nerve root cysts: an adjuvant diagnostic procedure and/or alternative treatment? Technical case report. *Neurosurgery* (1997) 40: 861-865.