

Acta Medica Okayama

Volume 43, Issue 2

1989

Article 5

APRIL 1989

A cytogenetic study of nonpolymalformed patients with mental retardation of clinically undefined etiology: application of a high resolution banding technique.

Kiyoshi Kikkawa*

Kouji Narahara[†]

Hiroshi Kimoto[‡]

*Okayama University,

[†]Okayama University,

[‡]Okayama University,

A cytogenetic study of nonpolymalformed patients with mental retardation of clinically undefined etiology: application of a high resolution banding technique.*

Kiyoshi Kikkawa, Kouji Narahara, and Hiroshi Kimoto

Abstract

We performed a cytogenetic study on 140 nonpolymalformed patients with mental retardation of clinically undefined origin, using a high resolution banding technique, to determine how much chromosome abnormalities contribute to the etiology of this condition. A total of 15 patients (10.7%) were found to have autosomal or sex chromosomal abnormalities. Autosomal abnormalities included partial monosomy (5 cases), reciprocal translocation (one case), 13/14 robertsonian translocation (3 cases), unbalanced translocation (one case), inverted duplication of 15q (one case) and mosaic trisomy 21 (one case). Sex chromosomal abnormalities comprised structural rearrangement of the short arm of the X chromosome (one case) and 47, XXY in a pure or mosaic form (two cases). It should be noted that four out of the 5 cases of partial monosomy had subtle interstitial deletions, which might have been unidentified by the conventional G-banding method alone. In one case of the robertsonian translocation 46,XY,t(13;14)/45,XY,t(13;14), a small deletion was thought to have occurred in the cells with a chromosome number of 45. Comparison of clinical features of the 15 chromosomally abnormal patients with those of patients with normal karyotypes did not show any clinical parameter indicative of chromosome imbalance. These results suggest that a subtle chromosomal deletion is specific to mental retardation associated with few malformations. We believe that diagnostic evaluation of mentally retarded patients, even if nonmalformed, should include chromosome analysis using a high resolution banding technique.

KEYWORDS: chromosomes, high resolution banding technique, subtle interstitial deletion, mental retardation

*PMID: 2728904 [PubMed - indexed for MEDLINE]

Copyright (C) OKAYAMA UNIVERSITY MEDICAL SCHOOL

A Cytogenetic Study of Nonpolymalformed Patients with Mental Retardation of Clinically Undefined Etiology: Application of a High Resolution Banding Technique

Kiyoshi Kikkawa*, Kouji Narahara and Hiroshi Kimoto

Department of Pediatrics, Okayama University Medical School, Okayama 700, Japan

We performed a cytogenetic study on 140 nonpolymalformed patients with mental retardation of clinically undefined origin, using a high resolution banding technique, to determine how much chromosome abnormalities contribute to the etiology of this condition. A total of 15 patients (10.7%) were found to have autosomal or sex chromosomal abnormalities. Autosomal abnormalities included partial monosomy (5 cases), reciprocal translocation (one case), 13/14 robertsonian translocation (3 cases), unbalanced translocation (one case), inverted duplication of 15q (one case) and mosaic trisomy 21 (one case). Sex chromosomal abnormalities comprised structural rearrangement of the short arm of the X chromosome (one case) and 47, XXY in a pure or mosaic form (two cases). It should be noted that four out of the 5 cases of partial monosomy had subtle interstitial deletions, which might have been unidentified by the conventional G-banding method alone. In one case of the robertsonian translocation 46,XY,t(13;14)/45,XY,t(13;14), a small deletion was thought to have occurred in the cells with a chromosome number of 45. Comparison of clinical features of the 15 chromosomally abnormal patients with those of patients with normal karyotypes did not show any clinical parameter indicative of chromosome imbalance. These results suggest that a subtle chromosomal deletion is specific to mental retardation associated with few malformations. We believe that diagnostic evaluation of mentally retarded patients, even if nonmalformed, should include chromosome analysis using a high resolution banding technique.

Key words: chromosomes, high resolution banding technique, subtle interstitial deletion, mental retardation

The diagnosis, treatment and prevention of mental retardation is an important medical problem to pediatricians as well as to child neurologists. The prevalence of severe mental retardation (IQ below 50)

ranges from 0.22 to 0.58% and, if mild and borderline retardation is included, the rate reaches 3 to 4% of the general population (1). Although diagnostic assessments are essential for the treatment and genetic counselling of the families, the etiology has been elucidated in only about a half of re-

* To whom correspondence should be addressed.

tarded patients (2-4).

Large scale cytogenetic studies of the mentally retarded population have shown that approximately 20% of the patients have chromosome abnormalities (4-6). In view of the fact that chromosomal abnormality is one of the major etiologies of mental retardation, we have previously studied retarded patients with multiple congenital malformations whose phenotype could not be classified into any recognizable syndrome. We found chromosome abnormalities in an appreciable proportion (15%) of the patients (7). It is known that both malformations and the degree of mental retardation may be mild in certain chromosomal syndromes (8-9). Nonetheless, cytogenetic study has seldom been performed on nonpolymalformed patients with clinically undefined mental retardation.

The recent development of high resolution banding techniques has made it possible to analyze chromosomes in much more detail than with the conventional banding method, facilitating the detection of subtle chromosome imbalances (10-11). In the present paper, we describe the incidence and types of chromosome abnormalities found in mentally retarded patients with few malformations by a high resolution banding technique.

Materials and Methods

Subjects. A total of 140 nonpolymalformed subjects, consisting of 86 males and 54 females, were enrolled in this study. They were seen either in the out-patient service of the Department of Pediatrics, Okayama University Medical School Hospital or in that of Asahigawa Jidoin, Hospital for Handicapped Children, Okayama, from January, 1979 to September, 1988. Their ages at examination ranged from one year to 19 years, with an average of 5.3 years. Criteria for the enrollment were as follows: [1] The etiology of mental retardation was not recognizable clinically. All the patients under 3 years of age at examination were

followed and later found to have definite mental retardation (IQ below 85). Those with a family history of mental retardation, neonatal asphyxia, or progressive encephalopathy due to CNS degenerative or convulsive disorders (West and Lennox syndromes) were excluded from the study. [2] The patients had two or less malformations. In this study, two or more malformations which occurred in the same developmental field were assessed as a single malformation, in accordance with the report of Summitt (12). None of the subjects was found to have a severe motor handicap.

Cytogenetic study. Phytohemagglutinin-stimulated peripheral blood lymphocytes were cultured at 37°C for 68 to 72 h in Eagle's MEM supplemented with 15% (vol) bovine calf serum and kanamycin (100 µg/ml). As described previously (11), ethidium bromide (10 µg/ml) and Colcemid (0.05 µg/ml) were added to the cultures 2 h prior to harvest, and cells in early metaphase and prometaphase were collected. Standard techniques were used for hypotonic treatment and fixation. In all patients, air-dried slides aged 2 to 7 days were treated with 0.01% trypsin in phosphate buffered saline and stained with 2% Giemsa in 1/15 M Sørensen buffer (GTG-banding) (13). Where necessary, Q-banding by fluorescence using quinacrine (QFQ-banding) (14), R-banding by bromodeoxyuridine using acridine orange (RBA-banding) (15), C-banding by barium hydroxide using Giemsa (CBG-banding) (16), silver staining of nucleolar organizing regions (AgNOR-staining) (17) and distamycin A/4'-6-diamidino-2-phenylindole (DA/DAPI) staining (18) were further applied. A minimum of 10 cells per patient was counted, and at least 2 karyotypes over 550 bands per haploid set were analyzed. The chromosome designation was based on the International System for Human Cytogenetic Nomenclature (1985) (19). When a chromosome abnormality was detected, available relatives were also studied.

Statistical analysis. Furthermore, to determine whether any clinical feature indicated the presence of a chromosome abnormality, features including degree of mental retardation, number of malformations, birth weight, height at examination, and parental ages of patients with chromosome abnormalities were compared statistically with those with normal karyotypes. The birth weight

Table 1 Clinical features and karyotypes of the 15 patients with chromosome abnormalities

Case no.	Age (year)	Sex	Parental age at birth (year)		Birth weight (g)	Height (cm)	Severity of MR ^a	Karyotype	Parental origin	Malformations
			Pat.	Mat.						
1	1	F	33	27	2,500	70.8	Mild	46, XX, del (2) (q12 ; q14.2)	<i>de novo</i>	Frontal bossing
2	4	F	29	25	2,840	98.6	Mild	46, XX, del (2) (q33 ; q35)	<i>de novo</i>	Eye (strabismus, mongoloid slant)
3	7	M	30	29	3,750	110.4	Moderate	46, XY, del (5) (q22 ; q31)	<i>de novo</i>	Anteverted nostril, eye (strabismus, antimongoloid slant)
4	2	F	36	30	2,090	73.4	Moderate	46, XX, del (13) (q21.2 ; q22)	<i>de novo</i>	Glaucoma, carp like mouth
5	5	F	34	29	2,560	95.7	Moderate	46, XX, r (3) (p25 ; q29)	<i>de novo</i>	Microcephaly, CDH ^a
6	8	F	36	29	2,430	120.0	Severe	45, XX, t (13 ; 14) (p11.2 ; q11.2) or (q12.1 ; p11.2)	?	Clinodactyly, cleft palate
7	11	M	25	25	2,600	134.2	Profound	45, XY, t (13 ; 14) (p11.2 ; q11.2) or (q12.1 ; p11.2)	?	Clinodactyly, small penis
8	9	M	32	?	3,650	126.5	Mild	45, XY, t (13 ; 14) ^b /46, XY, t (13 ; 14) ^b	?	
9	2	M	32	28	3,760	102.0	Mild	46, XY, t (2 ; 3) (q13 ; p13)	father	
10	2	M	28	24	3,380	88.5	Mild	46, XY/47, XY, +21 (7%)	<i>de novo</i>	Finger (short, clinodactyly)
11	9	M	?	?	4,165	148.9	Borderline	46, XY, 1p+	<i>de novo</i>	
12	1	F	27	26	2,730	79.0	Profound	47, XX, +inv dup (15q)	<i>de novo</i>	CDH
13	1	M	26	24	3,100	72.3	Mild	46, Y, inv dup (X) (p22.1 ; p22.3)	<i>de novo</i>	Strabismus, malformed ear
14	3	M	?	26	3,100	99.2	Mild	47, XXY	<i>de novo</i>	Retentio testis, pulmonary stenosis
15	5	M	34	25	3,140	96.2	Profound	46, XY/47, XXY (40%)	<i>de novo</i>	Hypertrichosis

^a: Abbreviations: MR, mental retardation; CDH, congenital dislocation of the hip.

^b: Breakpoints are the same as in cases 6 and 7.

and height at examination were both expressed as standard deviation (SD) scores. The chi-square test and Student's *t* test were used for statistical analysis.

Results

Cytogenetic study. High-resolution banding analysis over the level of 550 bands per haploid set was successful in the majority of the subjects (115/140, 82.1%). In the 25 unsuccessful cases, chromosomes were analyzed using the conventional GTG-banding. A total of 15 patients were found to have a major chromosome abnormality. The

overall incidence of chromosome abnormalities was 10.7%. Karyotypes and clinical features of these patients are summarized in Table 1. The abnormalities consisted of autosomal abnormalities in 12 patients and sex chromosomal abnormalities in 3 patients. Among the cases of autosomal abnormalities, 5 cases (cases 1 to 5) were partial monosomy, 4 cases (cases 6 to 9) were reciprocal or robertsonian translocations, and the remaining 3 cases were mosaic trisomy 21 (case 10), unbalanced translocation (case 11) and extra chromosome, +inv dup (15q) (case 12). The sex chromosomal abnormalities included one case of a structural abnormality of the short arm of chromosome X

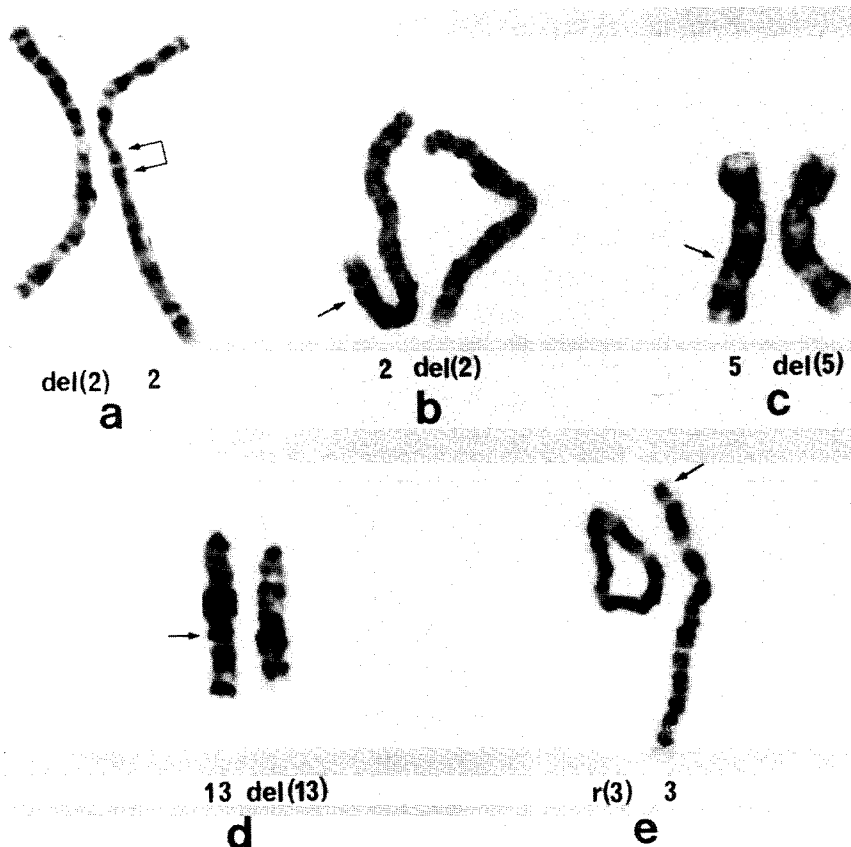


Fig. 1 Partial G-banded karyotypes of cases of partial monosomy: a, case 1; b, case 2; c, case 3; d, case 4 and e, case 5. Arrows indicate deleted chromosome segments. In case 3, high resolution banding analysis was unsuccessful.

(case 13) and 2 cases of Klinefelter syndrome (cases 14 and 15). The chromosome aberrations were found to have occurred *de novo* in 11 cases and to have been inherited in one case. In the 3 cases of 13/14 robertsonian translocation, the parental origin was not determined because of the unavailability of either of the parents' chromosomes. It should be noted that 4 out of the 5 cases of partial monosomy (cases 1 to 4) would not have been detected by the use of the conventional GTG-banding technique alone. Brief cytogenetic descriptions of the cases of chromosome abnormalities follow. Cases 1 to 5 (Fig. 1): In all but one of the cases of monosomy (case 5), deletions involved an interstitial chromosome segment, which corresponded to one to three bands at the level of 550 bands per haploid set. In case 5, the terminal regions of both the short and long arms of chromosome 3 were deficient. Case 8 (Fig. 2): The chromosome count was 45 in half of the cells examined and 46 in the remaining half. The minute chromosome in the cells with 46

chromosomes was considered to be derived from the translocation $t(13;14)(p11.2;q11.2)$ or $(q12.1;p11.2)$. This interpretation seemed to be supported by the single centromeric staining observed upon C-banding. Mitotic loss of the microchromosome might have resulted in the cells with 45 chromosomes. It is, therefore, concluded that deletion of the paracentromeric region of the long arm of either chromosome 13 or 14 was involved in this abnormality. The abnormality seemed to have occurred *de novo*, though a chromosome study could not be performed on the mother because she was dead. In cases 6 and 7, whose chromosome number was 45, cytogenetic findings were identical to those in the cells with 45 chromosomes in case 8. Case 9: Since the same chromosome rearrangement was found in the patient's father, a causal relationship

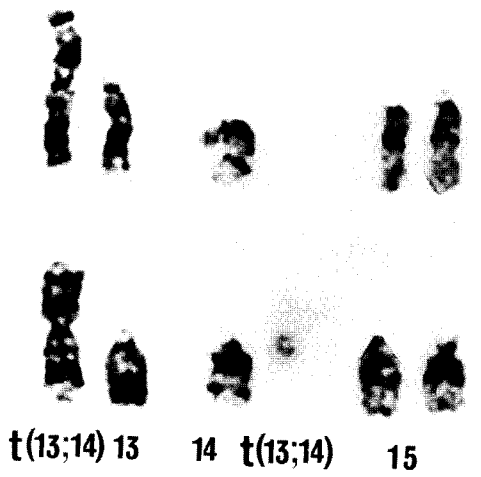

Fig. 2 Partial G-banded karyotypes of case 8 with 13/14 robertsonian translocation. The minute chromosome derived from the translocation in the cells with a chromosome number of 46 (lower panel) was missing in those with a chromosome number of 45 (upper panel).

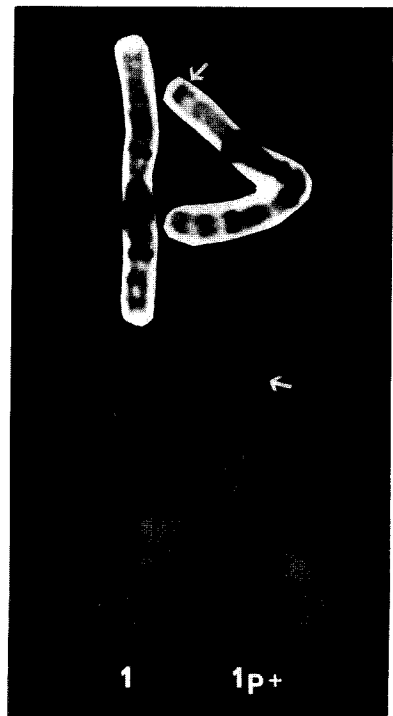


Fig. 3 Partial GTG-banding (top) and QFQ-banding (bottom) karyotypes of case 11. Arrows indicate a segment of unknown origin translocated onto the terminal portion of chromosome 1.

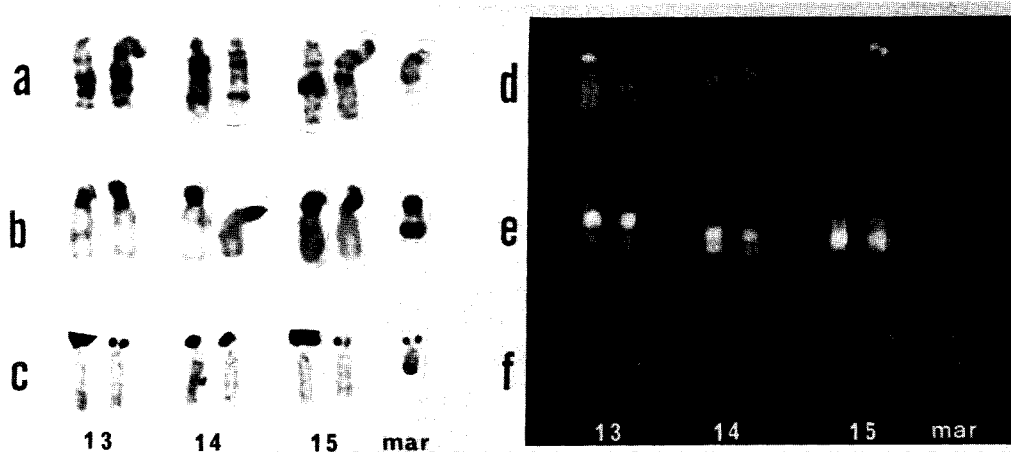


Fig. 4 Partial karyotypes of case 12, analyzed by GTG-banding (a), CBG-banding (b), AgNOR-staining (c), QFQ-banding (d), RFA-banding (e) and DA/DAPI-staining (f). The extra chromosome (mar) was confirmed to be inv dup (15) (p ter \rightarrow q 11.2 :: q 13 \rightarrow p ter).

between the abnormality and mental retardation seemed to be questionable. Case 11 (Fig. 3): An unidentifiable chromosome segment was found to have been translocated onto the terminal portion of chromosome 1. The case was therefore trisomic for the unknown autosomal segment as well as monosomic for the terminal portion of chromosome 1. Case 12 (Fig. 4): A G-like additional chromosome was observed in all cells examined. Its origin was confirmed to be inv dup (15) (p ter \rightarrow q 11.2 :: q 13 \rightarrow p ter) by means of QFQ-banding, CBG-banding, AgNOR-staining and DA/DAPI-staining. The clinical and cytogenetic findings of case 13 have already been reported elsewhere (20).

Statistical analysis of clinical features. Comparisons of clinical features of the patients with chromosome abnormalities with those of the patients with normal karyotypes showed a statistically significant difference only in the number of malformations. About twice as many patients with chromosome abnormalities as those with normal karyotypes were found to have two developmentally unrelated malformations [Table 2, 8/15 (53%) in the abnormal group vs. 30/125 (24%) in the normal group, $df = 2$, $\chi^2 = 6.07$, $0.05 > P > 0.025$]. However, the frequency of each malformation was similar in the two groups (data not shown). There was also no significant difference in the degree of mental retardation (Table 3, df

Table 2 Numbers of malformations in the patients with normal and abnormal karyotypes

No. of malformations	Karyotype		Total
	Normal	Abnormal	
0	52	3	55
1	43	4	47
2	30	8	38
Total	125	15	140

Table 3 Severity of mental retardation in the patients with normal and abnormal karyotypes

Severity of mental retardation	Karyotype		Total
	Normal	Abnormal	
Borderline to mild	56	8	64
Moderate to severe	49	4	53
Profound	20	3	23
Total	125	15	140

= 2, $\chi^2 = 0.03$, $P > 0.05$), paternal age (30.9 ± 3.6 in the abnormal group vs. 30.2 ± 3.8 in the normal group, $df = 113$, $t = 0.63$, $P > 0.05$), maternal age (24.7 ± 7.1 in the abnormal group vs. 27.0 ± 3.4 in the normal, $df = 115$, $t = 1.86$, $P > 0.05$), birth weight (-0.68 ± 2.18 in the abnormal group vs. -1.21 ± 1.82 in the normal, $df = 109$, $t = 1.00$, $P > 0.05$) and height at examination (-0.30 ± 1.14 in the abnormal group vs. -0.28 ± 0.97 in the normal, $df = 108$, $t = 0.09$, $P > 0.05$).

Discussion

An unexpectedly high proportion (10.7%) of nonpolymalformed patients with mental retardation of clinically undefined etiology had chromosome abnormalities. As shown in Table 4, there have been 10 cytogenetic studies of patients with multiple congenital malformations and idiopathic mental retardation (7, 12, 21-28), but only one other study has been reported concerning nonpolymalformed patients with mental retardation (28). The frequency of chromosome abnormalities in our study is 1.7 times as high as that in the comparative study (6.4%). The higher frequency can be attributed not only to the stricter selection criteria in our study but also to the use of the high resolution banding technique. Indeed, the 4 cases with a subtle interstitial deletion of autosomes would not have been identified without this technique. The present study did not investigate the fragile X chromosome abnormality cytogenetically. If the fragile X chromosome, which is known to be associated with minor phenotypic abnormalities (29), had been considered in our study, the overall incidence of chromosome abnormalities would have been even higher.

The comparison of the types of chromosome abnormalities found in studies of mental

retardates with multiple congenital malformations and those without such phenotypes (Table 4) has confirmed our assumption that autosomal trisomies are less frequent, while sex chromosomal abnormalities are more frequent in nonpolymalformed patients than in the polymalformed. It is intriguing that the ratio of autosomal monosomies is similar in the two groups, and that the frequency of 13/14 robertsonian translocation in the nonpolymalformed group is 3 times as high as that in the polymalformed group. Virtually all the monosomies in the nonpolymalformed group affected small interstitial autosomal segments or ring chromosomes in which neither the long arm nor short arm had significant deletions. As previously suggested (30), abnormalities involving chromosome segments containing few transcriptionally active genes vital to organ development can produce few phenotypic effects. Our findings imply that a subtle deletion of such a segment is a characteristic chromosome abnormality for nonpolymalformed patients with clinically undefined mental retardation.

The reason that the 13/14 robertsonian translocation is significantly more common in the nonpolymalformed group can be explained in the same way as for the aforementioned subtle deletions. There are two types of 13/14 robertsonian translocation: one involving a reunion between the short arms or centromeres of chromosomes 13 and 14, and the other involving a reunion between the short arm and long arm of these chromosomes (31). The former type of translocation exerts no harmful phenotypic effects and is often found in habitual aborters or parents delivering trisomy 13 infants. Since the incidence of the 13/14 translocation in the general population is estimated to be 0.1% (32), the occurrence of this type of translocation in the polymalformed group seems to be fortuitous. On the con-

Table 4 Chromosome abnormalities in malformed patients and nonmalformed patients^a with unclassifiable mental retardation

Authors	Cases examined	Autosomal abnormalities				Sex chromosome abnormalities no. (%)	Total no. (%)
		Trisomy ^b no. (%)	Monosomy ^c no. (%)	Translocation			
				Reciprocal no. (%)	Robertsonian no. (%)		
Malformed patients :							
Summitt, 1969	50	1 (2.0)	2 (4.0)	1 (2.0)			4 (8.0)
Daly, 1970	50	2 (4.0)	2 (4.0)	1 (2.0)	1 (2.0)	2 (4.0)	8 (16.0)
Carrel, 1973	121	11 (9.1)	5 (4.1)	1 (0.8)	1 (0.8)	1 (0.8)	19 (15.7)
Erdtmann, 1975	51	3 (5.9)	3 (5.9)			1 (2.0)	7 (13.7)
Doyle, 1976	90	3 (3.3)	1 (1.1)			1 (1.1)	5 (5.6)
Magnelli, 1976	50	4 (8.0)	2 (4.0)				6 (12.0)
Tharapel & Summitt, 1977	200	2 (1.0)		3 (1.5)			5 (2.5)
Narahara, 1981	74	6 (8.1)	4 (5.4)			1 (1.4)	11 (14.9)
Coco & Penchaszadeh, 1982	200	16 (8.0)	6 (3.0)	2 (1.0)		5 (2.5)	29 (14.5)
Ieshima & Takeshita, 1985	121	9 (7.4)	5 (4.1)		1 (0.8)	1 (0.8)	16 (13.2)
Total	1007	57 (5.7)	30 (3.0)	8 (0.8)	3 (0.3)	12 (1.2)	110 (10.9)
Nonmalformed patients :							
Ieshima & Takeshita, 1985	295	1 (0.3)	6 (2.0)	3 (1.0)	1 (0.3)	8 (2.7)	19 (6.4)
Present study	140	3 (2.1)	5 (3.6)	1 (0.7)	3 (2.1)	3 (2.1)	15 (10.7)
Total	435	4 (0.9)	11 (2.5)	4 (0.9)	4 (0.9)	11 (2.5)	34 (7.8)

a: 5p-, 13 trisomy, 18 trisomy, inv (9), fragile X, and Prader-Willi syndrome are excluded from calculation.

b: Includes unbalanced translocation.

c: Includes ring.

trary, the cytogenetic finding in our case 6 lends support to the hypothesis of a subtle deletion involved in the etiology of nonpolymalformed patients. In this case, the minute chromosome derived from the latter type of robertsonian translocation was missing in the cells with 45 chromosomes, resulting in monosomy for the paracentromeric region of the long arm of either chromosome 13 or 14. The same conception may be extrapolated to the other nonpolymalformed patients with the 45, XX or XY, t(13;14) abnormality, though it remains to be clarified by molecular study using DNA probes assigned to the paracentromeric regions of the long

arms of chromosomes 13 and 14.

It is generally believed that autosomal imbalances always produce phenotypic abnormalities including mental retardation, craniofacial dysmorphism, skeletal anomalies, intrauterine and postnatal growth failure. Our study has demonstrated that this generalization does not hold true for all autosomal abnormalities. Even mentally retarded patients with two or less malformations were found to have chromosome abnormalities such as subtle autosomal deletions. Furthermore, the clinical features of the patients with chromosome abnormalities were not significantly different from those of the

patients with normal karyotypes except in the number of malformations. There was, however, no specific malformation more commonly seen in the patients with chromosome abnormalities. These results suggest that diagnostic evaluation of patients with clinically undefined mental retardation, either malformed or nonmalformed, should include chromosome analysis using a high resolution banding technique.

References

- Rudolph AM and Hoffman JIE: *Pediatrics*. Appleton and Lange, Norwalk (1987) pp 378-381.
- Milunski A: The causes and prevalence of mental retardation; in *The Prevention of Genetic Disease and Mental Retardation*, WB Saunders, Philadelphia (1975) pp 19-50.
- Arima M, Ohtahara S, Suzuki Y, Takesada M, Takeshita K, Nagabata M and Yamashita F: Etiological analysis of mental retardation. *Hattatsu-shougaikenkyu* (1982) **4**, 198-205 (in Japanese).
- Finefeld SL: Clinical assessment of 4,500 developmentally delayed individuals. *J Ment Defic Res* (1984) **28**, 129-142.
- Rasmussen K, Nielsen J and Dahl G: The prevalence of chromosome abnormalities among mentally retarded persons in a geographically delimited area of Denmark. *Clin Genet* (1982) **22**, 244-255.
- Fryns JP, Kleczkowska A, Kubiś E and Van den Berghe H: Cytogenetic findings in moderate and severe mental retardation. A study of an institutionalized population of 1,991 patients. *Acta Paediatr Scand* (1984) Suppl 313, 1-23.
- Narahara K: A cytogenetic study of children with clinically unclassifiable multiple congenital malformations and mental retardation. *Acta Med Okayama* (1981) **35**, 343-355.
- De Grouchy J and Turleau C: *Clinical Atlas of Human Chromosomes*. Wiley Medical, New York (1984).
- Schinzl A: *Catalogue of Unbalanced Chromosome Aberrations in Man*. De Gruyter, Berlin (1984).
- Yunis JJ, Sawyer JR and Ball DW: The characterization of high resolution G banded chromosomes of man. *Chromosoma* (1978) **67**, 293-307.
- Ikeuchi T and Sasaki M: Accumulation of early mitotic cells in ethidium bromide-treated human lymphocyte cultures. *Proc Jpn Acad* (1979) **55(B)**, 15-18.
- Summitt RL: Cytogenetics in mentally defective children with anomalies: A controlled study. *J Pediatr* (1969) **74**, 58-66.
- Seabright M: A rapid banding technique for human chromosomes. *Lancet* (1971) **2**, 971.
- Caspersson T, Zech L, Johansson C and Modest EJ: Identification of human chromosomes by DNA-binding fluorescent agent. *Chromosoma* (1970) **30**, 215-217.
- Dutrillaux B, Laurent C, Couturier J and Lejeune J: Coloration par l'acridine orange de chromosomes préalablement traités par le 5-bromodéoxyuridine (BUDR). *C R Acad Sci Paris* (1973) **276**, 3179-3181.
- Sumner AT: A simple technique for demonstrating centromeric heterochromatin. *Exp Cell Res* (1972) **75**, 304-306.
- Bloom SE and Goodpasture C: An improved technique for selective silver staining of nucleolar organizer regions in human chromosomes. *Hum Genet* (1976) **34**, 199-206.
- Schweizer D, Ambros P and Andrie M: Modification of DAPI banding on human chromosomes by prestaining with a DNA-binding oligopeptide antibiotic, distamycin A. *Exp Cell Res* (1978) **111**, 327-332.
- An International System for Human Cytogenetic Nomenclature (1985), Harnden DG, Klinger HP, Jensen JT, Kaelbling M, eds, Karger, Basel (1985).
- Narahara K, Kodama Y, Kimura S and Kimoto H: Probable inverted tandem duplication of Xp in a 46, Xp+Y boy. *Jpn J Hum Genet* (1979) **24**, 105-110.
- Daly RF: Chromosome aberrations in 50 patients with idiopathic mental retardation and in 50 control subjects. *J Pediatr* (1970) **77**, 444-453.
- Carrel RE, Sparkes RS and Wright SW: Chromosome survey of moderately to profoundly retarded patients. *Am J Ment Defic* (1973) **77**, 616-622.
- Erdtmann B, Salzano FM and Mettevi MS: Chromosome studies in patients with congenital malformations and mental retardation. *Humangenetik* (1975) **26**, 297-306.
- Doyle CT: The cytogenetics of 90 patients with idiopathic mental retardation/malformation syndromes and 50 normal subjects. *Hum Genet* (1976) **33**, 131-146.
- Magnelli NC: Cytogenetics of 50 patients with mental retardation and multiple congenital anomalies and 50 normal subjects. *Clin Genet* (1976) **9**, 169-182.
- Tharapel AT and Summitt R: A cytogenetic survey of 200 unclassifiable mentally retarded children with congenital anomalies and 200 normal controls. *Hum Genet* (1977) **37**, 329-338.
- Coco R and Penchaszadeh VB: Cytogenetic findings in 200 children with mental retardation and multiple congenital anomalies of unknown cause. *Am J Med Genet* (1982) **12**, 155-173.
- Ieshima A and Takeshita K: Cytogenetic study

- in mentally retarded patients. I. The incidence of chromosome abnormalities and significance of chromosome banding method. *Nihonshounikagakkaiishi* (1985) **89**, 1612-1623 (in Japanese).
29. Sutherland GR and Hecht F: Fragile Sites on Human Chromosomes. Oxford University, New York (1985) pp 132-149.
30. Couturier J, Morichon-Delvallez N and Dutrillaux B: Deletion of band 13 q21 is compatible with normal phenotype. *Hum Genet* (1985) **70**, 87-91.
31. Niebuhr E: Dicentric and monocentric robertsonian translocations in man. *Humangenetik* (1972b) **16**, 217-226.
32. Nielsen J, Wohlert M, Faaborg-Andersen J, Hansen KB, Hvidan L, Krag-Olsen B, Moulvad I and Videbech P: Incidence of chromosome abnormalities in newborn children. Comparison between incidences in 1969-1974 and 1980-1982 in the same area. *Hum Genet* (1982) **61**, 98-101.

Received December 12, 1988 ; accepted February 17, 1989