

Acta Medica Okayama

Volume 51, Issue 6

1997

Article 7

DECEMBER 1997

Carpal tunnel syndrome induced by two types of calcium deposition

Harutomo Ikawa*

Hiroyuki Hashizume[†]

Hajime Inoue[‡]

*Okayama University,

[†]Okayama University,

[‡]Okayama University,

Carpal tunnel syndrome induced by two types of calcium deposition*

Harutomo Ikawa, Hiroyuki Hashizume, and Hajime Inoue

Abstract

Two rare cases of carpal tunnel syndrome caused by calcification in the carpal tunnel are reported. One case involved a tumorous calcification consisting of basic calcium phosphate, and the other involved a diffuse calcification consisting of a mixture of calcium pyrophosphate dihydrate and basic calcium phosphate. These cases suggest that the shape of carpal tunnel calcifications is influenced by the nature of calcifying substance itself, i.e., whether it is heterogenous or homogenous.

KEYWORDS: carpal tunnel syndrome, calcium deposition disease

*PMID: 9439776 [PubMed - indexed for MEDLINE]

Copyright (C) OKAYAMA UNIVERSITY MEDICAL SCHOOL

Brief Note

Carpal Tunnel Syndrome Induced by Two Types of Calcium Deposition

Harutomo IKAWA, Hiroyuki HASHIZUME* and Hajime INOUE

Department of Orthopaedic Surgery, Okayama University Medical School, Okayama 700, Japan

Two rare cases of carpal tunnel syndrome caused by calcification in the carpal tunnel are reported. One case involved a tumorous calcification consisting of basic calcium phosphate, and the other involved a diffuse calcification consisting of a mixture of calcium pyrophosphate dihydrate and basic calcium phosphate. These cases suggest that the shape of carpal tunnel calcifications is influenced by the nature of calcifying substance itself, i.e., whether it is heterogenous or homogenous.

Key words: carpal tunnel syndrome, calcium deposition disease

Carpal tunnel syndrome (CTS) is caused by many etiologies which can be grossly divided into local or systemic causes. Local etiologies include space occupying lesions caused by nonspecific flexor tenosynovitis (1); trauma, including chronic dislocation of the lunate bone (2) and malunited Colle's fractures; ganglions or lipomas (1); and anomalous muscle bellies (3). Systemic etiologies include pregnancy, amyloidosis, hypothyroidism, hyperparathyroidism (1), acromegaly (4), and mucopolysaccharidosis (5). Two cases of CTS caused by intra-carpal tunnel calcification involving different materials and morphologies are reported in this study.

Case Report

Case 1. A 66-year-old woman visited our clinic complaining of numbness in the right fingers and motor disturbance of the thumb. The symptoms had started 4 months before her first visit. She had been treated for calcified tendinitis of the left shoulder 10 months prior to visiting our clinic. A physical examination revealed de-

creased sensation in the right thumb to middle fingers and mild thenar muscle atrophy. Both Phalen's test and Tinel's sign were positive. Laboratory data were normal. Calcium pyrophosphate dihydrate (CPPD) and uric acid were negative in an analysis of knee synovial fluid. An electrophysiological study of the right median nerve revealed a motor nerve distal latency of 13.5 msec on the right and 5.20 msec on the left. Distal latency of the sensory nerve was undetected on the right hand but was 6.0 msec on the left.

An oval calcification in the carpal tunnel was clearly observed by an X-ray view of the carpal tunnel (Fig. 1a). Resection of the flexor retinaculum and removal of the tumorous calcification were performed 5 days after her first visit. A white and capsule-like tumor, 1.5 cm × 0.5 cm in size was observed on the palmar side of the carpal ligaments (Fig. 1b).

Hematoxylin-eosin (H-E) staining of the extracted tumor revealed a nodular lesion composed of an eosinophilic, granular and hyaline substance (Fig. 1c). Inflammation of the tendon sheath was not observed. The extracted tissue was determined to be basic calcium phosphate (BCP) (Fig. 2).

The symptoms disappeared completely 9 months after surgery. Post-surgery distal latency of the motor nerve was 5.20 msec and that of the sensory nerve was 9.87 msec.

Case 2. A 78-year-old woman visited our clinic complaining of numbness of the fingers and motor disturbance of the thumb. These symptoms had started 5 months before her first visit. She had had a history of arthralgia for 10 years but the arthralgia was absent when she visited our clinic. A physical examination revealed decreased sensation in the thumb to the ring fingers and

* To whom correspondence should be addressed.

significant thenar muscle atrophy. Phalen's test was negative but Tinel's sign was positive for both hands. No

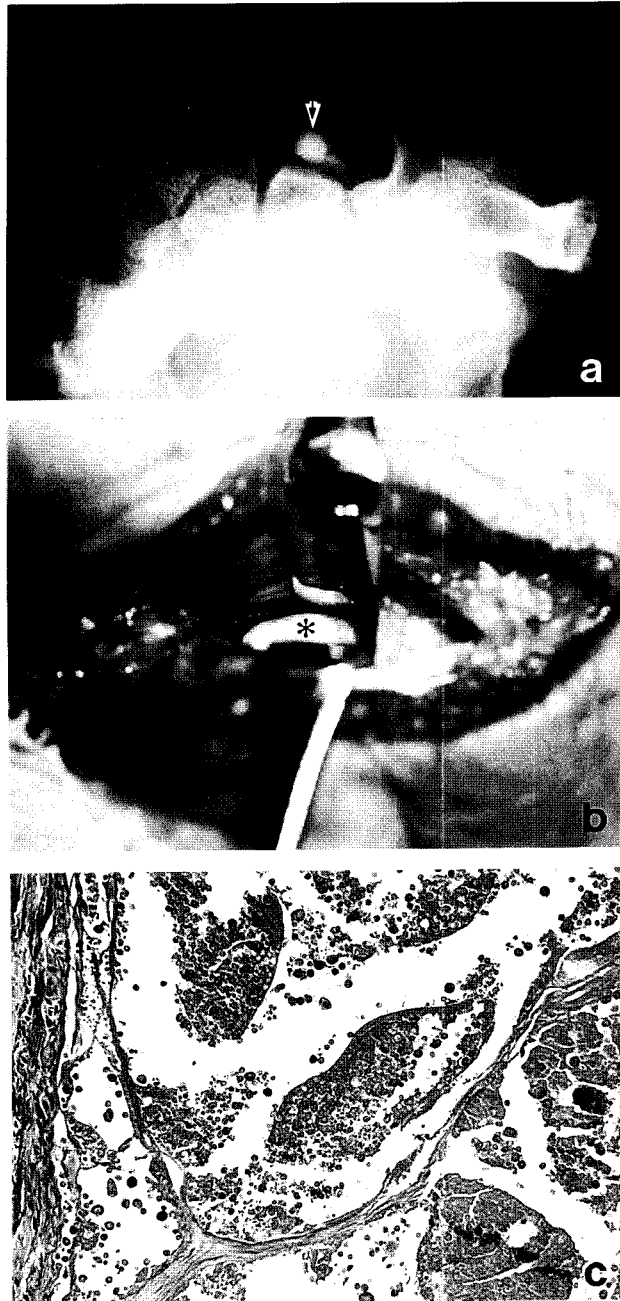


Fig. 1 Clinicopathological findings in Case 1. a) Carpal tunnel view showing an oval calcification (\downarrow) in the carpal tunnel. b) During surgery, a white, capsule-like tumor, 1.5 cm \times 0.5 cm in size (*), was observed on the palmar side of the carpal ligaments. c) Light microscopic view of the extracted tumor showing a nodular lesion composed of an eosinophilic, granular and hyaline substance (H-E, \times 100).

evidence of hyperparathyroidism was found. Distal latency of the motor nerve was 14.17 msec on the right and 15.50 msec on the left, and distal latency of the sensory nerve was 12.20 msec on the right and 11.60 msec on the left.

An anteroposterior view of X-ray showed diffuse calcification in the triangular fibrocartilage complex and the third carpometacarpal joint. Furthermore, diffuse calcification in the carpal tunnel was observed by carpal tunnel view (Fig. 3a). A dissection of the flexor retinaculum and a resection of the carpal ligament, including the calcification and the neurolysis of the epineurium of the median nerve were performed 45 days after her first visit. A white protrusion 1 cm in diameter was observed around the palmar side of the capitate (Fig. 3b).

H-E staining and transmission electron microscopy revealed that the extracted tissue seemed to consist of a mixed deposition containing both CPPD and BCP. CPPD appeared as basophilic needle-shaped clusters and parallelogram-shaped crystals (Fig. 3c). BCP appeared as round crystals on transmission electron microscopy (Fig. 4). Neither clusters of crystals nor inflammation were observed in the flexor retinaculum, flexor tendon sheath or in the epineurium of the median nerve.

The symptoms had disappeared and the atrophy of the muscles had reversed 10 months after surgery. Distal latency of a right motor nerve was 5.60 msec and that of a right sensory nerve was 10.26 msec. Distal latency of the motor and sensory nerve on the left side, which was not treated surgically, was aggravated.

Discussion

Arthritis-inducing crystalline depositions include the following: monosodium urate crystals (acute gouty arthritis, chronic tophaceous gouty arthritis); CPPD crystals (acute pseudogout, chronic pyrophosphate arthropathy), BCP crystals including hydroxyapatite crystals (acute calcific periartthritis, acute hydroxyapatite arthritis, chronic hydroxyapatite arthritis) (6). These diseases are considered to be the causes of CTS. Of these diseases, pseudogout and BCP deposition can be observed as calcification on X-rays.

The morphology of calcifications in the carpal tunnel which cause CTS can be divided into tumorous calcifications and diffuse calcifications, based on their radiographic images. Several cases of tumorous calcification have been reported (7-9) since the first report by Phalen

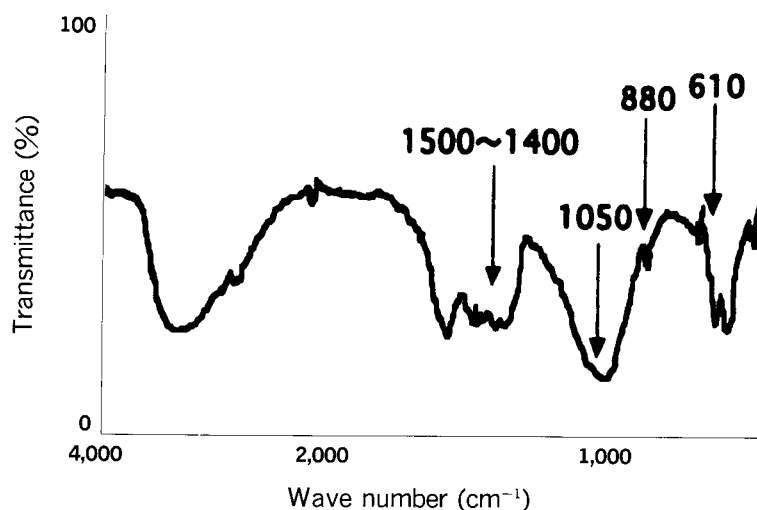
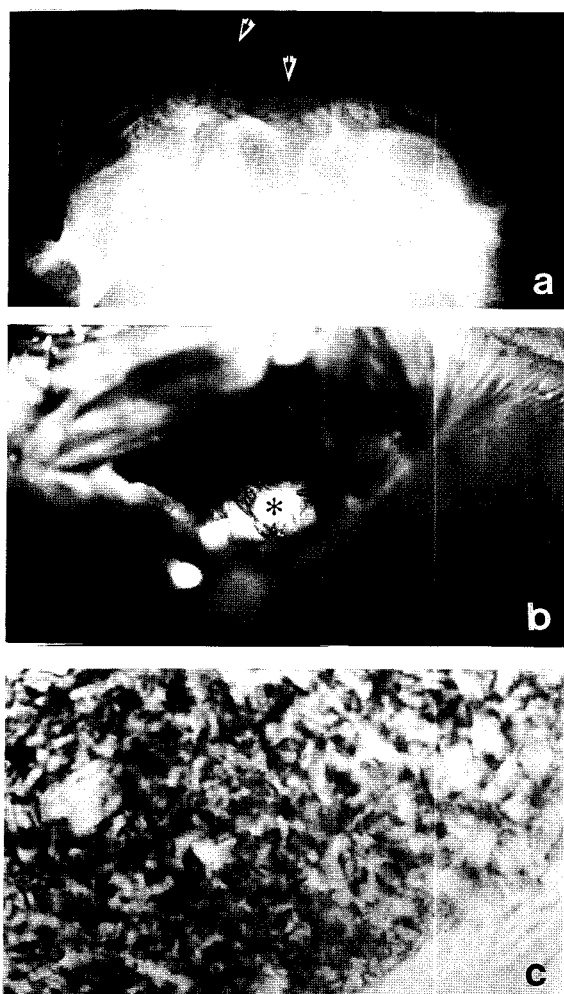


Fig. 2 The infrared spectrum of the extracted tissue. The spectrum showed an absorption region of 1500-1400 cm^{-1} , 1050 cm^{-1} , 880 cm^{-1} and 610 cm^{-1} .



(1) (Table 1). However, there have been no detailed reports on the nature of the calcifying substances. There have also been several reports of diffuse calcification treated by surgical removal (10, 11). CPPD was detected in all of these cases, and BCP including hydroxyapatite was also detected in some cases. Case 1 in our report is the first confirmed case in which BCP was the substance responsible for the tumorous calcification present in the carpal tunnel. Although it was not possible to determine the calcifying substance in Case 2 by infrared spectrum analysis, because the extracted tissues were organic and not homogenous, BCP was observed by transmission electron microscopy, as has been reported in previous studies (12). It seems that tumorous calcification generally consists of BCP, whereas diffuse calcification consists of BCP and CPPD. The findings in the two cases reported in this study indicate that the shape of carpal tunnel calcifications is influenced by the nature of calcifying substance itself. It appears that homogenous components induce tumorous calcified masses and heterogenous components induce diffuse calcifications.

Fig. 3 Clinicopathological findings in Case 2. a) Carpal tunnel view showing significant diffuse calcification (↓) in the carpal tunnel. b) During surgery, a white protrusion 1 cm in diameter (*) was observed on the palmar side of the capitate. c) Light microscopic view of the extracted tissues showing clusters of basophilic needle-shaped and some parallelogram-shaped crystals (H-E, $\times 1,000$).

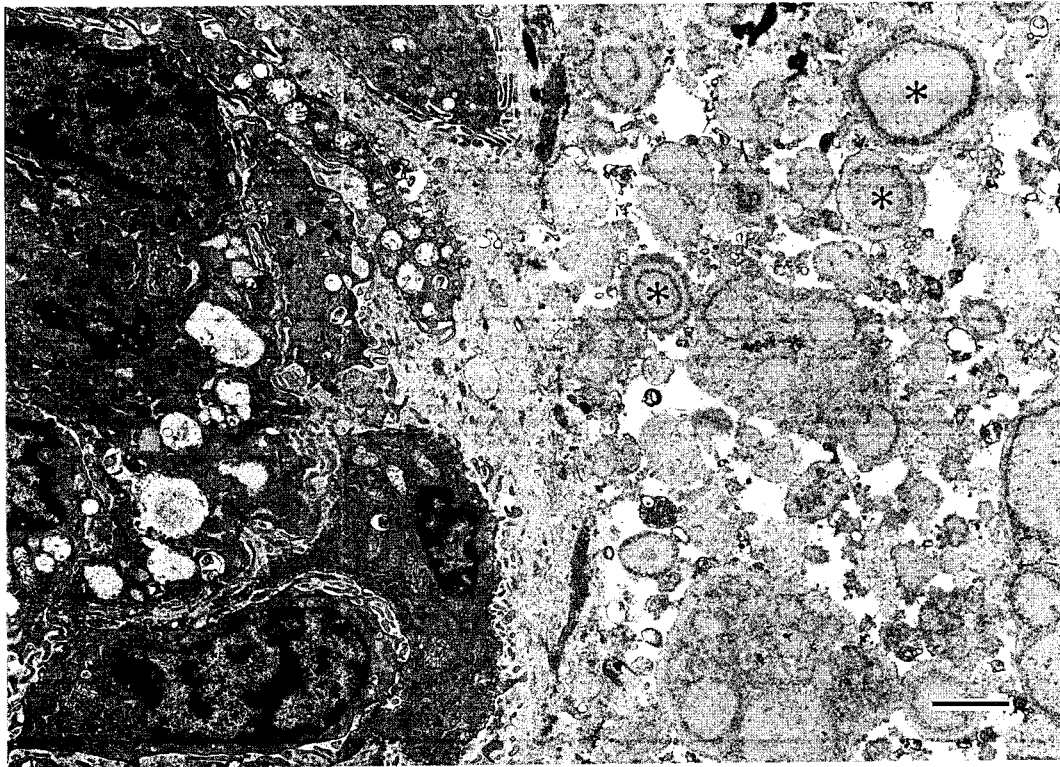


Fig. 4 Electron micrograph of extracted tissues from Case 2. The micrograph shows hydroxyapatite crystals (*). Bar, 2 μ m.

Table I Reports of calcification in the carpal tunnel

Calcification pattern	Year	Reporter	Composition of calcification	Treatment	Connected disease
Tumorous	1966	Phalen <i>et al.</i>	Calcium and gouty topi	—	—
	1983	Das De	Calcium contained	Operation (postop 6 weeks symptom free)	—
	1983	Ametewee	Unknown	Cast 3 weeks (post 2 months, calcification and symptom free)	Trauma (contusion)
	1984	Edwards <i>et al.</i>	Dystrophic calcification	Operation (postop 2 years, sensory loss persists)	Calcified supraspinatus tendon
	1997	Ikawa <i>et al.</i>	Basic calcium phosphate	Operation (postop 9 months, symptom free)	Calcified tendinitis of the shoulder
Diffuse	1968	Weinstein <i>et al.</i>	CPPD	Operation	Hyperparathyroidism
	1976	Spiegel <i>et al.</i>	CPPD, Hydroxyapatite	Operation (postop 6 weeks, symptom free)	—
	1997	Ikawa <i>et al.</i>	CPPD, Basic calcium phosphate	Operation (postop 10 months, symptom free)	Calcified tendinitis of the shoulder

CPPD: Calcium pyrophosphate dehydrate.

References

1. Phalen GS: The carpal-tunnel syndrome: Seventeen years' experience in diagnosis and treatment of six hundred fifty-four hands. *J Bone Jt Surg Am Vol* (1966) **48**, 211-228.
2. Chen WS: Median-nerve neuropathy associated with chronic anterior dislocation of the lunate. *J Bone Jt Surg Am Vol* (1995) **77**, 1853-1857.
3. Smith RJ: Anomalous muscle belly of the flexor digitorum superficialis causing carpal-tunnel syndrome. *J Bone Jt Surg Am Vol* (1971) **53**, 1215-1216.
4. Oldberg GS: The carpal tunnel syndrome and acromegaly. *Acta Soc Med Upsal* (1971) **76**, 179-190.
5. Starreveld E and Ashenurst EM: Bilateral carpal tunnel syndrome in childhood: Report of two sisters with mucopolipidosis III (Pseudo-Hurler Polydystrophy). *Neurology* (1975) **25**, 234-238.
6. Fam AG: Calcium pyrophosphate crystal deposition disease and other crystal deposition diseases. *Curr Opin Rheumatol* (1992) **4**, 574-582.
7. Ametewee K: Carpal tunnel syndrome produced by a post traumatic calcific mass. *Hand* (1983) **15**, 212-215.
8. De Das S: Carpal tunnel syndrome due to a calcareous mass in the carpal tunnel. *Singapore Med J* (1983) **24**, 175-177.
9. Edwards AJ, Sill BJ and Macfarlane I: Carpal tunnel syndrome due to dystrophic calcification. *Aust NZ J Surg* (1984) **54**, 491-492.
10. Weinstein JD, Dick HM and Grantham SA: Pseudogout, hyperparathyroidism, and carpal tunnel syndrome. *J Bone Jt Surg Am Vol* (1968) **50**, 1669-1674.
11. Spiegel PG, Ginsberg M, Skosey JL and Kwong P: Acute carpal tunnel syndrome secondary to pseudogout. *Clin Orthop* (1976) **120**, 185-187.
12. Lagier R, Boivin G and Gerster JC: Carpal tunnel syndrome associated with mixed calcium pyrophosphate dihydrate and apatite crystal deposition in tendon synovial sheath. *Arthritis Rheum* (1984) **27**, 1190-1195.

Received April 30, 1997; accepted September 5, 1997.