

Endoscopic Mucosal Resection of Primary Anorectal Malignant Melanoma: A Case Report

Shouichi Tanaka* Takeyuki Ohta† Tsuyoshi Fujimoto‡
Yasuhiro Makino** Ichiro Murakami††

*Department of Gastroenterology, Iwakuni Clinical Center, National Hospital Organization,

†Department of Gastroenterology, Iwakuni Clinical Center, National Hospital Organization,

‡Department of Gastroenterology, Iwakuni Clinical Center, National Hospital Organization,

**Department of Gastroenterology, Iwakuni Clinical Center, National Hospital Organization,

††Department of Pathology, Iwakuni Clinical Center, National Hospital Organization,

Endoscopic Mucosal Resection of Primary Anorectal Malignant Melanoma: A Case Report*

Shouichi Tanaka, Takeyuki Ohta, Tsuyoshi Fujimoto, Yasuhiro Makino, and Ichiro Murakami

Abstract

Anorectal melanoma is a rare malignant tumor with a poor prognosis. However, several studies have reported cases of long-term survival. In this report, we present a patient with anorectal melanoma who has survived for 9 years after endoscopic mucosal resection. An 85-year-old man was referred to our hospital for further examination and treatment of an anal tumor 2cm in size. Endoscopic ultrasonography revealed that the depth of tumor invasion was confined to the sub-mucosal layer. Endoscopic mucosal resection was performed, and the tumor was diagnosed as a malignant melanoma. The patient was followed without any additional treatment, which was per his wishes. Although melanoma recurred 4 times thereafter, endoscopic mucosal resection was performed for each recurrent lesion. Thus, he has been alive for 9 years since the first endoscopic mucosal resection without distant metastases. If the depth of tumor invasion is shallow, endoscopic mucosal resection is a useful option among other therapeutic modalities.

KEYWORDS: malignant melanoma, anorectum, endoscopic mucosal resection (EMR), long-term survival

Case Report

Endoscopic Mucosal Resection of Primary Anorectal Malignant Melanoma: A Case Report

Shouichi Tanaka^{a*}, Takeyuki Ohta^a, Tsuyoshi Fujimoto^a,
Yasuhiro Makino^a, and Ichiro Murakami^b

Departments of ^aGastroenterology and ^bPathology, Iwakuni Clinical Center, National Hospital Organization, Iwakuni, Yamaguchi 740-0041, Japan

Anorectal melanoma is a rare malignant tumor with a poor prognosis. However, several studies have reported cases of long-term survival. In this report, we present a patient with anorectal melanoma who has survived for 9 years after endoscopic mucosal resection. An 85-year-old man was referred to our hospital for further examination and treatment of an anal tumor 2 cm in size. Endoscopic ultrasonography revealed that the depth of tumor invasion was confined to the submucosal layer. Endoscopic mucosal resection was performed, and the tumor was diagnosed as a malignant melanoma. The patient was followed without any additional treatment, which was per his wishes. Although melanoma recurred 4 times thereafter, endoscopic mucosal resection was performed for each recurrent lesion. Thus, he has been alive for 9 years since the first endoscopic mucosal resection without distant metastases. If the depth of tumor invasion is shallow, endoscopic mucosal resection is a useful option among other therapeutic modalities.

Key words: malignant melanoma, anorectum, endoscopic mucosal resection (EMR), long-term survival

In the gastrointestinal (GI) tract, the anorectum is a site at which malignant melanoma arises frequently. Anorectal malignant melanoma has been shown to result in worse prognoses than cutaneous melanoma [1]. However, several studies [2-4] have reported cases of long-term survival when treatment consisted only of local surgical excision. We herein present the case of a patient with anorectal malignant melanoma treated by endoscopic mucosal resection (EMR) alone. He has survived for 9 years without distant metastases.

Case Report

An 85-year-old man visited an outside hospital with a chief complaint of anal bleeding in July 1999. He underwent colonoscopy and an anal tumor was found. He was admitted to our hospital for further examination and treatment. His past medical history was significant and included sigmoidectomy in 1986 for sigmoid colon cancer. Physical examination and routine blood tests revealed no major abnormalities. Barium enema showed a nodular tumor about 2 cm in size in the rectum adjacent to the anal verge (Fig. 1A). Colonoscopic examination revealed a dark and nodular polypoid lesion about 2 cm in size, which was 1 cm above the anal verge (Fig. 1B). The tumor had a smooth surface, and there was no evidence of erosion or ulceration. A 20-MHz ultrasound catheter probe

Received June 9, 2008; accepted August 22, 2008.

*Corresponding author. Phone: +81-827-31-7121; Fax: +81-827-31-7059
E-mail: tanaka@iwakuni-nh.go.jp (S. Tanaka)

revealed a hypoechoic mass, and indicated that the lesion was nearly confined to the submucosal layer (Fig. 1C). Whole body computed tomography and upper GI endoscopy did not reveal any other abnormalities.

The endoscopic biopsy specimen revealed a round cell tumor, but a definitive diagnosis was not made. Therefore, EMR was performed to not only control the bleeding, but also to make a definitive diagnosis.

The resection specimen, measuring 22×18mm, showed a black solid tumor that was covered with normal mucosa in a cut surface view (Fig. 2A). Microscopic findings revealed diffuse infiltration of round or spindle-shaped tumor cells that contained melanin in the submucosal layer (Fig. 2B). Immunohistochemically, tumor cells were positive for Human Melanin Black-45 (HMB-45) (Fig. 2C). The final diagnosis was a primary anorectal malignant melanoma

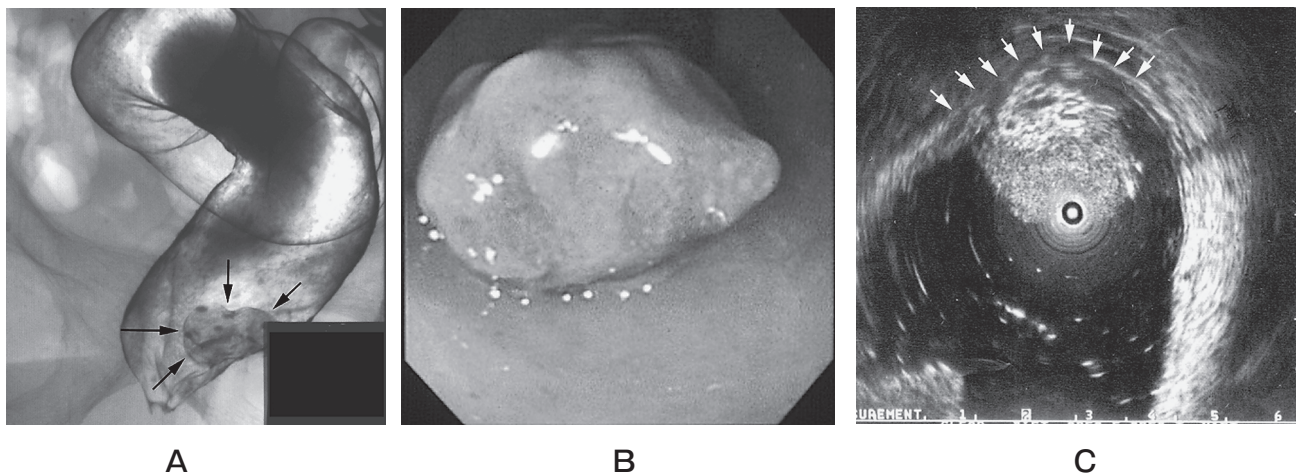


Fig. 1 A, Barium enema image showing a nodular tumor about 2cm in size in the rectum adjacent to the anal verge (arrows); B, Colonoscopic view of lesion, demonstrating a dark and nodular polypoid lesion about 2cm in size at 1cm above the anal verge; C, EUS image showing the lesion as a hypoechoic mass, indicating it is almost confined to the submucosal layer. Arrows indicate the submucosal layer.

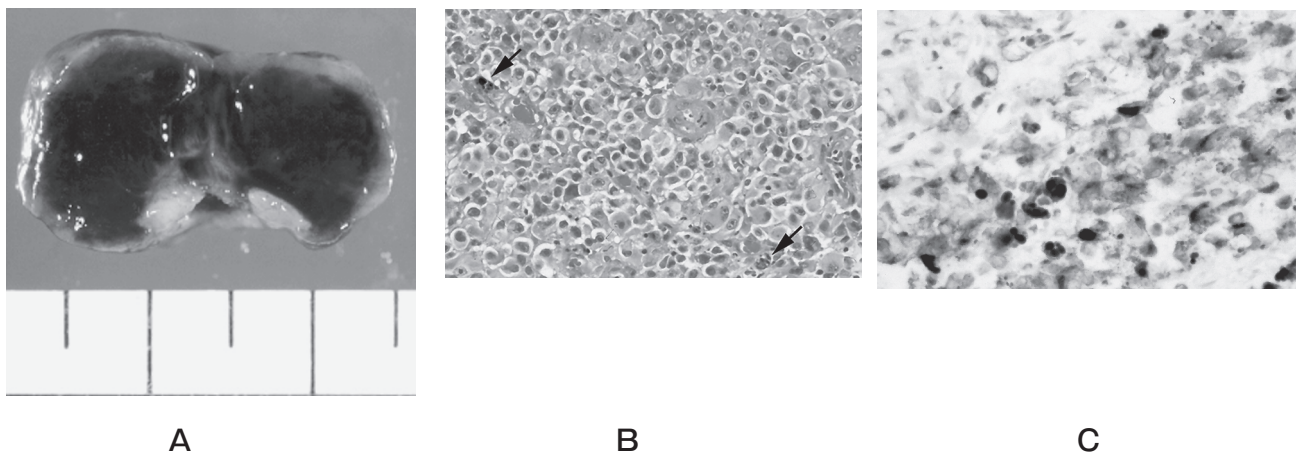


Fig. 2 A, A cut surface view of the resection specimen, measuring 22×18mm, showing a black solid tumor covered with normal mucosa; B, Photomicrograph of resection specimen showing diffuse infiltration of round or spindle-shaped tumor cells containing melanin (arrows) in the submucosal layer (Hematoxylin and Eosin staining, ×300); C, Immunohistochemically, tumor cells were positive for HMB-45 (HMB-45 staining, ×400).

based on these histopathological features. Tumor cells were not seen in the resected margin. However, both lymphatic and venous invasion were noted. The patient was followed without any additional treatment, because the patient and his family refused additional treatment.

Local recurrence was confirmed at the same site 1 year and 10 months after EMR. The recurrent tumor, 3×4 cm in size, was larger than the first tumor. EMR was performed for the recurrent tumor because the patient and his family refused other options. The resection specimen was histopathologically similar to the first tumor.

Moreover, 3 years and 2 months after the first EMR, melanoma recurred at the site adjacent to the first tumor. This tumor was 1.5 cm in size, and EMR was performed. To date there have been 2 more local recurrences, but EMR was performed for each lesion. The patient remains well without distant metastases.

Discussion

The GI tract is the third most common site of occurrence of malignant melanoma, after the skin and eyes [3]. In the GI tract, the anorectum is a site at which malignant melanoma arises frequently, because of the presence of abundant melanocytes in the mucosa of the anal canal [5]. However, anorectal malignant melanoma is a rare disease, since melanoma accounts for less than 1% of primary anorectal malignancies [6].

Anorectal malignant melanoma is thought to have a poor prognosis because it is often misdiagnosed for hemorrhoids, which causes a delay in making the correct diagnosis [1, 3]. Overall, the 5-year survival rate is reported to be 10% or less even if radical surgery (abdominoperineal resection) and chemotherapy are performed [6].

However, several studies have reported cases of long-term survival. For example, Malik *et al.* [3] reported the case of a patient with a 5.75-mm thick anorectal melanoma who survived for 10 years after wide local excision. Whooley *et al.* [7] reported a 5-year survivor after abdominoperineal resection and chemotherapy for a 2.5-mm thick anorectal melanoma. It has been shown that an important determinant of prognosis for any primary melanoma is the tumor thickness. Specifically, "thin" anorectal melanomas

(<1 mm) have a more favorable prognosis than thicker anorectal melanomas [8, 9]. However, there are cases of long-term survival in spite of the presence of thick lesions (>4 mm) or lesions of intermediate thickness (1–4 mm). With regard to cutaneous melanomas, Clark *et al.* [10] reported that the invasive radial growth phase of melanoma is indolent and incapable of metastasis. Histologically, it is characterized by scattered foci of papillary dermal invasion that are only comprised of scattered cells or small clusters, and with only rare mitotic figures. Whooley *et al.* [7] proposed that these histological findings might also be related to the prognosis for anorectal melanoma. In the present case, it is possible that this tumor possessed the histological feature of being incapable of metastasis in addition to a small volume of tumor cells.

In Japan, approximately 15 cases of survival longer than 5 years have been reported [11, 12]. According to an analysis of these long-term survivors, the conditions for longer survival were a tumor diameter of less than 5 cm and a tumor depth of invasion confined to the muscularis propria.

EMR for primary malignant melanoma in the GI tract has been performed in only 5 cases [2, 13–15] including ours. These cases are summarized in Table 1. Relatively long-term survival was achieved in most cases. Among these cases, only our case involved no additional treatment after EMR.

In the present case, local recurrence has occurred four times so far. EMR was performed for each recurrent lesion. The patient is alive with no evidence of distant metastases even though 9 years have passed since the first EMR. Endoscopic ultrasonography (EUS) for the first lesion confirmed that tumor invasion was confined to the submucosa. Examination of the specimen resected by EMR confirmed the negative margins. Therefore, this case is thought to have met the conditions for long-term survival. However, in the future, close follow-up for local recurrence including distant metastases is necessary.

Long-term survival is expected, even if less invasive surgery such as EMR is performed, in cases of anorectal melanoma in which a shallow depth of invasion is confirmed by EUS. Thus, the staging system and selection of therapeutic modalities should be based on tumor size and depth of invasion.

Table 1 Reported cases in which EMR was performed for primary malignant melanoma in the GI tract

No.	Authors (year)	Age/Sex	Location	Size (mm)	Depth	Additional treatment	Prognosis
1	Herman <i>et al.</i> [13] (2001)	55/M	Esophagus	50	—	IFN [§] therapy	25 months
2	Nishina <i>et al.</i> [2] (2001)	76/M	Anorectum	10	M [†]	Local excision	8 years
3	Fukui <i>et al.</i> [14] (2002)	54/F	Anorectum	6	—	APR [¶] +chemotherapy	More than 6 years
4	Hirose <i>et al.</i> [15] (2002)	57/M	Esophagus	33	SM [‡]	Irradiation	12 months
5	Our case (2008)	85/M	Anorectum	22×18	SM	None	9 years

† M, invasion confined to the mucosal layer;

‡ SM, invasion confined to the submucosal layer;

§ IFN, interferon;

¶ APR, abdominoperineal resection.

References

- Wong JH, Cagle LA, Storm FK and Morton DL: Natural history of surgically treated mucosal melanoma. *Am J Surg* (1987) 154: 54–57.
- Nishina T, Kunieda K, Miya K, Saji S, Shimokawa K, Katada M and Watanabe K: Two cases of anorectal malignant melanoma showing prolonged survival after local additional excision followed by biopsy and abdomino-perineal resection followed by incisional biopsy. *Jpn J Gastroenterol Surg* (2001) 34: 292–296 (in Japanese).
- Malik A, Hull TL and Milsom J: Long-term survivor of anorectal melanoma: report of a case. *Dis Colon Rectum* (2002) 45: 1412–1417.
- Bullard KM, Tuttle TM, Rothenberger DA, Madoff RD, Baxter NN, Finne CO and Spencer MP: Surgical therapy for anorectal melanoma. *J Am Coll Surg* (2003) 196: 206–211.
- Alazmi WM, Nehme OS, Regalado JJ and Rogers AI: Primary gastric melanoma presenting as a nonhealing ulcer. *Gastrointest Endosc* (2003) 57: 431–433.
- Weinstock MA: Epidemiology and prognosis of anorectal melanoma. *Gastroenterology* (1993) 104: 174–178.
- Whooley BP, Shaw P, Astrow AB, Toth IR and Wallack MK: Long-term survival after locally aggressive anorectal melanoma. *Am Surg* (1998) 64: 245–251.
- Wanebo HJ, Woodruff JM, Farr GH and Quan SH: Anorectal melanoma. *Cancer* (1981) 47: 1891–1900.
- Angeras U, Jonsson N and Jonsson PE: Primary anorectal malignant melanoma. *J Surg Oncol* (1983) 22: 261–264.
- Clark WH Jr, Elder DE, Guerry IV D, Braitman LE, Trock BJ, Schultz D, Synnestvedt M and Halpern AC: Model predicting survival in stage I melanoma based on tumor progression. *J Natl Cancer Inst* (1989) 81: 1893–1904.
- Hara H, Asano M, Asai S, Kato Y, Furukawa S and Ando H: A case report of prolonged survival of anorectal melanoma. *Jpn J Gastroenterol Surg* (1992) 25: 2046–2049 (in Japanese).
- Shimada K, Chubachi S, Ichinohe F, Satoh M, Sugawara K, Rokkaku Y, Aono G, Kanno M, Tsuchiya A and Ohara T: A long-surviving patients with concurrent malignant melanoma of the anorectal region and early gastric cancer—a case report and review of the Japanese literature-. *Jpn J Cancer Clin* (1996) 42: 1109–1119 (in Japanese).
- Herman J, Duda M, Lovecek M and Svach I: Primary malignant melanoma of the esophagus treated by endoscopic ablation and interferon therapy. *Dis Esophagus* (2001) 14: 239–240.
- Fukui R, Hata F, Yasoshima T, Honma T, Nomura H, Sasaki K, Nishimori H, Sasaki K, Kutomi G, Ohno K, Oikawa I, Sasaki K, Tarumi K, Ishiyama Y, Kobayashi K, Yamamoto N and Hirata K: Malignant melanoma of the anorectum: report of four cases. *Surg Today* (2002) 32: 555–558.
- Hirose T, Idee Y, Hanashi T, Yoshida M, Kato H, Monma K, Funada N and Koike M: Malignant melanoma of the esophagus, report of a case. *Stomach and Intestine* (2002) 37: 1361–1365 (in Japanese).