

Medicine
Neurology fields

Okayama University

Year 2005

Panayiotopoulos syndrome: a consensus
view

Colin Ferrie, *Leeds General Infirmary*
Roberto Caraballo, *Hospital de Ninos Prof Dr JP Garrahan*
Athanasios Covanis, *The Children's Hospital Agia Sophia*
Veysi Demirbilek, *Istanbul University*
Aysin Dervent, *Istanbul University*
Sara Kivity, *Schneider Children's Medical Centre of Israel*
Michael Koutroumandis, *St Thomas' Hospital, UK*
Zarko Martinovic, *Belgrade University Medical School*
Hirokazu Oguni, *Tokyo Women's Medical University*
Alberto Verrotti, *Ospedale Policlinico*
Federico Vigevano, *Bambino Gesu Children Hospital*
Kazuyoshi Watanabe, *Nagoya University School of Medicine*
Despina Yalcin, *Sisli Etfal Education Hospital*
Harami Yoshinaga, *Okayama University*

This paper is posted at eScholarship@OUDIR : Okayama University Digital Information Repository.

<http://escholarship.lib.okayama-u.ac.jp/neurology/2>

Panayiotopoulos syndrome: a consensus view

Colin Ferrie* MD, Department of Paediatric Neurology, Leeds General Infirmary, UK.

Roberto Caraballo MD, Servicio de Neurologia, Hospital de Niños Prof Dr JP Garrahan, Buenos Aires, Argentina.

Athanasios Covanis MD DCH PhD, Neurology Department, The Children's Hospital Agia Sophia, Athens, Greece.

Veysi Demirbilek MD;

Aysin Dervent MD, Cerrah Pasa Medical Faculty, Department of Neurology, Istanbul University, Turkey.

Sara Kivity MD, Pediatric Epilepsy Unit and EEG Laboratory, Schneider Children's Medical Centre of Israel, Petach, Tiqwa, Israel.

Michael Koutroumanidis MD, Department of Clinical Neurophysiology and Epilepsies, St Thomas' Hospital, London, UK.

Zarko Martinovic MD PhD, Department of Epilepsy and Clinical Neurosciences, Belgrade University Medical School, Serbia and Montenegro.

Hirokazu Oguni MD PhD, Department of Pediatrics, Tokyo Women's Medical University, Japan.

Alberto Verrotti MD PhD, Division of Pediatrics, Department of Medicine, Ospedale Policlinico, Chieti;

Federico Vigevano MD, Division of Neurology, Bambino Gesù Children Hospital, Rome, Italy.

Kazuyoshi Watanabe MD PhD, Department of Pediatrics, Nagoya University School of Medicine, Nagoya, Japan.

Despina Yalcin MD, Neurological Clinic, Sisli Etfal Education Hospital, Istanbul, Turkey.

Harami Yoshinaga MD, Department of Child Neurology, Okayama University Medical School, Japan.

**Correspondence to first author at Department of Paediatric Neurology, Clarendon Wing, Leeds General Infirmary, Leeds LS2 9NS, UK.
E-mail: colindferrie@aol.com*

The aim of this paper is to promote the correct classification of, and provide guidelines on, the diagnosis and management of Panayiotopoulos syndrome (PS). An international consortium of established researchers in the field collaborated to produce a consensus document. The resulting document defines PS, characterizes its electro-clinical features, considers its likely pathogenesis, and provides guidance on appropriate management. We conclude that PS is a common idiopathic, benign seizure disorder of childhood, which should be classified as an autonomic epilepsy, rather than an occipital epilepsy.

The International League Against Epilepsy (ILAE) 2001 Diagnostic Scheme recognized two childhood occipital epilepsies, including early-onset benign childhood occipital epilepsy and late-onset childhood occipital epilepsy.¹ It proposed the alternative name of Panayiotopoulos type for the former²⁻⁷ and Gastaut type for the latter.⁸⁻¹⁴ In so doing it followed historical precedence, as these two seizure disorders were both described around the same time in the early 1980s and were considered by leading authorities to be variants of the same underlying disorder. However, during the past decade independent studies from around the world have strongly suggested that this is an erroneous view and that these conditions are likely to be separate disorders, rather than variants of a

single disorder, and that, although seizures in Gastaut-type occipital epilepsy are indeed likely to originate in the occipital lobes, this is unlikely to always be the case in Panayiotopoulos syndrome (PS).

It has also become apparent that PS is one of the most common childhood seizure disorders. Despite this, and unlike the situation that pertains with similarly common childhood seizure disorders, notably febrile seizures and benign childhood epilepsy with centrotemporal spikes (Rolandic epilepsy), no guidelines have been published reflecting a consensus on how it should be managed.

This document has been produced to rectify this situation. It has been produced by an international consortium of investigators and clinicians who have studied PS over several decades and who have pooled their work¹⁵⁻⁴⁴ to reach a consensus on the definition of PS, characterization of its clinical and electroencephalogram (EEG) features, its appropriate designation in terms of the pathophysiology of its characteristic seizures, and how it should be most appropriately managed.

Definition of Panayiotopoulos syndrome

PS is a benign age-related focal seizure disorder occurring in

early and mid-childhood. It is characterized by seizures, often prolonged, with predominantly autonomic symptoms, and by an EEG that shows shifting and/or multiple foci, often with occipital predominance.

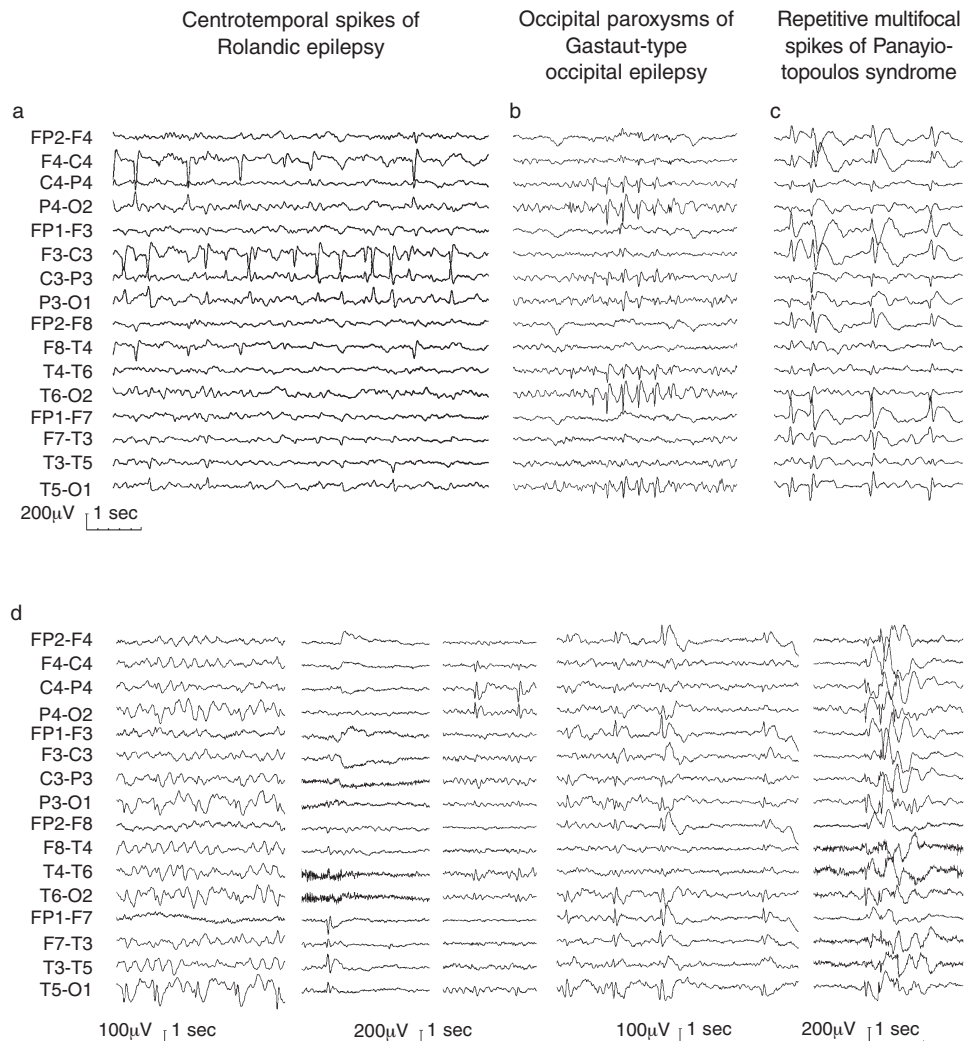
Clinical features of Panayiotopoulos syndrome, including prognosis

PS occurs in children who are otherwise normal and is not associated with the development of significant neurodevelopmental problems. Although it has been described as starting as early as 1 year of age and as late as 14 years of age, a notable feature is that most individuals have their first seizure around the age of 5 years. Three-quarters of patients have their first seizure between the ages of 3 and 6 years. It affects males and females almost equally.

The only seizure type that it is recognized may proceed the characteristic seizures of PS are febrile seizures.

Seizures in PS occur predominantly in sleep, particularly the early part of sleep. This can be both nocturnal sleep and daytime naps. In two-thirds of patients, seizures occur only in sleep. The seizures of PS are characterized by autonomic symptoms. All functions of the autonomic nervous system

Figure 1: Interictal electroencephalogram (EEG) a) in Rolandic epilepsy (centrotemporal spikes), b) Gastaut-type childhood occipital epilepsy (occipital spikes), and c) Panayiotopoulos syndrome (spikes may appear in any location, unifocal or, usually, multifocal and repetitive). d) EEG variability in five children with Panayiotopoulos syndrome despite similar clinical manifestations of autonomic seizures.



can be affected, but emetic symptoms are the most obvious. Emetic symptoms may include one or more of nausea, retching, and vomiting. In around three-quarters of patients, all three emetic symptoms are reported. Although vomiting is very common, it is not a prerequisite for diagnosis. When a seizure occurs while awake the child is typically initially fully conscious, able to speak, but complains of feeling nauseated. If the seizure occurs in sleep, the child may awaken and complain of nausea, or else may be found vomiting. In a minority of seizures in PS, features more commonly seen in other idiopathic focal epilepsies of childhood may occur.

Other autonomic features are also commonly present early on in the seizure. These include: colour changes, especially pallor, but sometimes flushing or cyanosis; pupillary changes, particularly mydriasis, less often miosis; coughing; cardiorespiratory and thermoregulatory alterations; and urinary, and less common faecal incontinence and modifications of intestinal mobility. Headache may be described and is generally concurrent with other autonomic symptoms. Details of the cardiorespiratory abnormalities, such as apnoea and changes in heart rate, are sparse and require further study.

In nearly all seizures, consciousness is initially intact but becomes impaired as the seizure progresses, with the child becoming confused or unresponsive. Deviation of the eyes and often the head to one side is common (around 60% of seizures), although it is not usually an early symptom, generally occurring after emetic symptoms. One-third of seizures terminate in hemi- or generalized convulsions.

Some seizures in PS are manifested as the child becoming unresponsive and flaccid. This may occur without, or be followed by, convulsive features. Such attacks may suggest a syncope and the terms 'ictal syncope' or 'ictal syncopal-like episodes', 'syncopal-like seizures', and 'fainting-like attacks' have been used to designate them. Usually, but not always, the syncopal-like features occupy a brief part of the seizure during which more usual autonomic and other features occur. It is not known if any such episodes are associated with transient

cerebral ischaemia (owing to, for example, apnoea or bradycardia/asystole) as in true syncope. The EEG during one such episode showed ictal epileptiform activity, rather than diffuse slowing. Syncopal-like features appear to be very rare in other types of epilepsy (apart from as part of the post-ictal state after generalized tonic clonic seizures).

Potentially life-threatening cardiorespiratory arrest has been reported. We are aware of four possible cases of this in PS. Given the number of patients with PS reported in the literature, it is possible that this complication occurs in up to 1 in 200 individuals with PS. Hence PS is a potential cause of sudden unexpected death in epilepsy (SUDEP). Therefore, whereas the syndrome is benign in terms of its evolution (see below), the seizures that characterize it may not be. This is an area where further study is required.

Seizures in PS are typically long. Forty-four per cent of seizures last 30 minutes or longer, constituting autonomic status epilepticus. Such events commonly terminate in hemi- or generalized convulsions. Convulsive status epilepticus is described but is exceptional. The mean duration of seizures that last less than 30 minutes is 9 minutes. There are no recorded instances of residual neurological damage after seizures in PS.

PS is among the most benign of all seizure disorders. Around one-third of all patients will have a single seizure (hence the term 'seizure disorder' is preferred to epilepsy). Most will have between two and five seizures. A few have more than 10 seizures. Very frequent seizures are unusual but do not exclude the diagnosis. Seizures usually remit within 1–2 years of onset. Around one-fifth of patients develop other, usually infrequent, seizures during childhood and adolescence. These are usually Rolandic seizures and, less frequently, visual seizures; they all remit. The risk of epilepsy in adult life appears to be no higher than in the general population, although there is a need for more studies with long-term follow-up. Atypical evolution of PS with the development of absences and drop attacks has been described, but is exceptional.

Table I: Comparison of the clinical and electroencephalogram features of three idiopathic focal epilepsies encountered in children

	<i>Panayiotopoulos syndrome</i>	<i>Rolandic epilepsy</i>	<i>Gastaut-type idiopathic childhood occipital epilepsy</i>
Prevalence among children 1–15 years			
with afebrile seizures, %	6	15	1–2
Mean age at onset (range), y	4–5 (1–14)	8–9 (1–15)	8–9 (3–16)
Sex prevalence, %	54 males	60 males	50 males
Seizure characteristics			
Main type of seizure	Autonomic and often with emesis	Focal sensory-motor	Focal visual
Duration	Long (usually 9 min or longer)	Moderate (usually 2–4 min)	Brief (seconds to 1–2 min)
Focal non-convulsive status epilepticus (>30min), %	44	Rare	Exceptional
Frequency of seizures	Infrequent	Infrequent	Many, sometimes daily
Single seizures only, %	30	10–20	Exceptional
Circadian distribution, %	Mainly in sleep (64)	Mainly in sleep (70)	Mainly while awake (>90)
Interictal electroencephalogram	Multifocal spikes	Centrotemporal spikes	Occipital spikes
Continuous prophylactic treatment	Often not needed	Often not needed	Needed
Prognosis	Excellent	Excellent	Uncertain
Risk of epilepsy as an adult, %	2?	3	20?
Remission within 1–3 years from first seizure	Common	Common	Uncommon
Similar seizures after remission	None	Only one case is reported	Common
Developmental and social prognosis	Normal	Normal	Usually good

Electroencephalogram

The (probably) erroneous view that PS is an occipital epilepsy arose as a consequence of its initial recognition in children whose interictal EEG showed occipital paroxysms consisting of runs of high-amplitude sharp and slow wave complexes in the posterior head regions and often attenuating when fixation was eliminated. Although such interictal EEG abnormalities are not infrequently encountered in the syndrome, they are by no means typical of it.

The interictal EEG of PS shows a normal background with high-amplitude sharp and slow wave complexes (Fig. 1). These are similar in morphology to those seen in benign childhood epilepsy with centrottemporal spikes. However, in PS there is great variability in their location. Occipital localization is the most common, but all other brain regions may be involved. Moreover, they frequently shift in location, this possibly being age-related. Brief generalized discharges are occasionally encountered. The sharp waves or sharp and slow wave complexes may repeat themselves more or less regularly and propagate, especially to frontal regions. The term 'cloned-like' has been used to describe this appearance. Its specificity for PS remains to be determined. Subgroups of patients with PS have been defined based upon differing interictal EEG patterns. These may vary in the age of onset of seizures, frequency of seizures, and duration of seizures.

EEG abnormalities in PS are accentuated by sleep. Patients are not expected to be photosensitive. Variants of the EEG that are uncommon but compatible with the diagnosis include mild background abnormalities and small or inconspicuous spikes. Similar EEG patterns to those seen in PS occasionally occur in children with other seizure disorders and in children without seizures.

Ten per cent of patients with PS may have a normal awake EEG but abnormalities are nearly always seen in sleep EEG or series of EEGs. Consistently normal EEGs are exceptional.

None of the interictal EEG abnormalities in PS appear to determine prognosis. The EEG, as in some other epilepsies, often remains abnormal long after clinical remission of seizures. The abnormalities are expected to become less florid with time and usually eventually disappear.

Ictal EEG recordings are rare. The discharge consists of rhythmic monomorphic decelerating theta or delta activity. Focal onset from the occipital regions is most frequent, but bifrontal ictal onsets have also been described.

Pathophysiology

The EEG in PS appears to indicate that the condition is associated with a diffuse/multifocal cortical hyperexcitability. This is also supported by magnetoencephalographic data.⁴⁵ The predominance of interictal occipital EEG abnormalities suggests the possibility that the site of seizure onset is usually occipital. This is supported by the fact that three out of four reported ictal recordings had occipital onset. However, it seems likely that seizure onset may also be from extra-occipital sites. The clinical manifestations suggest that there is preferential spread to autonomic centres, including emetic centres or their cortical projections. Where these are is undetermined.

PS is one of the age-related idiopathic focal epilepsies of childhood. Evidence suggests that its aetiology and pathogenesis is likely to be similar to that of other similar epilepsies, such as benign childhood epilepsy with centrottemporal spikes. PS is compared with Rolandic epilepsy and Gastaut-

type idiopathic childhood occipital epilepsy in Table I.

Management

Education about the nature and prognosis of the syndrome is the cornerstone of correct management. Parents of children with the disorder should receive detailed information about the nature of the disorder and appropriate management of further seizures.

Recommendations for antiepileptic drug treatment of PS come from case series. There are no randomized controlled studies. Prognosis, in terms of ultimate remission of seizures, does not appear to be affected by antiepileptic drug treatment. There is currently no evidence that the prolonged, non-convulsive seizures of PS pose a risk of damage. The seizures are often few in number. These features are similar to the situation with benign childhood epilepsy with centrottemporal spikes, in which it is now generally considered that antiepileptic drug treatment is not always required. Regular antiepileptic drug treatment in PS is probably most appropriately reserved for those children in whom seizures are unusually frequent or distressing or are otherwise significantly interfering in the life of the child. Prolonged seizures in PS can reasonably be treated with 'rescue' benzodiazepines (rectal diazepam or oral midazolam) as for febrile seizures.

There is no evidence that any particular antiepileptic drug is more efficacious than any other in PS. Of the established antiepileptic drugs, carbamazepine and sodium valproate appear to be equally appropriate. Given the benign nature of the syndrome, it is particularly important to avoid adverse effects; polypharmacy is rarely, if ever, indicated. The EEG should not be used as a guide to starting or stopping antiepileptic drug treatment. Given the short duration of active seizures in most children with PS, withdrawal after 1–2 seizure-free years is appropriate.

DOI: 10.1017/S0012162206000508

Accepted for publication 9th December 2005.

References

1. Engel J Jr. (2001) A proposed diagnostic scheme for people with epileptic seizures and with epilepsy: report of the ILAE Task Force on Classification and Terminology. *Epilepsia* **42**: 796–803.
2. Panayiotopoulos CP (1981) Inhibitory effect of central vision on occipital lobe seizures. *Neurology* **31**: 1330–1333.
3. Panayiotopoulos CP (1988) Vomiting as an ictal manifestation of epileptic seizures and syndromes. *J Neurol Neurosurg Psychiatry* **51**: 1448–1451.
4. Panayiotopoulos CP (1989) Benign childhood epilepsy with occipital paroxysms: a 15-year prospective study. *Ann Neurol* **26**: 51–56.
5. Panayiotopoulos CP (1999) Extraoccipital benign childhood partial seizures with ictal vomiting and excellent prognosis. *J Neurol Neurosurg Psychiatry* **66**: 82–85.
6. Panayiotopoulos CP (2002) *Panayiotopoulos Syndrome: A Common and Benign Childhood Epileptic Syndrome*. London: John Libbey.
7. Panayiotopoulos CP (2004) Autonomic seizures and autonomic status epilepticus peculiar to childhood: diagnosis and management. *Epilepsy Behav* **5**: 286–295.
8. Gastaut H. (1981) Benign epilepsy with occipital spike waves in children. *Bull Mem Acad R Med Belg* **136**: 540–555.
9. Gastaut H. (1982) A new type of epilepsy: benign partial epilepsy of childhood with occipital spike-waves. *Clin Electroencephalogr* **13**: 13–22.
10. Gastaut H. (1982) Benign spike-wave occipital epilepsy in children. *Rev Electroencephalogr Neurophysiol Clin* **12**: 179–201.

11. Gastaut H. (1982) The benign epilepsy in childhood with occipital spike wave complexes. *EEG-EMG Z Elektroenzephalogr Elektromyogr Verwandte Geb* 13: 3–8.
12. Gastaut H. (1982) Benign spike-wave occipital epilepsy in children. *Rev Electroencephalogr Neurophysiol Clin* 12: 179–201.
13. Gastaut H, Zifkin BG. (1987) Benign epilepsy of childhood with occipital spike and wave complexes. In: Andermann F, Lugaresi E, editors. *Migraine and Epilepsy*. Boston: Butterworths. p 47–81.
14. Gastaut H, Roger J, Bureau M. (1992) Benign epilepsy of childhood with occipital paroxysms. Up-date. In: Roger J, Bureau M, Dravet C, Dreifuss FE, Perret A, Wolf P, editors. *Epileptic Syndromes In Infancy, Childhood And Adolescence*. London: John Libbey. p 201–217.
15. Caraballo R, Cersosimo R, Medina C, Fejerman N. (2000) Panayiotopoulos-type benign childhood occipital epilepsy: a prospective study. *Neurology* 55: 1096–1100.
16. Caraballo RH, Astorino F, Cersosimo R, Soprano AM, Fejerman N. (2001) Atypical evolution in childhood epilepsy with occipital paroxysms (Panayiotopoulos type). *Epileptic Disord* 3: 157–162.
17. Caraballo RH, Sologuestua A, Granana N, Adi JN, Cersosimo RO, Mazza E, Foster O, Fejerman N. (2004) Idiopathic occipital and absence epilepsies appearing in the same children. *Pediatr Neurol* 30: 24–28.
18. Covanis A, Lada C, Skiadas K. (2003) Children with rolandic spikes and ictus emeticus: Rolandic epilepsy or Panayiotopoulos syndrome? *Epileptic Disord* 5: 139–143.
19. Demirbilek V, Dervent A. (2004) Panayiotopoulos syndrome: video-EEG illustration of a typical seizure. *Epileptic Disord* 6: 121–124.
20. Ferrie CD, Beaumanoir A, Guerrini R, Kivity S, Vigeveno F, Takaishi Y, Watanabe K, Mira L, Capizzi G, Costa P, Valseriati D, Gironi D, Lerman P, Ricci S, Vigliano P, Goumas-Kartalai A, Hashimoto K, Robinson RO, Panayiotopoulos CP. (1997) Early-onset benign occipital seizure susceptibility syndrome. *Epilepsia* 38: 285–293.
21. Ferrie CD, Grunewald RA. (2001) Panayiotopoulos syndrome: a common and benign childhood epilepsy. *Lancet* 357: 821–823.
22. Ferrie CD, Koutroumanidis M, Rowlinson S, Sanders S, Panayiotopoulos CP. (2002) Atypical evolution of Panayiotopoulos syndrome: a case report. *Epileptic Disord* 4: 35–42.
23. Kivity S, Lerman P. (1989) Benign partial epilepsy of childhood with occipital discharges. In: Manelis J, Bental E, Loeber JN, Dreifuss FE, editors. *Advances in Epileptology. XVIIth Epilepsy International Symposium*. New York: Raven Press. p 371–373.
24. Kivity S, Lerman P. (1992) Stormy onset with prolonged loss of consciousness in benign childhood epilepsy with occipital paroxysms. *J Neurol Neurosurg Psychiatry* 55: 45–48.
25. Kivity S, Ephraim T, Weitz R, Tamir A. (2000) Childhood epilepsy with occipital paroxysms: clinical variants in 134 patients. *Epilepsia* 41: 1522–1523.
26. Koutroumanidis M. (2002) Panayiotopoulos syndrome: a common benign but underdiagnosed and unexplored early childhood seizure syndrome. *Br Med J* 324: 1228–1229.
27. Lada C, Skiadas K, Theodorou V, Covanis A. (2003) A study of 43 patients with Panayiotopoulos syndrome: a common and benign childhood seizure susceptibility. *Epilepsia* 44: 81–88.
28. Martinovic Z. (2001) Panayiotopoulos syndrome. *Lancet* 358: 69.
29. Martinovic Z. (2001) Clinical correlations of electroencephalographic occipital epileptiform paroxysms in children. *Seizure* 10: 379–381.
30. Martinovic Z. (2002) Panayiotopoulos syndrome or early-onset benign childhood occipital epilepsy. *Epilepsia* 43: 1268–1272.
31. Nahum E, Kivity S, Ben Ari J, Weisman Y, Schonfeld T. (2001) Benign occipital epilepsy mimicking a catastrophic intracranial event. *Pediatr Emerg Care* 17: 196–198.
32. Oguni H, Hayashi K, Imai K, Hirano Y, Mutoh A, Osawa M. (1999) Study on the early-onset variant of benign childhood epilepsy with occipital paroxysms otherwise described as early-onset benign occipital seizure susceptibility syndrome. *Epilepsia* 40: 1020–1030.
33. Oguni H, Hayashi K, Funatsuka M, Osawa M. (2001) Study on early-onset benign occipital seizure susceptibility syndrome. *Pediatr Neurol* 25: 312–318.
34. Oguni H. (2001) Panayiotopoulos syndrome. *Lancet* 358: 69.
35. Ohtsu M, Oguni H, Hayashi K, Funatsuka M, Imai K, Osawa M. (2003) EEG in children with early-onset benign occipital seizure susceptibility syndrome: Panayiotopoulos syndrome. *Epilepsia* 44: 435–442.
36. Sanders S, Rowlinson S, Manidakis I, Ferrie CD, Koutroumanidis M. (2004) The contribution of the EEG technologists in the diagnosis of Panayiotopoulos syndrome (susceptibility to early onset benign childhood autonomic seizures). *Seizure* 13: 565–573.
37. Ueno M, Oguni H, Yasuda K, Osawa M. (2001) Neurophysiological study of secondary synchronous occipito-frontopolar spikes in childhood. *Clin Neurophysiol* 112: 2106–2112.
38. Verrotti A, Domizio S, Guerra M, Sabatino G, Morgese G, Chiarelli F. (2000) Childhood epilepsy with occipital paroxysms and benign nocturnal childhood occipital epilepsy. *J Child Neurol* 15: 218–221.
39. Verrotti A, Domizio S, Melchionda D, Guerra M, Mucedola T, Onofri M, Chiarelli F, Sabatino G. (2000) Stormy onset of benign childhood epilepsy with occipital paroxysmal discharges. *Childs Nerv Syst* 16: 35–39.
40. Vigeveno F, Lispi ML, Ricci S. (2000) Early onset benign occipital susceptibility syndrome: video-EEG documentation of an illustrative case. *Clin Neurophysiol* 111 (Suppl. 2): S81–S86.
41. Watanabe K. (2004) Benign partial epilepsies. In: Wallace SJ, Farrell K, editors. *Epilepsy in Children*. London: Arnold. p 199–220.
42. Yalcin AD, Kaymaz A, Forta H. (1997) Childhood occipital epilepsy: seizure manifestations and electroencephalographic features. *Brain Dev* 19: 408–413.
43. Yoshinaga H, Koutroumanidis M, Shirasawa A, Kikumoto K, Ohtsuka Y, Oka E. (2005) Dipole analysis in Panayiotopoulos syndrome. *Brain Dev* 27: 46–52.
44. Verrotti A, Salladini C, Trotta D, di Corcia G, Chiarelli F. (2005) Ictal cardiorespiratory arrest in Panayiotopoulos syndrome. *Neurology* 64: 1816–1817.
45. Kanazawa O, Tohyama J, Akasaka N, Kamimura T. (2005) A magnetoencephalographic study of patients with Panayiotopoulos syndrome. *Epilepsia* 46: 1106–1113.