

Pakistan Journal of Nutrition 8 (8): 1199-1203, 2009

ISSN 1680-5194

© Asian Network for Scientific Information, 2009

Some Biochemical, Haematological and Histological Responses to a Long Term Consumption of *Telfairia occidentalis*-Supplemented Diet in Rats

Emeka, E.J. Iweala*¹ and Onyechi Obidoa²

¹Department of Biological Sciences, Biochemistry and Molecular Biology Unit,
Covenant University, P.M.B 1023, Ota, Ogun State, Nigeria

²Department of Biochemistry, University of Nigeria, Nsukka, Nigeria

Abstract: Some biochemical, haematological and histological responses were studied in rats undergoing a long term feeding with a *Telfairia occidentalis*-supplemented diet. Biochemical and hematological parameters investigated included serum protein, total cholesterol, lipid peroxidation, haemoglobin, white blood cells, Aspartate aminotransferase, Alanine aminotransferase, Alkaline phosphatase, Glutathione-s-transferase and Superoxide dismutase. Histological changes associated with *Telfairia occidentalis*-supplemented diet on the liver, intestine and testes were also examined. Results showed that *Telfairia occidentalis*-supplemented diet caused a significant increase ($p < 0.05$) in weight and haemoglobin. Cholesterol and lipid peroxidation were significantly reduced ($p < 0.05$). There were however no significant changes in the enzymes including Aspartate aminotransferase, Alanine aminotransferase, Alkaline phosphatase, Glutathione-s-transferase and Superoxide dismutase. Only Alkaline phosphatase was significantly reduced ($p < 0.05$). Histological changes showed hypertrophy of the intestinal propia and reduced goblet cells while the testes exhibited thick basement membrane and large spermatogonia.

Key words: *Telfairia occidentalis*, weight, haemoglobin, cholesterol, lipid peroxidation

INTRODUCTION

Regular consumption of plant foods are associated with numerous health benefits rooted in their various physiological effects as a result of their phytochemical and nutritional constituents (Hunter and Fletcher, 2002). Green leafy vegetables are particularly important in promoting health because of their rich sources of nutrients (Gupta and Prakash, 2009). *Telfairia occidentalis* (Fluted pumpkin) is a common tropical green leafy vegetable native to many African countries especially Eastern Nigeria (Burkett, 1968). It thrives in humid climate and well drained soils and is usually cultivated in garden and family farms around homes. *Telfairia occidentalis* belongs to the family Cucurbitaceae and has simple, dark green veined leaves that is as wide as 18 cm and long as 35 cm. *T. occidentalis* contains nutrients such as proteins, carbohydrates, vitamins, minerals and fiber (Fasuyi, 2006). It also contains oxalates, saponins, glycosides, flavonoids, alkaloids and resins (Tindall, 1968; Akubue *et al.*, 1980). The nutritional content of *T. occidentalis* makes it desirable as dietary supplement for humans. The leaves are widely consumed and used in preparation of soups and salads. In ethno medicine, the fresh leaves are used in the treatment of anemia, convulsion and malaria (Alada, 2000; Gbile, 1986). The wide spread consumption of leaves of *T. occidentalis* reflects a substantive measure of its nutritional acceptability of as a health promoting plant food. In spite of the widespread use of *T. occidentalis*, there is scanty

information on its various biological and histological effects. This study investigated some biochemical, haematological and histological changes associated with the long term consumption of a diet supplemented with leaves of *T. occidentalis* in albino rats.

MATERIALS AND METHODS

Preparation of leaves of *T. occidentalis*: Fresh leaves of *T. occidentalis* were harvested fresh after 4 weeks of leaf emergence from a garden farm in South-Eastern Nigeria. The leaves were picked, air-dried and ground to a coarse powdered form with a hammermill. The proximate composition of the ground leaves of *T. occidentalis* were determined according to the procedure of AOAC (1975) in order to formulate an isonitrogenous and isocaloric feed together with other feedstuff.

Formulation of experimental feeds: Two feeds namely Control Diet (CD) and *Telfairia Occidentalis*-supplemented Diet (TOSD) were formulated. The feedstuff used in formulation of feed included feed grade maize, corn flour, fish meal, groundnut meal, bone meal and vitamin premix purchased from a reputable manufacturer (Jocan Agro Ltd, Umuahia, Nigeria). The proximate composition of the leaves of *T. occidentalis* was used as a guide in the formulation of the experimental diet that was both isocaloric and isonitrogenous. The Control Diet (CD) was formulated without the inclusion of *T. occidentalis* leaf powder while

the *Telfairia Occidentalis*-supplemented Diet (TOSD) was incorporated with 5% of *T.occidentalis* leaf powder.

Animal grouping and experimental design: A total of twenty albino male rats of the Wistar stock aged four weeks old used for the experiment were purchased from the animal house of the department of Biochemistry, University of Nigeria, Nsukka. The animals had an average weight of 45.5±2.85 g. The animals were fed with Control Diet (CD) at the start of the experiment for acclimatization and given water *ad libitum*.

The experimental design was completely randomized involving random distribution of the rats into two experimental groups namely Control Group (CG) and Experimental Group (EG) of ten animals each having similar group mean weights at the start of the experiment. The animals in CG and EG were fed Control Diet (CD) and *Telfairia Occidentalis*-supplemented Diet (TOSD) respectively and given water *ad libitum* for 180 days (9 6 months). Weight changes of animals in the two groups were recorded monthly.

Collection of blood, organs and tissue samples: At the end of the 180 days of feeding, six animals from each group were anesthetized and decapitated. Blood samples were collected in labeled sample bottles with drops of Ethylenediaminetetraacetic Acid (EDTA). Serum samples were collected in sample bottles without EDTA, allowed to clot and centrifuged at 5000 rpm for 10 min. The liver, intestines and testes were promptly excised soon after decapitation and stored in 10% formyl saline.

Haematological studies: Hemoglobin and White Blood Cells (WBC) were determined according to methods described by Dacie (1975) and Dacie and Lewis (1991).

Biochemical determinations: Total serum protein was determined by the Lowry method (1951), total and free cholesterol were determined by the method of Searcy and Bergquist (1960). Lipid peroxidation was determined by the method of Walin *et al.* (1993).

Enzyme assays: Glutathione-s-transferase was determined according to the method of Habig *et al.* (1974). Superoxide dismutase was assayed by the method of Jewett and Rocklin (1993). Aspartate Aminotransferase (AST), Alanine aminotransferase (ALT) and Alkaline Phosphatase (ALP) were determined using Randox test kits.

Histological studies: Histological studies on the organs and tissues were done according to procedures described by Disbrey and Rack (1974) and Drury and Wellington (1967). The tissues were viewed under light microscopy.

Statistical analysis: Results were expressed as Mean ± Standard Error of Mean (SEM) for triplicate determinations. A One-way analysis of variance (ANOVA) for a completely randomized design and Duncan's multiple range tests were used to analyze experimental data. Values were considered significant at p<0.05.

RESULTS

The results of the long term effect of feeding *Telfairia Occidentalis*-supplemented Diet (TOSD) on weight and some biochemical parameters are presented in Table 1. TOSD caused a significant percentage increase (p<0.05) in weight gain when compared to the control. There were significant reductions in the cholesterol level and lipid peroxidation to 0.88±0.10 Mm/L and 3.05±0.30 respectively in animals fed TOSD. Hemoglobin levels were also remarkably increased in the animals fed with TOSD. The changes in serum protein and WBC count were not statistically significant.

The effect of TOSD on some enzyme levels are presented in Table 2. All the enzymes did not show any significant changes except Alkaline phosphatase which significantly decreased to 76.3±3.68.

The histological features of liver, intestine and testes of the rats fed with Control Diet (CD) and TOSD are shown in Fig. 1a, 1b, 2a, 2b, 3a and 3b. There was a slight distortion in the hepatic architecture and plates of the animals fed with TOSD. Also the intestinal propia were

Table 1: Effect of *T.occidentalis*-supplemented diet (TOSD) on some biochemical and haematological parameters (n = 3)

Experimental groups (Diet)	Weight (%)	Protein (mg/ml)	Cholesterol (mM/L)	Hemoglobin (g/dl)	WBC (10 ⁹ /mm ³)	Lipid Peroxidation (mg/ml)
Control diet (CD)	60.0±7.28	261±16.4	1.43±0.18	9.8±0.50	5.13±0.29	5.03±0.23
<i>T.occidentalis</i> -supplemented diet (TOSD)	70.8±6.82*	279±13.2	0.88±0.10*	12.8±0.95*	5.27±0.17	3.05±0.30

**p<0.05

Table 2: Effect of *T.occidentalis*-supplemented diet (TOSD) on some enzymes (n = 3)

Experimental groups (Diet)	GST (IU/l)	SOD (U/mg protein)	AST (IU/l)	ALT (IU/l)	ALP (IU/l)
Control diet (CD)	5.41 ± 0.82	70.7 ± 3.68	88.7 ± 7.41	45.3 ± 5.3	88.6 ± 8.96
<i>T.occidentalis</i> -supplemented diet (TOSD)	7.13 ± 1.44	59.7 ± 2.62	63.0 ± 3.56	32.3 ± 4.03	76.3 ± 3.68

**p<0.05

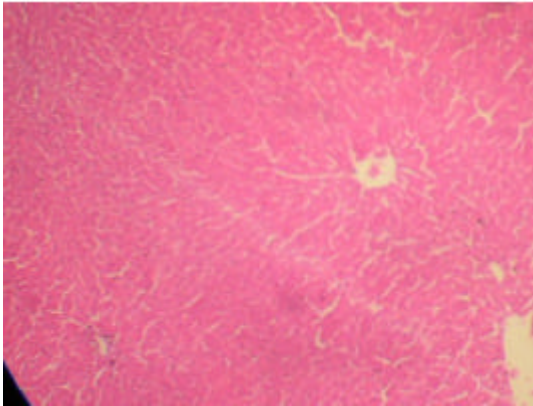


Fig. 1a: Photo micrography of a cross section of liver of rats fed with Control Diet (CD). MAG. x 40

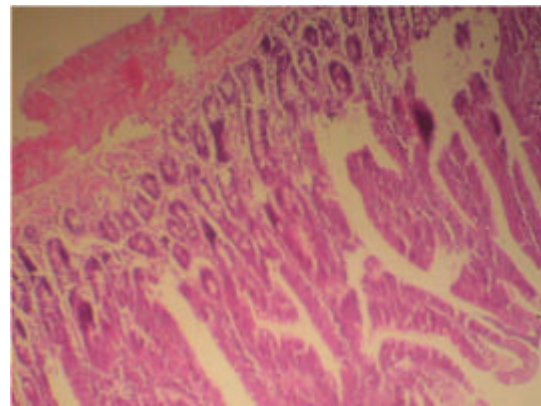


Fig. 2a: Photo micrography of a cross section of intestine of rats fed with control diet (CD). MAG. x 40

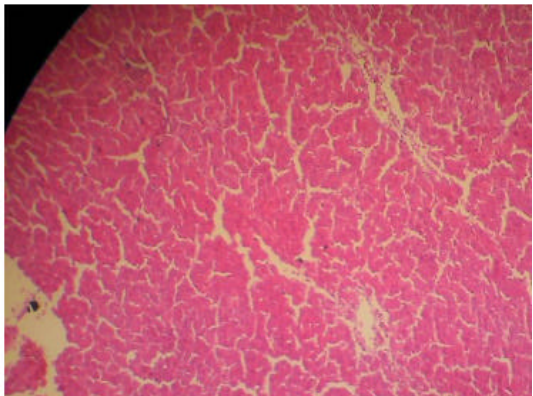


Fig. 1b: Photo micrography of a cross section of liver of rats fed with *Telfairia occidentalis*-supplemented Diet (TOSD). MAG. x 40

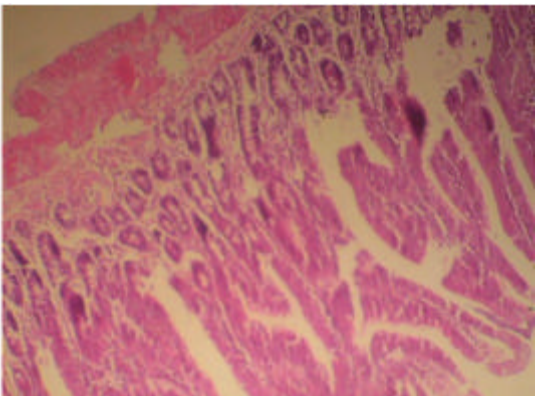


Fig. 2b: Photo micrography of a cross section of intestine of rats fed with *Telfairia occidentalis*-supplemented diet (TOSD). MAG. x 40

hypertrophied and while the goblet cells were reduced in the group fed TOSD. The testes of the rats fed with TOSD exhibited thickened basement membrane and large spermatogonia when compared to the control.

DISCUSSION

Telfairia occidentalis possesses unique nutritional and phytochemical properties which can have varied physiological and biochemical effects (Longe *et al.*, 1983). In this study, the long term feeding of *T. occidentalis*-supplemented diet (TOSD) caused a significant increase in weight of the animals which may be due to its content of rich nutrients. *Telfairia occidentalis* contains nutrients such as amino acids, fatty acids, mineral and vitamins (Fagbemi, 2007). The increase in weight may also be related to increased feed intake. Leaves of *T. occidentalis* are highly palatable and consumed largely in a variety of diets in South-Eastern Nigeria. The feed may also have effect on the feed conversion rate of the animals (Adedapo *et al.*, 2008).

In addition certain phytochemicals found in *T. occidentalis* may affect intake and digestibility of nutrients (Dube *et al.*, 2001). Lipid peroxidation was significantly reduced ($p < 0.05$) in the animals fed with TOSD. This result confirms the antioxidant effects of *Telfairia occidentalis* extracts reported by Nwanna and Oboh (2007). Anti oxidant effects of vegetables such as *Telfairia occidentalis* are attributed to the presence of phenolic compounds such as flavonoids, polyphenols as well as vitamins (Halliwell and Gutteridge, 1999). The non significant changes in the enzymes namely Alanine amino transaminase (ALT), Aspartate Transaminase (AST), Glutathione-s-transferase (GST) suggests some level of hepatoprotective effects of TOSD on the rats (Oboth, 2005). This presumption is also accentuated by the non significant change in serum proteins which are largely produced in the liver. Also the non-significant change in Superoxide Dismutase (SOD) complements the decrease in lipid peroxidation previously discussed.

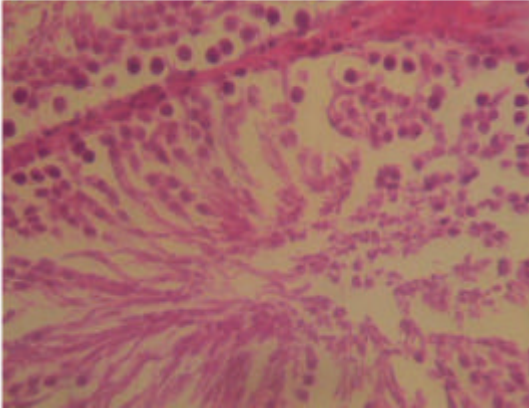


Fig. 3a: Photo micrography of a cross section of testes of rats fed with Control Diet (CD). MAG. x 8

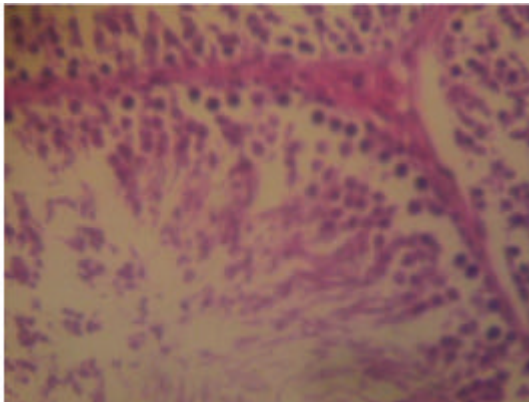


Fig. 3b: Photo micrography of a cross section of testes of rats fed with *Telfairia occidentalis*-supplemented diet (TOSD). MAG. x 8

These antioxidant effects of TOSD is indispensable in protecting the animals that consume the its leaves against reactive oxygen species. TOSD significantly increased the haemoglobin concentration of the rats. This finding is related to the presence of some haematological factors including proteins, iron, thiamine, riboflavin and nicotinamide in the leaves of *T.occidentalis* (Ganong, 1997; Fasuyi and Nonyerem, 2007). This result agrees with the study of Alada (2000) and lends validity to the use of leaves of *T.occidentalis* in treatment of anemia (Gbile, 1986). The TOSD showed various cellular effects on the histological characteristics of the tissues examined. The liver of rats fed TOSD showed some irregularity possibly due to the presence of minute quantities of alkaloids in the leaves of *T.occidentalis*. The intestinal histology showed some level of atrophy suggesting indigestibility. This could be attributed to the presence of tannins and saponins in leaves of *T.occidentalis* known to cause indigestion in

grazing animals (Reed, 1995). This observation could have toxic consequences. A further study on the effect of consumption of TOSD on intestinal function of rats is being carried out in our laboratory. Large spermatogonia seen in the histological examination of the testis of rats fed with TOSD is related to increase in spermatogenesis. This observation corroborates the finding of Nwangwa *et al.* (2007) which showed that *T.occidentalis* has regenerative effect on the histology of rat testes. There are unverified claims by traditional herbalists in Nigeria that consumption of leaves of *T.occidentalis* increases sperm count and reproductivity.

REFERENCES

- Adedapo, A.A., M.O. Sofidiya, M.J. Masika and A.J. Afolayan, 2008. Safety Evaluations of the aqueous extract of *Acacia karroo* stem bark in rats and mice. *Rec. Nat. Prod.*, 2: 128-134.
- Akubue, P.I, A. Kar and F.N. Nnachetta, 1980. Toxicity of extracts of roots and leaves of *Telfairia occidentalis*. *Planta Med.*, 38: 339-343.
- Alada, A.R.A., 2000. The haematological effect of *Telfairia occidentalis* diet preparation. *Afr. J. Biomedical Res.*, 3: 185-186.
- AOAC, 1975. Official methods of analysis. Association of official agricultural chemists 12th ed. Washington D.C 811-817.
- Burkett, H.M., 1968. The results of plants of West Africa. Vol. 1 pg. 603-604. Royal Botanic Garden Kews. England.
- Dacie, J.V., 1975. Practical haematology. Churchill Living-stone, New York.
- Dacie, J.V. and S.M. Lewis, 1991. Practical Haematology. Churchill Living-stone, New York.
- Dube, J.S., J.D. Reed and L.R. Ndlovu, 2001. Proanthocyanidins and other phenolics in *Acacia* leaves of Southern Africa. *Anim. Feed Sci. Technol.* 91: 59-67.
- Disbrey, B.D. and J.H. Rack, 1974. Histological Laboratory Methods. Livingstone, Edinburgh, pp: 56-128.
- Drury, R.A.B. and E.A. Wallington, 1967. Careton's Histological Technique, 4th ed. Oxford University Press, London, pp: 120-123.
- Fagbemi, T.N., 2007. Effects of processing on the nutritional composition of fluted pumpkin (*Telfairia occidentalis*) seed flour. *Nig. Food J.*, 25: 1-22.
- Fasuyi, A.O. and A.D. Nonyerem, 2007. Biochemical, nutritional and haematological implications of *Telfairia occidentalis* leaf meal as protein supplement in broiler starter diets. *Afr. J. Biotechnol.*, 6: 1055-1063.
- Fasuyi, A.O., 2006. Nutritional potentials of some tropical vegetable leaf meals: chemical characterization and functional properties. *Afr. J. Biotech.*, 5: 49-53.

- Ganong, W.F., 1997. A review of medical physiology pg. 496. Appleton and Large.
- Gbile, Z.O., 1986. Ethnobotany, Taxonomy and Conservation of Medicinal plant. In the state of medicinal plant research in Nigeria. Pg. 19 Edited by A.O. Sofowora.
- Gupta, S. and J. Prakash, 2009. Studies on Indian green leafy vegetables for their antioxidant activity. Plant Foods Hum. Nutr., 64: 39-45.
- Habig, W.H., M.J. Pabst and W.B. Jakoby, 1974. Glutathione S-transferases. The first enzymatic step in mercapturic acid formation. J. Biol. Chem., 249: 7130-7139.
- Halliwell, B. and J.M.C. Gutteridge, 1999. Free radicals in biology and medicine, Ed. 3, Oxford: Oxford University Press, Oxford.
- Hunter, K.J. and J.M. Fletcher, 2002. The antioxidant activity and composition of fresh, frozen, jarred and canned vegetable. Innov Food Sci. Emerg. Technol., 3: 399-406.
- Jewett, S.L. and A.M. Rocklin, 1993. Variation of one unit of activity with oxidation rate of organic substrate in indirect superoxide dismutase assays. Anal Biochem., 212: 555-9.
- Longe, O.G., G.O. Farinu and B.L. Fetuga, 1983. Nutritional value of the fluted pumpkin (*Telfairia occidentalis*). J. Agric. Food Chem., 311: 989-992.
- Lowry, O.H., N.J. Rosebrough, A.L. Farr and R.J. Randall, 1951. Protein measurement with the folin phenol reagent. J. Biol. Chem., 193: 265-275.
- Nwangwa, E.K., J. Mordi, O.A. Ebeye and A.E. Ojeh, 2007. Testicular regenerative effects induced by the extracts of *Telfairia occidentalis* in rats. Caderno de Pesquisa, série Biologia, 19: 27-35.
- Nwanna, E.E. and G. Oboh, 2007. Antioxidant and hepatoprotective properties of polyphenol extracts from *Telfairia occidentalis* (fluted pumpkin) leaves on acetaminophen induced liver damage. Pak. J. Biol. Sci., 10: 2682-7.
- Oboth, G., 2005. Hepatoprotective property of ethanolic and aqueous extract of fluted pumpkin (*Telfairia occidentalis*) leaves against garlic induced oxidative stress. J. Med. Food., 8: 560-563.
- Reed, J.D., 1995. Nutritional toxicology of tannins and related polyphenols in forage legumes. J. Anim. Sci., 73: 1516-1528.
- Searcy, P.I. and L.M. Bergquist, 1960. A new color reaction for the quantitation of serum cholesterol. Clin. Chem. Acta., 5:192-199.
- Tindal, H.D., 1968. Commercial vegetable growing. Oxford Press. London, Pg. 69.
- Wallin, B., B. Rosengren, H.G. Shertzer and G. Camejo, 1993. Lipoprotein oxidation and measurement of thiobarbituric acid reacting substances formation in a single microtiter plate: its use for evaluation of antioxidants. Anal. Biochem., 208: 10-15.