

SOLUTION

Volume One

2238

Includes
the Fully
Searchable
Online Text

See Details
Inside

Mastery of Surgery

FIFTH EDITION

Editor

Josef E. Fischer

Associate Editor

Kirby I. Bland

Section Editors

Mark P. Callery

G. Patrick Clagett

Daniel B. Jones

Frank W. LoGerfo

James M. Seeger



Wolters Kluwer
Health

Lippincott
Williams & Wilkins



Mastery of Surgery

FIFTH EDITION

Editor

Josef E. Fischer, M.D.

Mallinckrodt Professor of Surgery
Harvard Medical School;
Chairman, Department of Surgery
Beth Israel Deaconess Medical Center
Boston, Massachusetts

Associate Editor

Kirby I. Bland, M.D.

Fay Fletcher Kerner Professor
Chairman, Department of Surgery
University of Alabama at Birmingham School of
Medicine
Birmingham, Alabama

Section Editors

Mark P. Callery, M.D.

Associate Professor
Department of Surgery
Harvard Medical School;
Chief, Division of General Surgery
Beth Israel Deaconess Medical Center
Boston, Massachusetts

G. Patrick Clagett, M.D.

Jan and Bob Pickens Distinguished Professor
Division of Vascular Surgery
Department of Surgery
University of Texas Southwestern Medical
Center
Dallas, Texas

Daniel B. Jones, M.D.

Associate Professor
Department of Surgery
Harvard Medical School;
Chief, Section for Minimally Invasive Surgery
Beth Israel Deaconess Medical Center
Boston, Massachusetts

Frank W. LoGerfo, M.D.

William McDermott Professor of Surgery
Harvard Medical School;
Director, Division of Vascular and Endovascular
Surgery
Beth Israel Deaconess Medical Center
Boston, Massachusetts

James M. Seeger, M.D.

Professor and Chief
Division of Vascular Surgery
Department of Surgery
University of Florida College of Medicine
Gainesville, Florida

Acquisitions Editor: Brian Brown
Managing Editor: Julia Seto
Associate Director of Marketing: Adam Glazer
Project Manager: Bridgett Dougherty
Manufacturing Manager: Kathleen Brown
Creative Director: Doug Smock
Designer: Karen Quigley
Compositor: TechBooks
Printer: R.R. Donnelley, Willard

© 2007 by LIPPINCOTT WILLIAMS & WILKINS
530 Walnut Street
Philadelphia, PA 19106 USA
LWW.com

4th Edition © 2001
Lippincott Williams & Wilkins,
3rd, 2nd, 1st Editions © Little Brown

All rights reserved. This book is protected by copyright. No part of this book may be reproduced in any form or by any means, including photocopying, or utilized by any information storage and retrieval system without written permission from the copyright owner, except for brief quotations embodied in critical articles and reviews. Materials appearing in this book prepared by individuals as part of their official duties as U.S. government employees are not covered by the above-mentioned copyright.

Printed in the USA

Library of Congress Cataloging-in-Publication Data

Mastery of surgery / editor, Joseph E. Fischer ; associate editor, Kirby
I. Bland ; section editors, Mark P. Callery . . . [et al.] .— 5th ed.
p. : cm.

Includes bibliographical references and index.

ISBN-13: 978-0-7817-7165-8 (alk. paper)

ISBN-10: 0-7817-7165-X (alk. paper)

1. Surgery. I. Fischer, Josef E., 1937- II. Bland, K. I.

[DNLM: 1. Surgery. 2. Surgical Procedures, Operative. WC 100 M423
2007]

RD11 M29 2007
617—dc22

2006035127

Care has been taken to confirm the accuracy of the information presented and to describe generally accepted practices. However, the authors, editors, and publisher are not responsible for errors or omissions or for any consequences from application of the information in this book and make no warranty, expressed or implied, with respect to the currency, completeness, or accuracy of the contents of the publication. Application of this information in a particular situation remains the professional responsibility of the practitioner.

The authors, editors, and publisher have exerted every effort to ensure that drug selection and dosage set forth in this text are in accordance with current recommendations and practice at the time of publication. However, in view of ongoing research, changes in government regulations, and the constant flow of information relating to drug therapy and drug reactions, the reader is urged to check the package insert for each drug for any change in indications and dosage and for added warnings and precautions. This is particularly important when the recommended agent is a new or infrequently employed drug.

Some drugs and medical devices presented in this publication have Food and Drug Administration (FDA) clearance for limited use in restricted research settings. It is the responsibility of the health care provider to ascertain the FDA status of each drug or device planned for use in their clinical practice.

To purchase additional copies of this book, call our customer service department at (800) 638-3030 or fax orders to (301) 223-2320. International customers should call (301) 223-2300.

Visit Lippincott Williams & Wilkins on the Internet: at LWW.com. Lippincott Williams & Wilkins customer service representatives are available from 8:30 am to 6 pm, EST.

10 9 8 7 6 5 4 3 2 1

Chapter 87: Laparoscopic Gastric Bypass 980*Stacy A. Brethauer and Philip R. Schauer***Chapter 88: The Lap Band Technique of Placement 990***Paul E. O'Brien***Chapter 89: Laparoscopic Biliopancreatic Diversion with Duodenal Switch 995***Brian P. Jacob and Alfons Pomp***D. The Liver and Biliary Tract****Chapter 90: Surgical Anatomy of the Liver and Bile Ducts 1005***Henri Bismuth and Eric Vibert***Chapter 91: Diagnostic Considerations in Liver Disease 1019***Yuman Fong and Kimberly M. Dalal***Chapter 92: Drainage of Hepatic, Subphrenic, and Subhepatic Abscesses 1033***Jonathan L. Meakins, Andrew J. E. Seely, and Jane Phillips-Hughes***Chapter 93: Echinococcal Cysts: Etiology, Diagnosis, Complications and Medical and Surgical Treatment 1043***Mark P. Callery***Chapter 94: Echinococcal Cysts 1069***E. Moreno González, J.C. Meneu Díaz, and A. Moreno Elola***Chapter 94A: Echinococcal Cysts: Etiology***E. Moreno González, J.C. Meneu Díaz, and A. Moreno Elola***Chapter 95: Major Hepatic Resection for Primary and Metastatic Tumors 1076***Sheung Tat Fan, Chung Mau Lo, and Chi Leung Liu***Chapter 96: Treatment of Major Hepatic Trauma 1092***Donald D. Trunkey***Chapter 97: Cholecystostomy, Cholecystectomy, and Intraoperative Evaluation of the Biliary Tree 1106***O. James Garden***Chapter 98: Laparoscopic Cholecystectomy, Intraoperative Cholangiography, and Common Bile Duct Exploration 1116***John G. Hunter and Sarah K. Thompson***Chapter 99: Reconstruction of the Bile Duct: Anatomic Principles and Surgical Techniques 1129***Steven M. Strasberg and William Hawkins***Chapter 100: Current Application of Endoscopic Sphincterotomy, Lateral Choledochoduodenostomy, and Transduodenal Sphincteroplasty 1143***Jeffrey W. Hazey, E. Christopher Ellison, W. Scott Melvin, and Stephen G. Moon***Chapter 101: Treatment of Primary Sclerosing Cholangitis 1153***C. Wright Pinson and Mary T. Austin***Chapter 102: High Malignant Biliary Tract Obstruction 1165***Steven A. Curley***Chapter 103: Cholecystojejunostomy and Choledochojejunostomy/Hepaticojejunostomy 1174***Herbert R. Freund***Chapter 104: Operative Treatment for Choledochal Cyst 1182***Greg M. Tiao***Chapter 105: Biliary Atresia 1187***Faisal G. Qureshi, Orkan Ergun, and Henri R. Ford***Chapter 106: Liver Transplantation 1196***Douglas W. Hanto and Scott Johnson***Chapter 106a: The Unfinished Legacy of Liver Transplantation: Emphasis on Immunology 1212***Thomas E. Starzl and Fadi G. Lakkis***Volume II****E. The Pancreas****Chapter 107: Surgical Anatomy of the Pancreas 1223***Lee J. Skandalakis, Gene L. Colborn, John E. Skandalakis, Marios Loukas, Panajiotis N. Skandalakis, and Petros Mirilas***Chapter 108: Roux-en-Y Lateral Pancreaticojejunostomy for Chronic Pancreatitis 1244***Richard A. Prinz, Mark R. Edwards, and Roderick M. Quiros***Chapter 109: Pancreaticoduodenectomy for Chronic Pancreatitis 1253***L. William Traverso***Chapter 110: Partial, Subtotal, and Total Duodenum-preserving Resection of the Pancreatic Head in Chronic Pancreatitis and Neoplastic Lesions 1259***Hans G. Beger, Bettina M. Rau, and Bertram Poch***Chapter 111: Necrosectomy for Acute Necrotizing Pancreatitis 1268***Charles M. Vollmer, Jr.*

Kent W. Kercher, MD
 Department of Surgery
 Carolinas Medical Center
 Charlotte, North Carolina

Lalita Khoodhiar, MD
 Instructor in Medicine
 Department of Medicine
 Harvard Medical School
 Staff Physician
 Department of Medicine
 Beth Israel Deaconess Medical Center
 Boston, Massachusetts

Young Bae Kim, MD
 Director, Division of Gynecologic Oncology
 Beth Israel Deaconess Medical Center
 Assistant Professor of Obstetrics, Gynecology and
 Reproductive Biology
 Harvard Medical School
 Boston, Massachusetts

Masaki Kitajima, MD
 Department of Surgery
 School of Medicine
 Keio University
 Tokyo, Japan

W. John Kitzmiller, MD
 Associate Professor and Chief of Plastic
 Surgery
 Department of Surgery
 University of Cincinnati College of
 Medicine
 Chief, Division of Plastic Surgery
 Department of Surgery
 University Hospital
 Cincinnati, Ohio

Mikel V. Knazev
 Russia

Ira J. Kodner MD
 Professor of Surgery
 Washington University
 St. Louis, Missouri

Alan J. Koffron, MD
 Department of Surgery
 Northwestern Memorial Hospital
 Chicago, Illinois

Paul B. Kreienberg

**Jake E.J. Krige, MD, FACS, FCS (SA),
 FRCS (ED)**
 Associate Professor of Surgery
 Department of Surgery
 University of Cape Town Health Sciences Faculty and
 Surgical Gastroenterology
 Groote Schuur Hospital
 Cape Town, South Africa

Irving L. Kron, MD
 Professor and Chair
 Department of Surgery
 University of Virginia Health System
 Charlottesville, Virginia

Helen Krontiras, MD
 Section of Surgical Oncology
 University of Alabama School of Medicine
 Birmingham, Alabama

Robert D. Kugel, MD
 Herma Treatment Center Northwest
 Olympia, Washington

Alan P. Kypson, MD, FACS
 Assistant Professor of Surgery
 Division of Cardiothoracic and Vascular Surgery
 Brody School of Medicine
 East Carolina University
 Greenville, North Carolina

Fadi G. Lakkis, MD
 Thomas E. Starzl Transplantation Institute
 Department of Surgery
 University of Pittsburgh Medical Center
 Pittsburgh, Pennsylvania

Gregory J. Landry, MD
 Division of Vascular Surgery
 Oregon Health Sciences University
 Portland, Oregon

David W. Larson, MD
 Assistant Professor of Surgery
 Division of Colorectal Surgery
 Mayo Clinic
 Rochester, Minnesota

Ian C. Lavery, MB, BS
 The Cleveland Clinic Foundation
 Cleveland, Ohio

**Simon Law, MS, MA (Cantab), MB, BChir,
 FRCS(ED), FRCSEd, FRCSEd, FHKAM, FACS**
 Professor of Surgery
 University of Hong Kong Medical Centre
 Queen Mary Hospital
 Hong Kong, China

Anna M. Ledgerwood, MD
 Professor
 Department of Surgery
 Wayne State University
 Trauma Director
 Department of Surgery
 Detroit Receiving Hospital
 Detroit, Michigan

Bernard Travis Lee, MD
 Instructor in Surgery
 Harvard Medical School
 Division of Plastic Surgery
 Department of Surgery
 Beth Israel Deaconess Medical Center
 Boston, Massachusetts

Jeffrey E. Lee, MD
 Professor of Surgery
 Department of Surgery
 The University of Texas
 Professor of Surgery
 Department of Surgical Oncology
 MD Anderson Cancer Center
 Houston, Texas

W. Anthony Lee, MD
 Associate Professor
 Division of Vascular Surgery and Endovascular Therapy
 Department of Surgery
 University of Florida College of Medicine
 Gainesville, Florida

Luis R. Leon, Jr., MD, RVT
 Assistant Professor of Clinical Surgery
 Department of Vascular Surgery
 University of Arizona Health Sciences Center
 Chief
 Department of Vascular Surgery
 Southern Arizona Veterans Affairs Health Care
 System
 Tucson, Arizona

Antoon E.M.R. Lerut, MD, PHD
 Professor
 Department of Surgery
 Catholic University Chairman
 Department of Thoracic Surgery
 University Hospitals Leuven
 Leuven, Belgium

O. Alex Lesani, MD
 University Hospitals of Cleveland
 Cleveland, Ohio

Keith D. Lillemo, MD
 Professor and Chairman
 Department of Surgery
 Indiana University
 Chief of Surgery
 Department of Surgery
 Indiana University Hospital
 Indianapolis, Indiana

Timothy K. Liem, MD
 Division of Vascular Surgery
 Oregon Health Sciences University
 Portland, Oregon

Guilherme Lima
 The James Buchanan Brady Urological Institute
 Johns Hopkins Medical Institutions
 Baltimore, Maryland

Philip A. Linden, MD
 Harvard Medical School
 Associate Surgeon, Division of Thoracic Surgery
 Brigham and Women's Hospital
 Boston, Massachusetts

Fred N. Littooy, MD
 Eminent Professor
 Department of Surgery
 Loyola University Medical Center
 Maywood, Illinois

Chi-Leung Liu, MB, BS
 Department of Surgery
 The University of Hong Kong
 Queen Mary Hospital
 Hong Kong, China

Chung-Mau Lo, MB, BS
 Department of Surgery
 The University of Hong Kong
 Queen Mary Hospital
 Hong Kong, China

Frank W. LoGerfo, MD
 Distinguished William V. McDermott Professor of Surgery
 Division of Vascular and Endovascular Surgery
 Beth Israel Deaconess Medical Center
 Boston, Massachusetts

Marios Loukas, MD, PHD
 Associate Professor
 Department of Anatomical Sciences
 St. George's University
 Grenada, West Indies
 Department of Education and Development
 Harvard Medical School
 Boston, Massachusetts

Donald E. Low, MD
 Head, Section General Thoracic Surgery
 Virginia Mason Medical Center
 Clinical Instructor
 Department of Surgery
 University of Washington School of Medicine
 Seattle, Washington

Steph
 Profess
 Depart
 UMD
 Attent
 Depar
 Roben
 New J

Char
 Profes
 Depa
 Ways
 Dete
 Dete

Jam
 Profe
 Chiu
 Chiu
 Co-
 Um
 Pitt

Ro
 Chn
 Dep
 Ver
 Wa

Jar
 JS
 Inu
 Inu

Ja
 Ph
 H
 V
 A
 R

I
 M
 I

J

Chapter

106

Liver Transplantation

DOUGLAS W. HANTO AND SCOTT JOHNSON

Chronic liver disease is the eighth leading cause of death in the United States. The most common causes of this disease include hepatitis C virus (HCV), alcohol, nonalcoholic fatty liver disease, and hepatitis B virus. Liver transplantation is the only treatment remaining for many patients with end-stage liver disease. There are currently more than 17,000 patients waiting for a liver transplant, but only 6,168 transplantation procedures were performed in 2004.



INDICATIONS

Liver transplantation is indicated in patients with (a) debilitating or life-threatening complications of liver disease, or (b) early-stage hepatocellular carcinoma when surgical resection is not an option because of concomitant liver disease or tumor location. The specific disease indications include noncholestatic cirrhosis (e.g., alcoholic liver disease), chronic active hepatitis (B, C, or autoimmune), cryptogenic, nonalcoholic steatohepatitis, cholestatic liver disease/cirrhosis (e.g., primary biliary cirrhosis, primary sclerosing cholangitis, Caroli disease, and biliary atresia); fulminant liver failure (e.g., acetaminophen overdose, hepatitis, ischemia, idiosyncratic drug toxicity); metabolic diseases (e.g., α_1 -antitrypsin deficiency, Crigler-Najjar disease, type I, Byler disease, glycogen storage disease, types IA and IV, Wilson disease, hemochromatosis, tyrosinemia, ornithine transcarbamylase deficiency, and galactosemia); malignant neoplasms (e.g., hepatoblastoma, heman-gioendothelioma, angiosarcoma, hepatocellular carcinoma); and other disease-induced liver diseases, such as Budd-Chiari syndrome, benign neoplasms, and total parenteral nutrition (Table 1).

CONTRAINDICATIONS

The contraindications to liver transplantation have decreased as our ability to perform transplants successfully has improved for patients who are more sicker and more complex. Absolute contraindications include advanced uncorrectable cardiac or pulmonary disease, severe irreversible pulmonary hypertension (>50 mm Hg), irreversible

neurologic impairment, uncontrolled sepsis, and extrahepatic malignancy (with the exception of skin cancer and some neuroendocrine tumors). Protocols exist for a number of diseases that were previously thought to be absolute contraindications for transplantation. These diseases include human immunodeficiency virus (HIV), infection, advanced hepatocellular carcinoma, and cholangiocarcinoma (Table 2). There is currently a National Institutes of Health-sponsored trial of kidney and liver transplantation in selected HIV-positive patients.

TIMING

Prior to February 2002, allocation of deceased donor livers was heavily influenced by wait times of the intended recipient. In February 2002, the Model for End-stage Liver Disease (MELD) system was implemented by the United Network for Organ Sharing and de-emphasized waiting time and allocated deceased donor livers on the basis of severity of recipient disease. The MELD scoring system uses three objective laboratory values (serum creatinine, serum bilirubin, and international normalized ratio [INR]) that are entered into the regression equation to determine an individual's MELD score (range, 6 to 40):

$$\text{MELD score} = 9.57 \times \log_e \text{Creatinine (mg/dL)} + 3.78 \times \log_e \text{Bilirubin (mg/dL)} + \log_e \text{INR} + 6.43 \text{ (disease constant)}$$

This model was originally described to predict 3-month mortality rates in cirrhotic patients undergoing transjugular intrahepatic portal systemic shunts, but several studies have also shown that the MELD score predicts the risk of dying for patients awaiting liver transplantation. United Network for Organ Sharing allocates deceased donor livers first to status I patients and then patients according to their MELD score. A Pediatric End-Stage Liver Disease (PELD) system for pediatric patients has also been implemented that incorporates age, bilirubin, height/weight, INR, and bilirubin. Recent data

suggest that mortality rates for patients with a MELD score of 15 to 17 are equivalent with or without transplant, mortality rates are less with transplant for patients with MELD scores of more than 17, and mortality rates for patients with MELD scores of less than 15 are lower on the waiting list compared with transplant.

Patients with hepatocellular carcinoma meeting the United Network for Organ Sharing listing criteria (single tumor, <5.0 cm or two or three tumors, the largest of which is <3.0 cm) are initially assigned a MELD score of 22 (equal to a 3-month mortality rate of 15%) and are given additional points equivalent to a 10% mortality until they receive a transplant. This policy was instituted in order to facilitate transplantation for patients with hepatocellular carcinoma before their tumors were too large or had metastasized, thereby precluding successful transplantation.



PREOPERATIVE EVALUATION

Potential liver transplant recipients undergo an evaluation that begins with a history, physical examination, routine laboratory studies, chest radiograph, and electrocardiogram. All patients require hepatitis serology (A, B, and C), viral serology (herpes simplex virus, cytomegalovirus, Epstein-Barr virus, HIV, and varicella-zoster virus), infectious serology (rapid plasma reagin, toxoplasmosis, and rubella), α -fetoprotein, carbohydrate antigen 19-9 (in patients with suspected cholangiocarcinoma or sclerosing cholangitis), computerized axial tomography (CAT) or magnetic resonance imaging of the abdomen (for vessel patency, liver volume, and to rule out hepatic tumors) with computerized reconstructions of the vasculature, upper gastrointestinal endoscopy, dental evaluation, Pap smear, mammogram (in women older than 40 years), and prostate-specific antigen (in men older than 40 years). Other studies that are obtained less frequently, depending on the patient's history and disease, include pulmonary function tests, colonoscopy (in patients older than 50 years), echocardiogram, dipyr-

TABLE 1. INDICATIONS FOR LIVER TRANSPLANTATION

Noncholestatic cirrhosis
Hepatitis C virus
Alcohol
Cryptogenic
Autoimmune
Hepatitis B virus
Nonalcoholic steatohepatitis
Cholestatic cirrhosis
Primary biliary cirrhosis
Primary sclerosing cholangitis
Caroli disease
Biliary atresia
Other
Fulminant liver failure
Acetaminophen overdose
Hepatitis
Ischemia
Idiosyncratic drug reaction
Metabolic diseases
α -antitrypsin deficiency
Crigler-Najjar disease, type I
Byler disease
Glycogen storage disease types IA and IV
Wilson disease
Hemochromatosis
Tyrosinemia
Ornithine transcarbamylase deficiency
Galactosemia
Malignant neoplasms
Hepatoblastoma
Hemangioendothelioma
Hemangiosarcoma
Hepatocellular carcinoma
Cholangiocarcinoma
Metastatic
Other
Budd-Chiari syndrome
Polycystic liver disease
Total parenteral nutrition
Benign hepatic tumors

TABLE 2. CONTRAINDICATIONS TO LIVER TRANSPLANTATION

Absolute
Advanced uncorrectable cardiac or pulmonary disease
Severe irreversible pulmonary disease (>50 mm Hg)
Irreversible neurologic impairment
Uncontrolled sepsis
Extrahepatic malignancy (with the exception of skin cancer and some neuroendocrine tumors)
Relative
Human immunodeficiency virus infection
Advanced hepatocellular carcinoma
Cholangiocarcinoma

damole stress thallium study, cardiac catheterization with coronary angiography, and psychiatric evaluation (for any patient with a history of substance abuse, alcohol abuse, or psychiatric illness). Appropriate consultations from cardiology, pulmonary disease, neurology, and infectious disease specialists are obtained as needed.



TREATMENT OF PATIENTS WITH LIVER FAILURE

Acute Liver Failure

Patients with acute fulminant hepatic failure or decompensation of chronic liver disease require urgent inpatient evaluation and consideration of listing for liver transplantation. The principles of management of patients with acute fulminant hepatic failure include (a) protection against and treating of cerebral edema, (b) maintenance of other organ system function (e.g., cardiovascular, respiratory, and renal), (c) protection against complications of coagulopathy, (d) prevention of sepsis, and (e) prevention of hypoglycemia. Patients in stage III or IV coma are intubated when there is concern regarding respiratory insufficiency or a risk of aspiration.

All patients undergo placement of a Swan-Ganz catheter, an arterial line, and a Foley catheter for appropriate fluid management. A CT scan of the head is obtained. The patient's coagulopathy is corrected (INR, <1.5) and factor VII administration is particularly effective. An epidural, intraparenchymal, or subdural intracranial pressure monitor is placed to monitor intracranial pressure and cerebral perfusion pressure. Cerebral edema is managed by the use of hyperventilation, intravenous mannitol, and fluid restriction, maintaining the serum osmolality at approximately 325 mOsm/dL. The patient's coagulopathy is closely monitored and treated as needed with fresh-frozen plasma, cryoprecipitate, factor VII, and platelets. If the patient requires large amounts of blood products, diuretics are administered as necessary to avoid cerebral edema. Patients are treated with prophylactic antibiotics to prevent sepsis. Patients undergo very close neurologic monitoring and are aggressively treated for any evidence of an increase in intracranial pressure or a decrease in cerebral perfusion pressure (<60 mm Hg).

Chronic Liver Failure

The principles of managing patients with chronic liver failure require treating the manifestations of portal hypertension, in-

cluding controlling ascites, prevention of infection and bleeding, treating hepatic encephalopathy, maintaining adequate nutrition, and symptomatic relief. For patients with hepatocellular carcinoma, local control with radiofrequency ablation or chemoembolization is important to prevent disease progression while they are waiting for transplantation. These individuals are followed closely with CT or magnetic resonance imaging at 3-month intervals to ensure that disease does not progress beyond established criteria.

INTRAOPERATIVE MANAGEMENT

Because patients undergo induction of general anesthesia, often with a full stomach, a rapid-sequence induction with cricoid pressure is used for intubation. Monitoring and infusion lines, nasogastric tube, and Foley catheter are placed, and continuous electrocardiography, pulse oximetry, capnography, and core temperature monitoring are performed. Transesophageal echocardiographic monitoring in individuals with pre-existing cardiac disease or in those with evidence of pretransplant pulmonary hypertension should be used. Intraoperatively, close monitoring of arterial blood pressure, central venous and pulmonary artery pressures, cardiac output, systemic vascular resistance, stroke volume, and urine output is critical during the recipient hepatectomy, when blood loss can be significant. Laboratory studies, including hemoglobin/hematocrit, platelet count, electrolytes, ionized calcium, prothrombin time, partial thromboplastin time, and INR, factor and fibrinogen levels, fibrin degradation products, and arterial blood gases, are measured at least hourly.

There are several major events that occur intraoperatively during liver transplantation that require attention. During the recipient hepatectomy, it is critical to replace ongoing blood loss carefully and to maintain normal fluid, electrolyte, and coagulation homeostasis. Overly rapid correction of coagulation abnormalities, however, may lead to intraoperative thrombosis, including pulmonary embolus, and right heart failure. During the anhepatic phase, careful attention to hemodynamic changes, electrolyte abnormalities, and coagulation abnormalities is important, and appropriate measures to correct any deviations from normal are taken as necessary. Before unclamping the liver, additional calcium, sodium bicarbonate, and fluid or blood products are administered. After

the liver is unclamped, there can be a brief period of hyperkalemia, hypocalcemia, metabolic acidosis, depressed cardiac output and hypotension, pulmonary hypertension and right ventricular dysfunction, and fibrinolysis that requires careful correction. Once the patient is stabilized and all bleeding is controlled, overcorrection of minor abnormalities in the INR or platelet count should be avoided to minimize the risk of subsequent intravascular, hepatic artery, or portal vein thrombosis.

DECEASED DONOR SELECTION

Donor selection and liver procurement are critical to prevent primary nonfunction or delayed primary function of the transplanted liver, and to prevent disease transmission. Donor factors that must be considered include ABO and size compatibility, age, cause of death, hemodynamic stability, other medical conditions, social history, laboratory values, and viral serology. Primary nonfunction occurs in 5% to 10% of transplants and requires urgent retransplantation. Donor risk factors for primary nonfunction include advanced age (>60 years), macrovesicular steatosis (>30%), prolonged cold and warm ischemia, hypotension and vasopressor use, and the use of donors after cardiac death. Donors with one or more of these factors have been termed *expanded criteria donors* and, in the past, livers from these donors have been discarded. Because of the marked increase in the number of patients on the waiting list, many centers have expanded their use of these donors. In most instances, the presence of one factor alone will not have an impact on posttransplant organ function, but the presence of multiple factors may lead to initial poor function or primary nonfunction and must be considered. In addition to donor factors, recipient factors also can contribute to initial poor function or primary nonfunction.

HCV remains the most frequent indication for liver transplantation in this country and, because of the universal recurrence of the virus after transplant, HCV-positive donors have been used in HCV-positive recipients with equivalent patient and graft survival rates compared with HCV-negative donors. The use of steatotic livers and livers from older donors has been shown to increase the rate and progression of recurrent HCV after transplant and should be avoided.

Surgical Technique

DECEASED DONOR HEPATECTOMY

Standard Technique

A midline incision is made from the suprasternal notch to the symphysis pubis (Fig. 1). This includes a sternotomy. In obese patients, a transverse abdominal incision at the level of the umbilicus can facilitate exposure. The abdomen is thoroughly examined to exclude any unsuspected infections, malignancies, or other disease processes that would preclude organ retrieval. The dissection can proceed in one of several ways, depending on the surgeon's preference. In the standard technique, most of the dissection is performed "warm," while the heart is still beating. It is important to gain early control of both the supraceliac (Fig. 2) and infrarenal aorta in case the donor becomes unstable; this allows for rapid cannulation and aortic cross-clamping should the need arise. The right-sided peritoneal reflection is incised and the cecum, ascending colon, and small bowel mesentery are mobilized toward the left. The aorta can now be dissected and looped just proximal to its bifurcation. Next, the supraceliac aorta is controlled; the left coronary and triangular

ligaments are incised and the left lobe of the liver is retracted toward the right. The peritoneum overlying the gastroesophageal junction is divided and the esophagus is retracted toward the left. The diaphragmatic crura can then be divided to expose the supraceliac aorta, which is looped.

The dissection then continues in the gastrohepatic ligament. A replaced left hepatic artery arising from the left gastric artery occurs in approximately 17% of donors, usually passes through the superior portion of the gastrohepatic ligament to the liver, and must be carefully preserved by tracing it to its junction with the left gastric artery. The left gastric artery is then traced to its origin at the celiac trunk, identifying and ligating any arterial branches to the stomach. The dissection then continues in the hepatoduodenal ligament. The tissue of the hepatoduodenal ligament is incised close to the duodenum, the common bile duct is identified inferiorly, and the proper hepatic artery is identified at the superior aspect of the porta hepatis. The proper hepatic artery is dissected free and followed proximally along the superior border of the pancreas, and the gastroduodenal and right hepatic arteries are ligated. The splenic artery is identified and preserved if the pancreas is being retrieved and ligated, and divided if it is not. The common

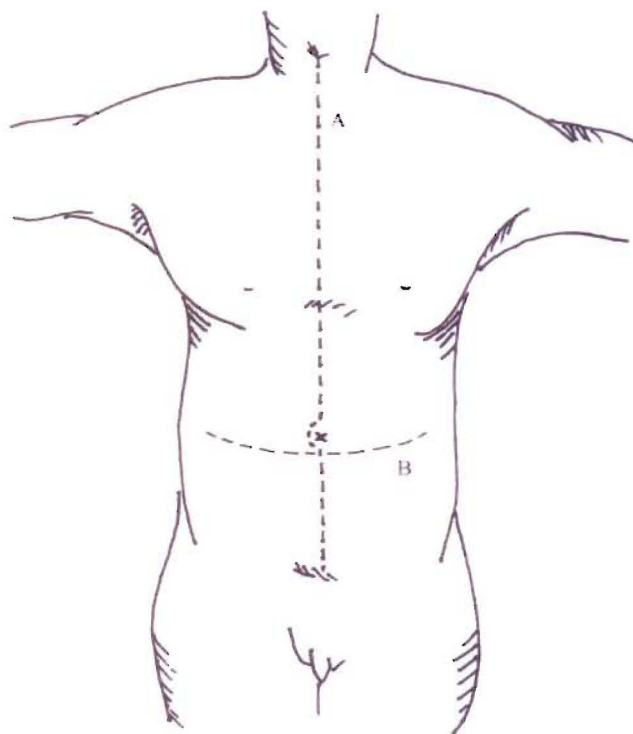


Fig. 1. Incision for deceased donor operation from the suprasternal notch (A) (B) to the pubic bone and which can be "cruciated" if required.

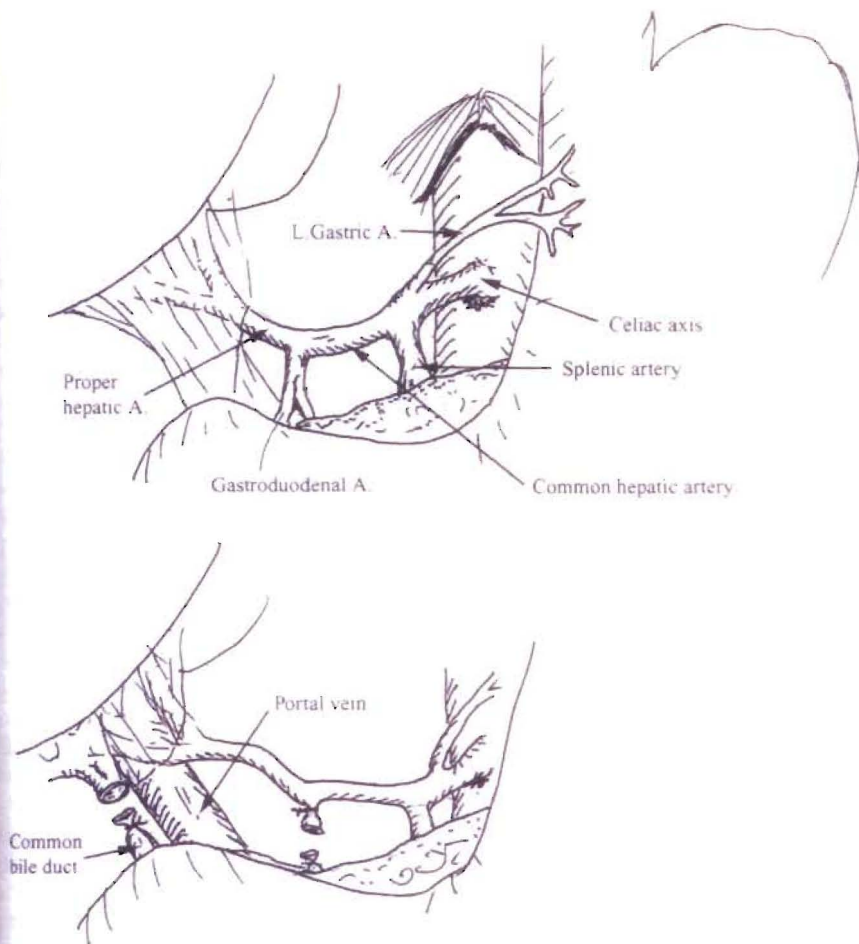


Fig. 2. Anatomic relationships in the porta hepatis and the supraceliac aorta.

hepatic artery is then freed to the level of the celiac axis.

The tissue between the hepatic artery and common bile duct overlying the portal vein is incised, and the anterior surface of the portal vein is exposed. The portal vein is mobilized and isolated. A replaced right hepatic artery, arising from the superior mesenteric artery, occurs in 19% of donors. It is located lateral and deep to the common bile duct and is traced to its origin with the superior mesenteric artery. In most cases, the replaced right hepatic artery can be separated from the head of the pancreas, allowing preservation of the pancreas for transplant if necessary. The proximal part of the superior mesenteric artery trunk is kept with the replaced right hepatic artery, and the distal part of the superior mesenteric artery is preserved with the pancreas. The portal vein is separated from the common bile duct, which is then encircled distal to the entry of the cystic duct while preserving the periductal tissue, which contains its blood supply, ligating the left gastric (coronary) vein along its superior aspect, and ligating

the pancreaticoduodenal vein branch that is usually on the anterior or inferior aspect of the portal vein. The common bile duct is then ligated distally, adjacent to the pancreas, and divided. An incision is made in the fundus of the gallbladder, and the biliary tree is irrigated with cold saline. This prevents necrosis of the biliary tract mucosa, which is caused by bile remaining in contact with the mucosa during cold storage.

Next, a site is selected for placement of the portal infusion catheter. This can be placed either directly into the portal vein itself, into the superior mesenteric vein, or into the inferior mesenteric vein. The superior mesenteric vein can be easily isolated at the root of the small bowel mesentery. The inferior mesenteric vein can be found just to the left of the ligament of Trietz. The infrahepatic vena cava is mobilized above the level of the renal veins. If easily visualized, the right adrenal vein can be ligated and divided at this time. Any remaining ligamentous attachments to the right lobe of the liver are then divided.

The patient is then systemically heparinized with 30,000 units, intravenously,

and the distal aorta is ligated with an umbilical tape. The aorta is compressed against the vertebral column by the assistant, an aortotomy is made, and a perfusion catheter is inserted into the aorta and secured with an umbilical tape. A No. 10-14 French catheter is inserted into the portal system, either through the inferior mesenteric vein, superior mesenteric vein, or directly into the portal vein. The supraceliac aorta is cross-clamped and the vena cava is vented in the right chest by incising the inferior vena cava-right atrium junction. Alternatively, the venting may take place through a cannula placed in the distal vena cava. Surface cooling of the liver, pancreas, and kidneys is achieved by placing cold slush solution in the abdomen.

Usually, 3 L (500 to 1,000 mL in children) of University of Wisconsin (UW) preservation solution is infused into the aorta, and 2 L (100 to 250 mL in children) are infused into the portal vein during a period of approximately 10 minutes (Fig. 3). The liver edges should be carefully observed for signs of overperfusion, manifested by a liver that is tense to palpation and rounded at the edges.

The liver is excised by dividing the aorta proximal to the celiac axis and distal to either the celiac axis or superior mesenteric artery, depending on whether a replaced right hepatic artery is present. If the pancreas is being removed, then the portal vein is divided to provide an adequate length of vein for the liver and for the pancreas. The inferior vena cava is divided proximal to the renal veins. The suprahepatic vena cava will have been divided above the diaphragm by the cardiac surgeon. The diaphragm is divided around the suprahepatic vena cava, and the liver is taken to the back table and placed in cold UW solution. An additional 250 to 500 mL of UW solution is infused into the hepatic artery, 500 to 750 mL is infused into the portal vein, and a small amount into the common bile duct. The effluent from the hepatic veins should be clear. The liver is then packaged in UW solution for transport. The iliac veins and arteries are excised and stored in cold UW in the event that vascular reconstruction is required in the recipient.

Before transplantation into the recipient, the deceased donor liver must be prepared on the back table. The diaphragm left on the liver is dissected free, and the suprahepatic vena cava is isolated. The three phrenic veins entering the suprahepatic vena cava must be identified, and must be suture-ligated to prevent bleeding after unclamping. The infrahepatic vena cava is cleaned of its attachments, the right adrenal

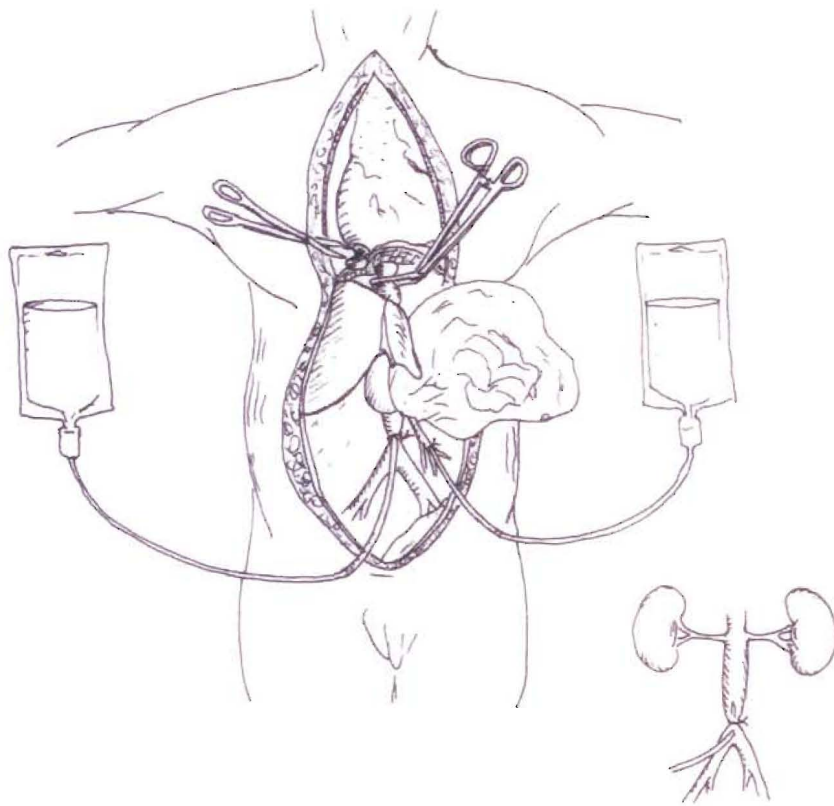


Fig. 3. Deceased donor liver procurement. The supraceliac aorta has been cross-clamped and the inferior vena cava divided at the atriocaval junction. Preservation solution is infused into both the aorta and portal vein. A drainage cannula is placed in the inferior vena cava.

vein is ligated, and any other small branches that were divided during retrieval are ligated. If the transplant is being performed as a piggyback the infrahepatic vena cava must be stapled with a vascular stapler or oversewn. The portal vein and hepatic artery are isolated, and the gallbladder is removed after ligation of the cystic artery and duct. UW solution is infused into the hepatic artery, portal vein, and vena cava to check for leaks. A portal vein cannula is secure in the portal vein for portal vein infusion during performance of the suprahepatic vena cava anastomosis.

Rapid Flush Technique

The "rapid flush" technique minimizes the amount of dissection before flushing with preservation solution. Although some surgeons use this technique or a variant routinely, it is most applicable in an unstable donor, from whom the expeditious removal of the liver is necessary, or in donors after cardiac death. The key steps involve division of the gastrohepatic ligament and isolation and preservation of a right or left hepatic artery, if present; incision and irrigation of the gallbladder; placement of a portal perfusion cannula in the inferior

mesenteric vein; placement of an aortic perfusion cannula in the distal aorta; and isolation of the supraceliac aorta for cross-clamping. The proximal aorta is clamped, and infusion of cold UW through the portal cannula and aortic catheter is begun. The liver, and often the pancreas, are then removed in a bloodless field. The common bile duct is divided. The right gastric artery and gastroduodenal artery are ligated on the side going to the liver, and divided. The left gastric artery and splenic artery are divided. The portal vein is dissected back to the junction of the splenic vein and superior mesenteric vein, which are divided once the portal flush has been completed. A patch of aorta incorporating the celiac axis is incised. The infrahepatic vena cava is divided just above the renal veins. The remaining peritoneal and diaphragmatic attachments are divided, and the liver and pancreas are removed en bloc and taken to the back table, where they are flushed as previously described. The liver and pancreas are then separated on the back table.

Donors after Cardiac Death

Liver transplantation using livers from donors after cardiac death or nonheart-

beating donors is being performed more frequently. Withdrawal of support usually takes place in an intensive care unit setting or in the operating room after consent is obtained. After withdrawal of life support, if the potential donor does not proceed to asystole within 1 hour, the procedure is usually abandoned. Incision is made only after 5 minutes of confirmed asystole and declaration of death by the patient's physician. A standard midline incision is made and the abdominal cavity is immediately packed with cold slush solution. The distal aorta is quickly cannulated with a large-bore cannula and perfusion begun with UW solution. It is usually easiest to vent through the distal vena cava. The supraceliac aorta is then cross-clamped. The organs and abdominal contents are carefully inspected during the flushing procedure. On completion of flushing, the procurement can then proceed using one of the techniques already described. This technique has not achieved widespread acceptance because of the logistics of retrieving organs from donors after cardiac death, concerns about long warm ischemia times leading to an increased risk of primary nonfunction, and biliary necrosis. With greater experience, however, donors after cardiac death could be an important source of viable livers, increasing the donor pool by 5% to 10%.

In Situ Splitting

A deceased donor liver may be split along anatomic planes allowing transplantation into two separate recipients.

Adult/Pediatric Split

In this technique, a left lateral segment graft is split from the main liver for use in a pediatric recipient, similar to a living donor left lateral segmentectomy (discussed later in this chapter and in Figure 6). The operation follows the principles of segmental liver anatomy as described by Couinaud. The split may be performed in situ or ex situ. Although in situ splitting is more time-consuming and requires careful coordination with the other procurement teams, it results in less biliary complications, less bleeding from the cut surface of the liver, and less risk of warm ischemic injury to the liver as it avoids back table manipulation of the allograft.

Standard principles of liver procurement are initially followed. The suprahepatic vena cava is exposed and the left hepatic vein is identified. The left hepatic vein is isolated separately from the middle hepatic vein. If there is a long common

Fig.
midd
left l
tery;

trun
duri
tran
in th
tified
into
vein
ven
may
The
The
and
arter
gin
vari
deal
plac
and
graf
plan
liga
con
inta
cro
per
the
sect
a le
me
side
6, 7
1) i

Ad
Th
her
ad
acc
are

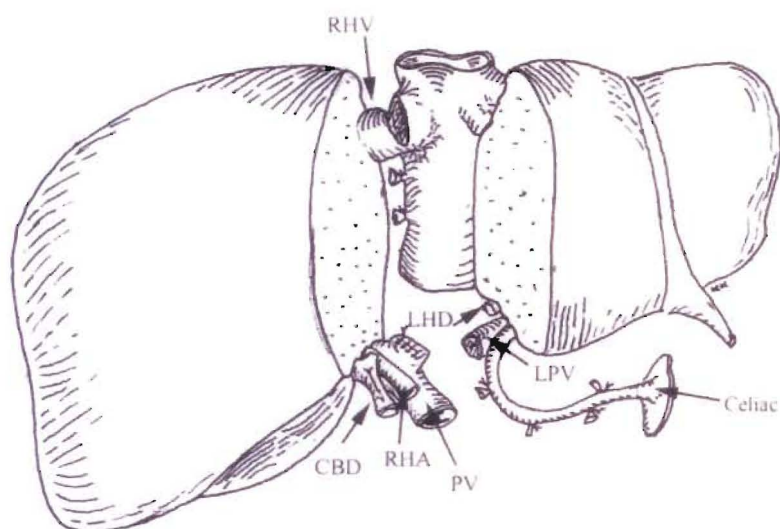


Fig. 4. Deceased donor adult/adult liver split. The liver is split in a plane just to the right of the middle hepatic vein, resulting in two hemigrfts. In this instance, the cava is preserved with the left lobe. RHV, right hepatic vein; LPV, left portal vein; LHD, left bile duct; RHA, right hepatic artery; PV, portal vein; CBD, common bile duct.

trunk, the left hepatic vein may be isolated during subsequent hepatic parenchymal transection. Dissection is then continued in the left hepatic hilum. This is best identified by following the umbilical ligament into the umbilical fissure. The left portal vein is isolated for its entire length. Small venous branches to segment 4 of the liver may be transected and ligated at this point. The left hepatic artery is also dissected. The segment 4 arterial branch is identified and preserved. Transection of the hepatic artery must be at a point distal to the origin of the segment 4 branch. Anatomic variations may be encountered and are dealt with accordingly. For example, a replaced left hepatic artery may be present, and this is kept with the lateral segment graft. Hepatic transection then begins in a plane just toward the right of the falciform ligament. Once parenchymal transection is complete, the vascular structures are left intact for the time being. The aorta is cross-clamped and flushing is performed per standard protocol. The liver graft can then be removed and the remaining transection completed *ex situ*. In this manner, a left lateral segment consisting of segments 2 and 3 is isolated. A larger, right-sided segment consisting of segments 4, 5, 6, 7, and 8 with the caudate lobe (segment 1) is also preserved for transplantation.

Adult/Adult Split

This is a true left-right split, whereby both hemilivers are transplanted into two small adults (Figs. 4 and 5). Again, the split is best accomplished *in situ*. All hilar structures are carefully identified. Bifurcations of the

hepatic artery, portal vein, and common bile duct are identified. The left hepatic vasculature can be temporarily clamped to identify a plane of transection. This is usually just toward the right of the middle hepatic vein. The liver parenchyma is carefully transected along this plane using standard methods. Once parenchymal transection is complete, the aorta is cross-clamped and flushing proceeds in the standard fashion. The liver is then removed and the final separation takes place on the back table.

There are several variations in the splitting of the vasculature. Typically, the main portal vein is kept with the right-sided graft because of the longer left portal vein

(Figs. 4 and 5). The celiac trunk, proper hepatic artery, and left hepatic artery are kept with the left-sided graft. This allows preservation of the segment 4 artery with the left-sided graft. The common bile duct is usually kept with the right-sided graft, with the division taking place at the left hepatic duct just beyond the bifurcation. The vena cava can be kept with either side (Figs. 4 and 5). Maintaining the cava with the right graft allows small and large hepatic veins draining the right to be kept intact (Fig. 5). The final result is a right-sided graft consisting of segments 5, 6, 7, and 8, and a left-sided graft consisting of segments 4, 3, and 2. Part of the caudate lobe may go to each side, depending on where the cava is preserved. Vascular structures may require reconstruction on the back table prior to implantation.

LIVING DONOR HEPATECTOMY

Left Lateral Segmentectomy

The left hepatic artery, left portal vein, and left hepatic duct are isolated far to the left of the porta hepatis at the base of the falciform ligament (Fig. 6). A segment 4 branch arising from the left hepatic artery is identified and preserved on the donor side. Similarly, any obvious portal venous branches supplying segment 4 should also be preserved. The left lateral segment hepatic vein is also identified and looped. Parenchymal transection takes place in a plane just to the right of the falciform ligament. The vessels are divided after systemic heparinization and the liver is flushed on the back table with cold UW solution. If necessary, a segment of recipient saphenous

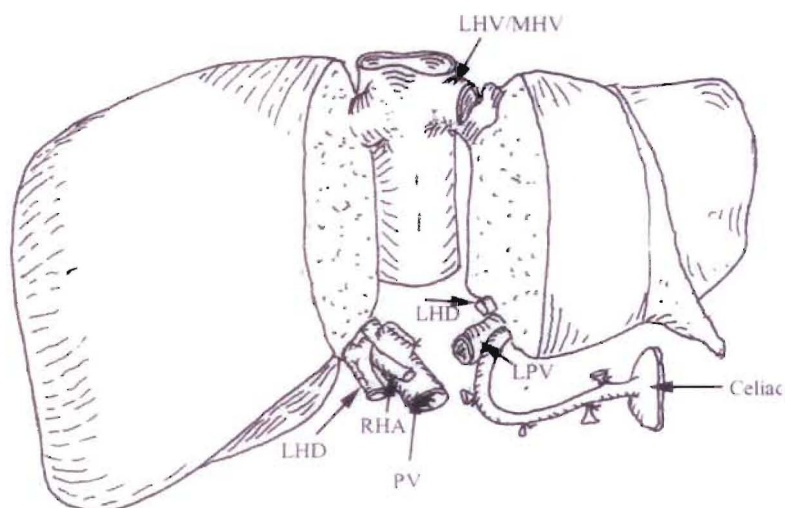


Fig. 5. Deceased donor adult/adult liver split. In this instance, the cava is preserved with the right lobe. LPV, left portal vein; LHD, left hepatic duct; RHA, right hepatic artery; PV, portal vein; MHV, middle hepatic vein.

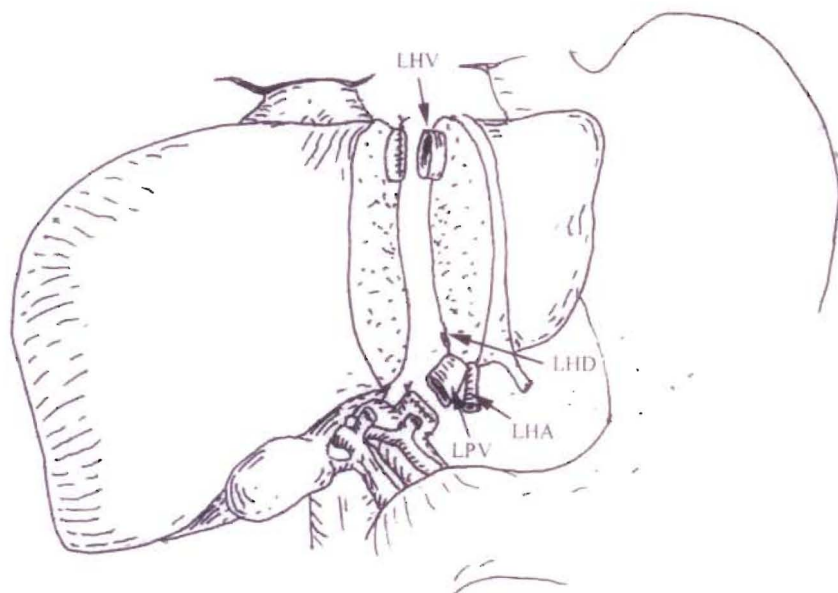


Fig. 6. Living donor left lateral segmentectomy. The liver is transected at the falciform ligament. Portal and arterial branches to the medial segment are preserved on the recipient side. LHV, left hepatic vein; LHD, left hepatic duct; LPV, left portal vein; LHA, left hepatic artery.

vein may be used to lengthen the hepatic artery. Portal vein grafts are avoided if possible.

Right Donor Hepatectomy

Dissection begins in the hepatoduodenal ligament (Fig. 7). The proper hepatic artery and its left and right bifurcation are identified. Occasionally, a segment 4 hepatic artery may arise from the right hepatic artery; this should be identified and preserved on the donor side. The gallbladder is excised and an intraoperative cholangiogram

is obtained through the stump of the cystic duct. It is of paramount importance to carefully delineate biliary anatomy as anatomic variations are common. If there is an early division of the right hepatic duct into anterior and posterior sectoral branches, it may not be possible to obtain a single duct, and two separate biliary anastomoses will have to be performed in the recipient. After cholangiography, the common bile duct is circumferentially dissected and the left and right hepatic ducts are exposed. This usually involves taking down the hilar plate. The portal vein and its left

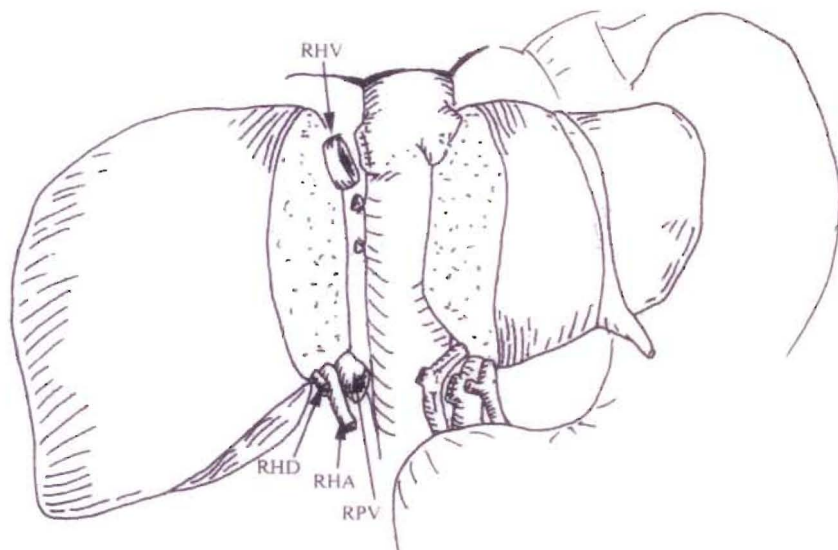


Fig. 7. Living donor right hepatectomy. The liver is transected in a plane to the right of the middle hepatic vein. RHV, right hepatic vein; RPV, right portal vein; RHA, right hepatic artery; RHD, right hepatic duct.

and right divisions can be exposed by retracting the freed hepatic artery toward the left side. Next, the right hepatic vein is identified and controlled. The right lobe of the liver is completely mobilized. The hepatocaval ligament is divided and small venous branches from the caudate lobe are ligated. Intraoperative ultrasound is particularly helpful in identifying the course of the middle hepatic vein, which guides parenchymal transection. Parenchymal transection is usually performed in a plane just toward the right of the middle hepatic vein. However, others prefer to transect the liver just to the left of the middle hepatic vein, keeping that structure with the graft.

On completion of parenchymal transection, the vessels are divided and the liver is flushed on the back table with cold UW solution. The liver is carefully inspected. Large segmental veins (draining segment 5 or 8) may require separate implantation, either directly into the recipient's vena cava or via a saphenous vein graft. Early bifurcation of the right portal vein may result in two separate portal venous branches. These can sometimes be spatulated together or, if this is not possible, reconstructed using a Y graft taken from explanted recipient portal vein.

RECIPIENT HEPATECTOMY

In this procedure, a bilateral subcostal skin incision with a midline extension to the xiphoid process is made (Fig. 8). The falciform ligament is divided cephalad until the anterior surface of the suprahepatic vena cava is identified. The left lobe of the liver is mobilized by dividing the left triangular and coronary ligaments and the gastrohepatic ligament. The hilar dissection begins by dividing the cystic duct and cystic artery. The left and right hepatic arteries are located along the superior border of the hilum and divided close to the liver to provide adequate length for a branch-branch anastomosis to the donor hepatic artery. The hepatic arteries are then dissected free proximally to the bifurcation, and a length of the common hepatic artery is cleared sufficiently to allow a clamp to be placed later. In some cases, neither the right and left hepatic arteries nor the common hepatic artery is suitable for anastomosis, and further dissection to or beyond the takeoff of the gastroduodenal artery may be necessary.

The tissue posterior to the hepatic artery is then divided, exposing the anterior aspect of the portal vein, which is mobilized distally to its bifurcation and proximally to the head of the pancreas. The

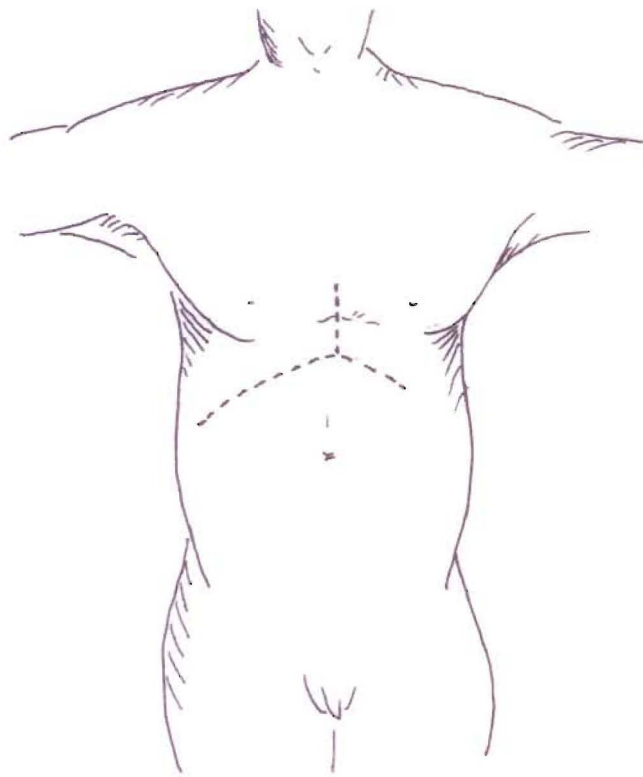


Fig. 8. Bilateral subcostal incision with a midline xiphoid extension in the recipient.

lymph node tissue inferolateral and posterior to the common duct is divided, and the posterior aspect of the portal vein is identified. An opening anterior to the portal vein and posterior to the common duct is then made, leaving intact as much of the surrounding tissue adjacent to the bile duct as possible to avoid devascularization of the bile duct. The common bile duct is ligated adjacent to the liver and divided.

The tissue overlying the anterior surface of the infrahepatic vena cava is then divided. Mobilization of the right lobe of the liver is performed by dividing the right triangular and coronary ligaments. At this stage, the procedure varies depending on whether a standard orthotopic transplant or piggyback transplant is to be performed. In a piggyback transplant, which is our preferred approach in almost all patients, the hepatic veins entering the posterior liver are isolated, ligated, or suture-ligated, and divided first along the left side and behind the caudate lobe. The liver is then retracted to the right, and the veins along the right side are also divided, with care being taken to identify, clamp, and suture-ligate large, right, accessory hepatic veins. The dissection proceeds until the liver has been separated up to the confluence of the hepatic veins where they enter the suprahepatic vena cava.

Using this technique, the inferior vena cava can be left in situ, reducing the blood loss, and the need for venovenous bypass to maintain venous return from the lower extremities can be eliminated. A vascular clamp is then placed around the confluence of the hepatic veins anterior to the inferior vena cava and the liver parenchyma adjacent to the clamp, divided, and the liver excised.

In a standard orthotopic liver transplant, the infrahepatic vena cava is isolated above the renal veins and looped with an umbilical tape. The tissue along the right side of the vena cava is then divided cephalad to the level of the suprahepatic vena cava. The right adrenal vein is doubly ligated and divided along with any other lumbar branches. The tissue along the left side of the vena cava is also divided so that the entire vena cava is separated from the retroperitoneum. The liver is then ready for removal. In patients with severe portal hypertension, or when exposure of the vena cava is difficult, isolation of the entire length of the vena cava is not necessary and, in fact, should be avoided to prevent hemorrhage from the retroperitoneum. The infrahepatic and suprahepatic vena cavae simply can be isolated enough to allow clamping, and the back wall of the vena cava can be left in place when the liver is excised.

To remove the liver once the patient is on venovenous bypass support, the infrahepatic vena cava and suprahepatic vena cava are clamped and the liver is removed. If the retrohepatic vena cava has not been isolated, the vena cava is incised anteriorly, leaving the posterior wall of the vena cava intact. Suture ligation of back-bleeding lumbar veins and the right adrenal vein is then accomplished.

VENOVENOUS BYPASS

The primary advantage of venovenous bypass is the maintenance of venous return and splanchnic venous drainage during the anhepatic phase, with improved hemodynamic stability and a reduction in mesenteric edema. Other benefits include improved renal perfusion as a consequence of lowered renal venous hypertension and the provision of additional time to obtain hemostasis in the retroperitoneum for placement of vascular grafts, when necessary, and for performance of the vascular anastomoses. Venovenous bypass can be performed by the percutaneous placement of heparin-bonded cannulae into the subclavian and femoral veins. The portal vein is cannulated with a Gott shunt and the portal, femoral, and subclavian lines are connected to the Bio-Medicus pump (Fig. 9).

DECEASED DONOR LIVER TRANSPLANT

Orthotopic Technique

The suprahepatic vena caval anastomosis is performed first as an end-to-end anastomosis (Fig. 10). The donor infrahepatic vena caval anastomosis is then performed while infusing 1 L of cold lactated Ringer's solution through the portal vein cannula. This clears the liver of UW solution, which is high in potassium and contains heparin. It also flushes air from the liver and reduces the risk of air emboli. The portal vein venovenous bypass cannula is clamped and removed from the recipient portal vein, which is clamped. The portal vein anastomosis is completed end-to-end with a loosely tied corner ("growth stitch") to allow expansion of the portal vein after unclamping. If the portal vein is thrombosed, a long donor iliac vein graft can be sewn end-to-side to the superior mesenteric vein, which is isolated in the mesentery of the transverse colon. Two sutures are placed in the corners of the free end of the donor vein to maintain its orientation as it is tunneled retrocolic, posterior to the antrum

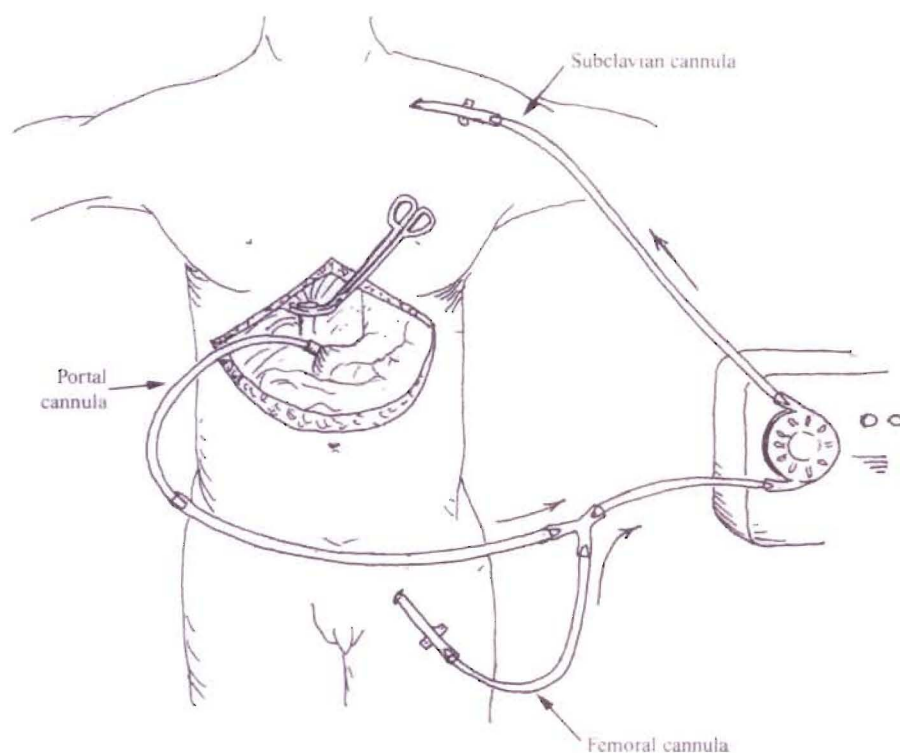


Fig. 9. Venovenous bypass.

and anterior to the pancreas, for anastomosis to the portal vein (Fig. 11). After completion of the vascular anastomoses, the clamps are removed sequentially. First, the portal vein clamp is removed and the liver perfused, followed by the suprahepatic vena cava clamp, and inferior vena cava clamp. Hemostasis is obtained and the patient is taken off venovenous bypass.

There are several techniques for performing the arterial anastomosis, depending on the size of the vessels and the arterial anatomy. It can be performed as an end-to-end anastomosis between the recipient proper hepatic artery and the donor common hepatic artery. Alternatively, the recipient right and left hepatic artery branches are opened longitudinally using Potts-Smith scissors to create a branch patch. An end-to-end anastomosis of the branch patch to the donor celiac axis with a Carrel patch is completed (Fig. 12). The donor common hepatic artery can also be sewn end-to-side to the junction of the common hepatic artery and the gastroduodenal artery. When there is a replaced right hepatic artery from the superior mesenteric artery, a cuff of superior mesenteric artery can be sewn end-to-end to the stump of the splenic artery or, if the replaced right hepatic artery has been divided, it is sewn directly to the splenic artery stump. Alternatively, if a cuff of aorta with the orifices of

the celiac axis and superior mesenteric artery is preserved, the aortic patch can be folded, the edges can be sewn together, and the distal superior mesenteric artery can be used for anastomosis to the recipient hepatic artery. If there is inadequate inflow via the recipient hepatic artery or celiac axis, a donor iliac artery graft can be placed to the supraceliac or infrarenal aorta as an end-to-side anastomosis.

The bile duct is usually reconstructed as an end-to-end choledochostomy using interrupted 5-0 monofilament absorbable sutures. Two sutures between the donor and recipient bile ducts are initially placed, one in the center of the posterior duct and one opposite this anteriorly. The posterior suture is tied, and interrupted sutures are placed superiorly and then inferiorly, leaving the anterior half of the anastomosis open. If a T tube is to be used, a No. 8-French T tube can be brought out through a separate choledochotomy in the recipient common bile duct with one limb crossing the anastomosis. The choledochotomy is repaired around the T tube with interrupted 5-0 monofilament absorbable sutures. The anterior row of sutures is then completed. The T tube is injected with saline to identify and allow repair of any leaks. An intraoperative cholangiogram is obtained. The bile duct anastomosis is then covered with

saline and air is injected into the T tube to further identify any leaks.

If the recipient bile duct is not usable secondary to disease (e.g., sclerosing cholangitis and large periductal varices) or a marked size discrepancy with the donor duct, an end-to-side Roux-en-Y choledochojejunostomy should be performed. A 60-cm Roux-en-Y loop is created. The jejunum is divided using a GIA stapler, and the end is oversewn with 4-0 interrupted silk sutures. Intestinal continuity is re-established with a two-layer end-to-side jejunojejunostomy 60 cm from the end of the Roux-en-Y loop. The inner layer is completed using a running 3-0 monofilament absorbable suture with a Connell stitch anteriorly. The outer layer is completed using 4-0 silk interrupted sutures. The Roux-en-Y loop is brought retrocolic. An end-to-side choledochojejunostomy is performed in a single layer using interrupted 5-0 Maxon sutures over a No. 5 French feeding tube as a biliary stent. Two enterotomies are made near the end of the Roux-en-Y loop, and a No. 5 French feeding tube is passed and secured to the bowel with a 5-0 Maxon purse-string suture. Interrupted 4-0 silk sutures are placed to create a tunnel for the feeding tube to prevent any leakage of intestinal contents. Two corner sutures of 5-0 Maxon are placed between the common bile duct and the bowel, and they are left untied. A posterior row of stitches is then placed inside-out on the bowel and outside-in on the common bile duct, with the knots tied on the inside for simplicity. The knots can be also tied on the outside by placing the sutures outside-in on both the bile duct and bowel using double-armed sutures, but it is unnecessary. The anterior row of sutures is then placed outside-in on the bowel and inside-out on the bile duct, with the knots tied on the outside. The anastomosis is checked as noted previously, and an intraoperative cholangiogram is obtained.

After hemostasis has been obtained, all anastomoses are again examined and the abdomen is irrigated with antibiotic-containing saline solution. Two Jackson-Pratt drains are placed, one subphrenically and posterolateral to the right lobe of the liver with the end adjacent to the suprahepatic vena cava, and one subhepatically posterior to the porta hepatis and anterior to the infrahepatic vena cava. The drains and T tube or biliary stent are brought out through separate stab incisions in the abdominal wall and secured to the skin with 3-0 nylon horizontal mattress sutures. The abdominal incision is closed.

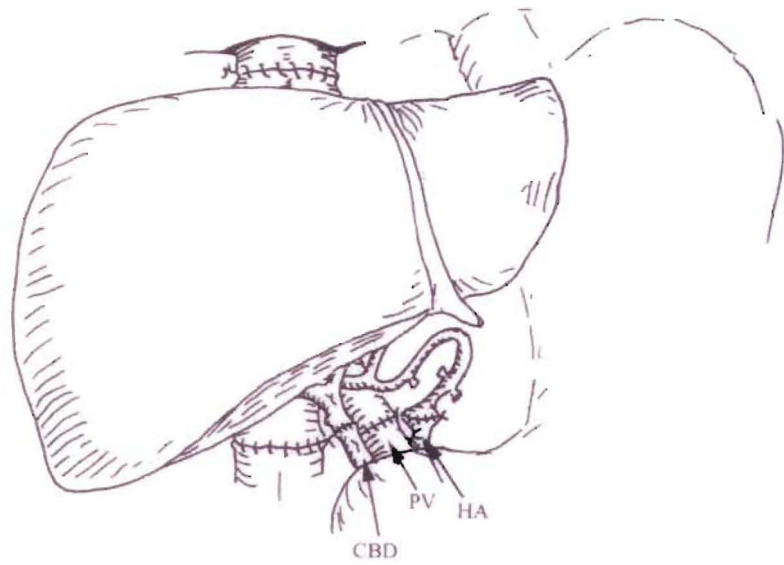
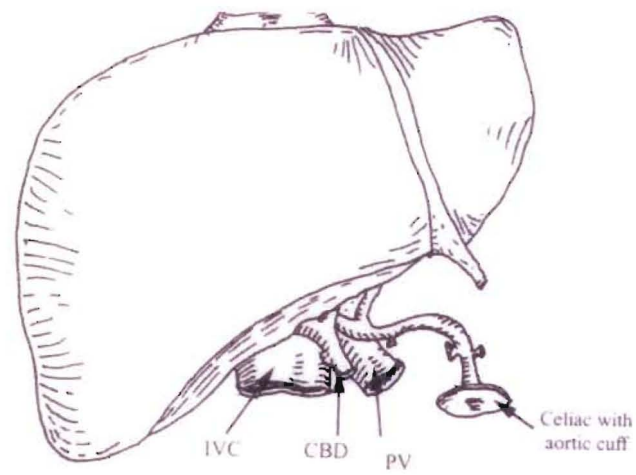


Fig. 10. Orthotopic deceased donor liver transplant. Suprahepatic and infrahepatic cavae (IVC) are separately anastomosed. Corresponding donor and recipient hepatic arteries (HA), portal vein (PV), and bile ducts are anastomosed end-to-end. CBD, common bile duct.

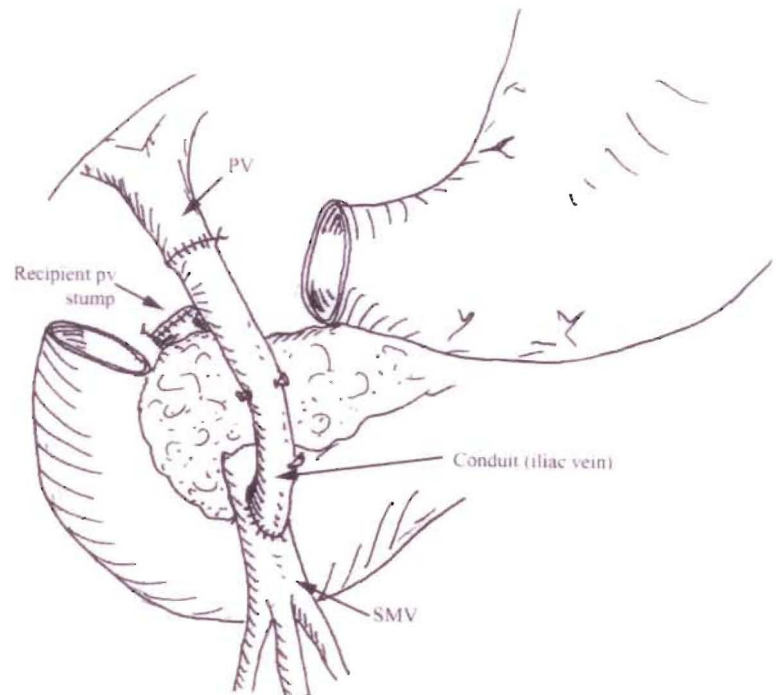


Fig. 11. Donor iliac vein graft from the recipient superior mesenteric vein (SMV) to the donor portal vein (PV).

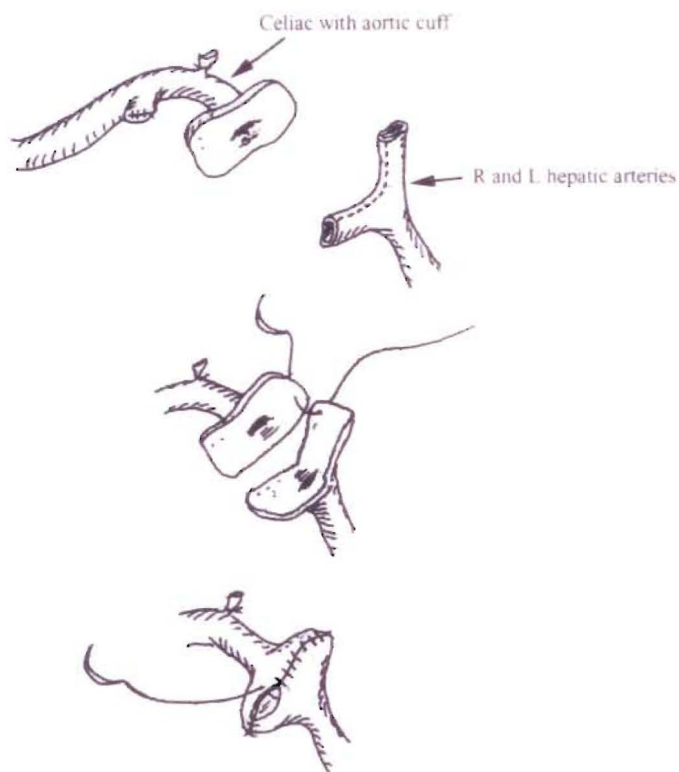


Fig. 12. Branch-patch technique for hepatic arterial anastomosis. The donor hepatic artery is procured with the celiac trunk and a surrounding aortic cuff. The recipient right and left hepatic arteries are incised at the bifurcation to create the branch patch; this is anastomosed to the aortic cuff.

Piggyback Technique

An alternative method for liver transplantation is the piggyback technique. This technique involves leaving the recipient vena cava in situ and mobilizing the liver off the inferior vena cava by dividing all the hepatic veins entering the posterior aspect of the liver. Only the left, middle, and right hepatic veins are left in place. A clamp is placed across the hepatic veins, and the confluence of the veins is opened (Fig. 13). The donor infrahepatic vena cava is oversewn or stapled with a vascular stapler on the back table, eliminating one anastomosis, and the donor suprahepatic vena cava is sewn end-to-end to the confluence of the recipient hepatic veins (Fig. 14). Venovenous bypass is not required. In addition, there is significantly less blood loss as a result of avoiding dissection posterior to the vena cava, where bleeding from retroperitoneal collaterals can be encountered.

Split Liver Transplantation

The surgical techniques for split liver implantation are similar to those described for living donor transplants. Generally, left lateral segments are transplanted into

pediatric recipients (Fig. 15). The right lobe can be transplanted into an adult recipient via orthotopic (Fig. 16) or piggyback placement (Fig. 17). The left lobe can be transplanted into a small adults orthotopically (Fig. 18) or piggyback (Fig. 19), depending on how the split was performed. Donor iliac vessels are used as extension grafts if necessary. Recipient and graft survival rates are similar to those reported for whole-organ transplants, but biliary complications are in the 20% to 30% range.

LIVING DONOR TRANSPLANTS

Left Lateral Segment Grafts

The graft is procured and prepared as previously described (Fig. 6). The recipient hepatectomy is similar to that described for the piggyback technique, with preservation of the entire vena cava, and as much length as possible on the left portal vein and hepatic artery. The donor left hepatic vein is sewn to the confluence of the left and middle hepatic veins in the recipient (Fig. 15). Attention to graft orientation within the abdomen and construction of a widely patent venous outflow is important to avoid postoperative congestion. The donor hepatic artery is anastomosed to the

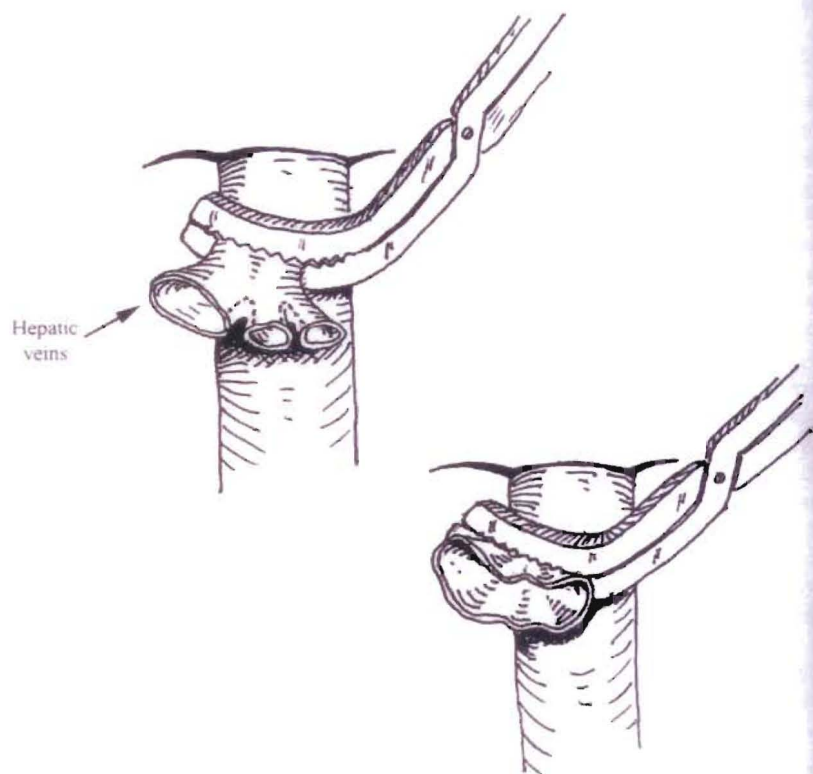


Fig. 13. Confluence of the main hepatic veins for piggyback liver transplantation.

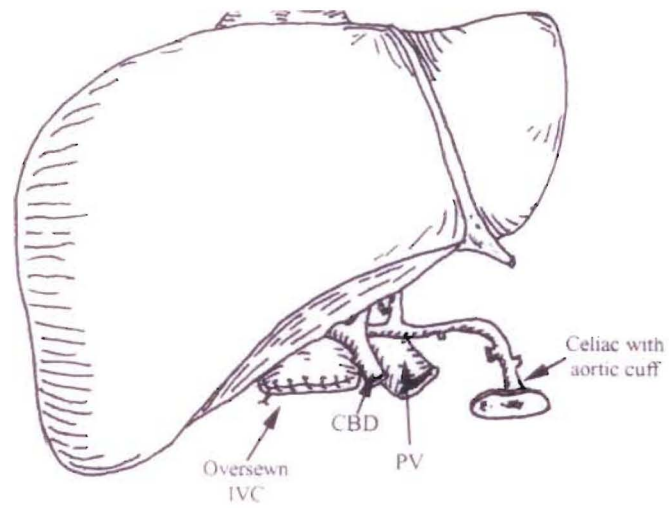


Fig. 14. Piggyback deceased donor liver transplant. The distal donor inferior vena cava (IVC) is oversewn, and the suprahepatic end is piggybacked onto the recipient IVC, usually at the orifices of the hepatic veins. Donor and recipient hepatic arteries (HA), portal veins (PV) and bile ducts are anastomosed end-to-end. CBD, common bile duct.

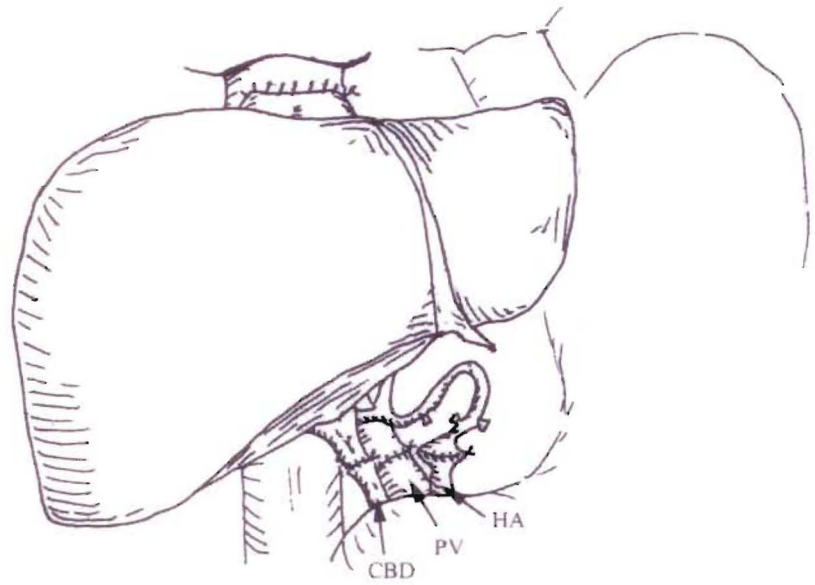
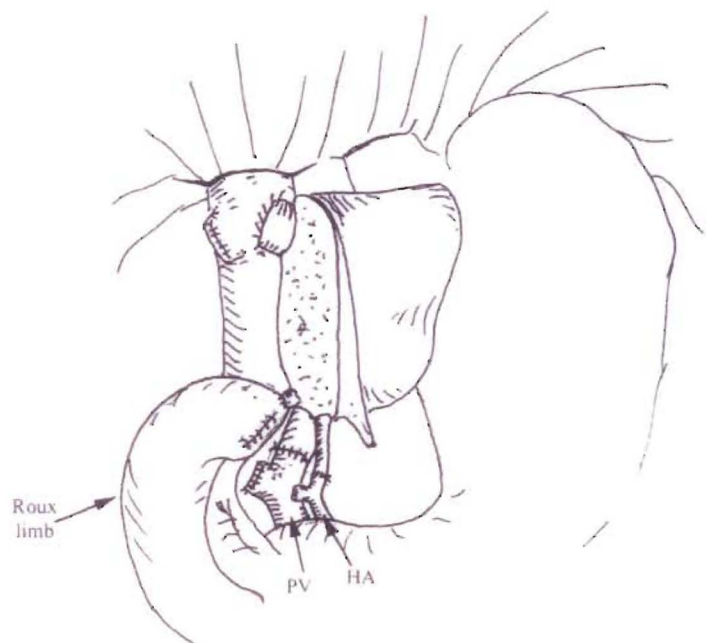


Fig. 15. Living donor left lateral segment transplant. The bile duct is anastomosed to a Roux-en-Y limb over a stent. Extension grafts may be used for vascular reconstruction. HA, hepatic artery; PV, portal vein.



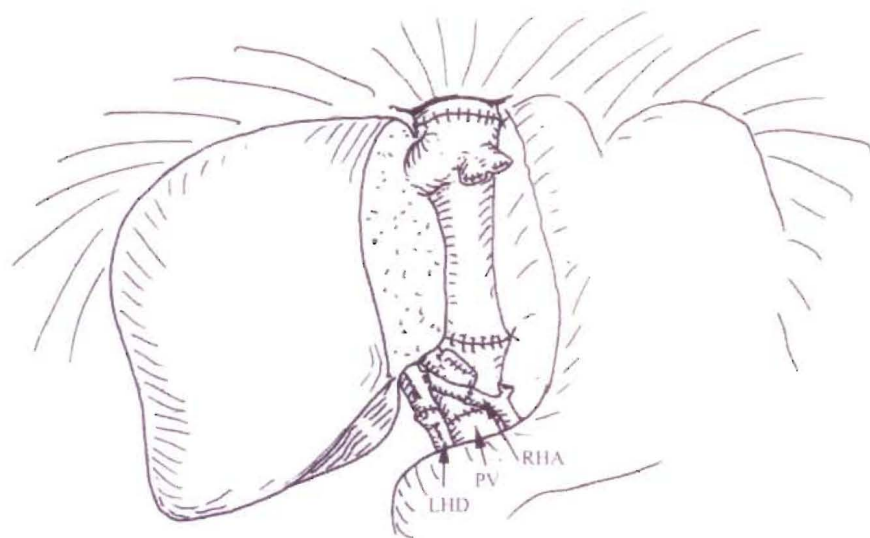


Fig. 16. Right lobe recipient operation. The cava can be sewn orthotopically. LHD, left hepatic duct; RHA, right hepatic artery; PV, portal vein.

recipient hepatic artery if length allows. A saphenous vein graft may be used to anastomose the hepatic artery directly to the aorta, and the use of a surgical microscope has led to a significant reduction in arterial complications. Not all arterial branches need to be revascularized so long as pulsatile back-bleeding is noted following anastomosis of the largest trunk. The graft portal vein can generally be sewn to the recipient left (or main) portal vein. Roux-en-Y biliary reconstruction is performed in some cases to separate segment 2 and 3 ducts.

Right Lobe Grafts

The recipient hepatectomy is performed in a similar manner. The right and left hepatic ducts are individually ligated beyond the common duct bifurcation. As much length as possible is maintained on the right hepatic artery. The right lobe graft is procured and prepared as previously described (Fig. 7). The donor right hepatic vein is anastomosed to the orifice of the recipient right hepatic vein (Fig. 17). Accessory hepatic veins draining segments V or VIII that are larger than 5 mm should

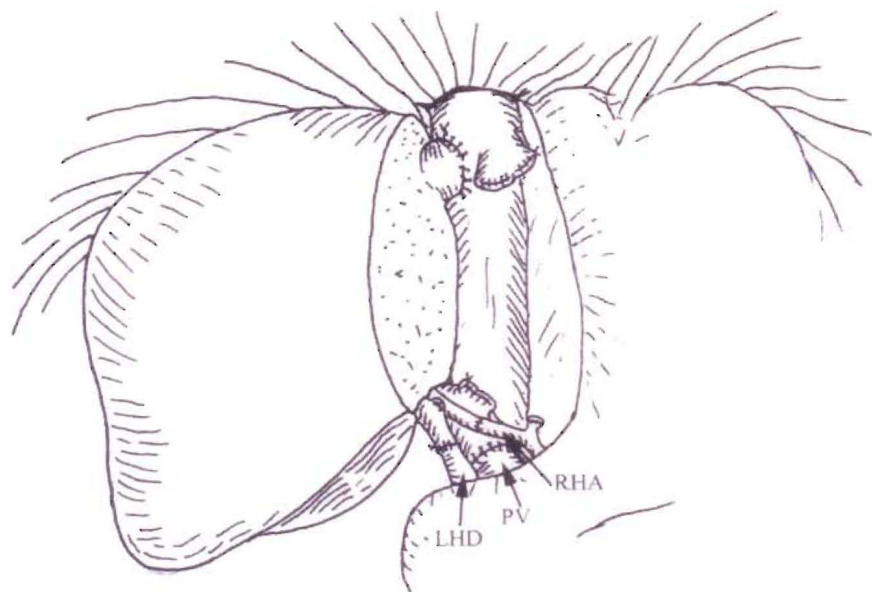


Fig. 17. Right lobe recipient operation (piggyback). The donor right hepatic vein is anastomosed to the widened orifice of the recipient right hepatic vein. LHD, left hepatic duct; RHA, right hepatic artery; PV, portal vein.

be reimplanted, either directly into the cava or through saphenous vein grafts. The donor portal vein is sewn to the recipient right (or main) portal vein. The donor and recipient right hepatic arteries undergo end-to-end anastomosis.

Several innovative variations in arterial reconstruction have been described, including Y grafts from the recipient hepatic artery bifurcation, if there are two donor arteries (ex situ reconstruction). Biliary reconstruction can be performed as an end-to-end anastomosis. Often, two separate anastomoses to anterior and posterior sectoral ducts have to be performed and in this situation, the donor right and left ducts may be used separately. Alternatively, Roux-en-Y biliary reconstruction may be employed.

INFECTION PROPHYLAXIS

A variety of infectious complications occurs after liver transplantation. Many of these infectious complications can be prevented or their severity reduced by appropriate prophylaxis. At the time a liver transplant candidate is listed for transplantation, he or she is prescribed Mycelex Troche (clotrimazole) three times per day to reduce fungal colonization in the gastrointestinal tract. After liver transplantation, our anti-infective prophylactic regimen includes (a) ampicillin/sulbactam, 3.0 g preoperatively and 1.5 g intravenously every 6 hours for 5 days postoperatively; (b) ganciclovir, 5 mg/kg intravenously twice a day for 14 days, followed by valganciclovir 900 mg/d for 3 months; (c) fluconazole, 400 mg by mouth once a day for 3 months; and (d) Bactrim SS, one tablet by mouth every day indefinitely.

IMMUNOSUPPRESSIVE PROTOCOL AND RESULTS

Our current induction immunosuppressive protocol includes the intraoperative use of mycophenolate mofetil (Cellcept), 500 mg intravenously, and methylprednisolone, 1 g intravenously. Postoperatively, patients receive mycophenolate mofetil (2 g/d), Solu-Medrol intravenously, changed to prednisone that is tapered to 0.3 mg/kg by 1 month posttransplant and discontinued by 3 months. On the first postoperative day, tacrolimus (0.07 mg/kg/d in two divided doses by mouth) is started, and the dosage is adjusted to maintain level of 8 to 10 ng/dL for the first 3 months posttransplant. Patients with acute renal failure or hepatorenal

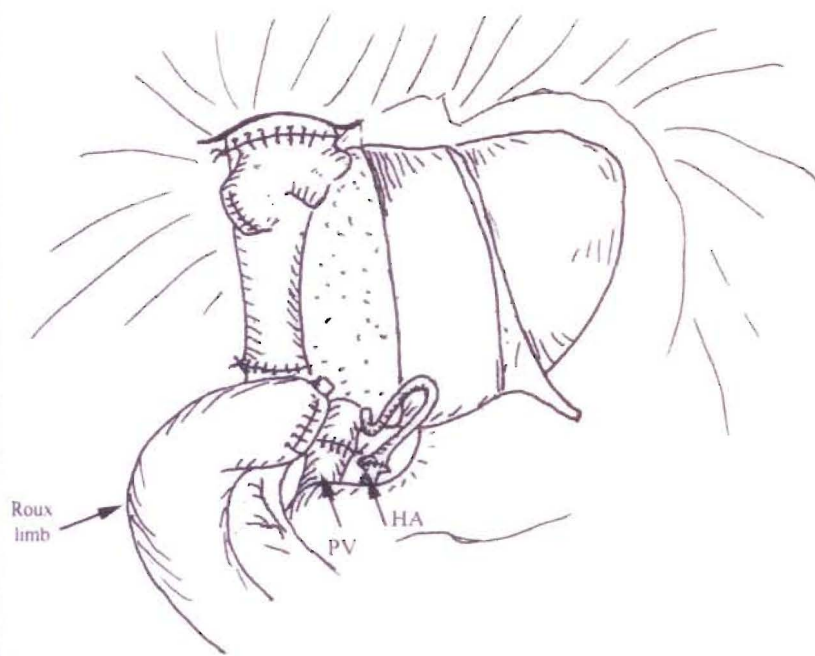


Fig. 18. Left lobe recipient operation. The cava can be sewn orthotopically. The left hepatic duct is anastomosed to a Roux-en-Y limb over a stent (depicted) or may be directly anastomosed to the recipient duct. PV, portal vein; HA, hepatic artery.

syndrome preoperatively may receive Thymoglobulin, a polyclonal antibody, or OKT3, an anti-CD3 monoclonal antibody, until renal function improves before starting tacrolimus. Alternatively, ra-

pamycin can be used, although it has been associated with an increased incidence of wound complications.

The incidence of rejection is approximately 36%. The incidence of second and

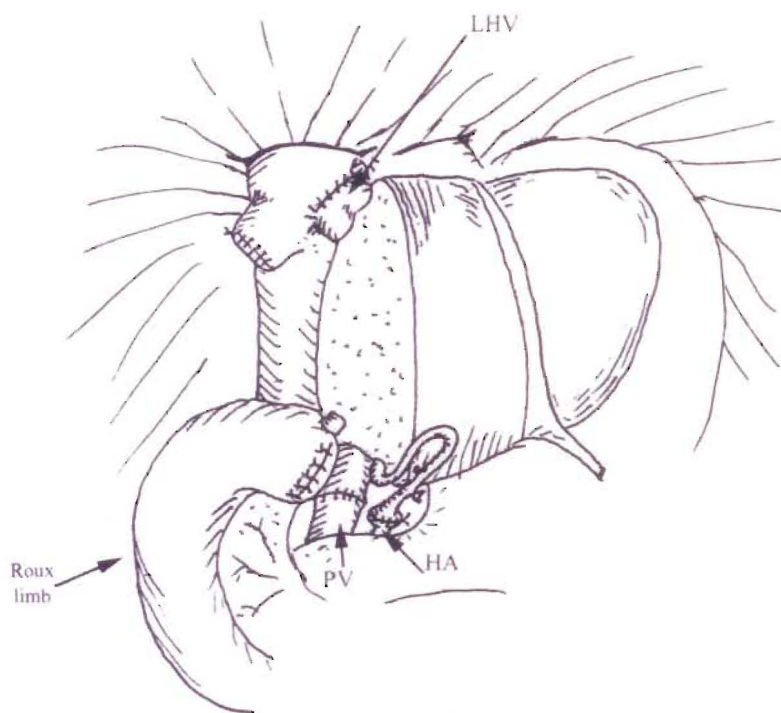


Fig. 19. Left lobe recipient operation. The donor left hepatic vein (LHV) is anastomosed to the widened orifice of the recipient LHV. The left hepatic duct is anastomosed to a Roux-en-Y limb over a stent (depicted) or may be directly anastomosed to the recipient duct. PV, portal vein; HA, hepatic artery.

third rejection episodes is 15% and 11%, respectively. Approximately 81% of rejection episodes respond to antirejection therapy with steroids.

OUTCOMES

Liver transplantation has made significant progress in the last decade. This progress has come from the development of new immunosuppressive agents, improved surgical techniques, improved patient selection, and the recent implementation of an allocation system based on the severity of disease. Data from the The U.S. Organ Procurement and Transplantation Network and the Scientific Registry of Transplant Recipients demonstrate that, for deceased donor liver transplant recipients, overall patient survival rates at 3 months, 1 year, and 3 years are 92%, 87%, and 79%, respectively. Corresponding overall graft survival rates for the same periods are 88%, 81%, and 72%. Overall patient survival for living donor recipients at 3 months, 1 year, and 3 years are 92%, 87%, and 79%, respectively, with graft survival rates for the same time periods of 86%, 80%, and 70%.

Severity of illness at the time of transplant continues to play an important role in determining outcomes. Several notable factors have been found to have a negative impact on patient survival, including hospitalization at the time of transplant (83% 1-year survival) and being an intensive care unit patient at the time of transplant (79% 1-year survival). A MELD score more than 30 at the time of transplant was associated with 86% and 76% patient survival at 3 months and 1 year, respectively, as compared with 89% patient survival at 1 year for patients with a MELD score of 11 to 30.

Cause of disease also plays a significant role in patient outcomes. Best results are seen in patients with metabolic liver disease (91% 1-year survival) and cholestatic liver disease (90% 1-year survival). Patients with fulminant hepatic disease fared worse, with a 1-year survival of 81%. Hepatitis C deserves additional attention because it remains the most prevalent indication for liver transplantation. The universal recurrence of hepatitis C after transplant and its potential to cause cirrhosis in up to 30% of recipients at 5 years begs for improved medical management of pretransplant and posttransplant disease, as well as improved patient and donor selection, to optimize outcomes for this difficult group.

ACKNOWLEDGEMENTS

The authors would like to thank Khalid Khwaja, MD who drew on the figures.

SUGGESTED READING

Abt PL, Desai NM, Crawford MD, et al. Survival following liver transplantation from non-heart beating donors. *Ann Surg* 2004; 239:87.

Busque S, Esquivel CO, Concepcion W, et al. Experience with the piggyback technique without caval occlusion in adult orthotopic cadaver liver transplantation. *Transplantation* 1998;65:66-77.

Busuttil RW, Goss JA. Split liver transplantation. *Ann Surg* 1997;229:313.

Busuttil RW, Klintmalm GK. *Transplantation of the liver*. Philadelphia: Elsevier Saunders, 2005.

Couinaud C. 1957 *Le Foi. Etudes anatomiques et chirurgicales*. Masson, Paris.

Hanto DW, Fishbein TM, Pinson et al. Liver and intestine transplantation: summary analysis, 1994-2003. *Am J Transplantat* 2005;5:916.

Humar A, Khwaja K, Sielaff TD, et al. Split-liver transplants for two adult recipients: technique of preservation of the vena cava with the right lobe graft. *Liver Transpl* 2004;10:153.

Johnson SR, Pavlakis M, Khwaja K, et al. Intensive care unit extubation does not preclude extrarenal organ recovery from donors after cardiac death. *Transplantation* 2005;80:1244.

Kamath PS, Wiesner RH, Malinchoc M, et al. A model to predict survival in patients with end-stage liver disease. *Hepatology* 2001; 33:464.

Lo CM, Fan ST, Liu CI, et al. Lessons learned from one hundred right lobe living donor liver transplants. *Ann Surg* 2004;240:151.

Mazzaferro V, Regalia E, Doci R, et al. Liver transplantation for the treatment of small hepatocellular carcinomas in patients with cirrhosis. *N Engl J Med* 1996;334:693.

Merion RM, Schaubel DE, Dykstra DM, et al. The survival benefit of liver transplantation. *Am J Transplant* 2005;5:307.

Wachs M, Bak TE, Karrer FM, et al. Adult living donor liver transplantation using a right hepatic lobe. *Transplantation* 1998;66: 1313.

Yao FY, Ferrel L, Bass NM, et al. Liver transplantation for hepatocellular carcinoma: expansion of the tumor size limits does not adversely impact survival. *Hepatology* 2001;33: 1394.

EDITOR'S COMMENT

Mechanism-Based Immunosuppression

Despite a reasonable rate of 1-, 3-, and 5-year survival after liver transplantation, a steady mortality rate during the first 5 years and beyond is exemplified by the statistics cited in this fine chapter. The delayed losses have been largely the result of the ravages of long-term immunosuppression. Specific principles of immunotherapy will have to be applied if improvement in late survival is to be achieved. These principles derive from two features of the alloimmune response that were exposed in 1962-1963 with kidney transplantation and have since been demonstrated with all other kinds of organ grafts, and under all regimens of immunosuppression. In the pioneer patients of 1962-1963, renal rejections that developed under azathioprine were easily reversed with the addition of large doses of prednisone. More importantly, successful rejection reversal frequently was succeeded by a greatly reduced requirement for maintenance immunosuppression. Histocompatibility matching was not a prerequisite for success. There was little threat of graft-versus-host disease, and perpetuation of organ graft survival almost always depended on lifetime drug treatment. Because of these striking differences from bone marrow transplantation (Table 1), organ engraftment was considered for many years to involve fundamentally different immunologic mechanisms. This misconception was challenged in 1992 by our discovery of small numbers of multilineage donor hematolymphopoietic cells (microchimerism) in long-surviving human liver and kidney recipients.

Organ engraftment then could be defined as a variable form of tolerance that resulted from "... responses of coexisting donor and recipient immune cells, each to the other, causing reciprocal clonal expansion followed by peripheral clonal deletion" (Fig. 1A). The graft-versus-host arm of the double immune reaction usually was clinically inapparent. The prerequisite for the variable organ-induced donor-specific tolerance was migration of the graft's passenger leukocytes to host lymphoid organs and induction there of the host-versus-graft response. Exhaustion and deletion of this response explained the characteristic rejection reversal and subsequent decline in need for immunosuppression in organ recipients.

COMMENTARY TABLE 1. DIFFERENCES BETWEEN CLINICAL ORGAN TRANSPLANTATION AND BONE MARROW TRANSPLANTATION (HISTORICAL VIEW)

Feature	Organ Transplantation	Bone Marrow Transplantation
Host cytoablation	No	Yes ^a
HLA matching	Not essential	Critical
Principal complication/disease	Rejection	Graft-versus-host disease
Immunosuppression-free	Uncommon	Common
Term for success	Acceptance	Tolerance
Leukocyte chimerism	No	Yes

^aIn hindsight, this therapeutic step allows a relatively unopposed graft-versus-host reaction and accounts for the other differences.

Cytoablation of bone marrow, but not of organ recipients, was the apparent reason for essentially all of the differences between the two kinds of transplantation. This unified view of transplantation was initially controversial, in part because it was incompatible with dogmas that made up much of the foundation of transplantation immunology. However, the paradigm was upheld in principle when Zinkernagel (Nobel Laureate 1996) formally proved in mouse infection models that the antigen-specific T-cell response against noncytotoxic micro-organs could be exhausted and deleted, and concluded that this was the explanation for the carrier state that may develop after infection with intracellular viruses (e.g., hepatitis viruses, cytomegalovirus, and Epstein-Barr virus). The clinical outcomes after an infection were determined by the balance between the amount of viral antigen and the number of induced virus-specific cytolytic T lymphocytes.

In this context, the objective of transplant immunosuppression is not merely to prevent rejection, but also to aid in the establishment of a beneficial balance between mobile donor antigen (the passenger leukocytes) and the donor specific T-cell response. The best chance to establish a balance favoring stable deletional tolerance is during the first few posttransplant weeks, during which the maximal

donor leukocyte migration provides the optimal conditions for reciprocal exhaustion-deletion of the double immune response (Fig. 1A). It was obvious that this one-time-only window of opportunity could be narrowed and closed by so much pre-emptive immunosuppression that clonal activation is subverted (Fig. 1B). To the extent that this would occur, later reduction of the primary overtreatment predictably would lead to recovery of the ineffectively deleted clone with the clinical consequence of delayed rejection (Fig. 1B).

Yet, the penalty of too little immunosuppression during the critical early period may be irreversible rejection. In 2001, we suggested that this dilemma could be addressed by application of one or both of the two therapeutic principles depicted in Figure 1C. The first principle is to administer no more posttransplant immunosuppression than would be needed to prevent irreversible immune-mediated damage. Because of histocompatibility and other confounding parameters in the human population, simple monotherapeutic immunosuppression (Fig. 1A) cannot be safely used. The second principle (recipient pretreatment) consists of reducing host immune responsiveness by nonmyeloablative conditioning before arrival of donor antigen, thereby bringing the anticipated antidonor

(continued)

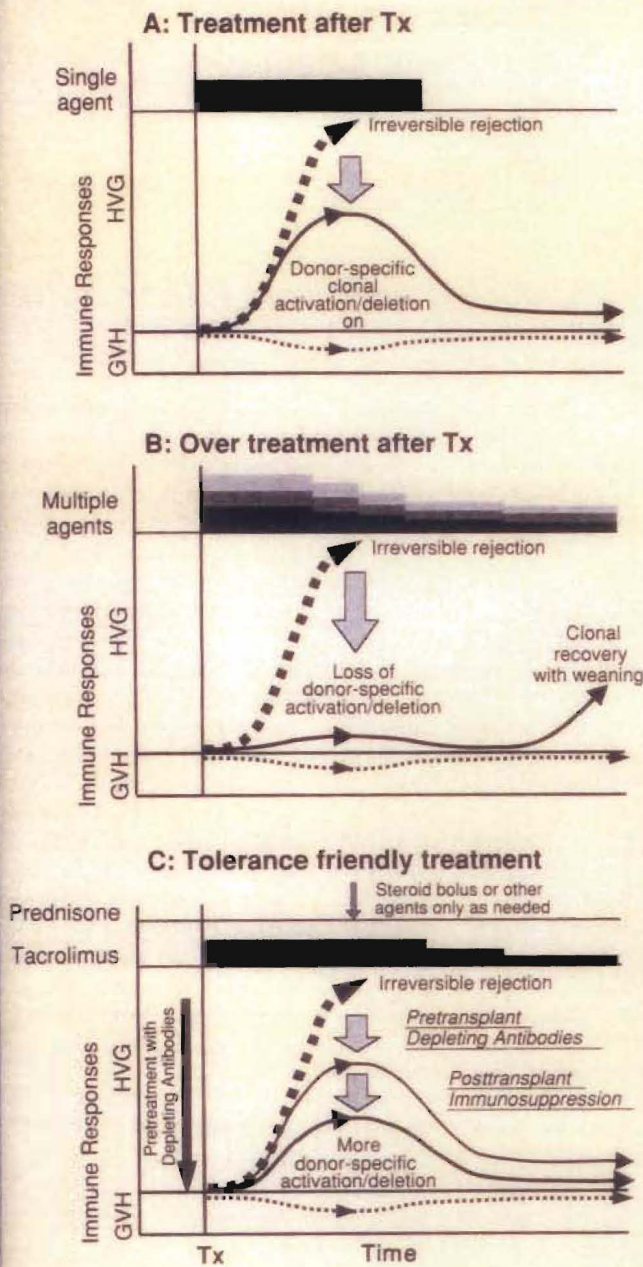


Fig. 1. Organ-induced tolerance. The upright curves depict the host versus graft (HVG) response. The inverted curves depict the usually silent graft-versus-host (GVH) reaction. **A:** Immunosuppression-aided tolerance in organ transplant models in which the recipient response that normally would cause rejection (dashed line) is reduced into a deletable range (continuous thin line) with a short course of early posttransplant immunosuppression. Lifetime tolerance may be present after stopping immunosuppression. This was the first convincingly demonstrated in canine liver recipients. **B:** A self-defeating consequence of excessive prophylactic overimmunosuppression with which clonal exhaustion-deletion is impaired. This antitolerogenic effect of overtreatment was not recognized until 2001. The initially overtreated recipient may be committed to unnecessarily high-maintenance immunosuppression. Multiple agents are depicted as layered bars. **C:** Protocol of "tolerance friendly" immunosuppression introduced at the University of Pittsburgh Medical Center. An antilymphoid antibody infusion prior to arrival of an allograft reduces the anticipated antidonor response into a more readily deletable range and allows maintenance treatment to begin with daily monotherapy, to which other agents are added only for rejection. Variable weaning from the monotherapy may be possible later. Tx, transplantation.

immune response into a more easily controllable and deletable range and making monotherapeutic immunosuppression (e.g., with tacrolimus) routinely feasible. The two principles have been combined at our center, using a single large dose of an antilymphoid antibody before transplantation (Thymoglobulin or Campath), followed by minimalist posttransplant tacrolimus monotherapy with the intent of eventual weaning.

Using the strategy, satisfactory results in organ recipients with reduced overall exposure to immunosuppression have been obtained, with the striking exception of liver recipients whose chronic end-stage hepatic failure was caused by hepatitis C virus (HCV). Because the mechanisms of immunologic responsiveness or nonresponsiveness to allografts and to HCV are the same, it is not difficult to understand why liver transplant im-

munosuppression in the HCV-infected patient has been fraught with difficulty. Suffice it to say, elucidation of the effects of immunosuppression on these mechanisms has made it possible to formulate therapeutic protocols that reduce HCV disease recurrence. This has been particularly important because HCV-associated hepatic disease accounts for almost half of the liver transplantations currently being done in the United States.

The implications of the coherent view of immune function and governance that have emerged from studies in transplantation and infection are too vast to describe here. Those interested in the development and details of the "new immunology" are urged to consult the articles for Suggested Reading that follow this commentary (particularly the liver-specific references).

T.E.S. and N.M.

COMMENTARY SUGGESTED READING

- Eghtesad B, Fung JJ, Demetris AJ, et al. Mechanism-based principles of immunosuppression for liver transplantation in HCV-infected patients. *Liver Transplant* 2005;11:1343.
- Starzl TE, Zinkernagel R. Antigen localization and migration in immunity and tolerance. *N Engl J Med* 1998;339:1905.
- Starzl TE, Zinkernagel R. Transplantation tolerance from a historical perspective. *Nat Rev Immunol* 2001;1:233.
- Starzl TE, Lakkis FG. The unfinished legacy of liver transplantation: emphasis on immunology. *Hepatology* 2006;43(suppl 1):S1.

Chapter

106A

Special Comment: The Unfinished Legacy of Liver Transplantation

THOMAS E. STARZL AND FADI G. LAKKIS

Legacy: Something immaterial, as a style or philosophy, that is passed from one generation to another. Anything handed down from, or as from, an ancestor.

During the past quarter century, the philosophy and practice of hepatology were dramatically transformed by the wide acceptance of orthotopic liver transplantation. Numerous milestones in the development and use of this procedure had been reached between 1955 and 1980 (Table 1). The prodigious task that lay ahead 25 years ago was diffusion of the complex new multidisciplinary enterprise into the national and international health care systems (Table 1). The extent to which this was accomplished is evident in the 2004 Action Plan for Liver Disease Research designed to "...coordinate research efforts [to treat hepatic and biliary disease] across the NIH."

RESEARCH AND DEVELOPMENT OPPORTUNITIES

The National Institutes of Health (NIH) plan was divided into 16 chapters, one of which was devoted exclusively to liver transplantation, with primary emphasis on clinical research. The liver transplant chapter began with the simple declarative sentence, "Liver transplantation is now the standard of care for patients with end stage liver disease or acute liver failure." It was a proud statement from the government agency whose unfailing support had made this possible. But, had liver transplantation matured so completely that there is nothing left to do but fine tuning? This view is negated by links to liver transplantation in almost all of the 15 other chapters of the NIH prospectus. Most of these links were to targets of research opportunity that already had been enriched by, or even owed their provenance to, liver transplantation.

For example, techniques of liver procurement, preservation, and replacement are currently being adapted in nontransplant circumstances (e.g., for subtotal hepatic resections). The discovery that portal venous blood contains substances important for maintenance of liver size, function, and the capacity for regeneration was the beginning of the still-evolving special field of hepa-

trophic physiology that is concerned with the functional and hormonal interrelationships of the different splanchnic organs. The hepatotropic studies ultimately led to the cure or palliation with liver replacement of numerous hepatic-based inborn errors of metabolism, providing the first examples of what might be accomplished in the future with gene therapy and the application of stem cell biology. Finally, religious beliefs, concerns about medical ethics, and public policy or legal issues that surfaced 4 decades ago with the first attempts of liver transplantation remain as unresolved agenda items in the NIH master plan of 2004.

However, the most frequently identified potential research initiatives in the NIH strategic plan of 2004 concerned the immune response and/or the manifold consequences of modifying it, not just for transplantation but also in the context of hepatitis, human immunodeficiency virus (HIV), and oncology (to which separate chapters of the plan were devoted). Using today's sophisticated tools (particularly those of molecular biology), it now may be possible to expand the sphere of immunology in new directions, fill in knowledge gaps, explain long-standing enigmas, and contribute ultimately to better patient care. With this in mind, the following discussion will consider specific issues of immunology that are central to the further development of liver transplantation and to improvement of treatment under multiple nontransplant circumstances.

THE RELATION OF ALLOENGRAFTMENT TO ACQUIRED IMMUNE TOLERANCE

The Historical View

Bone Marrow Transplantation

Transplantation immunology was brought to its present state by a series of events that began in 1943–1944 with Medawar's demonstration that rejection is an immune response. A year later, Owen discovered

mixed blood cell chimerism in freemartin cattle whose fused placentas had permitted fetal cross-circulation; such animals were subsequently shown to be mutually tolerant. Then, in 1953–1955, the strong association of donor leukocyte chimerism and acquired donor-specific tolerance was demonstrated in experiments in which allogeneic spleen and bone marrow cells were transplanted without immunosuppression into immunologically immature mice and into irradiated adult mouse recipients. After hematopoietic cell engraftment, the recipients could accept all other donor tissues and organs. The mouse tolerance models escalated during the ensuing 15 years to clinical bone marrow transplantation in immunodeficient and irradiated patients. However, success depended on the use of HLA-matched donors. Otherwise, the penalty for engraftment was lethal graft-versus-host disease (GVHD); that is, rejection of the host by the graft.

Organ Transplantation

In contrast to the "bench to bedside" chronology of bone marrow transplantation, organ transplantation (initially of the kidney) was accomplished in humans before proof of feasibility was demonstrated in an animal model and in the apparent absence of leukocyte chimerism. The first six kidney recipients with prolonged graft survival (1959–1962) were preconditioned with sublethal total-body irradiation, but were not infused with donor bone marrow cells. In 1960–1961, daily posttransplant azathioprine was shown to prolong kidney survival in dogs, and taken to clinical trials. Used alone or with other cytotoxic agents, azathioprine was only marginally effective. However, its combination with prednisone made renal transplantation a practical service by exposing two features of the alloimmune response that later were demonstrated with liver and all other kinds of organ transplantation and under all other regimens of immunosuppression.

TABLE 1. MILESTONES OF LIVER TRANSPLANTATION

Year	Description ^a
1955	First article in the literature on auxiliary liver transplantation
1956	Concept of liver replacement first mentioned
1958–1960	Results reported of canine total hepatectomy and liver replacement without immunosuppression
1960	Abdominal multivisceral transplantation described in nonimmunosuppressed dogs
1963	Azathioprine-prednisone cocktail introduced (kidneys first, then livers) and recognition of organ-induced tolerance
1963	Description of in situ preservation and procurement of cadaveric organs
1963	First attempts to transplant the human liver
1964–1965	Evidence reported of hepatotropic (liver-supporting) factor(s) in portal venous blood
1965	Liver-induced tolerance under a short course of azathioprine reported in dogs
1966	First liver xenotransplantation on July 15, 1966 (chimpanzee donor)
1966	Clinical introduction of ALG for kidney, then liver recipients
1966–1970	Evidence that HLA matching would not be a major factor in cadaveric organ transplantation
1967	First 1-year survivals after human liver replacements
1967–1968	Acceptance of brain death concept
1967–1969	Liver-induced tolerance in pigs without immunosuppression
1969	First textbook of liver transplantation based on 25 Denver cases
1969	First palliation (or cure) of inborn error of metabolism with liver transplantation
1973–1983	Evidence accrued that the liver controls cholesterol homeostasis
1973	Description of the liver's resistance to antibody-mediated rejection
1973–1975	Principal portal blood hepatotropic factor identified as insulin
1976	Causes of failure analyzed in first 93 Colorado cases of liver transplantation
1976	Improved slush liver preservation permitted long-distance procurement
1979	Systematic use of arterial and venous grafts for cadaveric liver revascularization
1979	Cyclosporine introduced for organ transplantation including two liver recipients
1980	Cyclosporine-steroid cocktail introduced clinically
1981	80% 1-year liver recipient survival reported using cyclosporine-prednisone
1982	Review of progress in liver transplantation generates widespread interest of hepatologists
1983	Introduction of pump-driven venovenous bypass without anticoagulation
1983–1995	USA consensus development conference conclusion that liver transplantation is a service (1983) is followed by rapid proliferation of transplant centers worldwide
1984	Standardization of in situ preservation-procurement techniques for cadaveric multiple organ donors
1984	Reversibility reported of B-cell malignancies (PTLD) in liver and other organ recipients
1984	Reports of reduced-size liver grafts for pediatric recipients
1984	Liver transplantation of patient with hypercholesterolemia verified hypothesis that the liver is the site of cholesterol homeostasis
1987–1989	First successful transplantation of liver-containing multivisceral grafts
1987	University of Wisconsin (UW) solution improves preservation of liver and other organs
1987	Successful extensive use of livers from "marginal" donors reported
1988	National adoption of Pittsburgh point system for cadaveric kidney and liver distribution complies with Organ Transplant Act of 1984
1989	Popularization of the "piggy back" variation of liver transplantation
1989	Clinical introduction of FK 506 (tacrolimus)-based immunosuppression
1989	First report of split cadaveric liver for transplantation into two recipients
1990	First use of live liver donors (left-side fragments)
1992–1993	Discovery of donor leukocyte microchimerism in liver (and other organ) recipients, placing organ and bone marrow cell transplantation on common ground
1998	Delineation of analogies between transplantation and infection immunology
1994–1999	Live donor transplantation of right-side liver fragments
2001	Mechanism-based tolerogenic immunosuppression proposed
2003	Double knockout of porcine $\alpha 1, 3GT$ gene, revitalizing hopes of clinical xenotransplantation
2003	Clinical use of tolerogenic immunosuppression
2005	Mechanisms of recurrent hepatitis under transplant immunosuppression elucidated

^aALG, antilymphocyte globulin; PTL, posttransplant lymphoproliferative disorders.

The first unexplained observation was that rejections that developed under azathioprine were easily reversed with the addition of large doses of prednisone rather than being inexorable, as previously thought. Secondly, a successful rejection reversal frequently was succeeded by a greatly reduced requirement for maintenance immunosuppression (Fig. 1), sug-

gesting that the graft was inherently tolerogenic. It also was learned that histocompatibility matching was not a prerequisite for success, that there was little threat of GVHD, and that perpetuation of organ graft survival almost always depended on lifetime drug treatment. In addition to these striking differences from bone marrow transplantation, none of the

organ recipients were thought to have donor leukocyte chimerism (Table 2).

Because of these striking disparities, organ engraftment and successful bone marrow transplantation were considered for many years to involve fundamentally different mechanisms. Experimental therapeutic strategies were empirically developed with the objective of endowing organ recipients

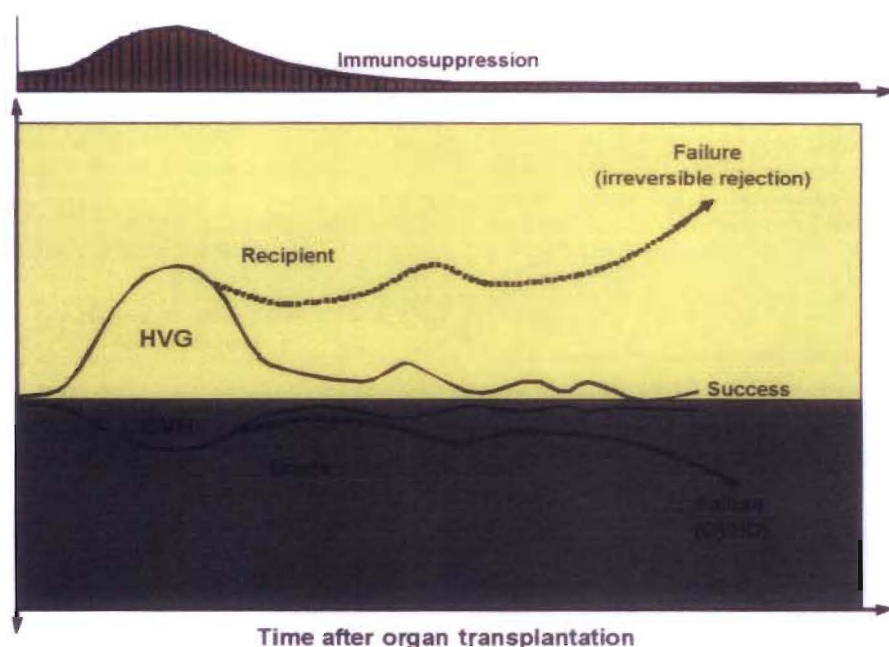


Fig. 1. Contemporaneous host-versus-graft (HVG) and graft-versus-host (GVH) immune responses after transplantation. The presence of the weaker GVH response in organ recipients (the inverted curves on a gray background) was not recognized until the discovery of microchimerism in 1992. However, the demonstration in 1962–1963 that the HVG response (rejection) is reversible and may be succeeded by a state of variable tolerance (yellow panel), allowed the practical development of immunosuppression-aided clinical organ transplantation. HGVD, graft-versus-host disease.

with the donor leukocyte chimerism-associated mechanisms of the bone marrow recipient while avoiding the penalty of GVHD. These strategies had in common the infusion of donor hematolymphopoietic cells into organ recipients that had been immunologically weakened by irradiation, antilymphoid antibody preparations, or other means (i.e., nonmyelotoxic cytoreduction). Although encouraging experimental results have been reported, such protocols have not found a significant niche in clinical organ transplantation practice because of their complexity, risks, and unpredictable consequences.

Nevertheless, this body of experimental work demonstrated that the establishment of a hematolymphopoietic population composed of donor and recipient cells was

possible in some models with a reasonably low risk of GVHD and could result in donor-specific tolerance, providing the donor cell contribution was at least 1% to 2% ("macrochimerism"). Levels below this ("microchimerism") were generally interpreted as either negative findings or artifacts. By so doing, the historical paradigm that attributed bone marrow and organ engraftment to different mechanisms required no substantive revision.

A Unification of Bone Marrow and Organ Transplantation

The historical paradigm was not challenged until 1992. When small numbers of multilineage donor hematolymphopoi-

etic cells (microchimerism) were found in animal and human recipients of long-surviving kidney and liver allografts, it was postulated that the mechanisms of organ engraftment differed only in degree from the leukocyte chimerism-dependent ones of successful bone marrow transplantation. Organ engraftment was now defined as a variable form of tolerance that resulted from "...responses of coexisting donor and recipient immune cells, each to the other, causing reciprocal clonal expansion followed by peripheral clonal deletion." The graft-versus-host arm of the double-immune reaction (the inverted curve in Fig. 1) usually was clinically inapparent.

The prerequisite for the donor-specific tolerance was migration of the graft's passenger leukocytes to host lymphoid organs and induction there of the host-versus-graft response. Because the multilineage passenger leukocytes of an organ are of bone marrow origin, their hematogenous migration into the recipient was, in essence, the equivalent of a bone marrow cell infusion. Exhaustion and deletion of the antidonor response explained the characteristic rejection reversal and subsequent decline in need for immunosuppression in organ recipients (Fig. 1). Cytoablation of bone marrow, but not of organ recipients, was the apparent reason for essentially all of the differences between the two kinds of transplantation, including the high risk to the bone marrow recipient of GVHD, and the need to restrict marrow donors to those with a histocompatibility match (Table 2). Importantly, essentially all cytoablated bone marrow recipients have a small residual population of their own hematolymphopoietic cells (i.e., mirror image microchimerism) rather than complete bone marrow replacement.

This unified view of transplantation was controversial, in part because it was incompatible with dogmas that made up much of the foundation of transplantation immunology. One point of contention was our view that historically rooted alternative engraftment mechanisms (listed in Table 3) were either epiphenomena or "variants or stages" of the clonal exhaustion-deletion that followed the key event of leukocyte migration. In addition, the role of small numbers of persistent cells (the microchimerism) in perpetuation of long-term graft survival was not yet clear. Finally, the crucial mechanism of clonal exhaustion-deletion was still generally considered to be only a theory. Although we did not know it at the time, precisely these issues were being addressed independently in

TABLE 2. DIFFERENCES BETWEEN CLINICAL ORGAN TRANSPLANTATION AND BONE MARROW TRANSPLANTATION

Feature	Organ Transplantation	Bone Marrow Transplantation
Host cytoablation	No	Yes'
HLA matching	Not essential	Critical
Principal complication	Rejection	Graft-versus-host disease
Immunosuppression-free	Uncommon	Common
Term for success	Acceptance	Tolerance
Leukocyte chimerism	No	Yes

'This therapeutic step allows a relatively unopposed graft-versus-host reaction and accounts for the other differences.

TABLE 3. MECHANISMS OF IMMUNE NONREACTIVITY**Essential**

1. Clonal exhaustion-deletion
2. Immune ignorance

Alternative

1. Special recipient cells: T-regulatory, suppressor, veto
2. Antibodies: idiotypic, "enhancing"
3. Cytokines: self-perpetuating combinations
4. Inhibitory molecules: down regulation
5. Graft secretions: soluble HLA antigens
6. Antigen presentation: defective or deviant
7. Anergy: absence of second signal, or cytokine exhaustion

Zurich but in the context of immune responsiveness and unresponsiveness to noncytopathic microparasites (see later discussion).

TOLERANCE FROM THE INFECTION PERSPECTIVE

The major histocompatibility complex-restricted mechanisms of T-cell recognition of, and response to, noncytopathic microorganisms, and to allografts, had been elucidated by Zinkernagel and Dougherty in the 1970s, but the mechanisms of acquired immune nonreactivity remained a puzzle. During the early 1990s, Zinkernagel and his associates in Zurich formally proved in mouse infection models that the antipathogen T-cell response could be exhausted and deleted, and concluded that this was the explanation for the carrier state that may develop after infection with noncytopathic (intracellular) viruses. As with transplantation, the critical step was migration of the pathogen or its peptide to host lymphoid organs. The presence of virus that failed to reach these destinations was not recognized by the host. This was termed *immune indifference* (now called *immune ignorance*). In essence, Zinkernagel et al. had clarified the interrelationship of immunity and tolerance to pathogens, and had defined tolerance in terms of two essential mechanisms: immune ignorance and clonal exhaustion-deletion. Moreover, they placed these mechanisms in the same dynamic context of antigen migration as that of transplantation.

Once the viral antigen reached lymphoid destinations and induced a cytolytic

T-lymphocyte (CTL) response, the outcome in the highly controlled models of lymphocytic choriomeningitis virus infection were determined by the balance between the amount of virus antigen and the number of induced antigen-specific CTLs (115). Analogous to the maximal flood of passenger leukocytes migrating from a transplanted organ, the critical period was during the first few days or weeks of viral replication. If the CTLs were induced in sufficient numbers, the result was disease control; if not, the result was clonal exhaustion-deletion and a carrier syndrome that ranged from asymptomatic to progressively more serious disease states. No matter what balance was established acutely, perpetuation of this balance (whether immunity, deletional tolerance, or some stage in between) depended on persistence of antigen with access to host lymphoid organs. The ability of small amounts of persistent virus to survive was attributed to its relocation in nonlymphoid sites that were inaccessible to host immune effector mechanisms. From these protected niches, the virus migrated secondarily to host lymphoid organs and could sustain immunity or, alternatively, maintain tolerance. Thus, persistent antigen was a two-edged sword.

THE BOUNDARY BETWEEN IMMUNITY AND TOLERANCE

The analogies between transplantation and infection were summarized in 1998 and generalized to other branches of immunology in the following statement: "...Migration and localization are the governing factors in immunologic responsiveness or unresponsiveness against infections, tumors and self, and against xenografts and allografts." All of the clinical scenarios of transplantation, and those resulting from infection by noncytopathic pathogens, could be correlated with the routes of migration and the ultimate localization of the respective antigens. The "gray area" between unequivocal immunity and durable tolerance included a diversity of transplant outcomes short of outright acute irreversible rejection, as well as a panoply of analogous virus carrier states; all represented different degrees of partial tolerance. Such immunologic "compromises" included chronic allograft rejection and its analogue, chronic hepatitis.

The Rejection Option

Organ Transplantation

The antigen migration is essentially the same with transplantation of the liver and

any other surgically revascularized whole organ (Fig. 2A). Movement of the passenger leukocytes is selective at first to host lymphoid organs, where a clonal anti-donor T-cell response is induced. The CTLs then target the transplanted organ as well as the peripheralized cells of the source graft (Fig. 2A).

Infection

The migratory principles after infection by noncytopathic microparasites are the same as those of passenger leukocytes, but the details differ as both the pathways of microorganism migration and the targets of the CTL response are dictated by the tropism of the various pathogens (Fig. 2B-D). For example, because of the liver tropism of the hepatitis viruses, the quantity of viral antigen that migrates to host lymphoid organs is small compared with that homing to the liver (Fig. 2B). At the lymphoid organs, virus-specific CTLs are induced by infected antigen-presenting cells displaying complexes of major histocompatibility complex molecules plus peptides derived from the pathogen. Because the induced CTLs then destroy infected host cells no matter where these "nonself" cells are located, the principal disease expression is hepatic (Fig. 2B).

The Tolerance Option without Immunosuppression

Organ Transplantation

Exceptions to the outcome of immunity (i.e., rejection) in untreated transplant recipients are rare. However, lifetime tolerance to liver allografts occurs without therapeutic manipulation in about 20% of outbred pig recipients, and with near 100% regularity using selected donor-recipient rat strain combinations, and the majority of mouse strain combinations. Less well leukocyte-endowed mouse heart and kidney allografts also reliably self-induce tolerance, although in far fewer strain combinations. These models of spontaneous transplantation tolerance demonstrate that graft-induced immune nonreactivity is a normal potential option of the immune response (Fig. 3A). Importantly, the "spontaneous tolerance" may be abrogated in some of these models by administering immunosuppression.

Infection

After most infections by noncytopathic parasites, the balance between antigen and antigen-specific CTL tilts within a few weeks to immunity. The exceptions in which protective immunity frequently does

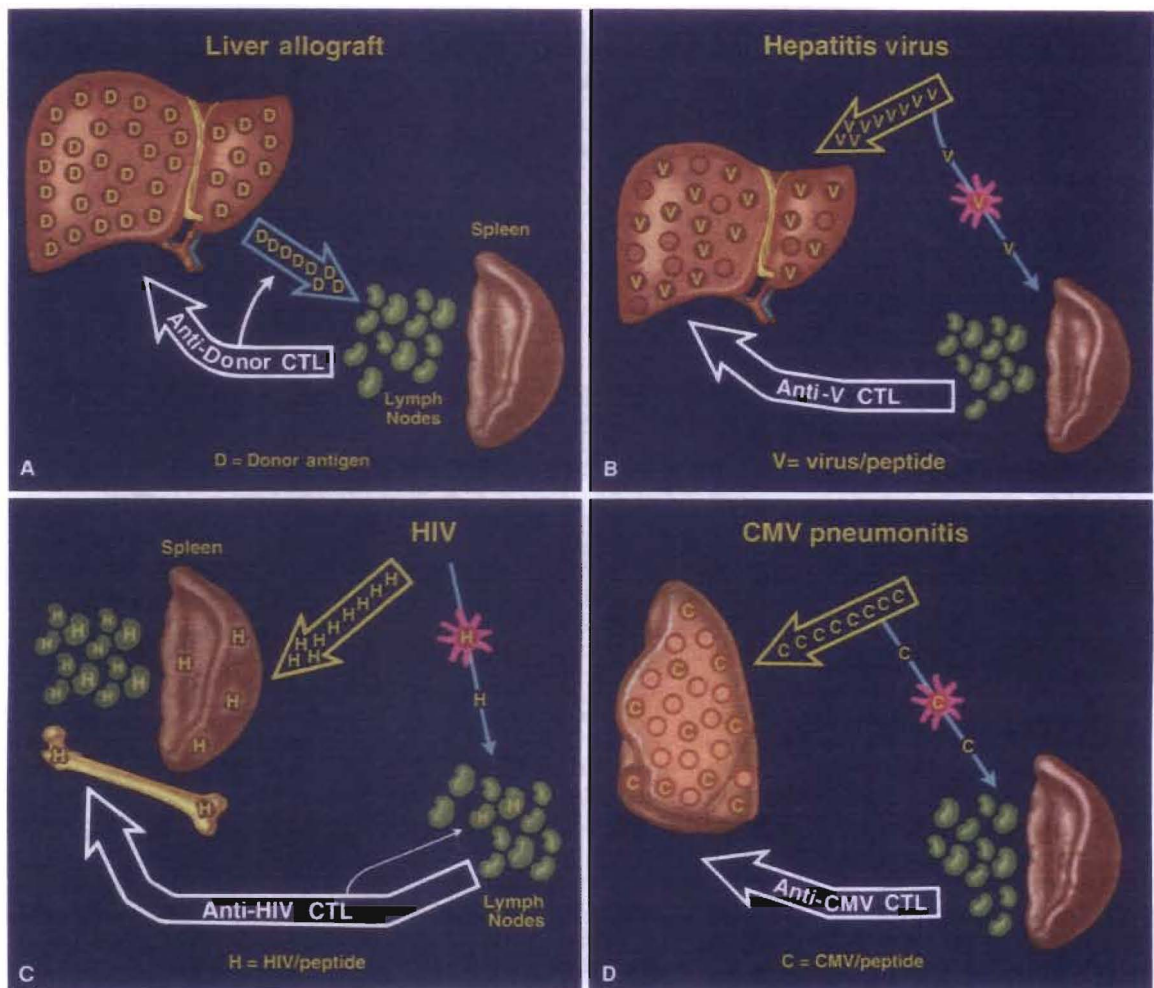


Fig. 2. The consequences of antigen spread and localization (see text) with liver or other kinds of organ transplantation (A), with a viral hepatitis infection (B), with a human immunodeficiency virus (HIV) infection (C), and with a pulmonary cytomegalovirus (CMV) infection (D). CTL, cytolytic T-lymphocyte.

not develop constitute a collection of some of the world's most difficult-to-treat diseases (e.g., acquired immunodeficiency syndrome [AIDS], hepatitis, and malaria).

THERAPEUTIC IMPLICATIONS

Infections with Noncytopathic Microorganisms

In 1994, Zinkernagel and Hengartner discussed the comparative pathophysiology of HIV (a retrovirus) and hepatitis B virus (HBV) a DNA virus) in the context largely developed with their studies of the lymphocytic choriomeningitis virus (an RNA virus). The authors argued that the consequences of HIV were caused principally by virus-specific cytotoxic T-cell-mediated immunopathology rather than by direct cytolytic effects or any other mechanism. The essence of their argument is shown in Figure 2C. After HIV antigen delivery to lymphoid organs by infected den-

dritic cells or other antigen-presenting cells, a CTL response is induced that targets CD4 (T helper) and all other infected cells. With the selective destruction of infected CD4 cells and eventual decimation of the infected antigen-presenting cell population, the inadequately renewed HIV-specific CTL clone is easily exhausted and deleted, and eventually the entire CTL population dwindles. Thus, the immunodeficiency of AIDS may be prevented at the outset by a strong CTL response, or alternatively, the response may cause immunodeficiency. The outcome from the events shown in Figure 2C depends on the balance established at an early time between the amount and localization of the virus versus the CTL response. A similar pathogenesis, but with variable targets and outcomes, pertains with all noncytopathic microorganisms; for example, hepatitis (Fig. 2B) and cytomegalovirus (Fig. 2D).

From this point of view, Zinkernagel and Hengartner had suggested in 1994

that the foremost therapeutic objective under most circumstances is to limit the extent of the infected cell targets, or in clinical terms, to reduce the viral load and restrict its spread. This has since been accomplished in HIV patients with zidovudine and protease inhibitors. It also was pointed out that once a large target is established, the deliberate resurrection of a strong CTL response could have the disastrous consequence of widespread host cell killing. It was suggested that a better option under these circumstances might be the administration of T-cell-directed immunosuppression in just the right amount to prevent the CTL-mediated destruction of massive numbers of host cells, but not so much that runaway viremia would merely expand the target for attack from a recovering CTL clone. Thus, the therapeutic aims in an intractable noncytopathic pathogen infection would be to predict, monitor, and equilibrate beneficial balances between pathogen distribution and

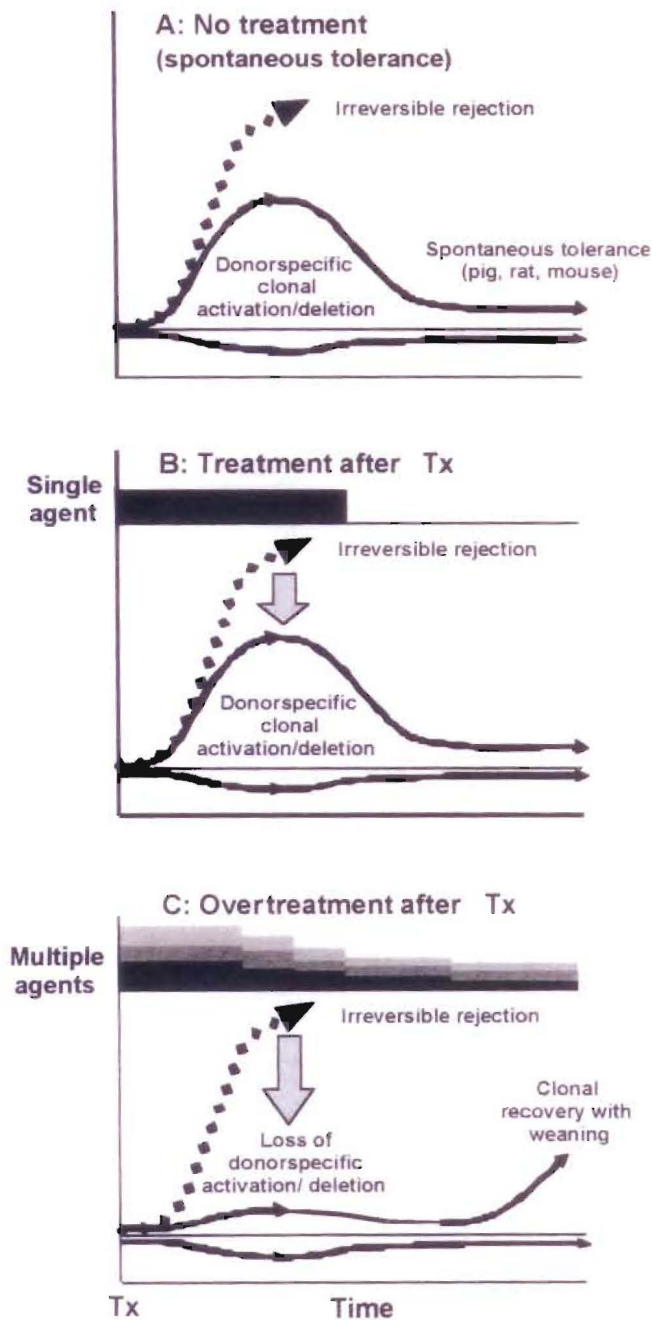


Fig. 3. Organ-induced tolerance. **A:** Spontaneous tolerance induced by the liver in experimental models in which the host-versus-graft immune response induced by the migratory donor leukocytes is too weak to eliminate the donor antigen and is exhausted and deleted (the rise and fall of the *continuous thin line*). Maintenance of engraftment depends on small numbers of persistent donor leukocytes (microchimerism). The less well leukocyte-endowed heart and kidney also can “self-induce” engraftment but in a much smaller number of models. **B:** Immunosuppression-aided tolerance in organ transplant models in which the recipient response that normally would cause rejection (*dashed line*) is reduced into a deletable range (*continuous thin line*) with a short course of early posttransplant immunosuppression. Lifetime tolerance after stopping immunosuppression was first convincingly demonstrated in canine liver recipients. **C:** A self-defeating consequence of excessive prophylactic overimmunosuppression (depicted with multilayered bars) with which clonal exhaustion-deletion is impaired. The initially overtreated recipient may be committed to unnecessarily high maintenance immunosuppression, an undesirable effect of too much immunosuppression that was not recognized until 2001. Tx, transplantation.

the absence of an immunopathologic T-cell response.

The Organ Engraftment Objective

Comparable antigen/CTL balances must be found and kept stable for successful transplantation. The best chance to establish a balance selectively favoring tolerance is during the first few posttransplant weeks, during which the maximal donor leukocyte migration provides the optimal conditions for reciprocal exhaustion-deletion of the double-immune response (Figs. 1 and 3B). It was obvious that this one-time-only window of opportunity could be narrowed or closed by so much prophylactic immunosuppression that clonal activation is subverted. To the extent this were to occur, later reduction of the primary overtreatment predictably would lead to recovery of the ineffectively deleted clone with the clinical consequence of delayed rejection (Fig. 3C). Yet, the penalty of too little immunosuppression during the critical early period may be irreversible rejection. In 2001, it was suggested that this dilemma could be addressed by application of one or both of the therapeutic principles depicted in combination in Figure 4.

The first principle (shown alone in Fig. 3B) consists of administration of no more posttransplant immunosuppression than the amount needed to prevent irreversible immune-mediated damage. Because of histocompatibility and other confounding parameters in the human population, such ideal immunosuppression in individual patients cannot be accurately predicted. With the second principle (recipient pretreatment), host global immune responsiveness can be reduced by nonmyeloablative conditioning before arrival of donor antigen, thereby bringing the anticipated donor-specific immune response into a more easily controllable and deletable range (Fig. 4). The two principles have been combined in a practical regimen using a single large dose of an antilymphoid antibody before transplantation followed by minimalistic posttransplant tacrolimus monotherapy with the intent of eventual weaning (Fig. 5). Satisfactory results in liver (Fig. 6) and other kinds of organ recipients with reduced overall exposure to immunosuppression have been obtained with the striking exception of liver recipients, whose chronic end-stage hepatic failure was caused by hepatitis C virus ([HCV] discussion follows).

The frequency and extent to which drug weaning can be accomplished in hepatitis-free liver recipients with such tolerance-facilitating immunosuppression

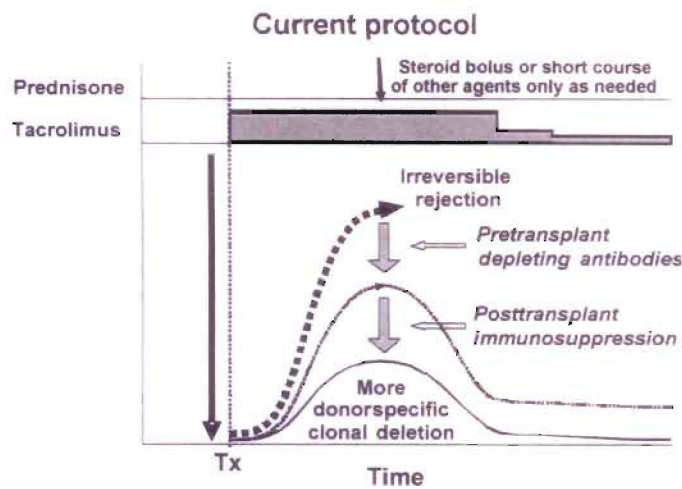


Fig. 4. Protocol of "tolerance friendly" immunosuppression introduced at the University of Pittsburgh Medical Center. An antilymphoid antibody infusion prior to arrival of an allograft reduces the anticipated antidonor response into a more readily deletable range and allows maintenance treatment to begin with daily monotherapy to which other agents are added only for rejection. Weaning from the monotherapy may be possible later. The inverted curve is at the bottom shows the usually silent graft versus host reaction shown more clearly in Figure 1. Tx, transplantation.

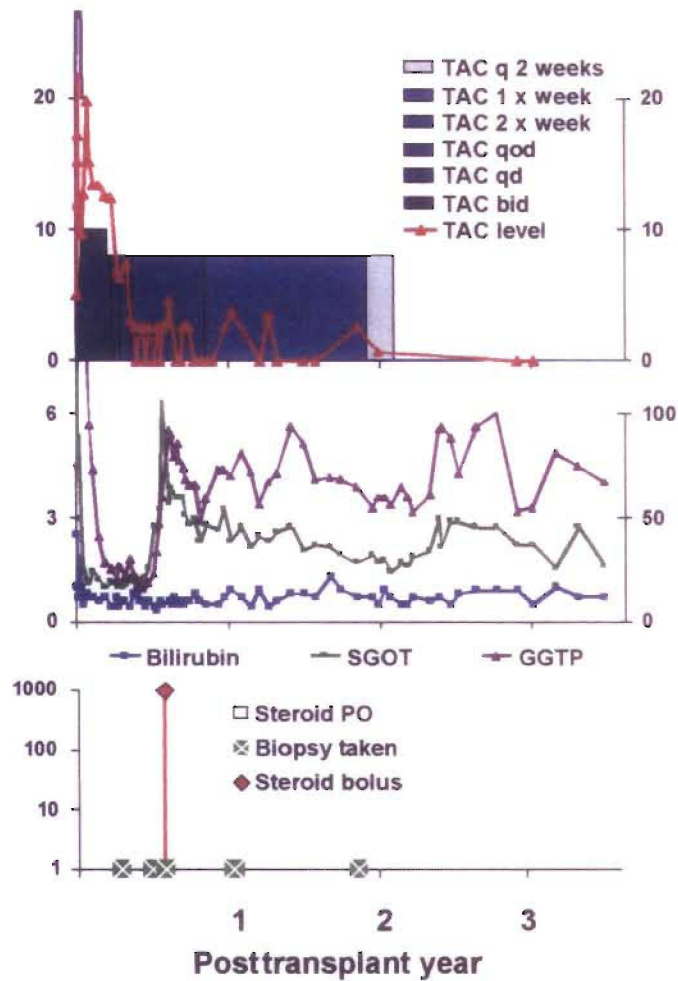


Fig. 5. An example of the strategy shown in Figure 4. A woman with a hepatic hemangioma who was infused with 5 mg/kg antithymocyte globulin (Thymoglobulin) prior to liver allograft revascularization. Tacrolimus (TAC) monotherapy was reduced from daily to every other day at 100 days, and to once per week by 10 months. Treatment was stopped at 22 months. She has been immunosuppression-free for 15 years. Serum bilirubin and measures of hepatic parenchymal function have been normal throughout. Although enzyme levels have been stable, these have hovered at a high normal range or slightly above since a rejection at 6 months, which was treated with 1 g methylprednisolone. SGOT, serum glutamic-oxaloacetic transaminase; GGTP, gamma-glutamyl transpeptidase

Thymoglobulin pretreatment

Campath pretreatment

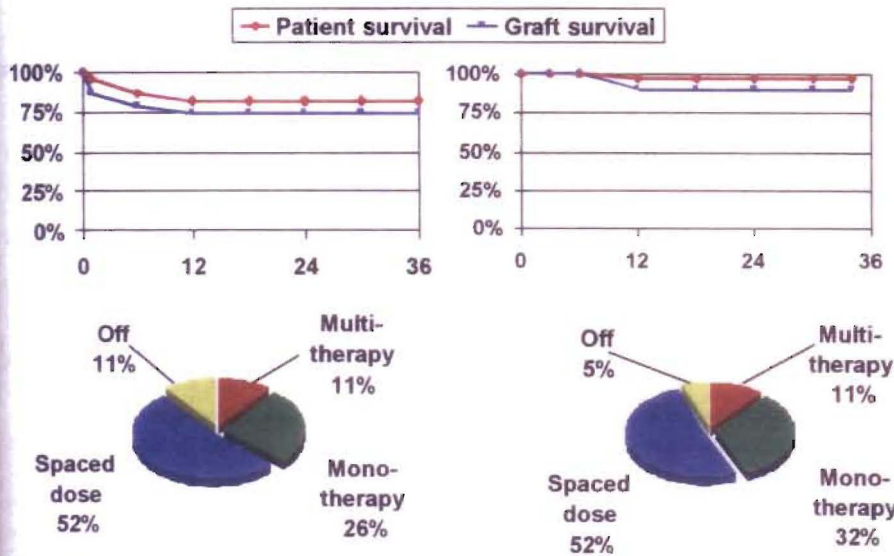


Fig. 6. Patient and graft survival (above) and current immunosuppression (below) of hepatitis-free primary liver transplant recipients treated in Pittsburgh with the principles of immunosuppression shown in Figure 4, and exemplified in Figure 5. *Left*: pretreatment was with an infusion of 5 mg/kg rabbit antithymocyte globulin (Thymoglobulin) ($n = 23$). *Right*: pretreatment was with 30 mg alemtuzumab (Campath) ($n = 38$).

has yet to be determined. Complete stoppage of treatment has been attempted only in a few of these recent cases. However, the feasibility of liberation from immunosuppressive drugs is evident from observations of our first 210 liver recipients: 184 at the University of Colorado (between 1963 and 1980) and 26 at the University of Pittsburgh (in early 1981). Thirty-five (17%) of the 210 patients have now reached or passed their posttransplant silver anniversary (Fig. 7). Thirty-two patients (15%) are still alive from 24.5 to 35.7 posttransplant years (mean, 27.1 ± 31 SD) and three died after 25 years from lung disease (no. 42 in Fig. 7), widespread metastases from colon carcinoma (no. 82) and de novo HCV infection (no. 93).

Importantly, 16 of the 35 quarter-century survivors had periods of 3 to 31 years off immunosuppression, as indicated by the green portion of the horizontal bars in Figure 7. In 5 of these 16 recipients, immunosuppression was resumed, but not because of breakthrough rejection in any case. The reason for treatment reinstatement in two patients was liver retransplantation necessitated by intractable biliary tract complications (no. 202 in Fig. 7) or because of HCV hepatitis (no. 125). A third recipient, whose cyclosporine-based immunosuppression was stopped after 11 years, was returned to treatment 6 years later because of cadaveric kidney transplantation (no. 192). The other two recip-

ients, who were asymptomatic and had rejection-free biopsies, were restarted on treatment because of patient and physician anxiety (nos. 64 and 105 in Fig. 7).

The Price of Chronic Immunosuppression

The consequences of a decision to resume immunosuppression without a clear justification may not be evaluable for years, or decades. When a detailed account of our 210 first recipients was published in the June 1993 issue of *Hepatology*, 50 (23%) of the patients had survived for at least a decade (maximum, 23 years). However, 7 had died from 1 to 11 years after their 10th anniversary, leaving 43 (20.5%) survivors. Rejection had not caused any of the late deaths. Instead, the most common lethal etiologies were hepatitis, other infections, malignant neoplasms, and drug-specific side effects. The same pattern has been apparent in the further shrinkage of survivors between 1993 and 2005 (from 43 to 32) for reasons other than rejection. Chronic immunosuppression clearly has been the principal direct or indirect cause of late mortality.

Organ Engraftment in HCV-Infected Patients

Although the importance of reducing or eliminating long-term immunosuppres-

sion is clear, when the tolerogenic strategy depicted in Figure 5 was applied in HCV-infected liver recipients, the results fulfilled the 1994 prophecy of Zinkernagel and Hengartner. First, the lymphoid depletion caused viremia. Then, when later attempts were made to wean from tacrolimus monotherapy, the heavily infected liver graft was targeted by recovering CTL, resulting in early and severe recurrent HCV disease. With recognition by Eghtesad and Fung et al. of what had happened, the explanation also was apparent for the worldwide epidemic of HCV recurrence that was associated with the various regimens of viremia-inducing heavy multiple drug immunosuppression. Because strong prophylactic immunosuppression cannot be administered indefinitely without fatal consequences, such treatment eventually must be reduced. The consequent CTL recovery was leading to widespread destruction of infected allograft cells in the same way as with the weaning of our lymphoid-depleted patients.

In contrast, light but continuous double-drug immunosuppression with tacrolimus and prednisone has allowed the systematic development of a relatively asymptomatic carrier state: a stable equilibrium between HCV and HCV-specific CTL. Thus, treatment protocols that minimize disease recurrence in HCV-infected liver allograft recipients must balance the desire to reduce immunosuppression or induce allotolerance with the need to prevent antiviral immunopathology. Curtailment of the epidemiologic implications of producing HCV-carrier recipients, and of the probability of insidious disease recurrence, will depend on containment of the viral load with yet to be developed HCV-specific drugs. One candidate is the protease inhibitor recently described in *Hepatology* by Reiser et al.

Tumor Surveillance

By the late 1960s, there was convincing evidence that immunosuppression in organ recipients could result in accidental engraftment of donor malignancies, accelerated growth of tumor metastases, or the development of new malignancies. Because the highest risk from these consequences has been in liver recipients, liver transplant centers have become hot beds of oncology research. Two tumors have been of particular interest because of their etiologic association with intracellular microorganisms: posttransplant lymphoproliferative disorders with the Epstein-Barr

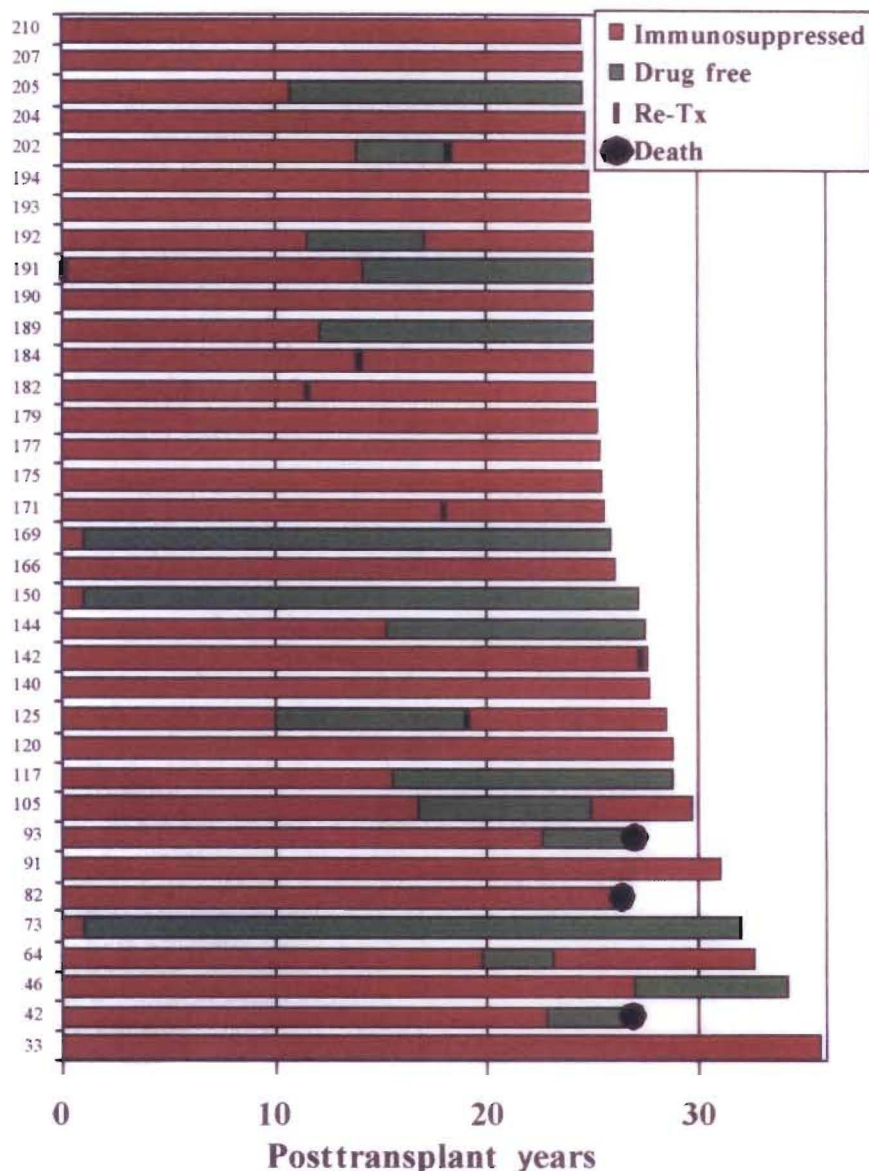


Fig. 7. The 35 patients from the first 210 who survived 25 or more years after liver replacement at the University of Colorado ($n = 184$) or University of Pittsburgh ($n = 26$). The times on (red) and off (green) immunosuppression in individual patients are displayed in the horizontal bars. Note that 6 of the 32 still-surviving recipients had retransplantation (Re-Tx) 11 to 28 years after the primary procedure.

virus and hepatocellular carcinoma with HBV. The posttransplant lymphoproliferative disorders, most of which are B-cell lymphomas, provided the first unequivocal proof of immune surveillance of a human malignancy when they disappeared after withdrawal of T-cell-directed immunosuppression.

The possibility of preventing virus-associated tumors with vaccines was demonstrated by Hilleman with proof of principle studies in primates of the simian virus 40 (SV₄₀) virus, and extended to humans 20 years later with the recombinant HBV vac-

cine trials. The HBV-associated hepatoma scourge was virtually eliminated in immunized Asian populations. How the anti-HBV-induced antibodies produced by the vaccine interrelate with T-cell immunity has been thoroughly studied with lymphocytic choriomeningitis virus and explained by Klenerman. The research and therapeutic opportunities opened by these and other observations is too vast to dwell on here, beyond emphasizing that the mechanisms of immune reactivity and nonreactivity to tumors are the same as those of transplantation.

Autoimmunity

The chimerism-dependent mechanisms of nonreactivity to allografts, all of which depend on mobile leukocytes, can be identified in a continuum of classic tolerance models that began with the observation by Owen of mixed blood cell chimerism in freemartin cattle, and ended in 1992 with the discovery of microchimerism in liver and other kinds of organ recipients (Fig. 8). Of historical interest, Paul Ehrlich recognized more than a century ago that a patient's tissues could be destroyed by an immune system run amuck. Ehrlich's term of *horror autotoxicus* is today's autoimmune disease. He postulated that there must be mechanisms to prevent this by "...a regulatory contrivance as yet undescribed." In the context of immunology described here, the contrivance that Ehrlich envisioned consisted of the mechanisms that have made transplantation feasible.

A NEED FOR CLOSURE

A coherent profile of immune function and governance has emerged from the studies of transplantation and infection summarized here. However, mechanisms of nonresponsiveness other than the essential ones of immune ignorance and clonal deletion (listed in Table 1) have generated a large body of historical and recent publications. In turn, these model-specific and poorly understood alternative mechanisms have become elements of recurring immunologic dogmas and theories. It may be asked if assigning them essential roles in transplantation tolerance is justifiable. Evidence of their existence derives from phenomena observed in experimental models in which the immune system is drastically perturbed (e.g., under conditions of lymphopenia) or the antigenic barriers to transplantation are significantly weakened (e.g., transplantation across minor histocompatibility mismatches). To complete the picture, it will be necessary to definitively determine the conditions for the development of these phenomena and to accurately assess their functional significance.

CONCLUSION

The article entitled "The Evolution of Liver Transplantation" published in 1982 in *Hepatology* concluded with the statement that "...what was inconceivable yesterday, and barely achievable today, often becomes routine tomorrow." Liver trans-

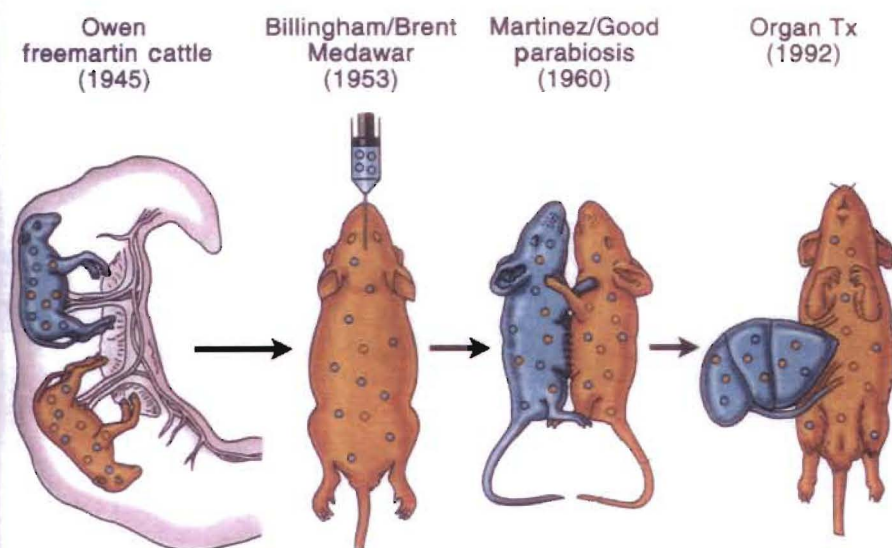


Fig. 8. The relation of organ-induced engraftment (right) to classic models of spontaneous donor leukocyte chimerism-associated tolerance. Tx, transplantation.

plantation proved to be a prime example. But the accomplishment was more than the addition of the crucial centerpiece for the treatment of otherwise lethal end-stage hepatic disease. Liver transplantation was from the beginning, and will continue to be, an instrument of scientific discovery in multiple fields, and above all in immunology.

Note: The contents of this chapter were first published as an article in *Hepatology* (2006;43(2 suppl 1):S151-163). It is reprinted with permission and slight modifications.

SUGGESTED READING

- Bachmann MF, Hunziker L, Zinkernagel RM, Storm T, Kopf M. Maintenance of memory CTL responses by T helper cells and CD40-CD40 ligand: antibodies provide the key. *Eur J Immunol* 2004;34:317.
- Berenguer M, Crippin J, Gish R, et al. A model to predict severe HCV-related disease following liver transplantation. *Hepatology* 2003;38:34.
- Brent L. *A history of transplantation immunology*. London: Academic Press, 1997:182.

- Burlingham WJ, Grailer AP, Fechner JH, et al. Microchimerism linked to cytotoxic T lymphocyte functional unresponsiveness (clonal anergy) in a tolerant renal transplant recipient. *Transplantation* 1995;59:1147.
- Colson YL, Li H, Boggs SS, Patrene KD, Johnson PC, Ildstad ST. Durable mixed allogeneic chimerism and tolerance by a non-lethal radiation-based cytoreductive approach. *J Immunol* 1996;157:2820.
- Cosimi AB, Sachs DH. Mixed chimerism and transplantation tolerance. *Transplantation* 2004;77:943.
- Curry MP. Hepatitis B and hepatitis C viruses in liver transplantation. *Transplantation* 2004;78:955.
- Lakkis FG, Arakelov A, Komieczny BT, Inoue Y. Immunologic ignorance of vascularized organ transplants in the absence of secondary lymphoid tissue. *Nat Med* 2000;6:686.
- Larsen CP, Elwood ET, Alexander DZ, et al. Long-term acceptance of skin and cardiac allografts after blocking CD40 and CD28 pathways. *Nature* 1996;381:434.
- Lechler R, Ng WF, Steinman RM. Dendritic cells in transplantation—friend or foe? *Immunity* 2001;14:357.
- Marcos A, Eghtesad B, Fung JJ, et al. Use of alemtuzumab and tacrolimus monotherapy for cadaveric liver transplantation: with particular reference to hepatitis C virus. *Transplantation* 2004;78:966.

- National Institutes of Health. *Action plan for liver disease research*. Washington, DC: US Dept of Health and Human Services; 2004. NIH Publication No. 04-5491.
- Neumann UP, Berg T, Bahra M, et al. Long-term outcome of liver transplants for chronic hepatitis C: a 10-year follow-up. *Transplantation* 2004;77:226.
- Reiser M, Hinrichsen H, Benhamou Y, et al. Antiviral efficacy of NS3-serine protease inhibitor BILN-2061 in patients with chronic genotype 2 and 3 hepatitis C. *Hepatology* 2005;41:832.
- Shapiro R, Basu A, Tan H, et al. Kidney transplantation under minimal immunosuppression after pretransplant lymphoid depletion with Thymoglobulin or Campath. *J Am Coll Surg* 2005;200:505.
- Smiley ST, Csizmadia V, Gao W, Turka LA, Hancock WW. Differential effects of cyclosporine A, methylprednisolone, mycophenolate, and rapamycin and CD 154 induction and requirement for NF- κ B: implications for tolerance induction. *Transplantation* 2000;70:415.
- Starzl TE, Demetris AJ. Transplantation milestones: viewed with one- and two-way paradigms of tolerance. *JAMA* 1995;273:876.
- Starzl TE, Demetris AJ, Trucco M, et al. Chimerism and donor-specific nonreactivity 27 to 29 years after kidney allotransplantation. *Transplantation* 1993;55:1272.
- Waldmann H. Transplantation tolerance—where do we stand? *Nat Med* 1999;5:1245.
- Walker LSK, Abbas AK. The enemy within: keeping self-reactive T cells at bay in the periphery. *Nat Rev Immunol* 2002;2:11.
- Wiesner RH, Sorrell MF, Villamil F, and the International Liver Transplantation Society Experts Panel, eds. Report of the first International Liver Transplantation Society expert panel consensus conference on liver transplantation and hepatitis C. In: Liver transplantation and hepatitis C: a single topic and consensus development symposium. *Liver Transpl* 2003;9(suppl 3):S1.
- Wood K, Sachs DH. Chimerism and transplantation tolerance: cause and effect. *Immunol Today* 1996;17:584.
- Zinkernagel RM, Doherty PC. The discovery of MHC restriction. *Immunol Today* 1997;18:14.
- Zinkernagel RM, Hengartner H. T-cell mediated immunopathology versus direct cytolysis by virus: implications for HIV and AIDS. *Immunol Today* 1994;15:262.
- Zinkernagel RM, Moskophidis D, Kundig T, Oehen S, Pircher H, Hengartner H. Effector T-cell induction and T-cell memory versus peripheral deletion of T cells. *Immunol Rev* 1993;131:199.

EDITOR'S COMMENT

What better way to finish the first volume but with a special comment by Dr. Thomas Starzl in association with Dr. Fadi Lakkis. The name Thomas Starzl needs no introduction to anyone in the world. He has seemingly and repeatedly been associated with the field of transplantation, specifically liver transplanta-

tion, having conceived of it, worked at it in difficult fashion, and finally brought it to the point where it is, while limited to academic medical centers, performed thousands of times a year all over the world. It is another example in which work in the clinic, as Dr. Starzl points out, then makes its way to the laboratory to

continue to enhance what has been started clinically. The fact that most of the great advances in medicine are actually surgical in the 20th century, including in no particular order, transplantation, blood transfusion, vascular surgery, cardiac surgery, parenteral nutrition, and endocrine treatment for various diseases,

(continued)

makes one wonder why the National Institutes for Health and National Research Policy continue to favor nonsurgeons. They get the overwhelming bulk of the money and yet have produced very little, compared with what surgery has done for the welfare of patients. I believe that since Congress has doubled the budget of the NIH twice in the past decade and has seen very little for their efforts and the amount of money expended, especially including those benefits to rural constituencies, Congress has then begun to take a more careful look at the lack of interest of the general research community in the health of patients. They are more interested in their own egos, their own accomplishments, and their own advancements. It is, in fact, for this reason that the budget has been cut and will continue to be cut for the foreseeable future, until the research community wakes up to the fact that they

must show an interest in the health of patients in exchange for their support from the federal government.

Tom Starzl carried out his great work at the beginning without much in the way of NIH support. He did this seemingly directed by himself, with enormous focus on what was an almost maniacal desire to perfect liver transplantation. The early years were not easy and required enormous expenditures of energy, people, time, and devotion to a goal that at that time seemed distant. Yet, it was accomplished and tens of thousands of patients all over the world owe their lives to Dr. Starzl and his group, initially at the University of Colorado.

Allotolerance has been the "holy grail" of transplantation. The argument in this wonderfully conceived and written chapter, meticulously documented, is the proposal that perhaps less is more; in other words, in order to induce allotolerance, what is needed

is not the type of immunosuppression that devastates all the immune mechanisms in the organism, but some type of balanced chimerism, if you will, into which the proposal of a pretransplant, antilymphocytic agent given in high dosage is then combined with a more moderate single-agent immunosuppression, in this case tacrolimus, with the ultimate hope of winning tolerance. This proposal alters the way in which we have traditionally done immunosuppression. The exception seems to be HCV-infected patients. Here, the goal is somewhat different: to induce allotolerance with the implications of the need to prevent autoantiviral immunopathology. This is the balance that Dr. Starzl seeks. As usual, the particular point is meticulously documented and seeks a global resolution to an issue. This is the legacy of Dr. Starzl's immense contributions to this field.

J.E.F.