

2216

Surgery of the Liver, Biliary Tract, and Pancreas

Fourth Edition

EDITOR-IN-CHIEF

**Leslie H. Blumgart, BDS, MD, DSc (Hon), FACS,
FRCS (ENG, EDIN), FRCPS (GLAS)**

ASSOCIATE EDITORS

Jacques Belghiti, MD

William R. Jarnagin, MD, FACS

Ronald P. DeMatteo, MD, FACS

William C. Chapman, MD, FACS


Markus W. Büchler, MD

Lucy E. Hann, MD

Michael D'Angelica, MD

2007

VOLUME 2



Techniques of Liver Replacement

W. J. Maesh
A. J. B. COSKAND T. E. STARZL

The steps by which liver replacement became the treatment of choice for numerous end-stage liver diseases (Starzl et al, 1989) were summarized more recently (Starzl, 2002). The basic operation was developed in dogs in 1958-1960 and attempted clinically in 1963 under azathioprine-prednisone immunosuppression. The first humans with prolonged survivals were reported in 1967 (Starzl, 1969). It was not until the availability of cyclosporine in the 1980s, however, that orthotopic liver transplantation became accepted worldwide as effective therapy. The results improved again with the advent of tacrolimus in the 1990s.

Elements other than immunosuppression have contributed to success, including improved patient selection and pretransplant management, noninvasive diagnostic methods, new antibiotics, and advances in anesthetic and perioperative critical care. Perfection of the donor and recipient operations was the crucial factor, however, on which all else ultimately depended. Surgical techniques employed at the University of Colorado and, since January 1981, at the University of Pittsburgh are presented in this chapter with emphasis on principles rather than details.

DONOR OPERATION

The use of multiple organs from a single cadaveric donor became practical with the development of standard procurement methods in the early 1980s. Subsequently, the University of Wisconsin preservation solution made storage of hepatic and other kinds of organ grafts relatively safe for 18 hours. The availability of this much time has allowed widespread sharing of livers, while permitting an accurate assessment of the grafts by histologic and metabolic criteria.

Standard Liver Procurement

A midline incision is made from the suprasternal notch to the pubis exposing the abdominal and thoracic organs of potential interest (Fig. 111.1). After it has been verified that the liver has a normal consistency and color, the left suspensory ligament is incised, allowing the left lobe to be retracted anteriorly and to the right. This retraction exposes the upper part of the gastrohepatic ligament, which contains the left gastric artery, the smallest branch of the celiac axis, and the arterial supply of the liver (Fig. 111.2). If an anomalous left hepatic arterial branch originates from the left gastric artery (Fig. 111.3), it must be preserved in continuity with the main left gastric artery (see Fig. 111.3, *inset*).

The largest branch of the celiac axis usually is the common hepatic artery. The right gastric and gastroduodenal arteries are ligated and divided (see Figs. 111.4 and 111.2). If the left gastric, right gastric, and gastroduodenal arteries are ligated in that order, the subsequent dissection of the common duct and the portal vein is rendered relatively bloodless. The common duct is transected as low as possible. The gallbladder is incised, permitting the bile to be washed out (see Fig. 111.3); this avoids autolysis of the extrahepatic and intrahepatic bile duct epithelium during storage. The portal vein now is dissected inferiorly to the confluence of the splenic and superior mesenteric vein (see Fig. 111.4).

After completing the hilar dissection, the aorta is encircled where it passes through the diaphragm and again just proximal to its distal bifurcation. Cannulae for infusion are placed into the splenic vein and, after total body heparinization, into the distal aorta (see Fig. 111.4). When all procurement teams are ready, the aorta is cross-clamped at the diaphragm by the abdominal surgeons (see Fig. 111.4), while the thoracic surgical team clamps the ascending aorta. Moderately rapid infusion of cold University of Wisconsin solution is started into the splenic vein and terminal aorta. At the same time, a cardioplegic solution is infused into the midportion of the ascending aorta. Congestion of the different organs is prevented by an incision in the suprahepatic inferior vena cava that allows the blood and infusate to drain into the pericardium (see Fig. 111.4).

HTK In adults, the liver usually feels cool after 1 L of infusion through the splenic vein and aorta. Smaller volumes are used for children. When the liver becomes cold and blanched, and the heart has been removed, the total hepatectomy is completed. The remaining dissection must be performed expeditiously but methodically. If the celiac axis is retained with the graft, a proximal segment of its splenic arterial branch also should be conserved for potential reconstruction of an anomalous hepatic artery (see later). One such aberrant artery originating from the superior mesenteric artery commonly is found posterior to the portal vein (Fig. 111.5). If the pancreas is to be discarded, the anomalous retroportal artery can be kept in continuity with the superior mesenteric artery, which can be traced to the aorta (see Fig. 111.5, *inset*), where its origin can be incorporated into a Carrel patch that is shared with the mouth of the celiac axis.

The liver is attached primarily by the vena cava above and below the liver. The vena cava below the liver is transected above the entry of the left and right renal veins (Fig. 111.6). The vena cava above the liver is transected with a surrounding rim of diaphragm that is carefully excised on the back table. The retrohepatic vena cava is dissected free, including ligation of the right adrenal vein and posterior lumbar tributaries. The liberated liver

is immediately placed in a solution-filled preservation bag that is packed in ice (see Fig. 111.7).

Modified Donor Procedures

Rapid Procurement

Use of the standard technique in stable donors has allowed the training of relatively inexperienced surgeons in the performance of a donor hepatectomy. When the technique is mastered, faster methods (also developed in Pittsburgh) can be applied electively or if required by urgent clinical circumstances. With the rapid techniques, little or no preliminary dissection is done except for encirclement of the supraceliac aorta and cannulation of the inferior mesenteric vein and terminal aorta (Fig. 111.8). If the heart is to be removed, the cardiac surgeon proceeds as if other organs are not to be harvested, but gives a warning when the circulation is stopped.

At the moment heart function ceases, the abdominal aorta is cross-clamped at the diaphragm, and an infusion of cold University of Wisconsin solution is started in the inferior mesenteric vein and the distal aorta (see Fig. 111.8). The amount of preservation fluid with the rapid technique is approximately double that used for the standard method (i.e., 2 L into the portal and arterial systems instead of 1 L each). When the liver becomes cold, the infusions are slowed. In the now bloodless field, the main vessels of the celiac axis can be ligated quickly, and the hilar dissection can be completed in a matter of minutes.

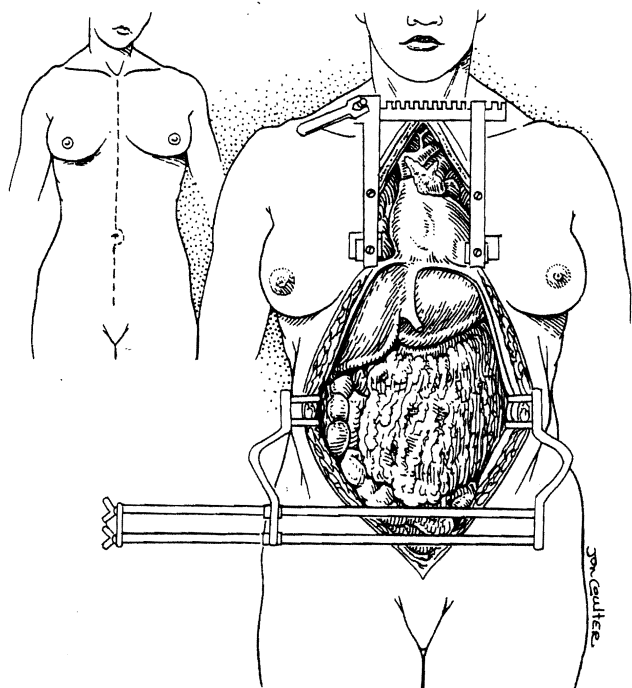


Fig. 111.1. Initial steps for liver retrieval, including complete dissection of the hepatic hilum with the standard multiple organ procurement technique.

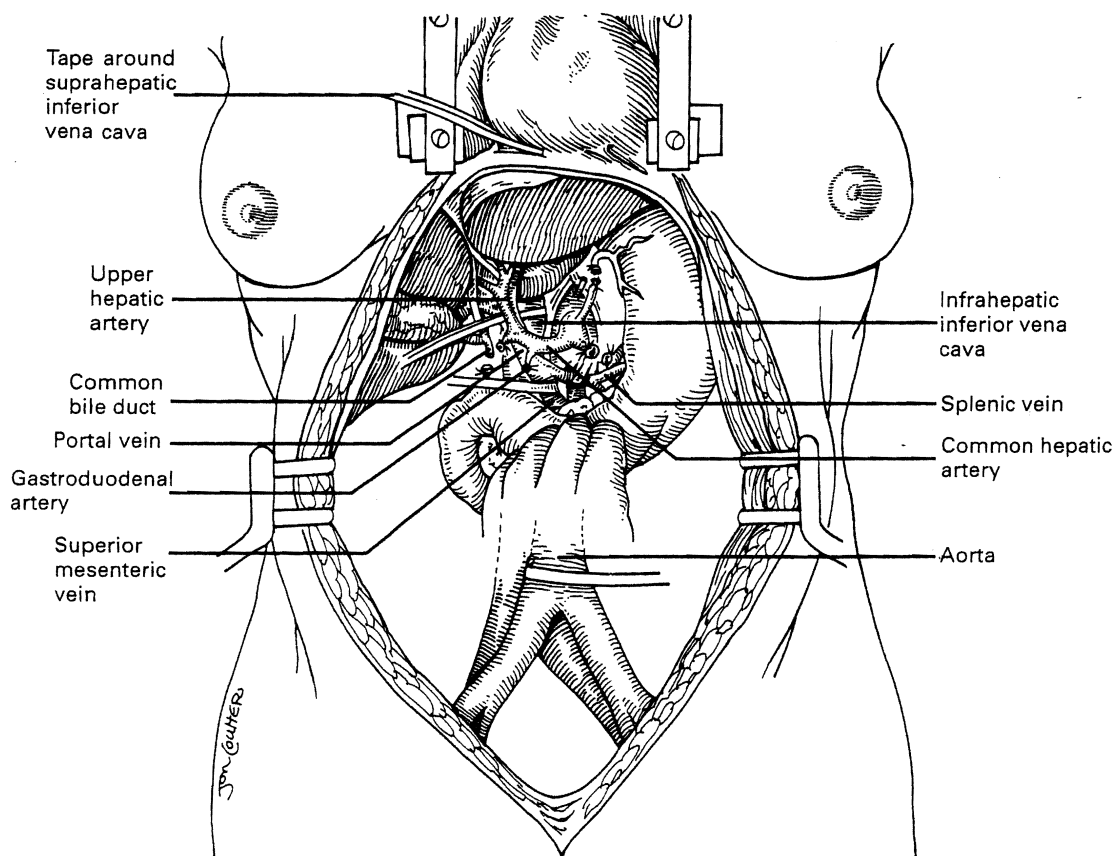


Fig. 111.2. Exposure for multiple organ retrieval in the cadaveric donor.

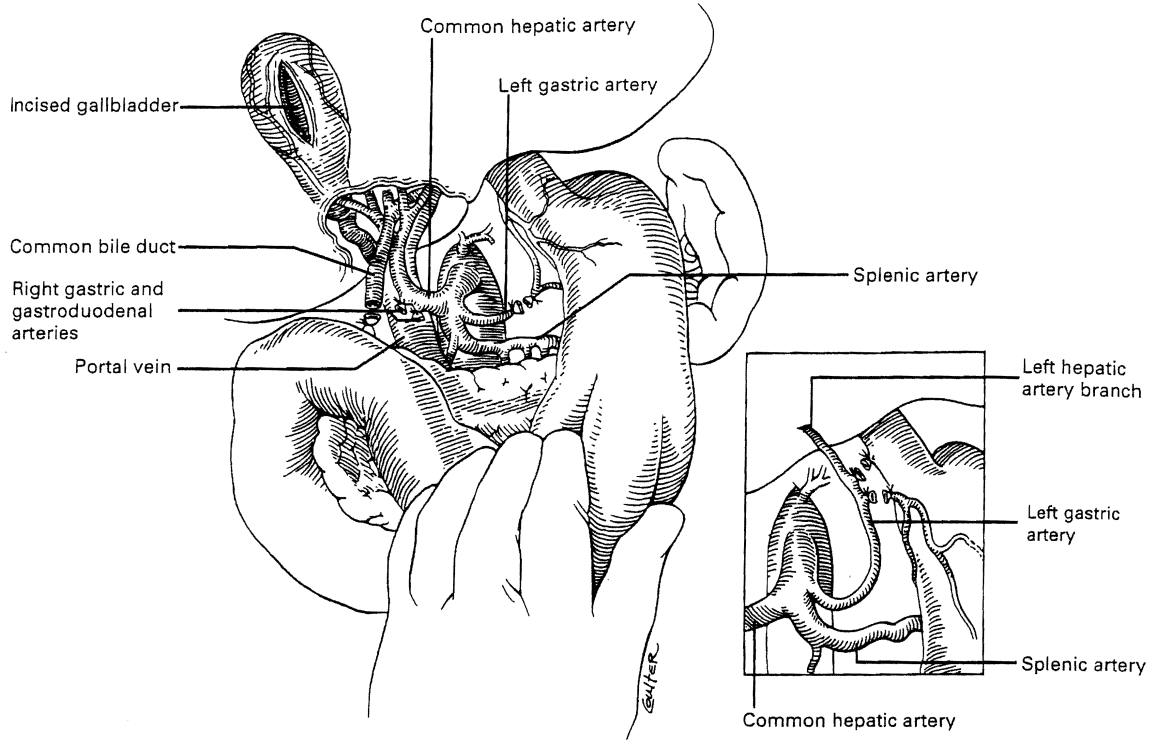


Fig. 111.3. Normal arterial anatomy in which the liver arterial supply is entirely from the common hepatic artery. The *inset* depicts a common anomaly in which all or part of the left lobar supply is from the left gastric branch of the celiac axis. The anomalous branch must be preserved. During the hilar dissection, the common duct is divided distally, and the gallbladder is incised to flush the biliary tree.

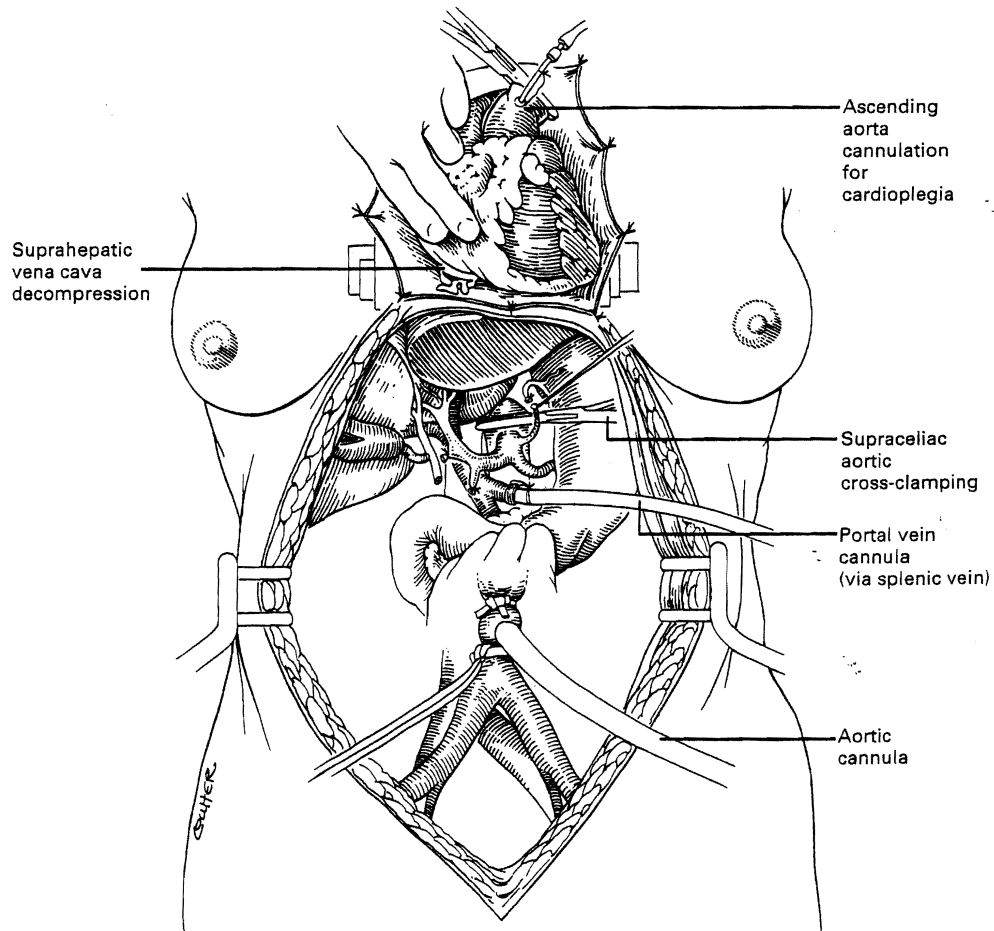


Fig. 111.4. In situ perfusion technique used when the heart, kidneys, liver, and other viscera are removed from the same donor. University of Wisconsin preservation solution is infused into the splenic vein and distal aorta with simultaneous venting of the suprahepatic inferior vena cava into the pericardium. Note the aortic cross-clamp above the celiac axis. The cannulation and cross-clamping of the thoracic aorta for infusion of a cardioplegia solution also are shown.

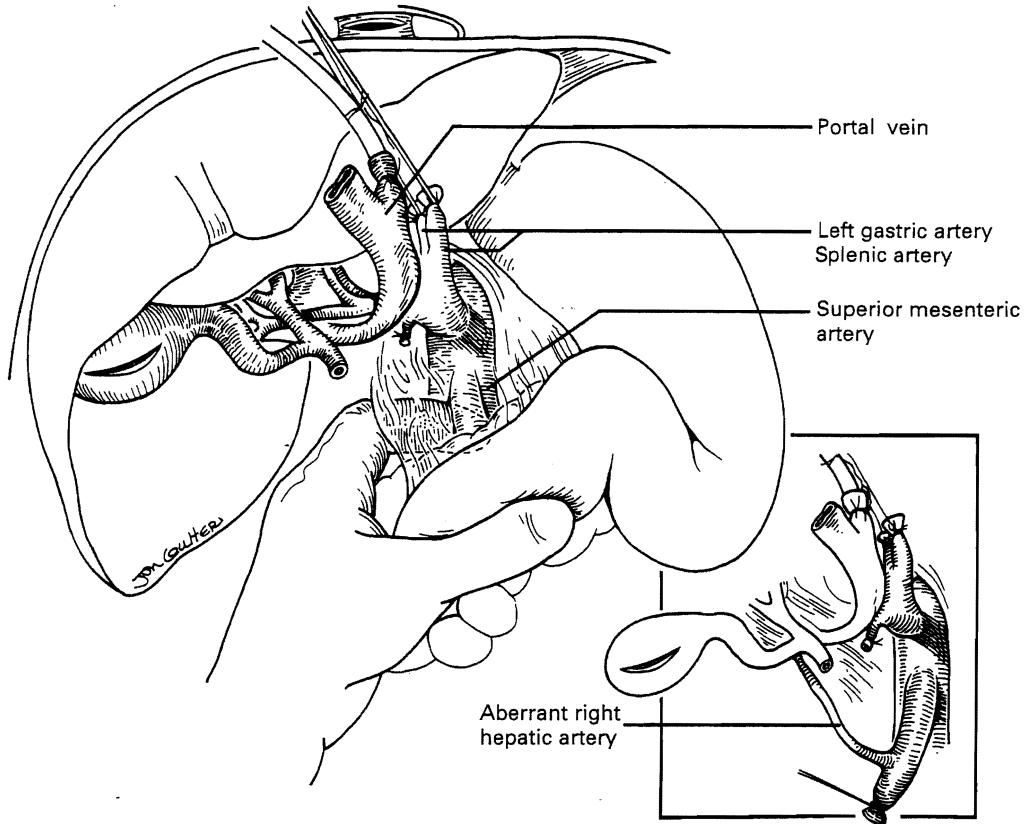


Fig. 111.5. Retraction of the liver and its portal structures to the right and performance of a Kocher maneuver to free up the duodenum and head of the pancreas. The presence of an anomalous right hepatic artery originating from the superior mesenteric artery (*inset*) just posterior to the portal vein is searched for.

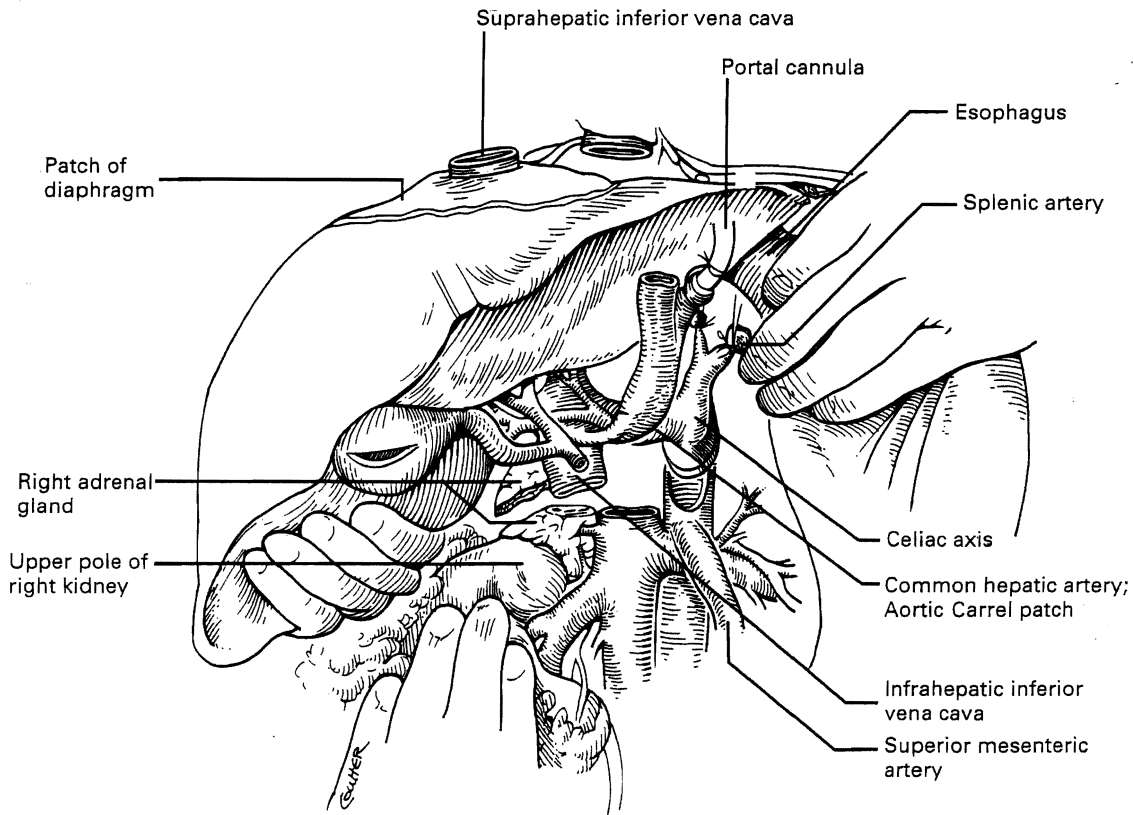


Fig. 111.6. The suprahepatic vena cava has been transected, with inclusion of a generous patch of diaphragm on the liver side. The infrahepatic vena cava is divided just above the origin of the renal veins. The celiac axis is removed with a Carrel patch of anterior aorta. If an anomalous right hepatic artery originating from the superior mesenteric artery is present, the origin of the superior mesenteric artery may be included in the Carrel patch (see Fig. 111.10A).

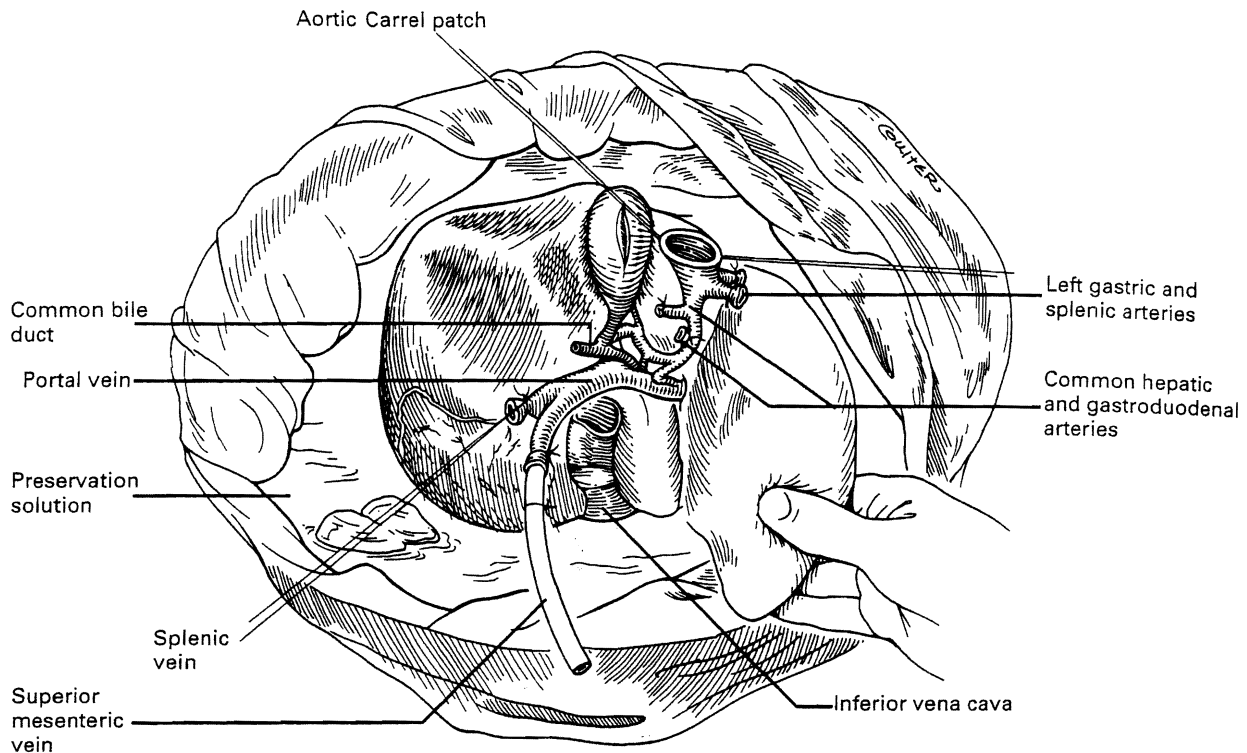


Fig. 111.7. The liver graft is placed in a basin containing iced preservation solution for back table preparation. The vascular cuffs are débrided of excess tissue, and any needed arterial reconstruction is performed (see Fig. 111.10).

The portal vein is cleaned inferiorly to the junction of the splenic and superior mesenteric veins, and these two tributaries are divided. As in the standard method, the surgeon must promptly exclude the possibility of a retroportal right hepatic artery originating from the superior mesenteric artery. The hepatectomy is then completed. The kidneys, which are excised only after the liver has been removed from the field, are kept cold throughout by continued slow intra-aortic infusion of the preservation fluid. It is possible by performing all dissections in the bloodless field to carry out multiple organ removal, including the heart, liver, and both kidneys, in about half an hour. Procurement of the intestine adds only a few minutes.

Super-Rapid Procurement

In arrested or non-heart-beating donors, an even quicker procedure can be used to procure satisfactory organs. The method also can be applied in countries that do not have "brain death" laws or under special legal or religious circumstances. Here, cooling requires urgent cannulation and cold fluid infusion into the distal aorta (Fig. 111.9A). Sternum splitting, thoracic aorta cross-clamping, and severance of the suprahepatic inferior vena cava (for venous decompression) are done (see Fig. 111.9B), deferring cannulation and perfusion of the portal venous system until after the various organs are at least partly cooled intra-arterially (see Fig. 111.9C). The various dissections are done in the same way as with the standard and rapid techniques. Effective application of this method requires an extremely high level of skill.

Back Table Surgery

No matter what procurement method has been used, further preparation of the liver is done on a separate back table before delivering the graft to the recipient surgeon. This liver should be kept cold by emerging it in a basin containing sterile ice slush (Fig. 111.7). Back table preparation includes the following:

1. Dissection and removal of extraneous tissue, such as diaphragm, adrenal gland, lymph node, pancreatic, peripancreatic, and ganglionic tissue
2. Preparation of cuffs of the suprahepatic and infrahepatic vena cava, cleaning of the portal vein and artery, and inspection of the bile duct
3. Verification of secure ligatures on small retrohepatic caval, portal vein, and hepatic arterial branches
4. Insurance of the continuity and integrity of all major structures that must be anastomosed to the companion recipient structures

Failure to have the graft completely ready for implantation when it is brought to the recipient operative field can result in irreversible damage to the graft or make it impossible to complete the recipient operation. Several methods of back table vascular reconstruction have been designed to repair technical accidents or to accommodate aberrant vessels or congenital anomalies. A common reason for back table reconstruction is the presence of an anomalous right hepatic artery originating from the superior mesenteric artery (Fig. 111.10).

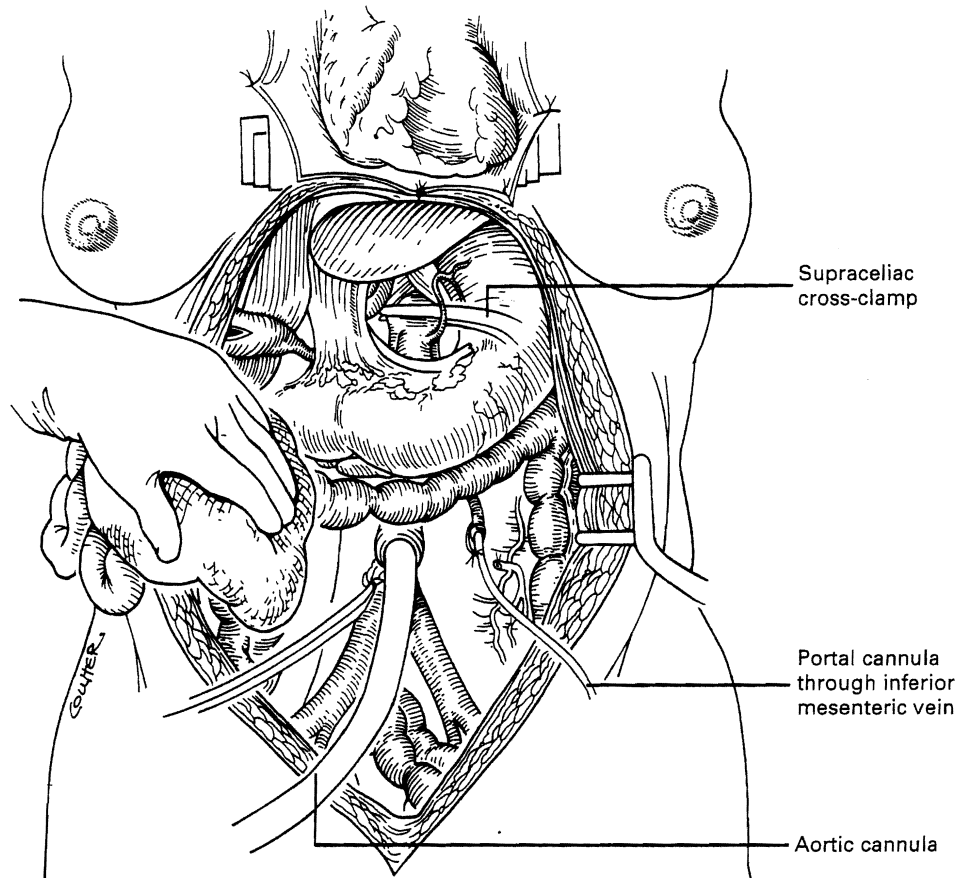


Fig. 111.8. Rapid technique of organ retrieval in which the initial dissection is limited to the exposure needed for the insertion of perfusion cannulae in the inferior mesenteric vein and distal aorta. If only the abdominal organs are to be used, the aorta is cross-clamped at the diaphragm.

Liver, Pancreas, and Intestine Procurement from the Same Donor

The pancreas and intestine can be retrieved independently or together with the liver. Before starting the procurement, the operation should be discussed by the involved surgeons. Considerations include organ priority, type and amount of preservation solution to be used, presence of aberrant hepatic arteries, length of portal vein, and a decision about which organ retains the celiac axis or superior mesenteric artery. An important step in any cadaveric donor operation is the removal and storage of long segments of the donor iliac arteries and veins and of other arteries and veins. These vessels can be used as vascular grafts to reconstruct the blood supply of the individual organs. With increased experience, it is rare to see any of the abdominal visceral organs discarded for purely technical reasons.

RECIPIENT OPERATION

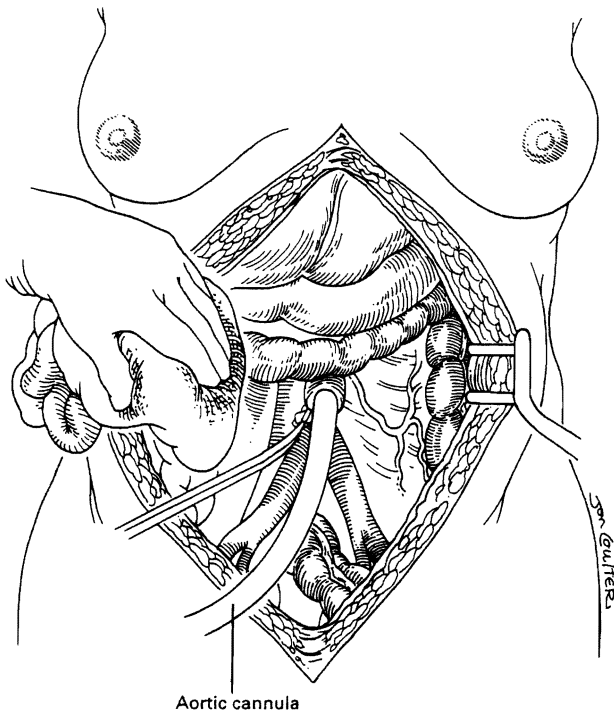
The recipient procedure tends to be long and physically demanding. Its different parts are so remarkably dissimilar that a single surgeon operating from "skin to skin" may find it difficult to change emotional and intellectual gears to keep pace with the evolving events. Removal of the diseased liver may be one of the most difficult challenges a surgeon faces. Yet, the vascular anastomoses can be among the most delicate and

sophisticated procedures one performs, especially in very small children. Achieving perfect hemostasis after the donor liver has been revascularized is crucial because failure can ruin all that has been accomplished; however, this is often an exhausting exercise, particularly at the end of many hours of demanding surgery. Finally, the delicate biliary tract reconstruction becomes the final thread on which the whole enterprise is suspended.

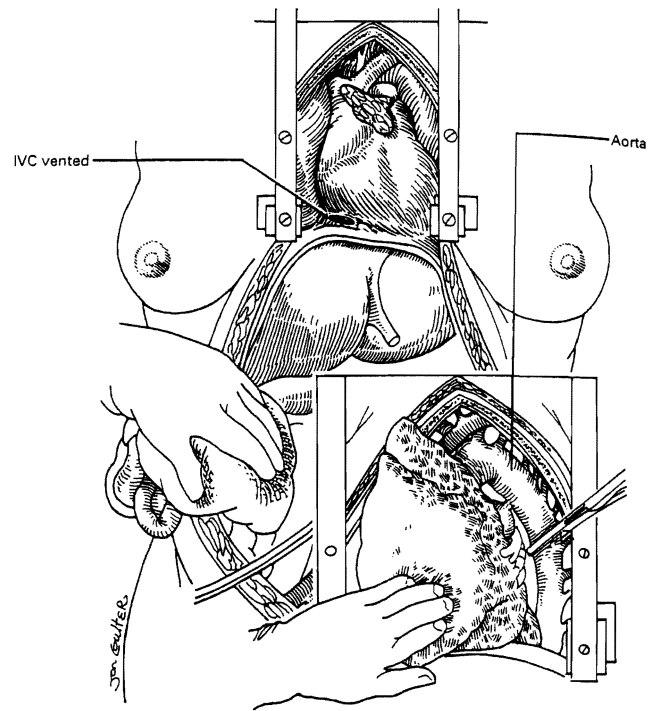
Abdominal Incision and Exposure

The exact location of the incisions may be influenced by previous right upper quadrant surgery, the presence of an ileostomy, the size and configuration of the liver, or other factors. A bilateral subcostal incision, extending on the right to just beyond the midaxillary line and on the left to just short of the anterior axillary line, with an upper midline extension and excision of the xiphoid process, was once the most commonly used incision (Fig. 111.11A). Such drastic exposure is not needed unless the patient has had extensive prior surgery with multiple adhesions. In other unusual circumstances, a lower midline extension may be needed (see Fig. 111.11A), especially if exposure of the distal aorta is required for reconstruction of the hepatic arterial supply. Thoracic extensions are rarely needed.

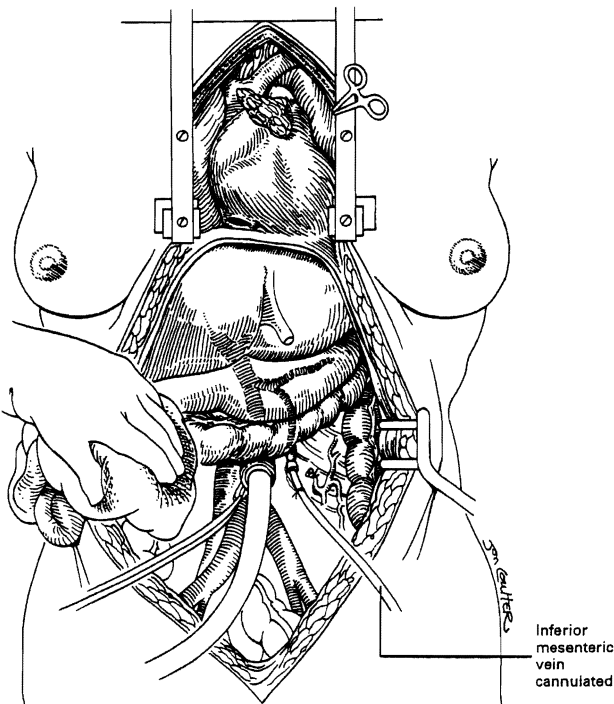
A bilateral subcostal incision (see Fig. 111.11B) or a right subcostal incision with or without an upper midline extension (see Fig. 111.11C) may be used. The right subcostal incision is



A



B



C

Fig. 111.9. The super-rapid technique used for unstable donors in which there is no time for exposure and placement of all the perfusion cannulae. A, A midline abdominal incision is used to cannulate the aorta and begin infusion. B, The sternum is split to expose the pericardium and thoracic aorta. The suprahepatic inferior vena cava (IVC) is incised and bled into the chest, while the descending thoracic aorta is cross-clamped (*inset*). C, The inferior mesenteric vein is cannulated and perfused only after the steps taken in A and B.

the most common one in current use (see Fig. 111.11C). The upper midline extension shown in Figure 111.11C usually is unnecessary in pediatric patients, and it frequently can be omitted in adults. Massive hepatomegaly, extensive prior abdominal surgery, or other factors may mandate the selection of a more disfiguring incision (see Fig. 111.11A or 111.11B). In patients requiring concomitant splenectomy or interruption of a prior splenorenal shunt, the incision may need to be extended to the left subcostal region.

Improved exposure with any of these incisions can be obtained with the use of the Rochard or other rib retractor, which permits access to the hepatic veins and suprahepatic vena cava (Fig. 111.12). In making the incision, it may be necessary to abandon delicate celiotomy techniques of meticulous hemostasis and resort to continuous hemostatic suturing along the cut edges of the fascia and preperitoneum. When the abdomen is entered, an effort must be made to find a plane of dissection just outside the liver capsule. Movement away from this plane risks an encounter

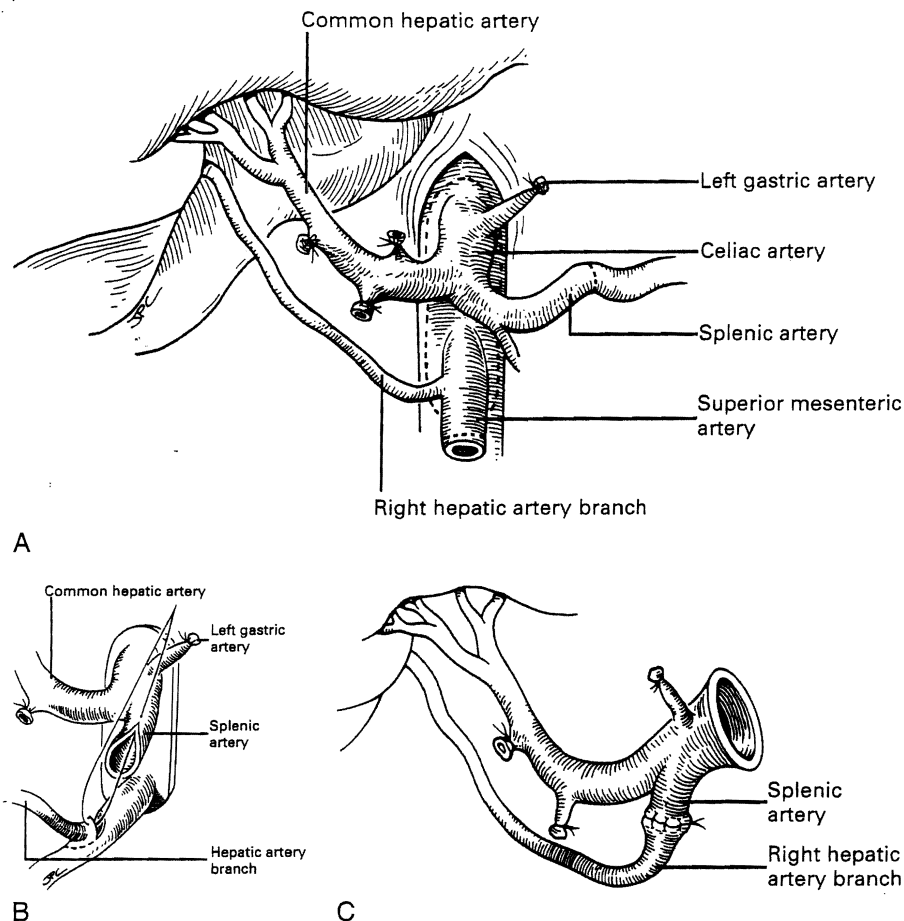


Fig. 111.10. Examples of reconstruction of an anomalous arterial supply to the liver. **A**, The origins of the celiac axis and superior mesenteric artery are removed from the anterior aorta in a common Carrel patch. **B** and **C**, An anomalous right hepatic artery is anastomosed to the graft splenic artery, leaving only the origin of the celiac axis for anastomosis in the recipient.

with major venous collaterals, which can result in disastrous hemorrhage early in the operation.

Intraoperative Determination of Surgical Strategy

There is no single best way to carry out orthotopic liver transplantation. When exposure has been obtained, it is important to assess the pathology and decide on the technical approach that best fits the pathologic circumstances. A surgeon who insists on following the same steps in unvarying order for all liver recipients experiences unnecessary hardship. The following is a description of the basic ingredients of the recipient operation, with particular emphasis on variations of host hepatectomy.

Venovenous Bypass

The most critical stage of the recipient operation is the anhepatic phase, during which the diseased liver is removed and replaced with the allograft. Obstruction of the portal vein and vena cava during this period results in splanchnic and lower body systemic venous hypertension. This situation has devastating consequences in some patients. During the early 1980s, a pump-driven venovenous bypass, used without recipient heparinization, was developed in Pittsburgh that allowed splanchnic and systemic blood

to return to the heart by way of an inflow cannula placed in the axillary vein (Fig. 111.13). This technique permitted the hepatectomy and implantation to be done with significant reductions in blood loss, intestinal edema, and postoperative renal failure.

Infants and small children weighing less than 15 kg tolerate venous occlusion reasonably well. Consequently, venovenous bypass has been routinely used only for patients of adult size. Even in adults, some experienced surgeons employ the bypass only when it becomes apparent that its use cannot be avoided. If bypass is not routine, the decision for or against its use should be made as early as possible in the course of the operation. The decision can be helped by testing the cardiocirculatory effects of test occlusion of the inferior vena cava and portal triad. If the test is conducted after preliminary dissection of the portal triad, and after the triangular and coronary ligaments are cut with entry into the right and left bare areas, it also is possible to evaluate the extent to which bleeding from raw surfaces can be anticipated without venovenous bypass.

Hilar Dissection

In "easy" cases, the individual hilar structures can be readily skeletonized. The hepatic artery and common duct are ligated as close to the liver as possible. The hepatic artery is dissected proximal to the origin of its gastroduodenal branch, facilitating exposure

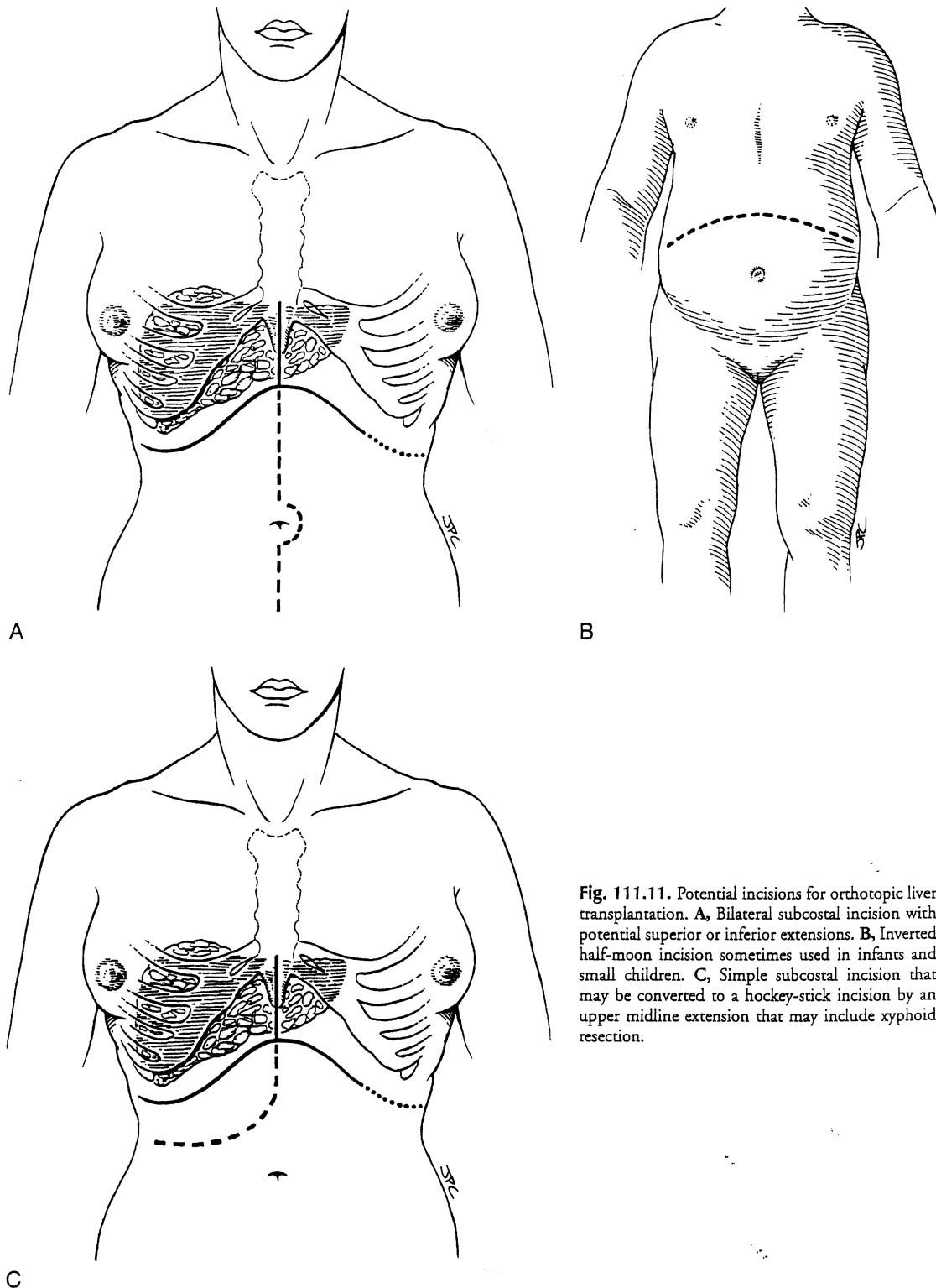


Fig. 111.11. Potential incisions for orthotopic liver transplantation. **A,** Bilateral subcostal incision with potential superior or inferior extensions. **B,** Inverted half-moon incision sometimes used in infants and small children. **C,** Simple subcostal incision that may be converted to a hockey-stick incision by an upper midline extension that may include xyphoid resection.

of the proximal portal vein (Fig. 111.14). Venovenous bypass can be initiated with cannulation of the transected portal vein at this time or later.

Host Hepatectomy with or without Vena Cava Removal

If hilar dissection has been accomplished uneventfully, the liver is devascularized and now can be excluded from the circulation

by cross-clamping the vena cava above and below the liver (Fig. 111.15A). The diseased organ with or without the segment of retrohepatic vena cava can be peeled out working from the hilum up or from the diaphragm down. If the vena cava is part of the specimen, the obligatory ligation of the right adrenal vein (see Fig. 111.15C) imposes a risk of adrenal infarction. If this occurs with venous hypertension and bleeding, the right adrenal gland should be removed immediately. Other systemic venous tributaries to the vena cava segment from the lumbar regions also must

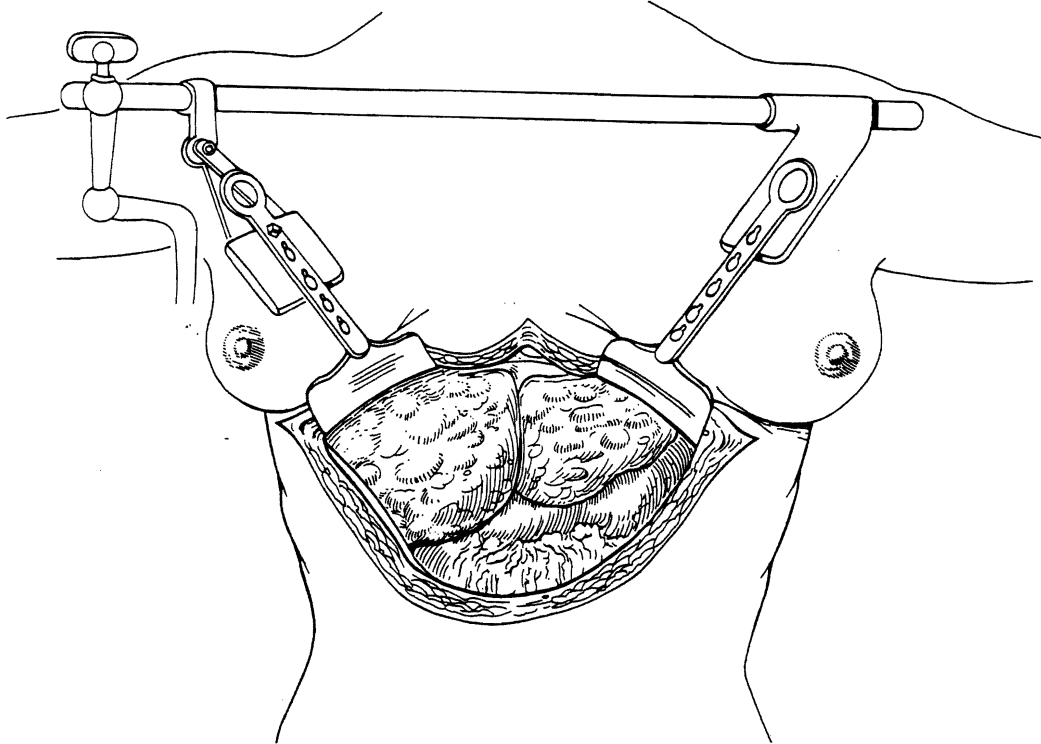


Fig. 111.12. Exposure, especially of the suprahepatic vena cava, can be facilitated by the use of self-retaining retractors, such as the Rochard device.

be scrupulously ligated. Because of regional venous hypertension in the right-sided bare area, it may be necessary then or later to obtain hemostasis by closing or oversewing the edges of the exposed bare areas with a continuous suture (see Fig. 111.15D).

Many of these problems can be circumvented if the host retrohepatic vena cava can be conserved (see Fig. 111.15A). Separation of

the diseased liver from the vena cava is done in the same way as in the classic experimental procedure of total canine hepatectomy. With this kind of hepatectomy, stumps of one or more of the main host hepatic veins are retained (see Fig. 111.16A) for eventual receipt of the allograft's venous outflow (Fig. 111.16B and C); this is known as the piggyback method of liver transplantation.

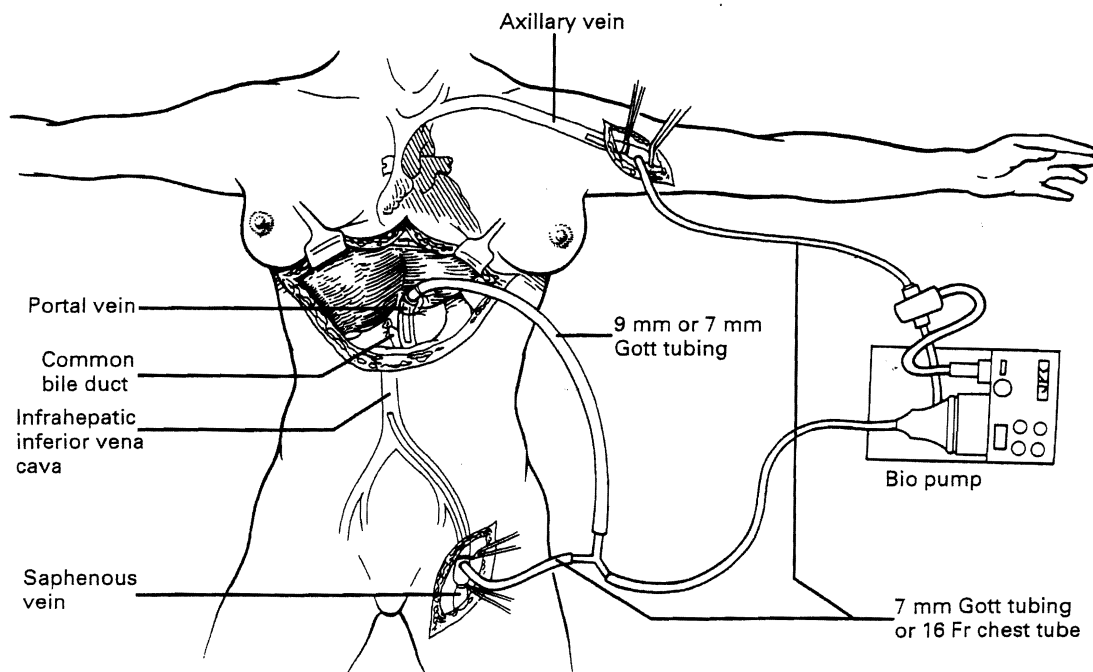


Fig. 111.13. Pump-driven venovenous bypass used to decompress the systemic and splanchnic venous beds during the anhepatic phase of liver transplantation.

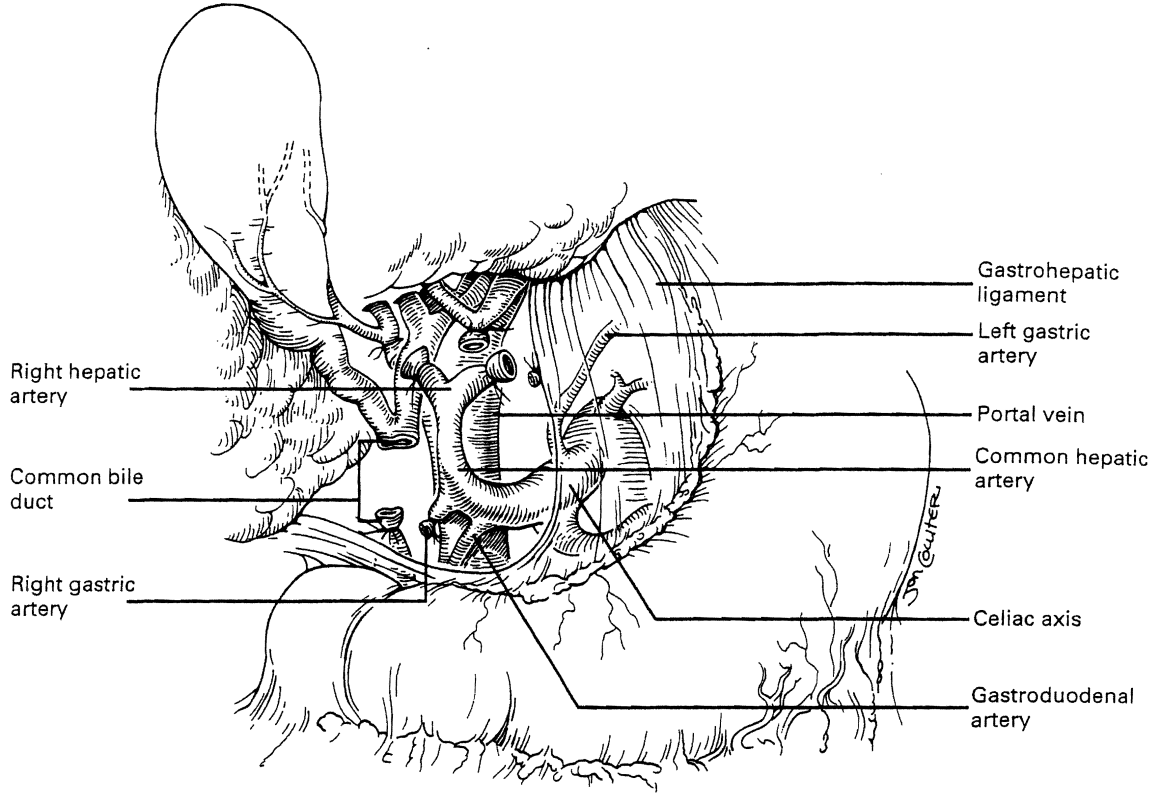


Fig. 111.14. Hilar dissection in the liver recipient.

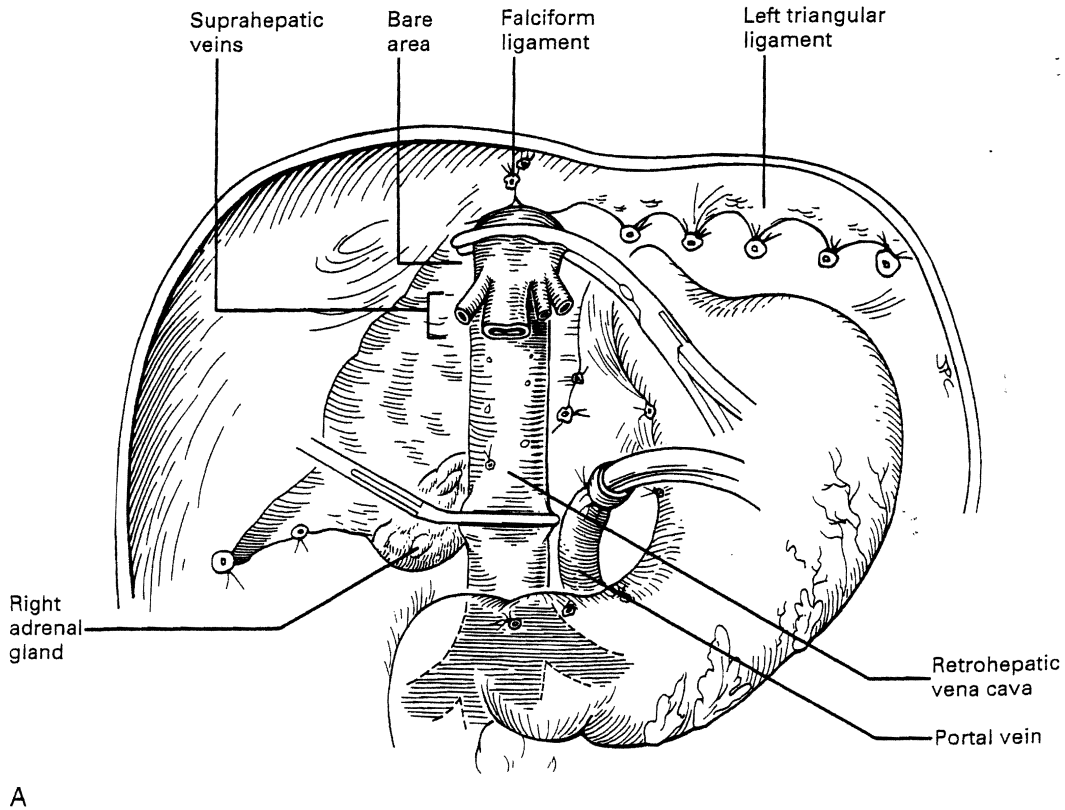


Fig. 111.15. Completed recipient hepatectomy on venovenous bypass. A, With preservation of host retrohepatic vena cava. Note the hepatic vein cuffs.

Continued

Fig
rect
is r

Te
tir
ca
of
ris
ac

A

Ir
o.

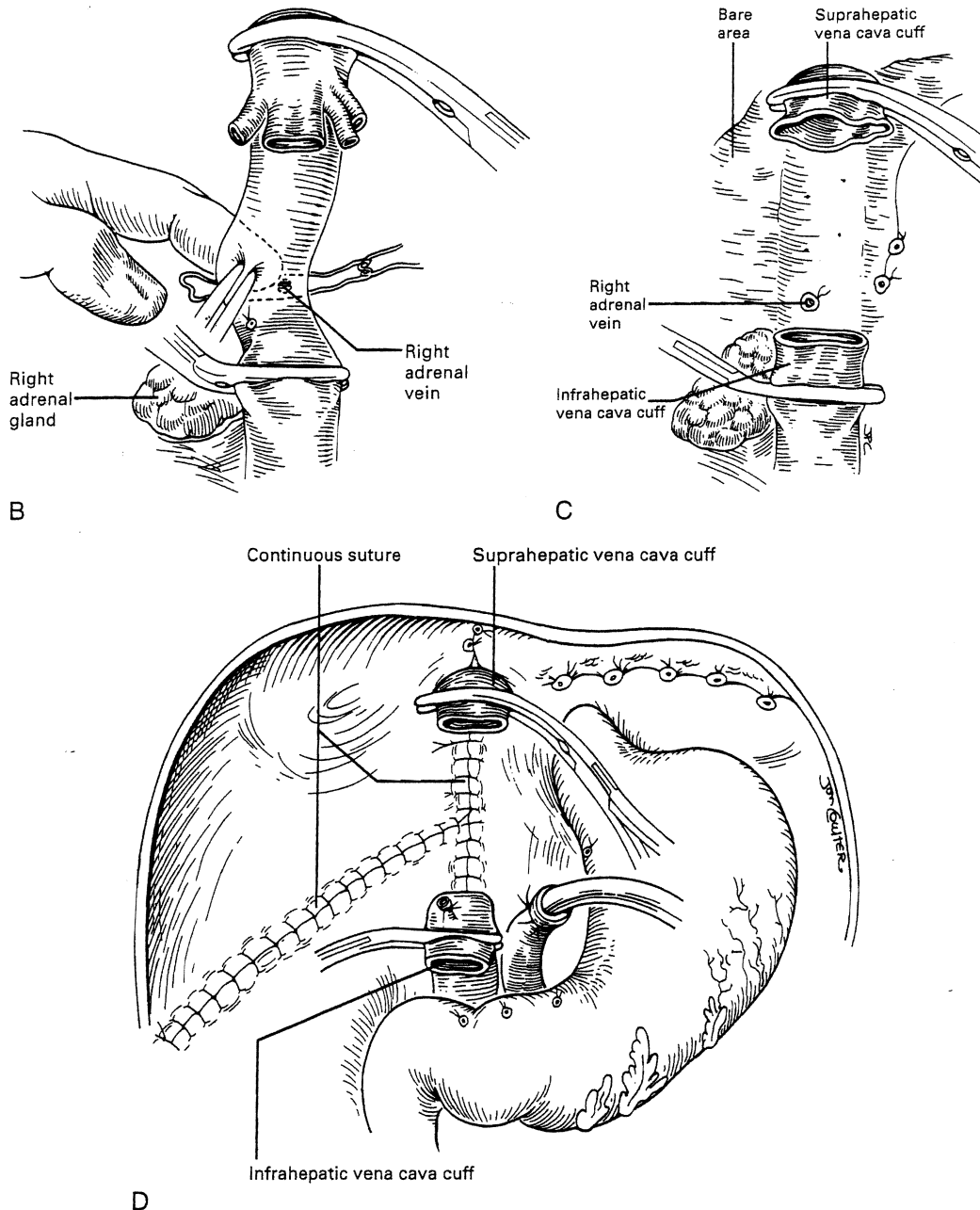


Fig. 111.15. cont'd. B, As in A, but with an injury to the right adrenal vein, which is being ligated. C, The retrohepatic vena cava has been included in the hepatectomy, necessitating ligation of its tributary lumbar veins and the right adrenal vein. D, Closure of the bare area to provide hemostasis. Bleeding from the bare area is more severe if the retrohepatic cava is removed because of the loss of venous drainage.

To the extent vena cava flow can be maintained during the sometimes tedious and difficult denudation of the retrohepatic vena cava, the need for venovenous bypass is eliminated. The amount of retroperitoneal dissection is reduced considerably. Finally, the risk of right adrenal infarction is eliminated, unless the right adrenal vein is injured as depicted in Fig. 111.15B.

Alternative Approaches to Hepatectomy

In many, if not most, cases, hepatectomy with or without inclusion of the retrohepatic vena cava is uncomplicated. Dissection of the

liver hilum sometimes is difficult or impossible, however, because of scarring or the presence of varices. In these situations, the suprahepatic vena cava can be approached first. After transecting the upper vena cava, removal of the liver can be done from top down, approaching the hilar structures from behind (Fig. 111.17). Alternatively, the inferior vena cava below the liver can be used as a "handle" to extract the liver from bottom to top, with cross-clamping (or transection) of the hilar structures at the earliest possible opportunity (Fig. 111.18). Finally, if adhesions are present that block access to the upper and lower vena cava and to the portal triad, the liver can be split, exposing the anterior surface of the retrohepatic vena cava (Fig. 111.19).

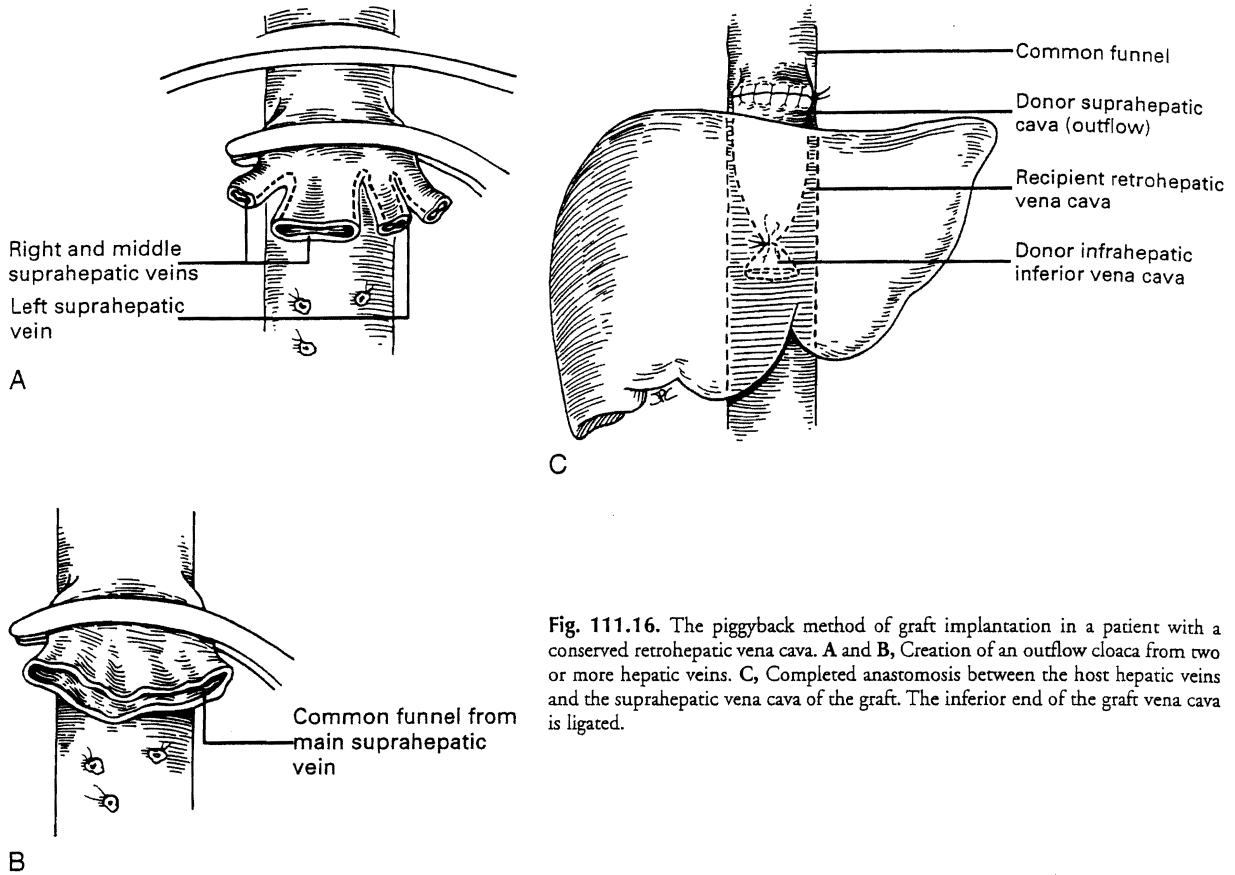


Fig. 111.16. The piggyback method of graft implantation in a patient with a conserved retrohepatic vena cava. A and B, Creation of an outflow cloaca from two or more hepatic veins. C, Completed anastomosis between the host hepatic veins and the suprahepatic vena cava of the graft. The inferior end of the graft vena cava is ligated.

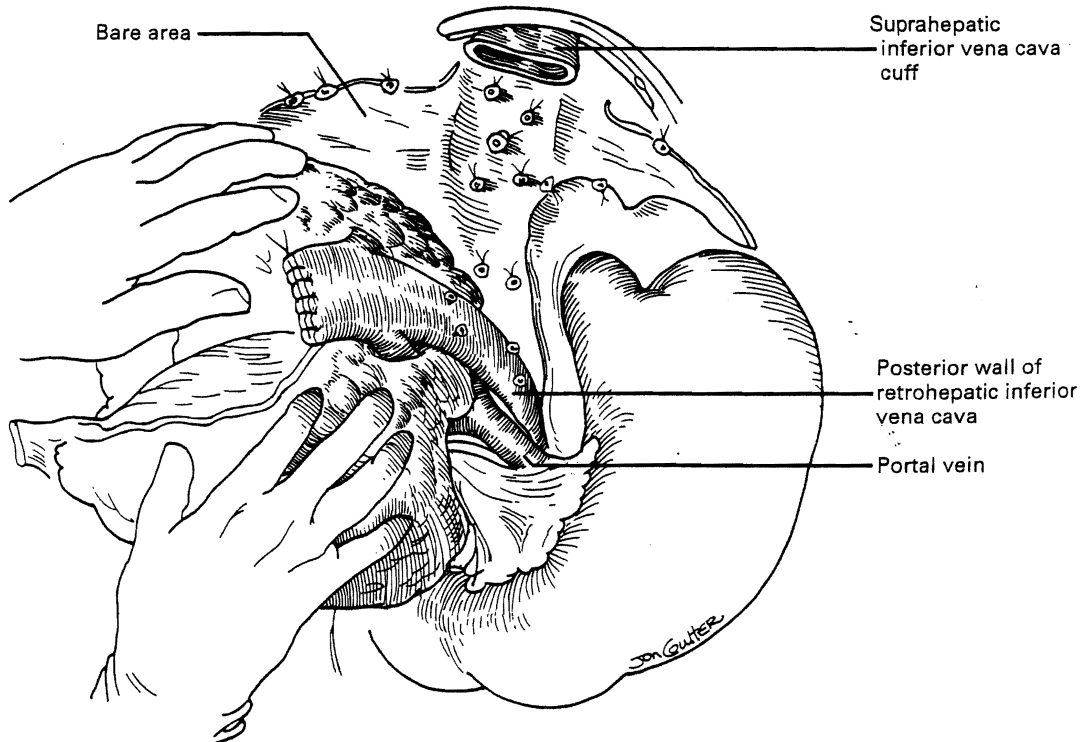


Fig. 111.17. Removal of the recipient liver from top down.

Once bleeding from the raw surfaces is controlled with continuous sutures, the two hepatic halves are stripped away from the surrounding structures. All of these hepatectomy variations are made easier by venovenous bypass.

VASCULAR ANASTOMOSES

It is important to have the surgical field completely prepared for implantation before the new liver is brought from the back table. The first graft vessel to be anastomosed always is the segment of donor vena cava into which all the hepatic veins of the transplanted liver drain. If host hepatectomy has included removal of the retrohepatic vena cava, the anastomosis is an end-to-end suprahepatic vena caval-to-suprahepatic vena caval connection at the diaphragm (Fig. 111.20A). With the piggyback operation in which the host vena cava is conserved, the suprahepatic vena cava is emptied into a cuff of host hepatic vein (see Fig. 111.16) or by a side-to-side anastomosis between the two vena cava segments (not illustrated).

The order of the other vascular anastomoses may vary. With the caval-sparing piggyback operation, the infrahepatic vena cava of the graft is ligated (see Fig. 111.16). When the host caval segment is excised, a common practice is to anastomose the infrahepatic vena cava (see Fig. 111.20B), followed by removal from the bypass and portal vein anastomosis (see Fig. 111.20C). These anastomoses may be done in reverse order (i.e., portal vein first). An experienced surgeon may prefer to perform the arterial anastomosis before the portal vein reconstruction or

complete all four anastomoses before unclamping. These decisions are influenced by the anatomic and physiologic circumstances in the individual case, including the efficiency with which the bypass system has functioned.

In all cases, it is important before definitive liver reperfusion to flush the allograft with lactated Ringer's solution (some surgeons prefer albumin). This is done through the cannula left in the graft portal vein at the time of procurement (see Fig. 111.20A). After its passage through the microvasculature of the allograft, the infusate is vented from the vena cava (see Fig. 111.20B). The objectives are to remove air and to rid the graft of the high-potassium solutions used for organ preservation (see Fig. 111.20B). Failure to perform this flush can result in air embolism or hyperkalemic cardiac arrest.

All of the vascular anastomoses are done with continuous suture. To avoid anastomotic strictures, particularly of the portal and arterial anastomoses, special techniques were developed that are made feasible by the ability of polypropylene (Prolene) suture to glide freely through tissue. A "growth factor" is left by tying the sutures at a considerable distance from the vessel wall. After the flow is restored through the anastomosis, the excess polypropylene recedes back into the vessel and redistributes itself throughout the circumference of the suture line (Fig. 111.21). If leaks develop, these are readily controlled with single additional sutures.

Rather than being whimsical, variations of the order and details of revascularization frequently are mandated by anatomic anomalies or by pathologic factors, including thrombosis of the portal vein, that contraindicated liver transplantation until

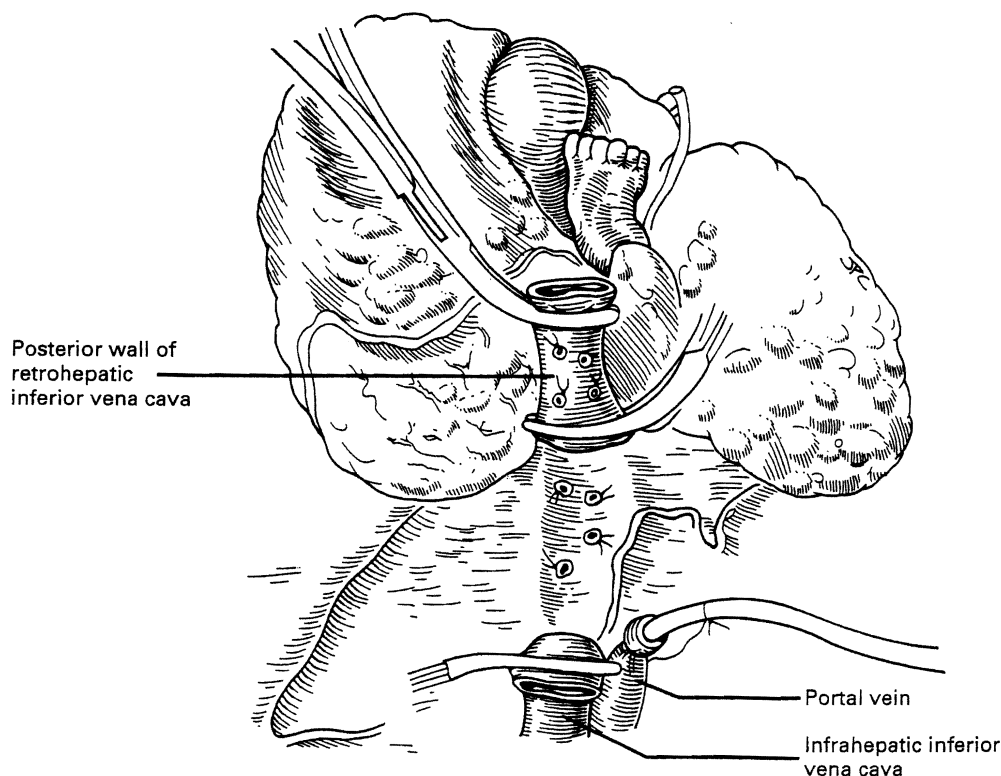


Fig. 111.18. Removal of the recipient liver from bottom up.

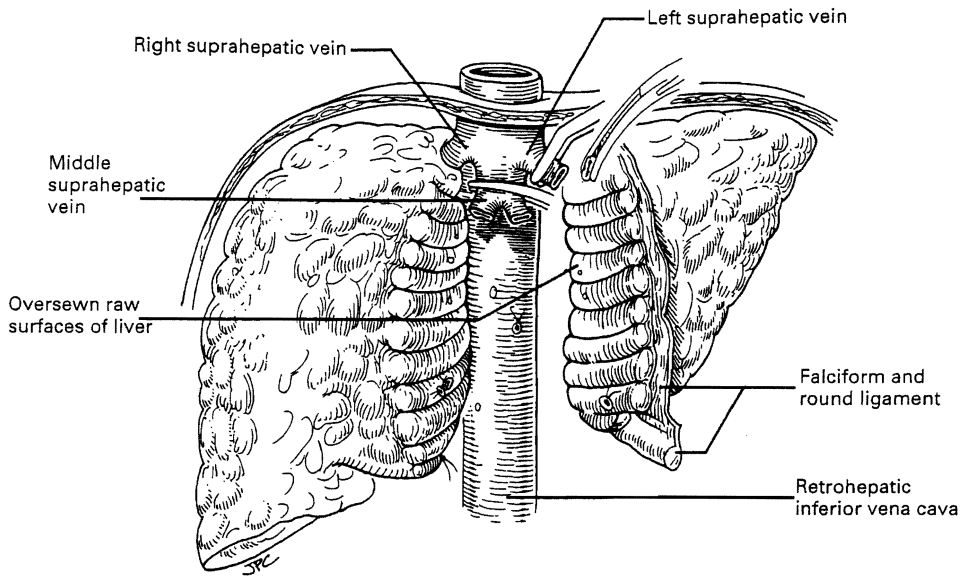


Fig. 11.19. Splitting technique of hepatectomy. The split is facilitated by insertion of the finger along the relatively vein-free anterior surface of the vena cava. The correct plane must be determined carefully by finger probing before any pressure is applied.

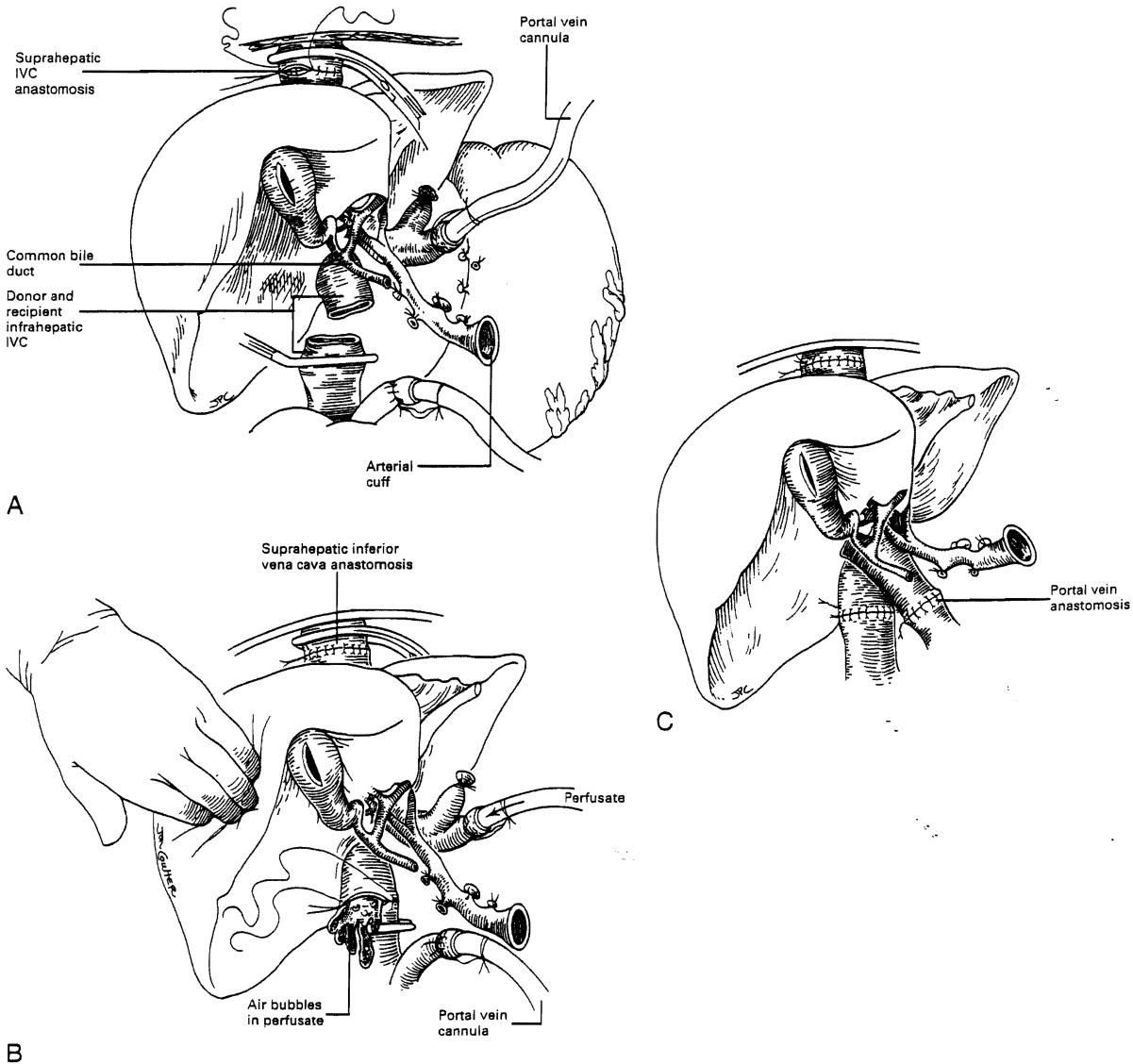


Fig. 11.20. Implantation steps. A, Suprahepatic vena cava anastomosis. B, Infrahepatic vena cava anastomosis. Before completing the anastomosis, the portal vein is infused with cold albumin or electrolyte solution. This allows air and the potassium-rich preservation fluid to be sucked out. C, The portal vein anastomosis after removal of the bypass cannula. IVC, inferior vena cava.

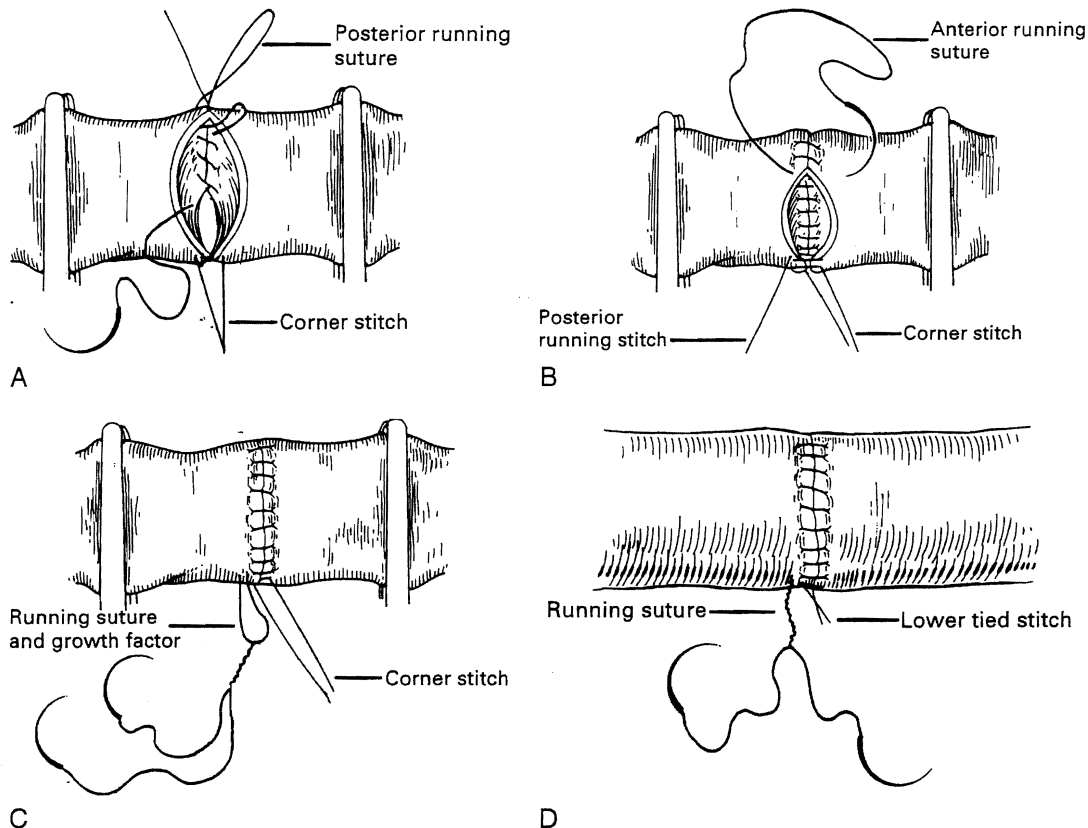


Fig. 111.21. Technique of venous anastomosis. A, Traction sutures are placed at each corner. One end of the far suture is brought to the inside and run in continuous fashion to approximate the back wall. B, The other end of the far suture is used from the outside to approximate the anterior wall. C, The continuous suture is tied away from the vein wall to allow for a growth factor. The near corner suture is tied next to the running suture to prevent separation of the vessel. D, The excess suture is drawn into the vessel, allowing the circumference to expand when blood flow is restored.

techniques were developed to deal with them. Declotting a thrombosed portal vein may be possible (Fig. 111.22A), but if not, iliac or other veins from the donor may be used as interposition grafts (see Fig. 111.22B) or as mesoportal jump grafts (see Fig. 111.22C). A mesoportal graft may be anastomosed end-to-side to the superior mesenteric vein and tunneled through the transverse mesocolon in an avascular plane anterior to the pancreas to reach the hepatic hilum for end-to-end anastomosis to the donor portal vein (see Fig. 111.22C).

Numerous techniques also have been used to restore the hepatic arterial supply. The ideal reconstruction when the allograft and recipient have normal arterial anatomy is shown in Fig. 111.23A. If there are anomalies, vascular injuries, or pathologic changes in the donor or recipient blood vessels that preclude effective rearterialization, grafts obtained from the donor can be used as a last resort (Fig. 111.24; see Fig. 111.23B and C).

Biliary Tract Reconstruction

Good hemostasis must be achieved before the biliary reconstruction is performed. If the recipient duct is disease-free, and if there is a reasonable size match between the donor and

recipient ducts, an end-to-end anastomosis is performed over a T-tube stent (Fig. 111.25). The anastomosis usually is performed with 8 to 10 interrupted absorbable sutures, such as 5-0 or 6-0 polyglycolic acid. Because the integrity of the anastomosis depends primarily on an adequate blood supply of donor and recipient ducts, the duct ends are trimmed back as much as is feasible. A small purse-string suture usually is placed around the T-tube exit site to prevent leakage, and the T-limb is brought out through a stab incision on the lateral side of the recipient duct. Some authorities believe that T-tube stenting is unnecessary.

If the recipient duct is diseased or otherwise inadequate for anastomosis, a choledochojejunostomy is performed. An 18-inch Roux-en-Y limb of proximal jejunum is brought up (usually antecolic) to the hepatic hilum, and the donor duct is anastomosed end-to-side to the jejunal limb using a running or interrupted 5-0 or 6-0 absorbable polyglycolic acid suture over a small internal Silastic stent (see Fig. 111.25, *inset*). The stent is secured in place with a rapidly absorbed fine catgut suture with the assumption that it will later pass spontaneously through the intestinal tract. The stent occasionally becomes stuck, however, and must be pushed out later by an interventional radiologist or removed at laparotomy.

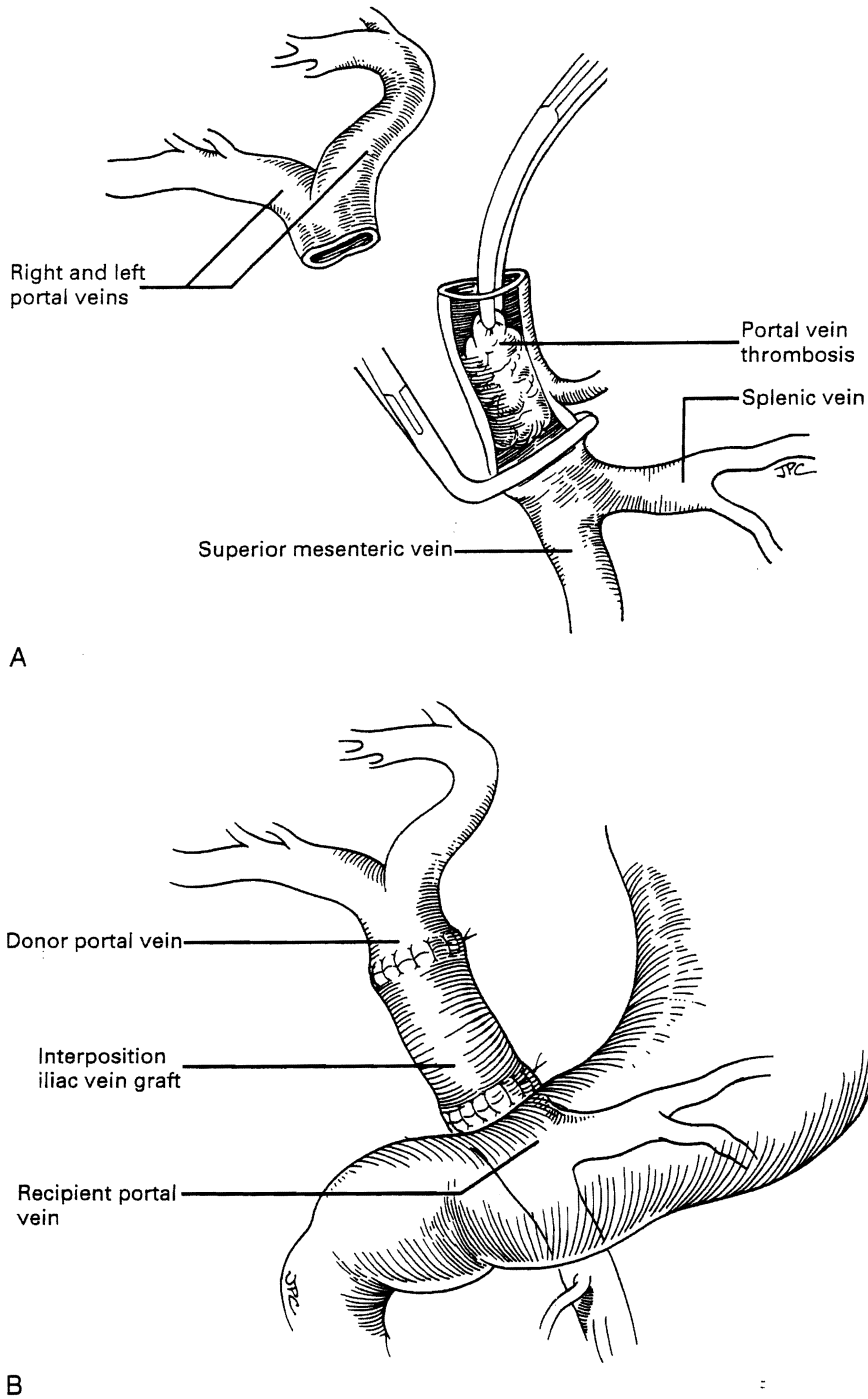


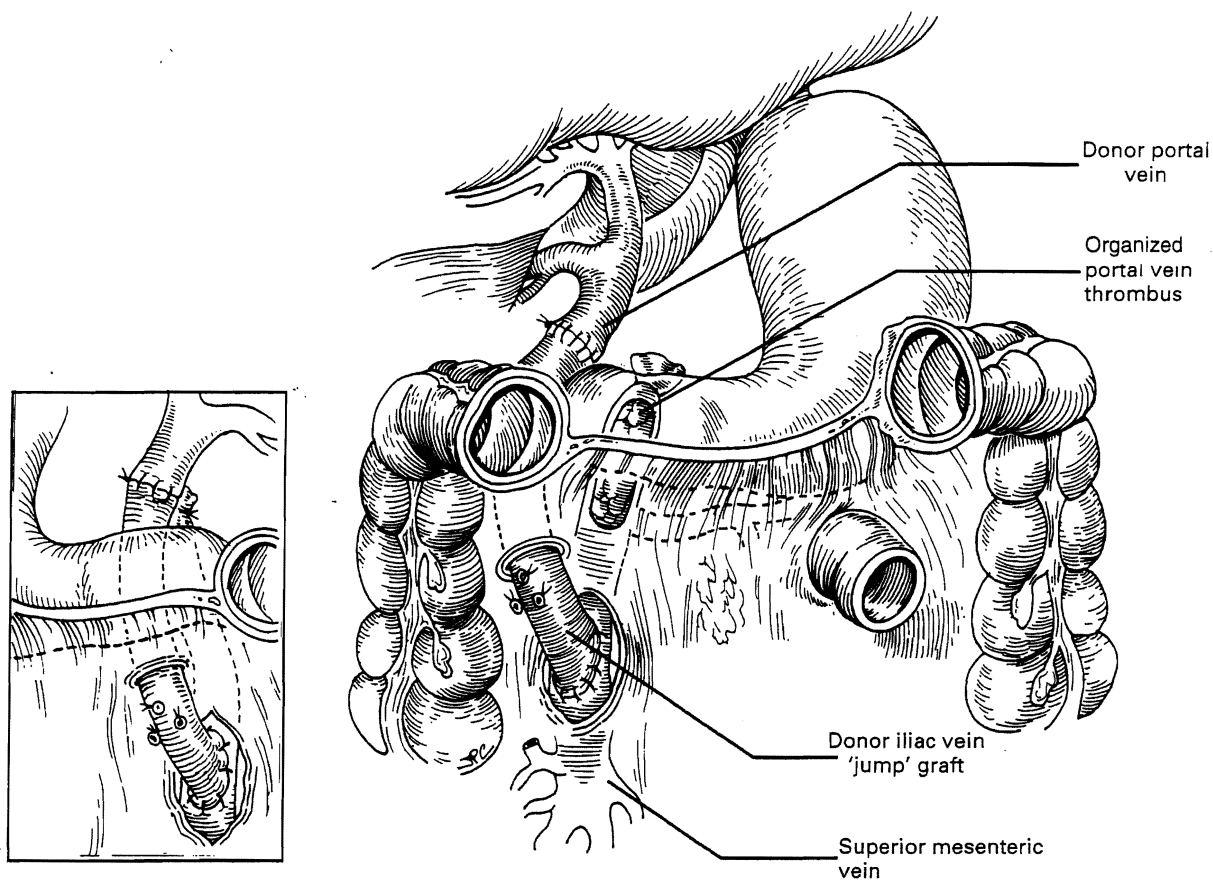
Fig. 111.22. Management of recipient portal vein abnormalities. **A**, Removal of thrombus. **B**, Use of an interposition graft of donor vein (or pulmonary artery) to bridge the gap between donor portal vein and the confluence of the mesenteric and splenic veins.

Continued

REDUCED SIZE LIVER TRANSPLANTATION

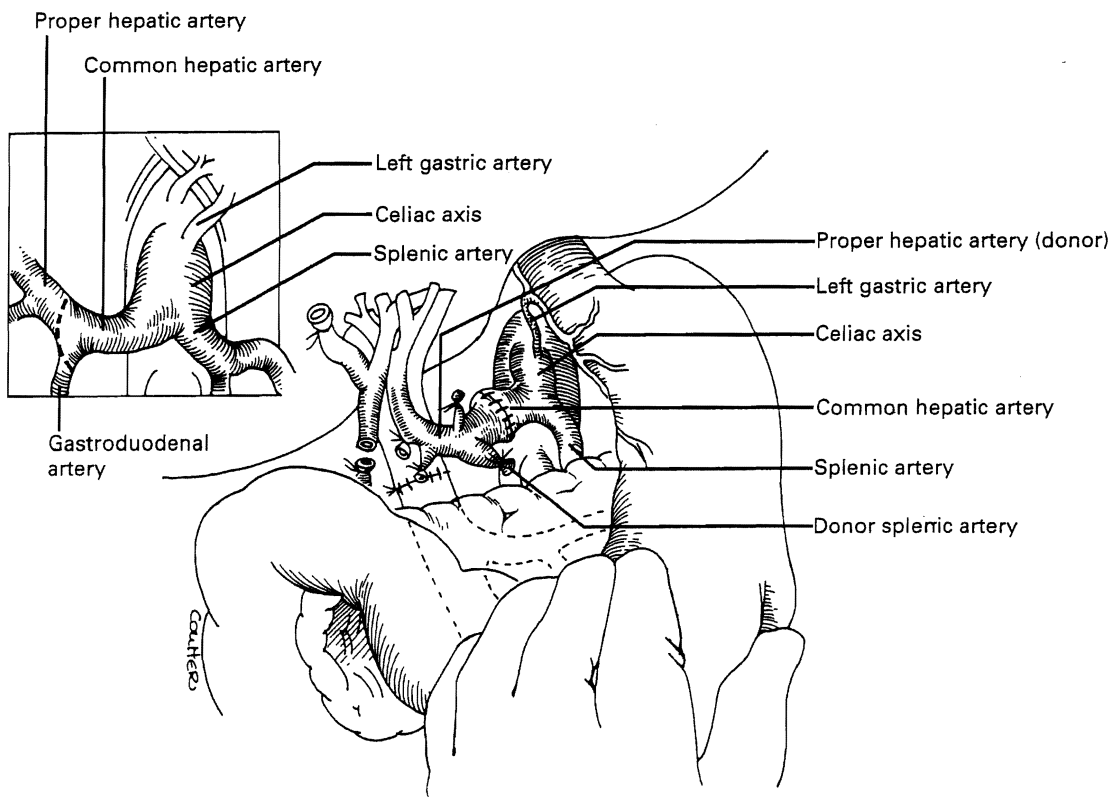
The scarcity of pediatric donors and the constraints of size matching often prohibit transplantation of a whole donor liver in a child or a small adult. Since 1980, the option of using a partial liver has

been exercised at most large transplant centers with results equal to or approaching those achievable with whole liver transplantation. Partial liver transplantation, its application in live donors, and the use of divided cadaveric livers (allowing one organ to be used for two recipients) are described in Chapters 107 and 109.



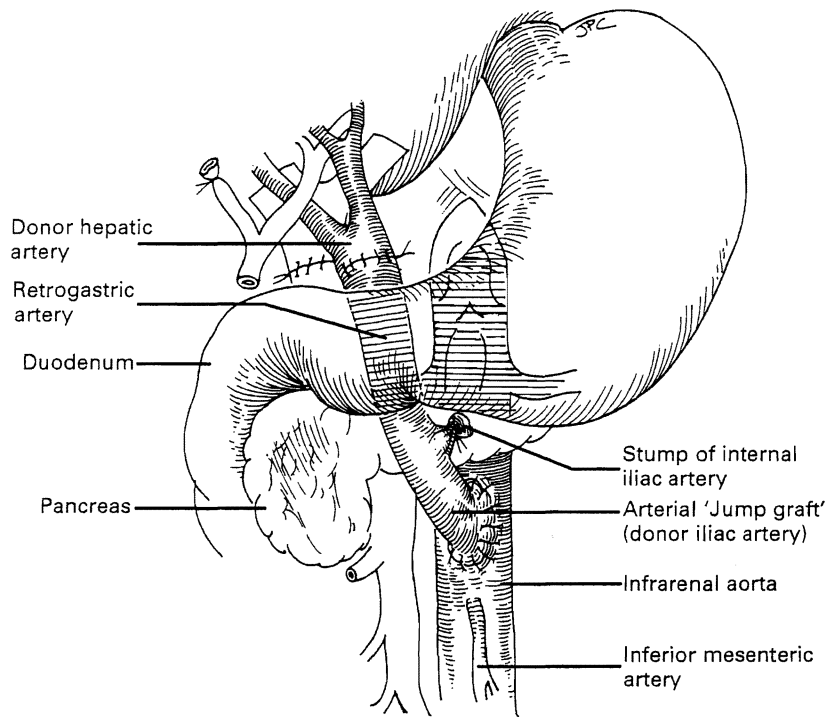
C

Fig. 111.22. cont'd. C, Donor vein jump graft from the host superior mesenteric vein to the graft portal vein. The jump graft is tunneled through the transverse mesocolon in front of the pancreas to the hepatic hilum. The graft can be anterior or posterior (*inset*) to the stomach.

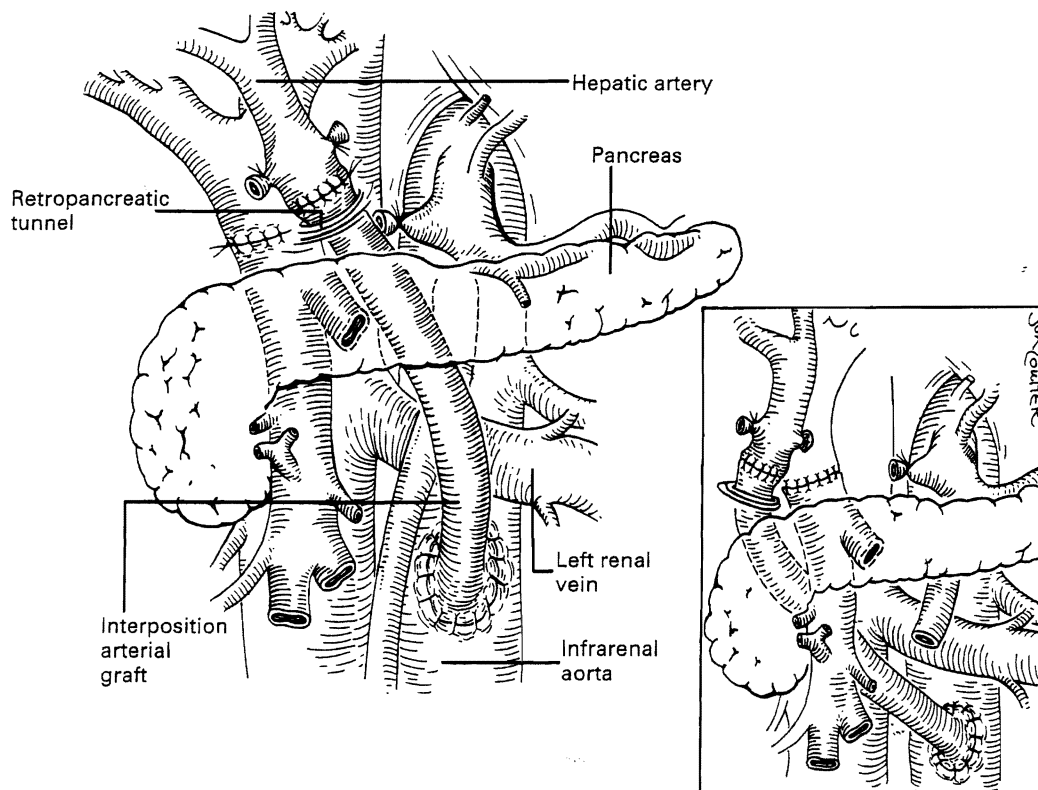


A

Fig. 111.23. Hepatic artery reconstruction. A, Most common reconstruction in which the graft celiac trunk is anastomosed to the recipient common hepatic artery. If there is a size discrepancy, the circumference of the recipient vessel can be increased as shown in the *inset*.



B



C

Fig. 111.23. cont'd. B, Jump graft of donor iliac artery based on the infrarenal aorta and tunneled anterior to the pancreas. C, Rarely used alternative retroperitoneal tunnel posterior to the pancreas and superior mesenteric artery.

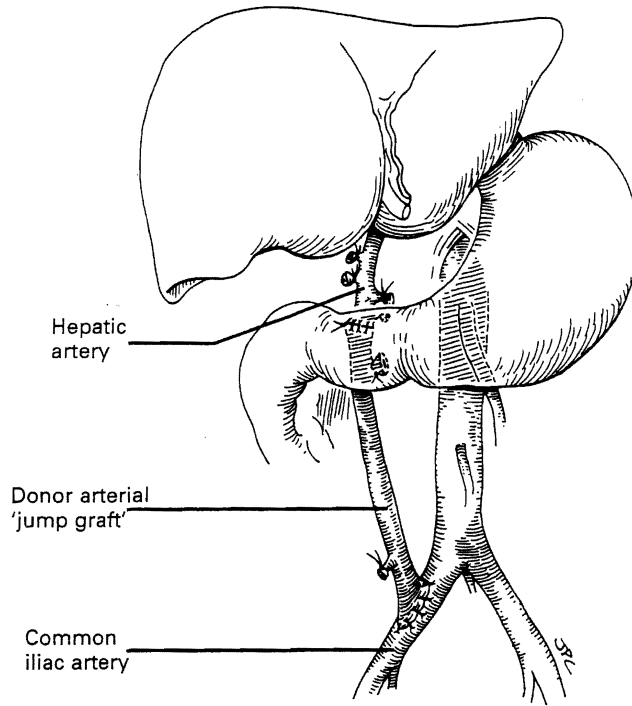
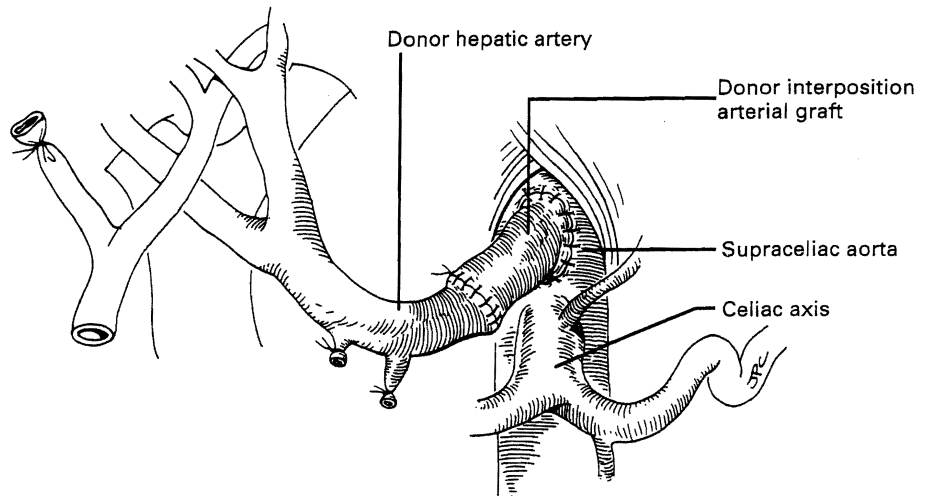


Fig. 111.24. Other originating sites for an arterial jump graft. A, Host iliac artery. B, Supraceliac aorta.

A



B

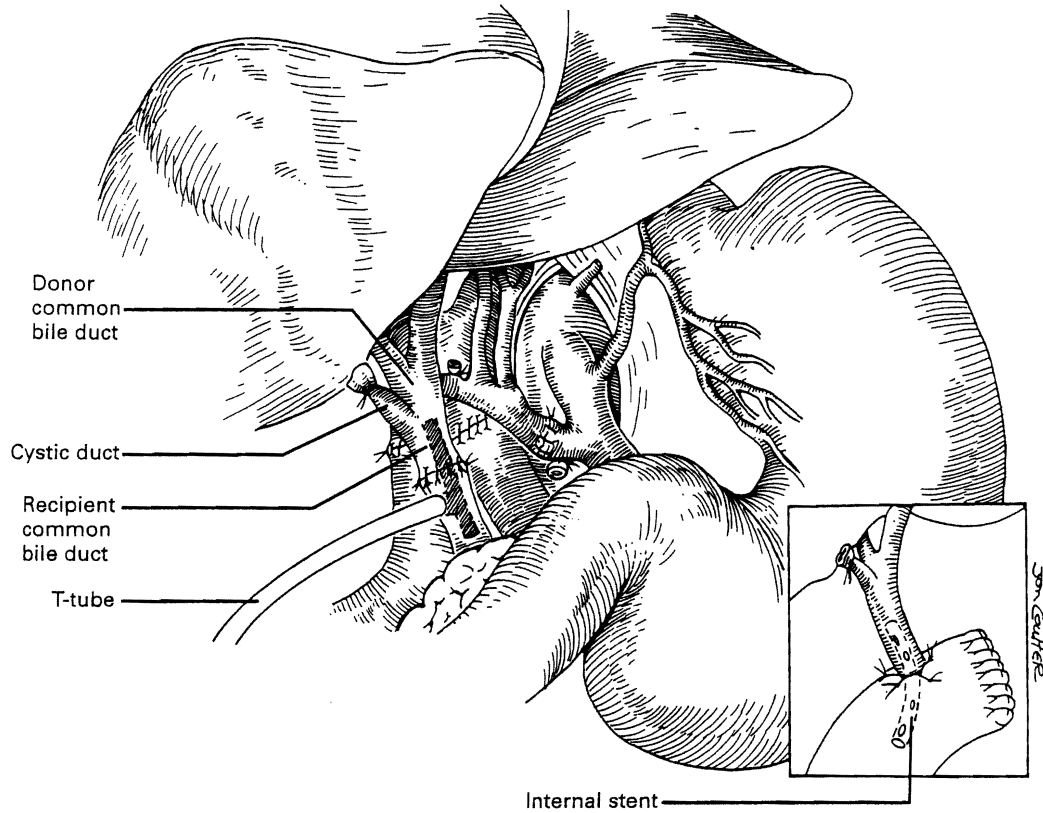


Fig. 111.25. Biliary tract reconstruction with end-to-end anastomosis over a T-tube. If duct reconstruction is not feasible or is contraindicated, the graft duct is anastomosed to a Roux-en-Y limb of host jejunum (*inset*).

REFERENCES

- Starzl TE, 1969: Experience in Hepatic Transplantation [with the assistance of C.W. Putnam]. Philadelphia, Saunders.
- Starzl TE, 2002: The saga of liver replacement, with particular reference to the reciprocal influence of liver and kidney transplantation (1955-1967). *J Am Coll Surg* 195:587-610.
- Starzl TE, et al, 1989: Medical progress: liver transplantation. *N Engl J Med* 321(part I):1014-1022; 321(part II):1092-1099.