

# Cold preservation of the human colon and ileum with University of Wisconsin solution

Kawashima Y, Takeyoshi I, Furukawa H, Lee RG, Starzl TE, Todo S. Cold preservation of the human colon and ileum with University of Wisconsin solution.

Clin Transplantation 1999; 13: 420-425. © Munksgaard, 1999

**Abstract:** The inclusion of the colon in the intestinal graft resulted in worsening patient and graft outcome and increased the incidence of infection and rejection. In this study, we examine the role of ischemia on the barrier function of the epithelium during cold ischemia. Samples were collected from 15 harvested and transplanted human donor grafts (colon, 10; ileum, 6), which were immersed in University of Wisconsin (UW) solution. Ischemia (6, 12, 24, and 48 h) and reoxygenation were performed to evaluate the mucosal electrical status using the Ussing chamber technique. The functions of enterocytes and crypt cells were tested by glucose and theophylline challenge. Modified Park's classification was applied to evaluate the severity of mucosal damage under light microscopy.

The colon had higher levels of baseline potential difference, short-circuit current, and resistance than the ileum during 6-48 h of ischemia. Colonic epithelial cells responded well to theophylline stimulation at 24 h of ischemia, while there was no ileal response. The colonic mucosa was histopathologically well preserved in UW solution for 48 h, and mucosal damage induced by reoxygenation was less than in the ileum. In conclusion, electrophysiologically and histopathologically, the colon is less susceptible to cold preservation damage than the ileum during storage with UW solution.

Intestinal dysfunction, dysmotility, high stomal output, and rapid transit time, resulting in dehydration and malabsorption, complicate the post-operative management of small bowel transplant recipients (1-3). Common anti-diarrhetic agents have not been effective in these cases. Theoretically, the addition of the colon to the composite intestinal graft is a potential surgical solution, and indeed, the efficacy of this approach has been demonstrated both experimentally and clinically (3-5).

Although the sensitivity of the small intestine to warm and cold ischemia has been well studied by morphology and biochemistry (6-10), only a few reports have examined the colon after warm ischemia (11-14). In a canine model employing the Ussing chamber method, we concluded that the colon was more resistant to ischemic insult than the small bowel (15). However, our multivariate risk factor analysis of 71 clinical small transplanta-

**Yoshiyuki Kawashima<sup>a,b</sup>,  
Izumi Takeyoshi<sup>a,b</sup>,  
Hiroyuki Furukawa<sup>a,c</sup>, Randall  
G Lee<sup>a</sup>, Thomas E Starzl<sup>a</sup> and  
Satoru Todo<sup>a,c</sup>**

<sup>a</sup> Thomas E Starzl Transplantation Institute, University of Pittsburgh Medical Center, Pittsburgh, PA. <sup>b</sup> Second Department of Surgery, Gunma University School of Medicine, Gunma. <sup>c</sup> First Department of Surgery, Hokkaido University School of Medicine, Hokkaido, Japan

**Key words:** colon - ileum - ischemia and reoxygenation injury - small bowel transplantation - Ussing chamber

Corresponding author: Yoshiyuki Kawashima, MD, Second Department of Surgery, Gunma University School of Medicine, 3-39-15, Showa-Machi, Maebashi 371-8511, Gunma, Japan.

Accepted for publication 5 April 1999

tion cases revealed that the inclusion of the colon in the intestinal graft resulted in greater graft loss and higher levels of serum tumor necrosis factor (TNF) (1). While we no longer include the colon, there is a need to confirm the change in the barrier function of the epithelium during cold ischemia. In this study, we extend the cold ischemic preservation study to the human colon and ileum in the same manner as in our canine study.

## Materials and methods

### Materials

Fifteen human intestinal grafts were used for this study. Procurement technique was described previously (16). Cold University of Wisconsin (UW) solution, 1-2 L for adult donors or 50-100 mL/kg for pediatric donors, was used for *in situ* flushing of the grafts via the aorta. After flushing, the graft was immersed in cold UW solution until transplan-

tation. Short segments of the ascending colon ( $n = 10$ ) and the distal portion of the ileum ( $n = 6$ ) were harvested just before the transplantation and were also kept in cold UW solution until the examination. All samples, except for one, were taken from different donor grafts.

#### Electrophysiological examination

Electrophysiologic measurements were performed in the same manner as in our canine study (15). Each human intestinal segment was studied electrophysiologically after 6, 12, 24, and 48 h of cold preservation. The ileum and the colon were rinsed with lactated Ringer's solution to remove any remaining luminal contents. The mucosa and submucosa were separated from the seromuscular layer by blunt resection. The separated mucosa and submucosa, without Peyer's patches, were mounted on a 13.5-mm diameter Ussing chamber (World Precision Instrument Inc., Sarasota, FL). When mounted in these chambers, the mucosa and submucosal plane surfaces were perfused with a recirculating oxygenated (95%  $O_2$  and 5%  $CO_2$ ) Krebs-Henseleit buffer solution at a pH of 7.4. The perfusion solution consisted of 120 mM NaCl, 4.7 mM KCl, 1.2 mM  $MgSO_4$ , 2.5 mM  $CaCl_2$ , 25 mM  $NaHCO_3$ , and 1.2 mM  $KH_2PO_4$ . The recirculating reservoirs were maintained at 37°C throughout the experiment. The study was performed in duplicate using two different Ussing chambers.

Equilibration of electrophysiological parameters required 30 min in the ileum and 50 min in the colon. To determine the potential difference (PD), short-circuit current (Isc) and resistance (R), 10 mM D-glucose was added to the perfusion buffer solution recirculating in each cell of the chamber. After an equilibration period, PD and Isc were measured directly every 5 min. R was calculated according to Ohm's law using voltage deflection

measurements of the transmucosal current (50 mA). The values of PD, Isc, and R at 30 min in the ileum and at 50 min in the colon were taken as representative baseline values for each sample. To determine electrophysiologic response to glucose stimulation, 10 mM mannitol was substituted for the glucose in the mucosal-side solution, and Isc was then measured over the next 20 min. After completing the glucose stimulation phase of the experiment, 5 mM theophylline was added in the submucosal-side reservoir, and measurements were continued for another 20 min. Differences between the highest values after stimulation and those before stimulation were determined.

#### Histopathology

Tissues taken at the end of each ischemic period and at the end of reoxygenation in the Ussing chamber were fixed with 10% buffered formalin, embedded in paraffin, cut into 5-mm sections, and stained with hematoxylin and eosin. Blind histopathological analysis was performed by a single pathologist. The severity of mucosal damage in the colon and ileum was graded according to Park's criteria as shown in Table 1 (17, 18). Because the colon lacked villi, these criteria were modified to distinguish the surface and superficial crypt epithelium. Using this modification, grade 4 damage exhibited severe changes, with denudation of villi in the small bowel and loss of superficial cryptal epithelium in the colon. In addition, we also examined the damage of the clinically transplanted ileum and colon, which were biopsied 1 or 2 h after reperfusion, and compared these results with the specimens studied *in vitro*.

#### Clinical course

Post-operative complications occurring within 30 d post-transplantation were examined.

#### Statistics

Values were expressed as a mean  $\pm$  standard error of the mean (SEM). A statistical software package, Stat-View™ (J 4.02, Abacus Concept Inc.), was used for the statistical analyses. In the electrophysiologic functions, Mann-Whitney U test was used for the comparison of the colon and the ileum. In addition, the Wilcoxon signed rank test was used for the comparison of time-related differences for data in each intestine. For the comparison of histopathologic changes of both intestines, the Wilcoxon signed rank test and the  $\chi^2$  test were used. A p value less than 0.05 was considered to be significant.

Table 1. Modified Park's classification

Ileum	Colon
0 Normal	Normal
1 Subepithelial detachment at villous tip	Detachment of intracryptal surface epithelium
2 Extended subepithelial space	Extended surface epithelial detachment
3 Epithelial lifting along villous side	Denudation of surface epithelium
4 Denudation of villi	Loss of superficial cryptal epithelium
5 Loss of villous tissue	Complete loss of cryptal epithelium
6 Infarction of crypt layer	Mucosal infarction
7 Transmucosal infarction	Transmural infarction

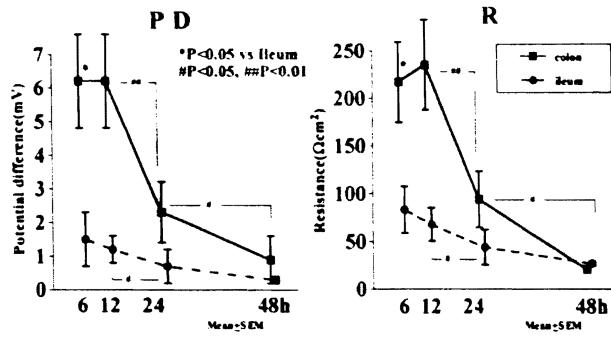


Fig. 1. Potential difference and resistance of the colon and the ileum. \*  $p < 0.05$  versus the ileum. #  $p < 0.05$ . ##  $p < 0.01$ .

**Results**

**Electrophysiology**

PD, Isc (data not shown), and R values were higher in the colon than in the ileum after 6 h of cold ischemia. Although these parameters decreased with duration for both intestines, the values of the colon remained unchanged between 6 and 12 h of ischemia and then decreased during the following 36 h. However, the values in the ileum showed a relatively constant decline during the first 24 h and remained unchanged during the following 24 h. (Fig. 1).

The increased values of Isc ( $\Delta$ Isc) induced by glucose stimulation were detected only in the ileum at 6 h of ischemia. The colon showed no response to glucose stimulation during cold ischemia (Fig. 2). Conversely, the colon showed a significantly greater response to theophylline stimulation than did the ileum at 6, 12, and 24 h of cold ischemia. Similar to the glucose stimulation, the ileum showed only a small response to theophyllin stimulation at 6 h of ischemia and showed no response during the next 42 h of ischemia (Fig. 2).

**Histopathology**

Fig. 3 shows the severity of the epithelial damage. After 6 h of cold ischemia, median mucosal damage of the ileum and that of the colon were grade 2, and most grafts showed varying degrees of edema in the lamina propria of both intestines. After both 12 and 24 h of cold ischemia, median mucosal damage of the ileum was grade 3, and epithelial detachment and villous denudation or destruction became apparent. By comparison, median mucosal damage of the colon was grade 1 after 24 h of ischemia, and the epithelial lining of the colon was well preserved. In reoxygenated tissues, the mucosal damage was evident in both intestines. In the ileum, median mucosal damage of the ileum was grade 4 after 6 h of ischemia, and

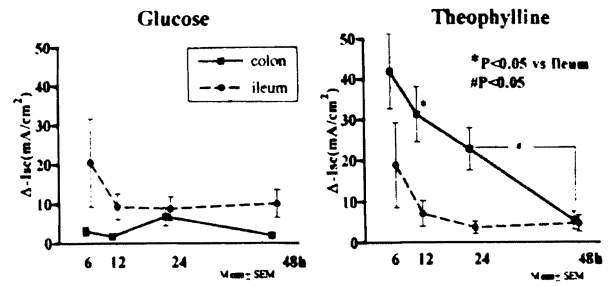


Fig. 2. Glucose and theophylline stimulated  $\Delta$ Isc of the colon and the ileum. \*  $p < 0.05$  versus the ileum. #  $p < 0.05$ . ##  $p < 0.01$ .

the damage to the villi was apparent. In the colon, median mucosal damage was grade 1 and grade 3 after 6 and 24 h of ischemia, respectively, and damage was limited to the surface cell lining and upper part of the crypt. More importantly, damage to the proliferative zone (greater than grade 5) was seen in several samples of the reoxygenated ileal mucosa at every point of ischemia. In the colon, proliferative damage was seen in the reoxygenated mucosa only after 48 h of ischemia.

In comparison with *in vivo* and *in vitro* samples, two of four *in vitro* ileal samples were estimated to be the same grade as the *in vivo* samples, and of the other two samples, one was overestimated by one grade and the other was underestimated by two grades in comparison to the *in vivo* samples. Of the *in vitro* colonic samples, four of six were underestimated by one to three grades compared with the *in vivo* samples, and two were overestimated by one grade. The number of sample was small, and there was no significant difference ( $p < 0.28$ ) in the rate of the underestimation between the colon and the ileum (Fig. 4)

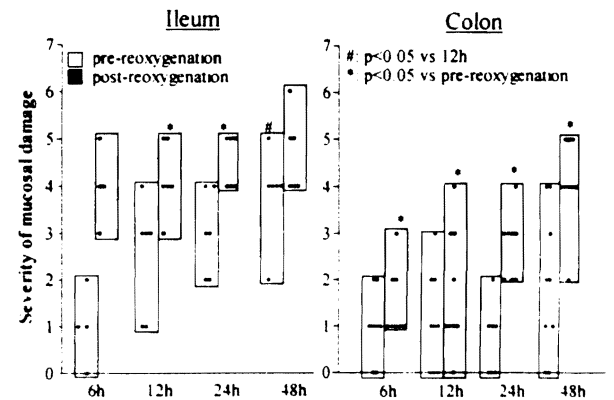


Fig. 3. Severity of mucosal damage induced by preservation and reoxygenation in the colon and the ileum. \*  $p < 0.05$  versus pre-reoxygenation. #  $p < 0.05$  versus 6 h.

## Clinical course post-transplantation

The graft colon was included in the intestinal graft of 14 of 15 recipients. Cold ischemic times ranged from 4.4 to 10.8 h. Three (21%) recipients developed post-operative complications (including respiratory syncytial virus infection, generalized seizures, and acute rejection), of which 2 died within 30 d post-transplantation. The third recipient died of rejection on the fifty-eighth post-operative day. The remaining 12 cases (79%) had no immediate post-operative complications and were able to take nutrition orally post-transplantation.

## Discussion

There are conflicting reports on the usefulness of the colon in intestinal transplantation. Black et al. (4) reported that the colon and ileum transplantation slows transit time, enhances weight gain, improves survival, and protects against bacterial contamination compared with ileum transplantation. Hashimoto et al. (5), co-investigators of Black, reported that the inclusion of the colon in an intestinal graft does not increase the rate of rejection. We reported that the inclusion of the colon in an intestinal graft was a risk factor post-transplantation in a multivariate survival analysis of 71 clinical transplantations (1). Our analysis of these patients showed that the recipients of the colon had higher levels of serum TNF than recipients of the ileum alone (1). TNF, a well-known proinflammatory cytokine, is augmented by rejection, graft versus host disease, or infection (19–21). Endotoxin (ETx) may play an important role for TNF production by macrophages (21). During warm ischemia of the canine colon, ETx, but not bacteria, easily permeated from the lumen to the peritoneal cavity and portal vein after only 30 min of warm ischemia (22). Elevated ETx and TNF levels in the portal blood were also seen at the end of 90 min of low flow ischemia in a rat shock

model (23). The disruption of the epithelial barrier induced by ischemia is thought to allow the permeation of ETx and then to augment TNF production.

We first examined the susceptibility of the canine epithelium in the colon and ileum to warm and cold ischemia using an *in vitro* Ussing chamber (15). This method is advantageous in that it can simulate reoxygenation *in vivo* and also provides an epithelial barrier function for the preserved intestines. The result of our canine study indicated that the colon is more resistant to cold ischemia than the ileum in both electrophysiologic and histopathological examinations during 48 h of preservation.

The colon had higher PD, Isc, and R than the ileum in our fresh canine samples, and the human colon also had higher values at 6 h of preservation. This observation is consistent with that of other investigators (24, 25). Spontaneous PD and Isc depend mainly on active transport processes ( $\text{Na}^+$  pump) regulated by  $\text{Na}^+ - \text{K}^+$  ATPase at the basolateral membrane (BLM) of epithelial cells in the small intestine (26). However, the colon has a more active ion transport, which secretes chloride to the luminal side energetically at the brush border membrane (BBM) (24, 27). The electrical status in the luminal side of the colon is clearly more negative than the ileum. Gazitúa and Robinson (27) investigated the rat colon using an apparatus similar to the Ussing chamber. They estimated that the amount of chloride secretion at the BBM is 5 units ( $1 \text{ unit} = 1 \mu\text{Eq cm}^2 \cdot \text{h}$ ). They also estimated the sodium transport at BBM as 3 units, which is compatible with the amount of sodium transport at BLM by sodium pump. If the sodium transport of the ileum is the same as that of the colon, the ratio of colonic and ileal PD is 8:3 (PD of the colon is 2.7 times higher than that of the ileum). Our canine study revealed that the PD of the colon is 8 mV and the PD of the ileum is 3 mV. This observation was somewhat compatible with the rat colon data. In the human samples, PD, Isc, and R could not be measured at the time of harvesting the donor intestines, but the colon showed significantly higher values in these parameters than the ileum, even after 6 h of ischemia. R is an index of the barrier function to passive ion flow through the paracellular pathway and reflects the integrity of the tight junction between the enterocytes (26). The small bowel epithelium and gall bladder were shown to be 'leaky' (low R) and the skin was 'tight' (high R) in a previous study. The R of the colon is between that of the small bowel and the skin. Using the Ussing chamber, Madara (28) reported that a tight junction increases the depth and

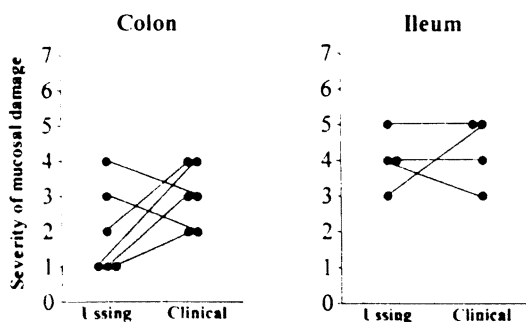


Fig. 4. Comparison of the severity of mucosal damage between *in vitro* and *in vivo* samples in the colon and the ileum.

the number of sealing strand by stimulation from the luminal side with a high osmotic mannitol solution, and changing the integrity of the tight junction is thought to be energy-dependent by cyclic adenosine monophosphate (cAMP). Considering these functional differences, we have concluded that the colon is more resistant to cold ischemic insult than the ileum. Though ischemia induces duration-dependent suppression of electrophysiology in both intestines, the colonic mucosa maintained high responses in the activity of absorptive enterocyte and cryptic cells, even when the ileum ceased these responses. In addition, the colon maintained better histological architecture than the ileum for the same time period.

The cold preservation study of the human colon and ileum showed results similar to our canine study, but the R was different. In dogs, the R of the colon had shown significantly lower values at 36 and 48 h of ischemia than that of the ileum. This was unexpected, but correlated to the permeability test of fluorescein isothiocyanate (FITC)-conjugated dextran (MW = 4400), a good marker of permeability through the paracellular pathway of the epithelium (29). The dog colon became more 'leaky' than the ileum after prolonged preservation. However, the human colon always showed higher values of R than the ileum during cold preservation, suggesting better barrier function in the human colon than in the dog model.

In addition, we have compared the severity of the reperfusion injury between *in vitro* and *in vivo* samples. In the colon, the damage was underestimated in 67% (4/6) of the *in vitro* specimens, while only 25% (1/4) of the ileum specimens were underestimated. The number of samples was small, but the *in vitro* samples from the colon tended to show less damage than the *in vivo* samples. This may be due to the difference of reoxygenation *in vitro* and *in vivo*, such as in blood or bloodless perfusion and or the intravenous or surface perfusion. Further study is needed to evaluate the histopathological damage to the colon. However, the mucosal damage in the human colon is lower than in the ileum, even *in vivo*. The human colon is considered to be more resistant to cold ischemia than the ileum.

Even though the colon has shown better barrier function of the epithelium, it does not explain the high TNF concentration after small bowel transplantation that includes the colon. Alexander et al. (30) proved that the ETx, *E. coli*, and *Candida* took the intracellular pathway through the epithelium as a permeation route in a thermally injured guinea pig and rat model (30). This evidence suggests that small bowel transplantation with or

without the colon always presents the risk of ETx permeation and bacterial translocation post-transplantation. In our clinical results, 79% of 15 small bowel recipients who received the colon were able to take nutrition orally post-transplantation. These transplantations were performed within 12 h from the onset of ischemia. In the 12-h preservation time, the human colon demonstrated better barrier function *in vitro* electrophysiologically and histopathologically, but during 12–24 h, the PD and R declined steeply, with rapid loss of energy. From our data, 12 h of preservation is thought to be safe for transplantation of the small bowel graft that includes the colon. However, further investigation of the barrier function of the epithelium is needed to avoid harmful ETx-derived post-operative complications.

There are two interesting reports using the *in vitro* Ussing chamber method to investigate the barrier function of the epithelium. One report discussed the importance of the mucus gel layer for preventing the attachment of bacteria to the epithelium for translocation (31). The other report noted the rapid restitution of small intestinal epithelium after injury to the villi (32). The latter is an observation specific to the small bowel. Moore et al. (32) reported that exposure to 0.06% Triton X-100 caused injury to the villi, which showed denudation of the villous tip. Two hours after the onset of this injury, as the villi collapsed, the disrupted edge of the epithelium encountered each other and covered the villi, indicating the recovery of electrophysiological status.

In conclusion, our results reveal that the colon is more resistant to cold ischemia than the ileum in both electrophysiologic and histopathological criteria. In addition, the colon was safely transplanted in 79% of our clinical cases within 12 h of cold ischemia. Twelve hours of cold ischemia is thought to be the safe time-frame for small bowel transplantation that includes the colon from our *in vitro* and clinical data. However, the barrier function of the intestinal epithelium needs further study to avoid ETx-derived post-transplant complications.

#### Acknowledgements

Aided by research grants from the Veterans Administration and Project grant no. DK 29961 from the National Institutes of Health, Bethesda, Maryland.

#### References

1. TODO S, REYES J, FURUKAWA H, ABU-ELMAGD K, LEE RG, TZAKIS AG, RAO AS, STARZL TE. Outcome analysis of 71 clinical intestinal transplantations. *Ann Surg* 1995; 222: 270.

1. TODO S, REYES J, FURUKAWA H, ABU-ELMAGD K, LEE RG, TZAKIS AG, RAO AS, STARZL TE. Outcome analysis of 71 clinical intestinal transplantations. *Ann Surg* 1995; 222: 270.
2. ASFER S, ZHONG R, GRANT D. Small bowel transplantation. *Surg Clin North Am* 1994; 74: 1197.
3. TODO S, TZAKIS A, REYES J, ABU-ELMAGD K, FURUKAWA H, NOUR B, CASAVILLA A, NAKAMURA K, FUNG J, DEMETRIS AJ, STARZL TE. Small intestinal transplantation in humans with or without the colon. *Transplantation* 1994; 57: 840.
4. BLACK RT, HASHIMOTO T, ZHONG RZ, BEHME RJ, GARCIA BM, DUFF JH, GRANT DR. Transplantation of segmental rat intestinal grafts including the ileocecal valve and the ascending colon. *Transplantation* 1994; 57: 997.
5. HASHIMOTO T, ZHONG RZ, GARCIA BM, BLACK RT, BEHME RJ, DUFF JH, GRANT DR. Treatment with FK506 prevents rejection of rat colon allograft. *Transplantation* 1994; 57: 1548.
6. FUJIWARA H, RAJU S, GROGAN JB, JOHNSON WW. Organ preservation injury in small bowel transplantation. *J Invest Surg* 1990; 3: 23.
7. SONNINO RE, PRITCHARD T, RIDDLE JM. Limited survival of rat small transplants preserved in University of Wisconsin solution for 48 hours. *J Invest Surg* 1993; 6: 185.
8. THALER W, OBERHUBER G, KLIMA G, MARGREITER R, SCHMID TH. Preservation of small bowel grafts - a comparison with two standard solutions. *Eur Surg Res* 1993; 25: 181.
9. RODRIGEWZ F, TOLEDO-PEREYRA LH, SUZUKI S. Twenty-four-hour total small bowel hypothermic storage preservation and transplantation in the rat: a study of various preservation solutions. *J Invest Surg* 1994; 7: 439.
10. BURGMANN H, RECKENDORFER H, SPERLICH M, SPIECKERMANN PG. Small bowel tissue high-energy phosphate regeneration after 7 hr of cold ischemic storage: comparison of University of Wisconsin and Eurocollins solutions. *J Surg Res* 1995; 58: 193.
11. ROBINSON JW, RAUSIS C, BASSET P, MIRKOVITCH V. Functional and morphological response of the dog colon to ischemia. *Gut* 1972; 13: 775.
12. ROBINSON JW, HAROUD M, WINSTORFER B, MIRKOVITCH V. Recovery of function and structure of dog ileum and colon following two hours' acute ischemia. *Eur J Clin Invest* 1974; 4: 443.
13. ROBINSON JW, MIRKOVITCH V, WINSTORFER B, SAEGESSER LF. Response of the intestinal mucosa to ischemia. *Gut* 1981; 22: 512.
14. MOORE RM, BERTONE AL, MUIR WW, STROMBERG PC, BEARD WL. Histopathologic evidence of reperfusion injury in the large colon of horses after low-flow ischemia. *Am J Vet Res* 1994; 55: 1434.
15. TAKEYOSHI I, ZHANG S, NAKAMURA K, IKOMA A, ZHU Y, STARZL TE, TODO S. Effect of ischemia on the canine large bowel: a comparison with the small intestine. *J Surg Res* 1995; 62: 41.
16. FURUKAWA H, ABU-ELMAGD K, REYES J, NOUR B, TZAKIS AG, TODO S, STARZL TE. Technical aspects of intestinal transplantation. In: Bravermann MH, Tawes RL, eds. *Surgical Technology International, II: Surgical Technology International*. 1994.
17. PARK PO, HAGLUND U, BUCKLEY GB, FALT K. The sequence of development of intestinal tissue injury after strangulation ischemia and reperfusion. *Surgery* 1990; 107: 574.
18. PARK PO, WALLANDER J, TUFVESON G, HAGLUND U. Cold ischemia and reperfusion injury in a model of small bowel transplantation in the rat. *Eur Surg Res* 1991; 23: 1.
19. GRANT D, HURLBUT D, ZHONG R, WANG P, CHEN H, GARCIA B, BEHME R, STILLER C, DUFF J. Intestinal permeability and bacterial translocation following small bowel transplantation in the rat. *Transplantation* 1991; 52: 221.
20. LI X, ZHONG R, QUAN D, ALMAWI W, JEYNIKAR A, GRANT D. Endotoxin in the peripheral blood during acute intestinal allograft rejection. *Transpl Int* 1994; 7: 223.
21. NESTEL FP, PRICE KS, SEEMAYER TA, LAPP W. Macrophage priming and lipopolysaccharide-triggered release of tumor necrosis factor-alpha during graft-versus-host disease. *J Exp Med* 1992; 175: 405.
22. PAPA M, HALPERIN Z, RUBINSTEIN E, ORENSTEIN A, GAFIN S, ADAR R. The effect of ischemia of the dog's colon on transmural migration of bacteria and endotoxin. *J Surg Res* 1983; 35: 264.
23. JIANG J, BAHRAMI S, LEICHTFRIED G, REDL H, LINGR W, SCHLAG G. Kinetics of endotoxin and tumor necrosis factor appearance in portal and systemic circulation after hemorrhagic shock in rats. *Ann Surg* 1995; 221: 100.
24. DAVIS GR, SANTA ANA CA, MORAWSKI SG, FORDRAN JS. Permeability characteristics of human jejunum, ileum, proximal colon and distal colon: results of potential difference measurements and unidirectional fluxes. *Gastroenterology* 1982; 83: 844.
25. POWELL DW. Barrier function of epithelia. *Am J Physiol* 1981; 241: G275.
26. KIRKMAN RL, LEAR PA, MADARA JL, TILNEY NL. Small intestine transplantation in the rat - immunology and function. *Surgery* 1984; 96: 280.
27. GAZITUA S, ROBINSON WL. Ion flux and electrical characteristics of the short-circuited rat colon in vitro. *Pflügers Arch* 1982; 394: 32.
28. MADARA JL. Increase in guinea pig small intestinal transepithelial resistance induced by osmotic loads are accompanied by rapid alterations in absorptive-cell tight junction structure. *J Cell Biol* 1983; 97: 125.
29. PANIZER N, WESTROM BR, LUIS A, LUNDIN S. Regional small-intestinal permeability in vitro to different-sized dextran and proteins in the rat. *Scand J Gastroenterol* 1993; 28: 205.
30. ALEXANDER JW, BOYCE ST, BABCOCK G, GIANOTTI L, PECK MD, DUNN DL, PYLES T, CHILDRESS CP, ASH SK. The process of microbial translocation. *Ann Surg* 1990; 212: 496.
31. MAXSON RT, DUNLAP JP, TRYKA F, JACKSON RJ, SMITH SD. The role of the mucus gel layer in intestinal bacterial translocation. *J Surg Res* 1994; 57: 682.
32. MOORE R, CARLSON S, MADARA JL. Rapid barrier restitution in an in vitro model of intestinal epithelial injury. *Lab Invest* 1989; 60: 237.