

2107

---

TEXTBOOK OF

# CRITICAL CARE

F O U R T H E D I T I O N

---

*Senior Editor*

---

**AKE GRENVIK, MD, PhD, FCCM**

Distinguished Service Professor of Critical Care Medicine  
University of Pittsburgh School of Medicine  
Director Emeritus, Multidisciplinary Critical Care Training Program  
University of Pittsburgh Medical Center  
Pittsburgh, Pennsylvania

*Editors*

---

**STEPHEN M. AYRES, MD, FCCM**

Professor of Medicine  
Dean Emeritus, Medical College of Virginia School of Medicine  
Director, International Health Programs  
Virginia Commonwealth University  
Richmond, Virginia

**PETER R. HOLBROOK, MD, FCCM**

Professor of Anesthesia and Pediatrics  
George Washington University School of Medicine  
Chief Medical Officer  
Children's National Medical Center  
Washington, DC

**WILLIAM C. SHOEMAKER, MD, FCCM**

Professor of Anesthesia and Surgery  
University of Southern California School of Medicine  
Los Angeles, California

**W.B. SAUNDERS COMPANY**

*A Division of Harcourt Brace & Company*

Philadelphia London Toronto Montreal Sydney Tokyo

---

## Intestinal and Multiple Organ Transplantation

Jorge Reyes, MD • Robert Selby, MD  
Kareem Abu-Elmagd, MD, PhD • Satoru Todo, MD  
George V. Mazariegos, MD • Javier Bueno, MD  
Thomas E. Starzl, MD, PhD

The evolution of intestinal transplantation has distantly paralleled that for kidney and liver transplantation. Though the introduction of cyclosporine made other organ transplants a clinical reality, success with intestinal transplantation remained almost nonexistent due to a high incidence of graft loss from rejection, infection, and technical complications.<sup>1</sup>

The experimental studies on intestinal transplantation, reported by Lillehei and colleagues in 1959 as an isolated organ graft in dogs<sup>2</sup> and subsequently by Starzl and Kaupp with the multivisceral graft in dogs (liver, stomach, pancreaticoduodenal complex, small and large intestine),<sup>3</sup> supported a unidirectional paradigm of transplantation and immunology similar to that found after bone marrow transplantation.<sup>4</sup> These experiments predicted that graft-versus-host disease (GVHD) would be precipitated through the immunocytes in the lymphoid-rich major histocompatibility complex (MHC) disparate intestinal allografts.<sup>5</sup>

Numerous attempts at clinical intestinal transplantation, performed after 1964 under azathioprine and steroid and subsequently cyclosporine immunosuppression, were largely unsuccessful. In 1987, a 3-year-old girl received a multivisceral abdominal graft that contained the stomach, duodenum, pancreas, small bowel, colon, and liver; she had an extended survival of 6 months with good intestinal graft function.<sup>6</sup>

A modified application of this operation was the transplantation of a "cluster" of organs in 1989.<sup>7</sup> This allograft consisted of liver and pancreaticoduodenal complex used after upper abdominal exenteration for malignancy (Fig. 184-1). Viability of varying lengths of intestine with these clusters was proven, as was evidence of regeneration after severe rejection-induced injury. The inclusion of the liver in this type of graft was believed to protect the other organs transplanted from the same donor against rejection.<sup>8,9</sup> Consequently, an even longer survival of 1 year was obtained in a recipient of a liver and small-bowel graft treated by Grant and associates.<sup>10</sup> Until 1990, there had been only two survivors of isolated cadaveric intestinal grafting.<sup>11,12</sup>

The success of the new immunosuppressant tacrolimus (FK-506 [Prograf]) in 1989 after clinical trials with liver and kidney transplantation allowed the transplantation of human intestinal grafts (alone or a part of a multivisceral graft) almost with routine success.<sup>13,14</sup> Successful intestinal transplantation then permitted the appreciation of the two-way paradigm of transplantation immunology<sup>15</sup>; it was postulated that two cell populations (of recipient and donor origin) reciprocally modulate immune responsiveness (host-versus-graft and graft-versus-host), including the induction of mutual nonreactivity with consequent organ allograft acceptance.<sup>16</sup>

### INDICATIONS

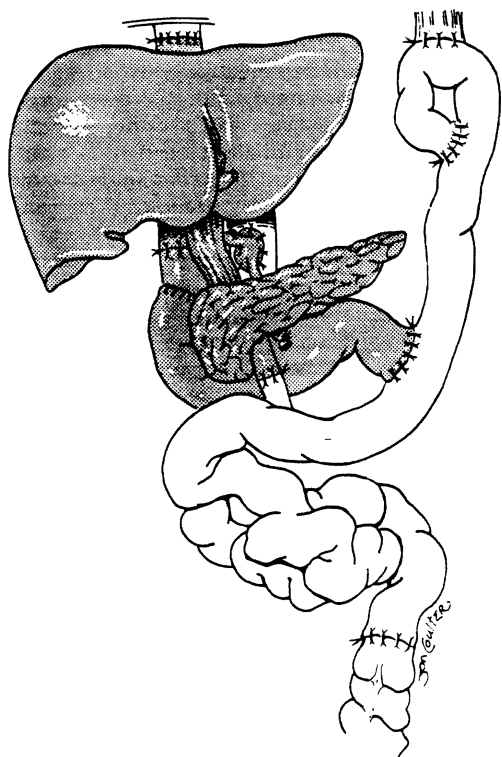
Loss of intestinal function may be acute (e.g., necrotizing enterocolitis, volvulus, mesenteric thrombosis) or chronic

allotransplantation: Experimental and clinical experience. *Ann Surg* 1970; 172:405-436.

4. Land W, Landgraf R, Illner WD, et al: Improved results in combined segmental pancreatic and renal transplantation in diabetic patients under cyclosporine therapy. *Transplant Proc* 1985; 17:317-324.
5. Starzl TE, Iwatsuki S, Shaw B, et al: Pancreaticoduodenal transplantation in humans. *Surg Gynecol Obstet* 1984; 159:265-272.
6. Corry RJ, Nghiem DD, Schulak JA, et al: Surgical treatment of diabetic nephropathy with simultaneous pancreatic duodenal and renal transplantation. *Surg Gynecol Obstet* 1986; 162:547-555.
7. Gruessner RWG: Tacrolimus in pancreas transplantation: A multicenter analysis. *Clin Transpl* 1997; 11:299-312.
8. Dodson F, Pinna A, Jabbour N, et al: Advantages of the rapid en-bloc technique for pancreas/liver recovery. *Transplant Proc* 1995; 27:3050.
9. Nghiem DD, Corry RJ: Technique of simultaneous renal pancreaticoduodenal transplantation with urinary drainage of pancreatic secretion. *Am J Surg* 1987; 153:405-406.
10. Corry RJ, Egidi MF, Shapiro R, et al: Enteric drainage revisited. *Transplant Proc* 1995; 27:3048-3049.
11. Corry RJ, Egidi MF, Shapiro R, et al: Tacrolimus without antilymphocyte induction therapy prevents pancreas loss from rejection in 123 consecutive patients. *Transplant Proc* 1998; 30:521.
12. Gritsch HA, Egidi MF, Sugitani A, et al: Comparison of azathioprine and mycophenolate mofetil in pancreas transplantation. *Transplant Proc* 1998; 30:526.
13. Egidi MF, Corry RJ, Sugitani A, et al: Enteric-drained pancreas transplants monitored by fine-needle aspiration biopsy. *Transplant Proc* 1997; 29:674-675.

### Bibliography

- Ames SA, Bowers VD, Corry RJ: Diagnosis of pancreas transplant rejection: Use of non-invasive tests to assess initial dysfunction in combined pancreas-kidney transplants. *Transplant Proc* 1989; 21:3639-3642.
- Bartlett ST, Schweitzer EJ, Johnson LB, et al: Equivalent success of simultaneous pancreas kidney and solitary pancreas transplantation: A prospective trial of tacrolimus immunosuppression with percutaneous biopsy. *Ann Surg* 1996; 224:440-452.
- Cooper MM, Wright FH, Smith JL, et al: Successful treatment of a high-output fistula with a somatostatin analogue following pancreas transplantation. *Transplantation Proc* 1989; 3738-3741.
- Corry RJ: Pancreatic-duodenal transplantation with urinary tract drainage. *In: Pancreatic Transplantation*. Groth C (Ed). London, Grune & Stratton, 1988, pp 147-153.
- Corry RJ, Zehr P: Quality of life in diabetic recipients of kidney transplants is better with the addition of the pancreas. *Clin Transplant* 1990; 4:238-241.
- Douzdjian V, Abecassis MM, Cooper JL, et al: Incidence, management and significance of surgical complications after pancreatic transplantation. *Surg Gynecol Obstet* 1993; 177:451-456.
- Gaber AO, El-Gebely Sdiman, Sugartran P, et al: Early improvement in cardiac function occurs for pancreas-kidney but not diabetic kidney alone transplant recipients. *Transplantation* 1995; 59:1105-1112.
- Georgi BA, Bowers VD, Smith JL, et al: Comparison of cholesterol levels between diabetic recipients: Pancreas-kidney and kidney transplantation. *Diabetes* 1989; 38 (Suppl 1):260-261.
- Marsh CL, Perkins JD, Sutherland DER, et al: Combined hepatic and pancreaticoduodenal procurement for transplantation. *Surg Gynecol Obstet* 1989; 168:254-258.
- Nghiem DD, Pitzen RH, Corry RJ: Evaluation of techniques for controlling exocrine drainage after segmental pancreatectomy in dogs: Implications for pancreatic transplantation. *Arch Surg* 1985; 120:1132-1137.
- Nghiem DD, Gonwa TA, Corry RJ: Metabolic effects of urinary diversion of exocrine secretions in pancreas transplantation. *Transplantation* 1987; 43:70-73.
- Nghiem DD, Schulak JA, Corry RJ: Duodenopancreatectomy for transplantation. *Arch Surg* 1987; 122:1201-1206.
- Smith JL, Hunsicker LG, Yuh WTC, et al: Appearance of type II diabetes mellitus in type I diabetic recipients of pancreas allografts. *Transplantation* 1989; 47:304-311.



**Figure 184-1.** Cluster allograft (shaded portion), including the liver, pancreas, and duodenal segment of small intestine. (From Starzl TE, Todo S, Tzakis A, et al: Abdominal organ cluster transplantation for the treatment of upper abdominal malignancies. *Ann Surg* 1989; 210:374-386.)

(e.g., Crohn's disease, radiation enteritis). Disease classification can be better viewed with an arbitrary division of *surgical* (short gut) and *nonsurgical* etiologic factors. Patients with surgical causes generally suffer from loss of bowel length after resections for atresias, infarctions (e.g., volvulus, vascular catastrophes, necrotizing enterocolitis), or strictures and fistulas as with Crohn's disease. With nonsurgical causes of intestinal failure, the anatomic length and gross morphology may be normal. These causes include motility disorders (e.g., intestinal pseudo-obstruction, Hirschsprung's disease), absorptive insufficiencies (e.g., microvillus inclusion disease), polyposis syndromes, and "incarcerating" desmoid tumors.

Total parenteral nutrition (TPN) is the standard of care for patients who are unable to maintain a normal nutritional state by use of the gastrointestinal tract alone (intestinal failure).<sup>17</sup> Transplantation of the intestine, either alone or accompanied by other intra-abdominal organs (liver, stomach, pancreas), may be beneficial in patients who do not respond to this therapy. The stability and duration of TPN support are variable, and failure of TPN can manifest with complicating factors, such as infection, metabolic disorders, difficulty with vascular access (from extensive venous thrombosis), and liver cirrhosis with end-stage liver disease. This has resulted in an inestimable rate of morbidity and mortality.

The decision regarding allograft composition focuses on the integrity of the remaining gut and other abdominal organs, both functionally and anatomically. Guidelines used in substantiating the need for concomitant liver replacement in these intestinal transplantation candidates are:

- Biochemical dysfunction (hyperbilirubinemia, transaminase abnormalities, hypoalbuminemia, and coagulopathy)
- Pathologic processes (fibrosis or cirrhosis on liver biopsy)

**TABLE 184-1. Partial and Complete Intestinal Allografts**

Organ Transplanted	Indication
Multivisceral (stomach, duodenum, pancreas, liver, small bowel, colon)	Pseudo-obstruction/aganglionosis syndrome with hepatic failure; diffuse splanchnic venous thrombosis and hepatic failure
Liver and small intestine	Hepatic failure after prolonged hyperalimentation for short gut syndrome
Liver, duodenum, and pancreas (organ cluster transplantation)	After upper abdominal exenteration for malignancy
Small intestine	Congenital or acquired absence or dysfunction

- The clinical presence of portal hypertension, as manifested by hepatosplenomegaly, ascites, or esophageal varices and portal hypertensive gastroenteropathy

Patients deficient in protein S, protein C, and antithrombin III (liver-derived) may be candidates for a combined liver/small intestine allograft in the absence of clinical liver disease.<sup>18</sup> Recipients lacking these substances experience diffuse thromboses within the splanchnic system and undergo transplantation for mesenteric venous hypertension rather than for intestinal failure. Patients with motility disorders or neoplasms that involve extensive lengths of the gastrointestinal tract are also candidates for replacement of this entire system (Table 184-1).

Table 184-2 lists the causes of intestinal failure in patients who have undergone transplantation at the University of Pittsburgh. Inability to continue TPN because of the development of hepatic cirrhosis or venous access limitations were the most frequent indications for transplantation.

## ABDOMINAL VISCERAL PROCUREMENT

The grafts were obtained from ABO-blood type identical brain-dead donors; matching of human leukocyte antigen (HLA) was random. No attempts were made to modulate the lymphoid tissue in the intestinal allograft by either irradiation or anti-lymphoid antibody treatment. University of Wisconsin solution was used for graft preservation.

The safe procurement of multiple visceral organs, either en bloc or as separate components, hinges on a few fundamental precepts. Conceptually, the focus is to isolate and cool the organs, thus preserving their vascular and parenchymal anatomy and function. Multivisceral en bloc retrieval, including the stomach, duodenum, pancreas, liver, and small intestine,

**TABLE 184-2. Indications for Composite and Isolated Intestinal Transplantation in 98 Patients at the University of Pittsburgh (May 1990 to August 1997)**

Pediatric Patients (60)		Adult Patients (38)	
Necrotizing enterocolitis	6	Crohn's disease	8
Gastroschisis	16	Thrombotic disorder	13
Volvulus	15	Trauma	7
Pseudo-obstruction	6	Pseudo-obstruction	1
Hirschsprung's disease	4	Radiation enteritis	1
Intestinal atresia	8	Desmoid tumor	4
Microvillus inclusion disease	3	Familial polyposis	1
Trauma	1	Volvulus	1
Intestinal polyposis	1	Gastrinoma	1
		Ulcerative colitis	1

is the parent operation, and the assembled components have been likened by Starzl and colleagues to a large clump of individual grapes from the whole.<sup>19</sup> An appreciation of the fundamental strategy of multivisceral organ retrieval leads to an understanding of the lesser variant operations (i.e., liver, small intestine, combined liver/small intestine, and organ cluster—liver, duodenum, and pancreas—transplantation). A more complete discussion of the specifics of organ procurement is presented in Chapter 177.

## RECIPIENT OPERATIONS

Most patients who need intestinal or multiorgan replacements have undergone multiple forays into the abdominal cavity for intestinal resections, lengthening procedures, and treatment of complications. This results in volume contraction of the abdominal cavity and severe adhesions. Consequently, the organs of the donor need to be smaller than those of the recipient to ensure proper abdominal closure. This allows for donor weight discrepancies of usually no greater than 20% than the recipient weight unless graft reduction can be surgically accomplished.

Previous operations may complicate the removal of the recipient's organs, especially if cirrhosis, portal hypertension, or inferior vena caval thromboses are present, all of which may be sequelae of the original disease or of prior operations. The recipient operation consists of removal of the failed organs with exposure of the vascular anatomy and, finally, allograft implantation. Following is a brief description of the salient features of the recipient operations.

## Multivisceral Transplantation

After abdominal exenteration and exposure of the retroperitoneal aorta and inferior vena cava have been performed, the multivisceral graft (Fig. 184-2A) is connected by its vascular attachments: first the suprahepatic attachment, then infrahepatic vena caval connections (or "piggyback" to the skeletonized recipient vena cava), and finally the arterioaortic anastomosis (using an aortic interposition homograft). The

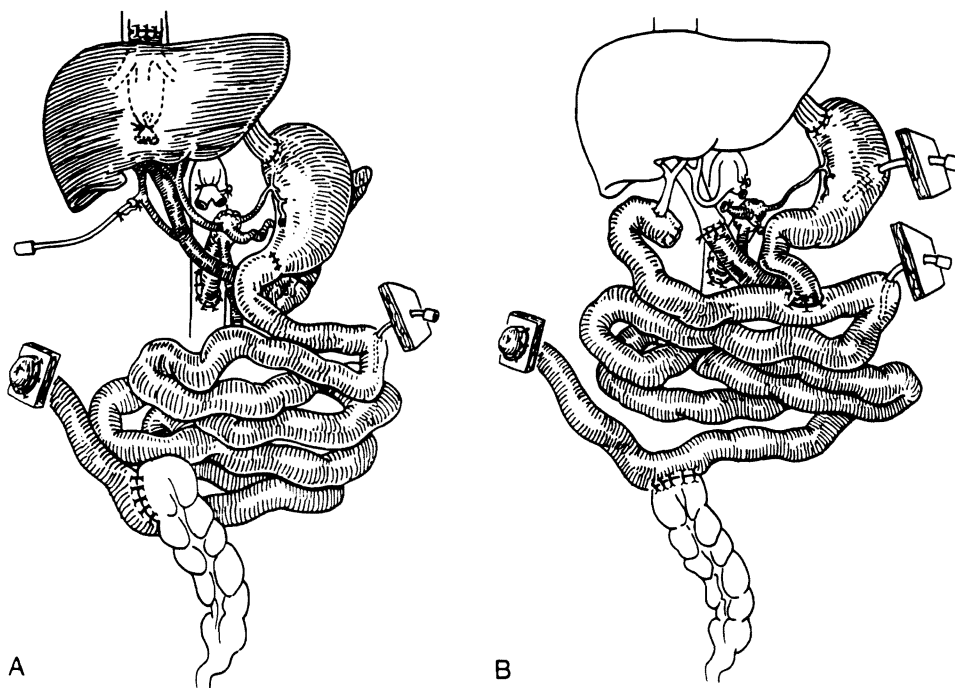
recipient's portal vein and its inflow organs (gastrointestinal tract, pancreas, and liver) are removed with the enterectomy. The donor portal vein retains its continuity via the liver in the procurement of the allograft; thus, no portal vein anastomosis is required in this procedure. Patients with a normal native liver can receive a modified multivisceral procedure that excludes the allograft liver as part of the composite of organs, with portal venous return directed into the recipient's portal vein (Fig. 184-2B).

Restoration of intestinal continuity requires an esophagogastric anastomosis and a coloenteric anastomosis with the distal ileum allograft. Initially, the patient also receives an ileostomy. Takedown of the ileostomy can be performed after several months, when oral nutrition is consistently adequate, a stable immunosuppressant regimen has been achieved, and there is no further need for frequent endoscopic surveillance.

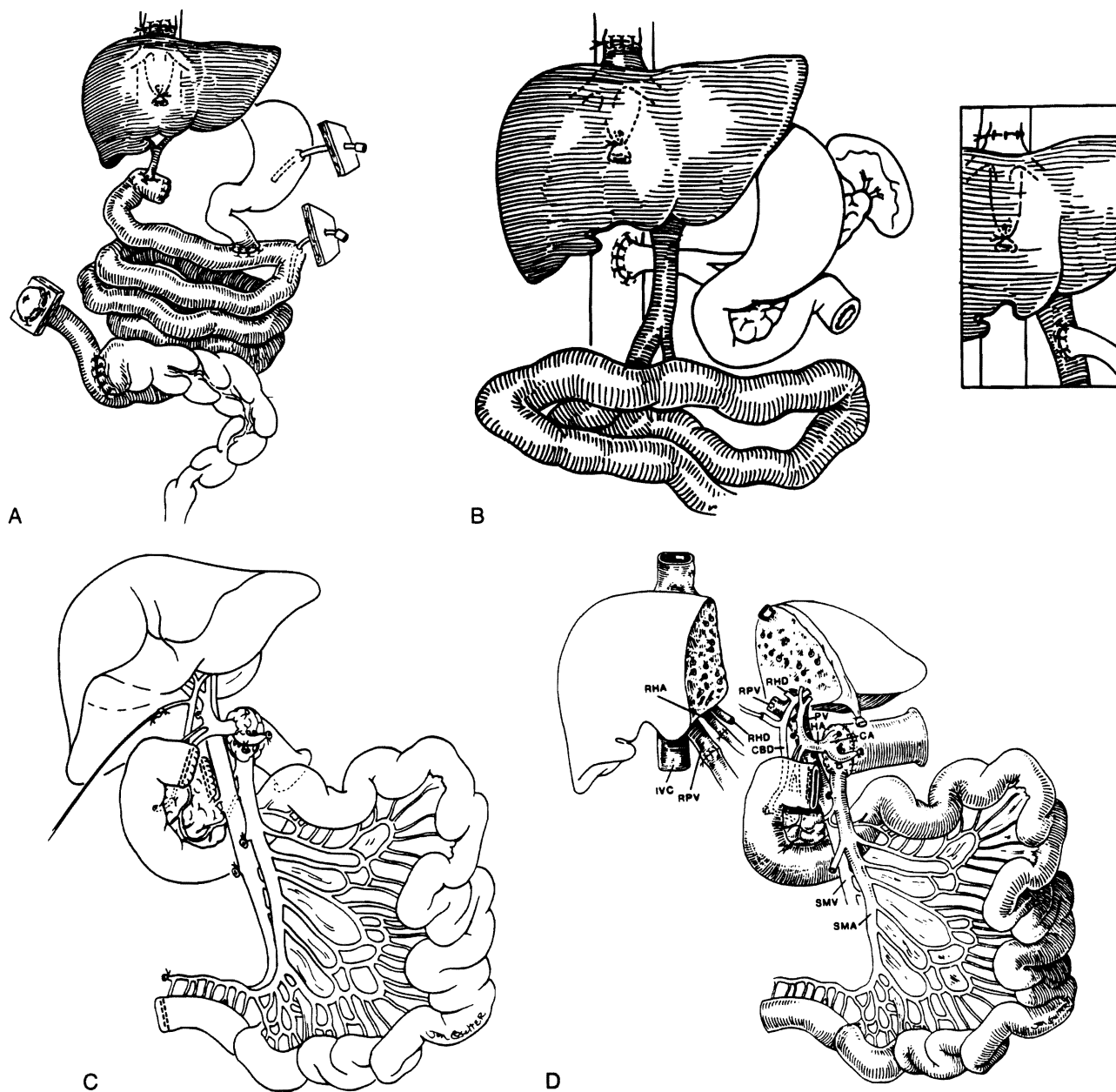
## Liver and Small Bowel

Liver and small intestine are removed in these patients, but the remainder of the foregut (stomach, duodenum, pancreas) is retained. When possible, the liver is removed with the retrohepatic vena cava preserved in situ.<sup>20</sup>

After the enterectomy, the composite allograft is implanted by anastomosing the suprahepatic vena cava of the donor, including the hepatic veins (so-called piggyback liver transplantation) end-to-side to the recipient's vena cava; the donor infrahepatic vena cava can then be ligated (Fig. 184-3A). The double arterial stem of the celiac and superior mesenteric arteries (via the Carrel patch technique) is connected to the infrarenal aorta (with an aortic conduit or iliac artery homograft), with subsequent graft reperfusion. Because the axial stem of the portal vein between the donor organs has remained intact, all that is required for the completion of portal flow is attachment of the portal vein of the remnant foregut in the recipient to the intact portal stem of the donor. This may not be possible, however, because of size discrepancy or difficult anatomic relationships between donor and recipient portal veins. In this case, a permanent portocaval shunt is performed (Fig. 184-3B). The intestinal anastomoses are then



**Figure 184-2.** Diagrams of multivisceral donor organs: complete multivisceral (A) and modified multivisceral (B). (From Reyes J, Bueno J, Kocoshis S, et al: Current status of intestinal transplantation in children. *J Pediatr Surg* 1998; 33:243-254.)



**Figure 184-3.** Modifications of the liver/small intestinal allograft.

*A.* Combined liver/small intestinal allograft.

*B.* Systemic porta caval shunt or recipient portal vein to donor portal vein shunt (*inset*) allows venous outflow of retained pancreas and stomach from recipient. (From Reyes J, Bueno J, Kocoshis S, et al: Current status of intestinal transplantation in children. *J Pediatr Surg* 1998; 33:243-254.)

*C.* Composite liver and intestine graft with preservation of the duodenum in continuity with the graft jejunum and hepatic biliary system. The allograft pancreas is transected to the right of the portal vein. (From Abu-Elmagd K, Reyes J, Todo S, et al: Clinical intestinal transplantation: New perspectives and immunologic considerations. *J Am Coll Surg* 1998; 186:512-527.)

*D.* *In situ* split liver graft that maintains the left lateral segment in continuity with the hepatic hilus and duodenum, with transection of allograft pancreas. (From Reyes J, Fishbein T, Bueno J, et al: Reduced sized orthotopic composite liver. Intestinal allograft: Rationale and *in situ* split technique in an initial experience. *Transplantation* 1998; 66:489-492.)

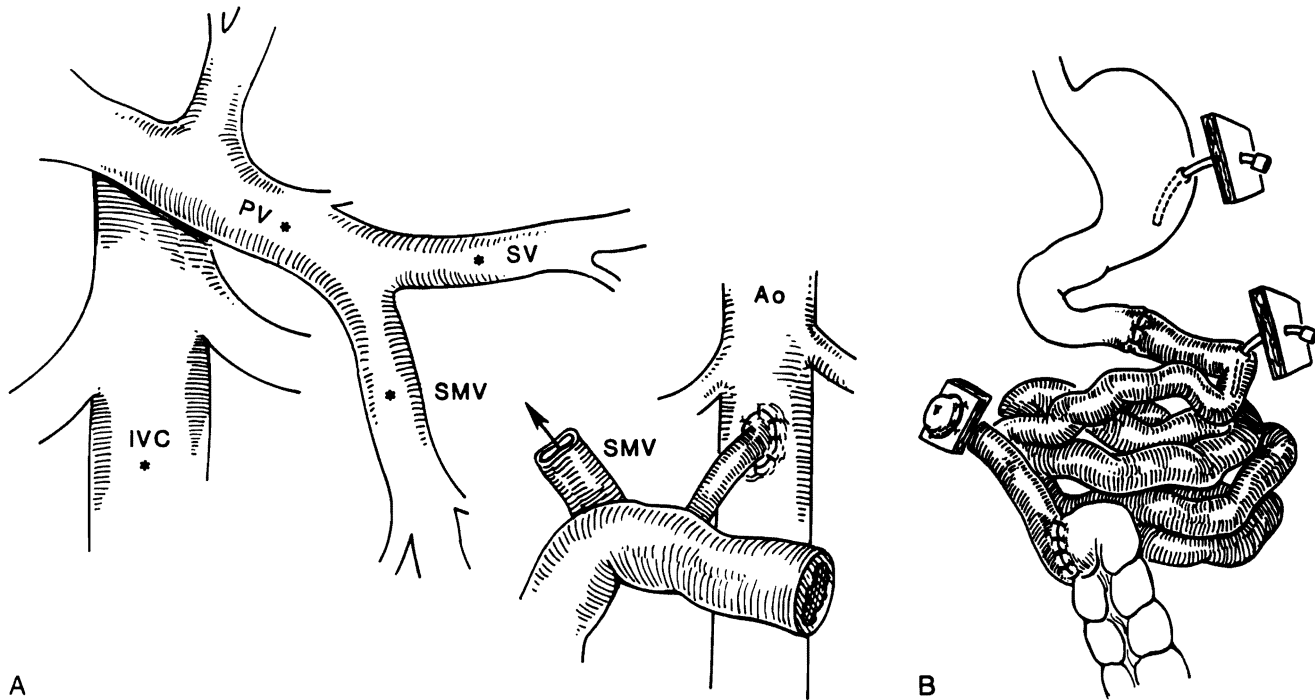
completed with a proximal jejunojejunostomy, an ileocolostomy, a temporary distal ileostomy, and a Roux-en-Y biliary anastomosis.

To avoid a biliary anastomosis (with its potential for complications), a modification of the original "cluster" allograft, as depicted in Figure 184-1, has been applied to the liver/small-bowel allografts. Here, the allograft duodenum remains in continuity with the allograft biliary system and varying lengths of allograft jejunum-ileum (Fig. 184-3C). In one such graft, a

reduced segment of allograft liver (the left lateral segment) was successfully used after an *in situ* split was performed to overcome a donor-recipient size mismatch in a critically ill pediatric recipient (Fig. 184-3D).

### Isolated Small Bowel

In cases of surgical short gut, the proximal and distal remnants of the intestine are identified; when there is functional disease



**Figure 184-4.** A, Arterialization and potential venous drainage options of the isolated small intestine allograft. B, Isolated small-bowel graft; the distal ileal chimney allows easy access to bowel mucosa. PV = portal vein; SV = splenic vein; SMV = superior mesenteric vein; IVC = inferior vena cava. (From Reyes J, Bueno J, Kocoshis S, et al: Current status of intestinal transplantation in children. *J Pediatr Surg* 1998; 33:243-254.)

or neoplasm, the recipient's diseased small intestine is removed. The superior mesenteric artery of the donor bowel is sewn to the infrarenal aorta, and the donor superior mesenteric vein to the recipient portal vein, superior mesenteric vein, splenic vein, or inferior vena cava (Fig. 184-4A). This may be facilitated by the use of an interposition venous graft. Reperfusion of the intestinal graft is effected after the vascular anastomoses. Intestinal continuity is completed with proximal and distal anastomoses, and access to the ileum for endoscopic examination is provided by a temporary "chimney" ileostomy (Fig. 184-4B).<sup>21</sup>

*Cold ischemia* refers to the time between procurement and implantation of the allograft and has ranged from 2.8 to 17 hours. *Warm ischemic time* for the allograft (sewing-in time) is about 30 minutes and is also a determinant of preservation injury to the intestine. In an attempt to reduce graft dysmotility, a segment of large intestine was included in 32 allografts. This technique was abandoned after 1994, and subsequently the enteric and celiac ganglia have been preserved for the last 16 grafts.

## IMMUNOSUPPRESSION

Immunosuppression is similar in recipients of small-bowel, liver/small bowel, cluster, and multivisceral transplants. Intravenous methylprednisolone is given immediately after graft reperfusion (1 g in adults, 10 mg/kg in children). Administration of tacrolimus (0.15 mg/kg/day) is then begun by continuous intravenous infusion, with steady-state whole blood levels (microparticle enzyme immunoassay) between 15 and 25 ng/mL as targets. A steroid taper of methylprednisolone is started at a dose of 5 mg/kg/day (for children) or 200 mg/day (for adults) and reduced over a period of 5 days to 1 mg/kg/day (for children) or 20 mg/day (for adults). In some cases, azathioprine may be added to mitigate the nephrotoxicity and

neurotoxicity of tacrolimus. A series of 23 patients completed a trial of cyclophosphamide (Cytosan), which was given at a dose of 2 mg/kg/day for 4 weeks. The patients were then switched to mycophenolate mofetil (15 to 30 mg/kg/day) or azathioprine (1 to 2 mg/kg/day). As gastrointestinal motility resumes, oral tacrolimus given twice daily may be used to supplement the intravenous regimen, which is gradually tapered.

Induction therapy as well as chronic maintenance therapy involves the use of two and often three drugs. If organ tolerance with minimal rejection episodes is demonstrated, however, gradual reduction and even cessation of steroid therapy may be possible.

Prostaglandin E<sub>1</sub> (Prostin) is administered, 0.003 to 0.009 mg/kg/min, for the first 5 postoperative days. This is given for its beneficial effects on renal perfusion as well as its prevention of microvascular thromboses, the damage-mediating event in acute cellular rejection and procurement injury.<sup>22</sup> Rejection was treated with optimization of tacrolimus level, supplemental steroids, and, if necessary, OKT3.

## BONE MARROW AUGMENTATION

The phenomenon of donor and recipient cell migration observed in this patient population was later confirmed to occur after transplantation of all solid organs. These "chimeric" composites form the basis of the two-way paradigm of transplantation immunology, with mutually canceling effects of donor and recipient cell populations producing eventual allograft acceptance.<sup>15</sup> According to this hypothesis, augmentation of leukocyte chimerism was performed with unaltered adjuvant donor bone marrow cells recovered from donor thoracolumbar vertebral bodies and infused postoperatively in a single infusion of  $3$  to  $5 \times 10^6$  cells/kg body weight, as previously described.<sup>23, 24</sup>

Monitoring of *chimerism* (the presence of donor cells) was performed serially after transplantation using the recipient's peripheral blood by either flow cytometry or polymerase chain reaction (PCR).<sup>25</sup> Graft-versus-host disease (GVHD) surveillance was studied in all suspected skin and gastrointestinal lesions by routine histology, with the detection of donor cells by immunohistologic staining for donor-specific human leukocyte antigen (HLA) antigens, and in situ hybridization technique using the Y-chromosome-specific probe, as previously described.<sup>15</sup>

## POSTOPERATIVE CARE

Recipients of multivisceral, liver/small-bowel, or cluster grafts commonly suffer from severe liver failure. Therefore, the care with respect to lungs, infection surveillance, and liver graft function is similar to that for routine liver transplant recipients. Recipients of isolated small-bowel transplants who have stable liver function have a lesser preoperative medical acuity.

## Ventilatory Management

Extubation can often be accomplished within 48 hours of transplantation. Unusual circumstances, such as graft malfunction, sepsis, inability to close the abdominal wall, and severe preoperative hepatic failure, may prevent early extubation. Because the operation is quite long (8 to 18 hours) and the patients are often in a weakened nutritional state preoperatively, a careful assessment of weaning parameters is required. The inspiratory force, forced vital capacity, and spontaneous minute ventilation are most important. It is wise to observe the patients for several hours while they remain intubated on continuous positive airway pressure (CPAP) to make certain that they can tolerate the withdrawal of mechanical support and extubation.

Incisional pain, ascites, and pleural effusions may compromise ventilation and the ability to cough. Muscle wasting and malnutrition, partial or complete paralysis of the right hemidiaphragm,<sup>26</sup> and occasional discrepancies in donor-recipient size that produce an increased intra-abdominal volume with compression of the thoracic cavity may be factors responsible for respiratory impairment. These patients often require low doses of intravenous narcotics, repeated thoracentesis and paracentesis, and supplemental extensive respiratory therapy if they are to avoid the need for reintubation.

Many patients have required tracheostomies because of the need for prolonged ventilatory support. Rarely (two cases), severe rejection of isolated small intestine allografts with systemic venous drainage into the inferior vena cava has been heralded by respiratory insufficiency and picture of acute respiratory distress syndrome (ARDS).

## Renal Function

Most intestinal transplant candidates have experienced some measure of renal injury due to multiple episodes of infection, antibiotic requirements, and liver failure. Early after transplantation, there is significant interstitial accumulation of fluid into the graft, lung, and peripheral tissues; this accumulation peaks at 48 to 72 hours. Extensive volume shifts into the transplanted bowel (related to preservation injury) and heavy ascites production (related to mesenteric lymphatic leakage) lead to intravascular volume depletion and can exacerbate the nephrotoxicity of tacrolimus and certain antibiotics. Continuous central venous pressure measurement, often for weeks following transplantation, provides important information for maximizing graft perfusion and preserving the integrity of the

kidneys. Two children have undergone inclusion of an allograft kidney with their primary intestine transplant, and one long-term pediatric survivor has required sequential kidney transplantation.

## Infection Control

Recipients of isolated or composite small-bowel grafts receive prophylactic, broad-spectrum intravenous antibiotics. Any history of recent nosocomial infections before transplantation should be addressed with the administration of appropriate specific antibiotics. Colonizing organisms growing from enterocutaneous fistulous tracts should be treated perioperatively.

All recipients are given a preoperative and postoperative "cocktail" of oral nonabsorbable antibiotics every 6 hours for 2 weeks; the mix includes amphotericin B, gentamicin, and polymyxin E and is intended to achieve selective bowel decontamination.<sup>27</sup> Surveillance stool specimens are obtained for culture weekly. When organisms grow in quantitative cultures to colonies of greater than 10<sup>8</sup> organisms in the presence of signs of systemic sepsis, or ongoing acute cellular rejection of the allograft, specifically directed intravenous antibiotics are added to the regimen to treat the presumed translocating organisms. This most commonly occurs during episodes of acute rejection, when the mucosal barrier of the allograft has been immunologically damaged; however, it may also be seen with enteritis associated with Epstein-Barr virus (EBV).<sup>28</sup>

The antiviral prophylactic strategy has evolved during this study period and presently includes a 2-week course of intravenous ganciclovir with concomitant CMV-specific hyperimmune globulin (Cytogam).<sup>29</sup> Lifetime oral trimethoprim-sulfamethoxazole is used as prophylaxis for *Pneumocystis carinii* pneumonia.

## Nutritional Support

Full nutritional support is initially provided via standard TPN. TPN is tapered gradually as oral or enteral feedings (via gastric or jejunal tube) are advanced. Tube feedings are initiated with an isotonic dipeptide formula containing medium-chain triglycerides and glutamine. This formula is later converted to a lactose-free and gluten-free diet that contains dietary fibers to promote normalization of intestinal motility and function. Most patients do not voluntarily eat adequate amounts early after the operation, and variations to this existed among the various intestinal transplant cohorts. Most impressive has been the resistance to resumption of oral feedings in pediatric recipients.<sup>30</sup> Therefore, enteral supplementation is required when the intestinal tract becomes functional. Management is highly "individualized," since the simplicity of an uneventful post-transplantation course may suddenly change with any surgical or immunologic complication. These complications can be manifested with serious fluid, caloric, protein, and trace element deficits.

## Assessment of Graft Status

A judgment of the anatomic and functional integrity of the graft begins in the operating room. The normal appearance of the mesentery and intestine is pink and nonedematous, with the intestine occasionally demonstrating contractions. Alterations from this appearance can be observed in the operating room and in the ileal stoma postoperatively.

Surveillance of intestinal graft rejection focuses on clinical evaluation and gross morphologic examination of the stoma and the distal ileum. Frequent routine enteroscopic surveillance has been the most reliable tool for the early diagnosis of intestinal rejection.<sup>31</sup> Endoscopic evaluations are performed



routinely twice a week through the allograft ileostomy; upper endoscopy is performed when clinical changes are not elucidated by distal allograft evaluation. Grossly, the bowel reacts to insult in nonspecific ways with edema, cyanosis, congestion, and increased stomal output; these alterations should signal a broad differential to include preservation injury, systemic sepsis, rejection, and enteritis.

The stomal output is assessed for volume, consistency, and the presence of reducing substances, which can be seen in the event of rejection, bacterial overgrowth, or malabsorption. Typical stomal output of a clear, watery effluent within the first week of implantation is 1 to 2 L/day for adults and 40 to 60 mL/kg/day for children. If these volumes are exceeded and no significant pathology is present, paregoric, loperamide, pectin, somatostatin, or oral antibiotics may be used singly or in combination to control the diarrhea. The presence of blood in the stool is always an ominous sign and indicates rejection until proven otherwise.

Serum tests are important in assessing injury to the liver (bilirubin, aspartate aminotransferase, and alanine aminotransferase), but no such tests exist for the intestinal grafts. Serum markers for nutritional adequacy and anabolic status (transferrin, albumin, retinoic acid) are of limited value, whereas specific tests of the absorptive ability of the graft are good measures of overall function. Assessment of small-bowel function relies on absorption studies of D-xylose and tacrolimus and on the quantitation of fat in the stool. Most patients show satisfactory absorption curves for D-xylose within the first postoperative month, with absorption improving over time. Abnormal results obtained after 1 month should always prompt an aggressive search for underlying pathology, especially rejection.

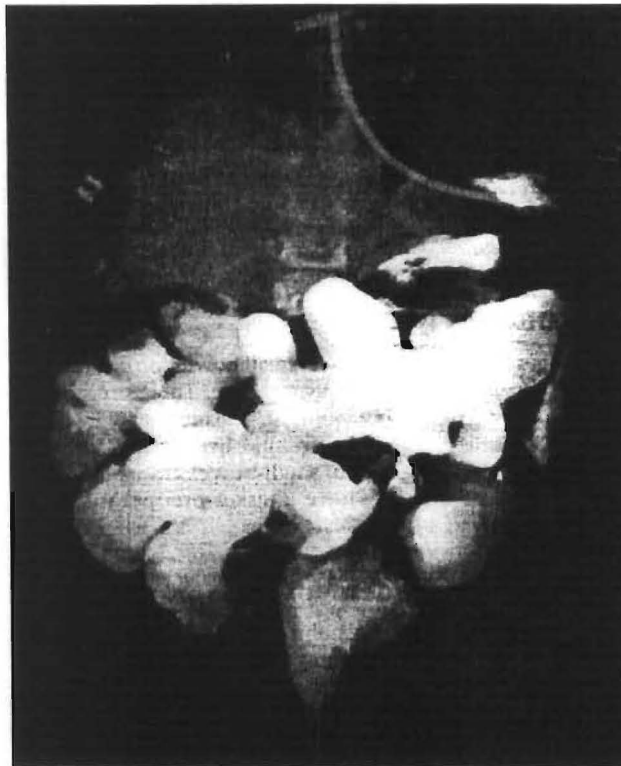The maintenance of satisfactory tacrolimus whole blood trough levels of 15 to 25 ng/mL with oral therapy alone is a good indicator of adequate absorption. In our patients, this level has occurred at a mean of 28 days after transplantation and tends to be delayed longer in recipients of multivisceral grafts.<sup>32</sup> The excretion of fat in the stool has been abnormal in almost all patients, but clinical steatorrhea has not been a problem.

Radiologic evaluations by standard barium gastrointestinal examination are valuable in assessing mucosal pattern and motility and are performed routinely after the first postoperative week. A normal mucosal pattern is expected. Intestinal transit time is about 2 hours. Intestinal graft rejection, when mild, can be suspected when evidence of mucosal edema exists. Severe rejection, with exfoliation of the mucosa, ablates the normal mucosal pattern and can be seen as segments of "tubulized" intestine and strictures (Fig. 184-5).

## COMPLICATIONS

Before the various potential complications are described, it is important to impart a general perspective on the care of these patients. Comprehensive management of intestinal recipients requires a multidisciplinary approach by surgeons, anesthesiologists, nurses, critical care physicians, pathologists, and a host of internal medicine subspecialists. Easy access to diagnostic and therapeutic modalities is paramount, including mechanical ventilation, hemodialysis, bronchoscopy, gastrointestinal endoscopy, thromboelastography, percutaneous cholangiography, ultrasonography, invasive and noninvasive contrast radiography, and sophisticated hemodynamic monitoring systems.

More important than the preceding, however, is a vigilance about patient care and attention to detail on the part of both physicians and nurses. Problems in these patients can originate from a multiplicity of sources. We can make several assumptions about these patients based on our experience:



**Figure 184-5.** Severely damaged allograft intestine in a recipient of a liver-small bowel after multiple episodes of rejection. Diffuse tubulized gut, strictures, and significant distention of the native duodenum are seen.

1. Preoperative deterioration of physical performance status predisposes to various organ system failure that persists in the postoperative period even though allograft function may be acceptable.
2. Treating transplant recipients is a labor-intensive task, requiring aggressive respiratory therapy, nutritional and antibiotic support, fluid management, and nursing care, often for prolonged periods in the intensive care unit.
3. Immunotherapy doses in patients with multivisceral transplants tend to be higher than in patients with single organ transplants.
4. Most patients experience episodes of infection and rejection after transplantation, often concomitantly. Any subjective complaints or objective abnormalities should be vigorously pursued until a cause is found or until these problems resolve.

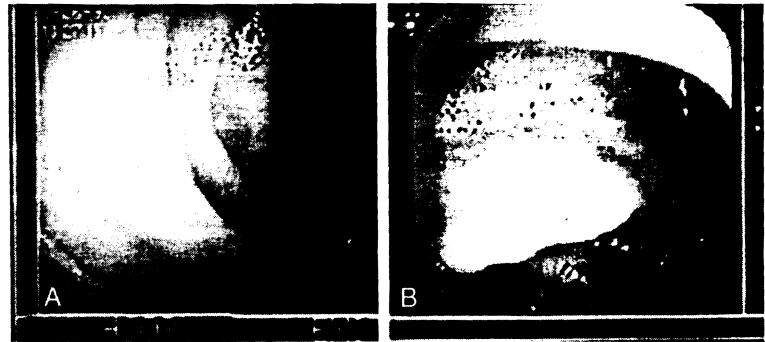
## Graft Rejection

Intestinal allograft rejection can present as an array of symptoms that include fever, abdominal pain, distention, nausea, vomiting, and a sudden increase in stomal output. The stoma may become edematous, erythematous, and friable. Gastrointestinal bleeding can occur in cases of severe uncontrollable rejection in which ulcerations and sloughing of the intestinal mucosa occur. Septic shock or ARDS may develop. Bacterial or fungal translocation can occur during intestinal allograft rejection as a result of disruption of the intestinal mucosal barrier. Gut decontamination must be instituted during these episodes.<sup>33</sup>

Endoscopically, the transplanted intestinal mucosa loses its velvety appearance. It may become hyperemic or dusky as well as hypoperistaltic. Erythema may be focal or diffuse. The mucosa becomes friable, and diffuse ulcerations appear (Fig. 184-6) (see Color Plate).



**Figure 184-6.** A, Normal endoscopic appearance of the transplanted small intestine. B, Moderate acute cellular rejection of an intestinal allograft demonstrating diffuse edema and focal erythema. (See Color Plate.)



Histologically, there is variable presence of lamina propria edema and villous blunting. However, the mononuclear cell infiltrates and cryptitis with apoptosis and regeneration are necessary for establishing the diagnosis of rejection. Neutrophils, eosinophils, and macrophages may be seen traversing the muscularis mucosa.<sup>34, 35</sup> The degree of epithelial and crypt cell damage varies. Complete mucosal sloughing and crypt destruction are seen in grafts with severe rejection. The mucosal surface is partially replaced by inflammatory pseudomembranes and granulation tissue (Fig. 184-7). This event may precipitate continuous blood loss as well as intermittent septic episodes from the damaged intestine.

Chronic rejection has been observed in patients with persistent intractable rejection episodes. Clinically progressive weight loss, chronic diarrhea, intermittent fever, and gastrointestinal bleeding dominate the presentation. Histologically, villous blunting, focal ulcerations, epithelial metaplasia, and scant cellular infiltrate are present on endoscopic mucosal biopsies. Full-thickness biopsy specimens show obliterative thickening of intestinal arterioles.

The incidence of acute intestinal allograft rejection during the first 90 days after transplantation is reported to be 92% in

isolated small-bowel transplant recipients and 66% in recipients of composite graft (multivisceral, liver/small bowel), suggesting that the liver is "protective" of the intestine, as seen experimentally.<sup>8, 36</sup> Interestingly, the incidence of acute liver allograft rejection in recipients of composite grafts is 43%, a rate similar to that seen after isolated liver transplantation.<sup>30</sup>

Mild graft rejection is treated initially with intravenous methylprednisolone; moderate or severe rejection is treated with a methylprednisolone taper. Tacrolimus trough levels in whole blood should reach 15 to 25 ng/mL by either the oral or intravenous route. OKT3 is used when rejection has progressed with a steroid taper; however, it should be entertained as the initial therapeutic agent in cases of severe mucosal injury and crypt damage. The use of cyclophosphamide-mycophenolate mofetil induction therapy or bone marrow augmentation has had no beneficial effect on the frequency of rejection.<sup>30, 36</sup>

### Postoperative Hemorrhage

Coagulopathy is more often an intraoperative problem that relates to liver dysfunction, qualitative and quantitative plate-



**Figure 184-7.** Acute cellular rejection. A, Endoscopic biopsy obtained 14 days after transplantation showed widening of the lamina propria with increased mononuclear cells, which were often cuffed around small vessels and infiltrating the crypt epithelium (*arrow*). (Hematoxylin and eosin,  $\times 140$ .) B, The reaction was more intense in biopsy specimens that contained lymphoid nodules and where blastogenesis, focal ulcerations, congestion, and neutrophil plugging of capillaries were also seen (moderate acute cellular rejection). (Hematoxylin and eosin,  $\times 140$ .) C, Uncontrolled acute rejection eventually resulted in widespread mucosal destruction; the mucosa was replaced by granulation tissue. Note the overlying inflammatory pseudomembrane (*arrow*). (Hematoxylin and eosin,  $\times 350$ .)

let defects, and fibrinolysis.<sup>37</sup> Intraoperative bleeding is furthered by vascularized adhesions from previous surgery and portal hypertension. Temporary graft reperfusion coagulopathy mediated by plasminogen activators from the graft may occur.<sup>38</sup> Efforts are taken to normalize these global aspects of coagulation by the end of the operative procedure, so that in the absence of liver dysfunction, the coagulopathy is usually minor in the postoperative period.

Postoperative intra-abdominal bleeding is most often a technical problem, arising from vascular anastomoses or extensive, raw peritoneal surfaces. Certainly, coagulation should be normalized if postoperative bleeding occurs; if bleeding is proved, the origin should be presumed surgical and managed as such by early exploration.

### Biliary Complications

Continuity of the biliary axis is preserved in multivisceral and cluster grafts as well as the modified liver/small-bowel graft. The standard liver/small-bowel graft requires a Roux-en-Y choledochojejunostomy. Correspondingly, these grafts can result in biliary system-related surgical complications (i.e., leaks and obstructions).

Biliary leaks usually occur within the first 2 weeks after liver/small-bowel transplantation and may herald their presence with bilious drainage from the abdominal wound or drains or merely with unexplained sepsis. The response to external bilious drainage should be immediate exploration with surgical revision of the biliary dehiscence. In the case of unexplained sepsis in any intestinal transplant recipient, all surgical anastomoses should be radiographically inspected (with percutaneous cholangiography); if leakage is suspected, the anastomoses should be openly revised. There is no place for percutaneous diversion of biliary or intestinal leakage in these patients, because both wound healing and antimicrobial immunity are impaired by multimodal immunotherapy.

Biliary obstruction generally follows an anastomotic stricture and is a delayed complication, but any clinical picture that resembles cholangitis or biliary obstruction should be investigated with cholangiography to prove patency, regardless of the timing after transplantation.

### Vascular Complications

Major arterial thrombosis is a disastrous complication that leads to massive necrosis of the organs correspondingly supplied. Elevation of hepatic enzymes and pallor of the intestinal stoma are accompanied by clinical deterioration, fulminant sepsis, and hepatic coma. Isolated small-bowel grafts can be removed with the expectation of patient recovery; however, in patients with composite grafts, the event is usually fatal unless early retransplantation can be performed. Patency of the arteries can be rapidly confirmed with Doppler ultrasound examination.

Because the superior mesenteric vein/portal vein axis is preserved in the composite grafts, venous outflow thrombosis is less likely to occur in these recipients. Isolated small-bowel grafts have an anastomosis of these veins that can potentially occlude. Ascites, stomal congestion, and, ultimately, mesenteric infarction would be the end result.

Neither of these problems produces subtle clinical signs, and diagnosis should be prompt and obvious. In our series, isolated thrombosis of the hepatic artery has occurred in a pediatric recipient of a liver/small-bowel graft, with consequent hepatic gangrene. This patient required retransplantation of the liver component of the graft, even though a full liver/small-bowel graft was desirable.

Incomplete obstruction of major inflow or outflow vessels

may be suspected on biopsy or based on clinical and laboratory evidence of organ dysfunction. Contrast vascular x-ray studies are confirmatory, and the correction is surgical or, in some cases, with balloon dilatation.

### Gastrointestinal Complications

Gastrointestinal bleeding after intestinal transplantation is an ominous sign that requires prompt attention. Rejection or infection is probable cause and should be immediately diagnosed or ruled out on the basis of enteroscopic biopsy results. The diagnosis of rejection relies not only on histologic evidence but also on the endoscopic appearance (see Figs. 184-6 and 184-7). Bleeding from ulcerated Epstein-Barr virus- or cytomegalovirus (CMV)-induced lesions can be easily differentiated by gross endoscopic examination. Empirical therapy for rejection is not acceptable.

Leakage of either the proximal or distal gastrointestinal anastomosis can occur in any recipient, but it is more common in children than in adults. Any fresh surgical margin, including native duodenal and colonic stumps and gastrostomy sites, are vulnerable to poor wound healing and subsequent leakage. Presentation is often dramatic (florid sepsis), with confirmation by radiologic contrast imaging. Surgical revision, evacuation of peritoneal soilage, and often reexploration are required to eliminate the contamination effectively. Again, sepsis without an obvious source should prompt the performance of contrast studies to document the integrity of all gastrointestinal anastomoses; if the findings are inconclusive, diagnostic laparotomy is indicated.

Native gastric atony and pylorospasm that produce early satiety or vomiting are common and self-limiting. The evolution of motility patterns in the denervated allograft intestine is not fully understood, although it is clear that various pathologic processes may alter the individual baseline. Hypermotility of the allograft intestine occurs early after transplantation; in the absence of rejection or bacterial overgrowth, it can be controlled with agents such as paregoric, loperamide, or pectin. Sudden changes in intestinal motility, particularly when accompanied by abdominal distention and vomiting in the case of decreased motility, should initiate a search for rejection.

### Infections

The frequency of infectious complications is high and is responsible for significant morbidity and mortality after intestinal transplantation. This reflects the relatively higher level of immunosuppression required to maintain the graft in these intestinal recipients. Other predisposing factors include the severity of the preoperative liver failure and the presence of intra-abdominal, pulmonary, or intravenous line-induced sepsis before transplantation. Also, technically more difficult transplantation procedures with increased operative time, transfusion requirements, and likelihood of reexploration reflect the advanced disease of these patients. Recipients of small-bowel grafts have the lowest incidence of complications because of the more elective nature of their candidacy.

Infectious pathogens include bacteria, fungi, and viruses. Infections are related (in order of frequency) to intravenous lines, the abdominal wound, deep abdominal abscesses, peritonitis, and pneumonia. Bacterial translocation in grafts damaged by rejection illustrates the need for concomitant antirejection and antimicrobial therapy and is a frequent source of infection.

Of the bacterial pathogens, staphylococci and enterococci are common, whereas gram-negative rods usually accompany polymicrobial infections. Not uncommonly, separate sources

of infection occur simultaneously, or mixed infections from the same source are present. This leads to multiple antibiotic regimens and sets the stage for the development of resistant organisms. Particularly problematic has been the nascent strain of panresistant enterococci. Persistence of a physiologic hyperdynamic state in a patient being treated for proven infection should raise the suspicion of retained phlegmonous material in the abdomen or the possibility of rejection.<sup>39</sup>

Fungal infections become problematic after heavy treatment of rejection, massive antibiotic usage, intestinal leaks, and multiple surgical explorations. We routinely employ low-dose amphotericin B prophylaxis in patients with these complications. Established fungal infections require long-term, full-dose antibiotic therapy and reduction of immunotherapy. All recipients with persistent sepsis are potential candidates for moderation of immunosuppressant dosages if no coexistent cellular rejection is present. However, complete withdrawal of immunosuppression has been impossible in this recipient population because of a high incidence of rebound rejection, which then requires augmentation of immunotherapy.

Clinical CMV infection has occurred in 36% of intestinal graft recipients and often involves the allograft intestine. Although the incidence and distribution of disease, according to donor and recipient CMV serologic status, are similar in adults (44%) and children (31%), the clinical course has been dramatically better in children. Successful clinical management has been accomplished in 88% of episodes with ganciclovir alone or in combination with CMV-specific hyperimmunoglobulin. Immunosuppression was maintained at baseline and reduced only in the face of deteriorating clinical disease, thus indicating rebound rejection.<sup>29</sup> A CMV-positive donor graft transplanted into a CMV-negative recipient is a significant risk factor, but intense baseline immunosuppression with high tacrolimus levels and cumulative doses of pulse steroids is a constant feature.<sup>40</sup> Clinical presentation has generally been enteritis of variable severity with focal ulcerations and bleeding (Fig. 184-8) (see Color Plate). We currently avoid CMV-positive grafts only for CMV-negative candidates who are awaiting isolated intestinal grafts. However, CMV-negative candidates awaiting the larger composite grafts, because they are at risk for death from liver failure, may still receive a CMV-positive graft.<sup>29</sup>

Less commonly, respiratory syncytial virus, adenovirus, and parainfluenza virus have occurred in children. All viral infections are opportunistic and have as a "common denominator"

the need for aggressive treatment of rejection episodes in complicated patients with high Acute Physiologic and Chronic Health Evaluation (APACHE) scores.

Post-transplantation lymphoproliferative disease (PTLD) associated with the Epstein-Barr virus has occurred in 20% of all patients, with children (27%) being at a significantly higher risk than adults (11%). Presentation varies from totally asymptomatic observations at routine endoscopy, nonspecific intestinal and systemic symptoms, bleeding, lymphadenopathy, and tumors, to fulminant disease. Risk factors other than age included the type of graft, splenectomy, and the use of OKT3. Therapy included the reduction and withdrawal of immunosuppression, antivirals (ganciclovir, acyclovir, hyperimmunoglobulin), cytokines (interferon- $\alpha$ ), and chemotherapy. However the disease was lethal in 45% of our patients. Rebound rejection was a significant contributor to mortality.<sup>30, 36, 41</sup>


### Graft-Versus-Host Disease

Skin changes consistent with graft-versus-host disease were confirmed by histopathologic criteria in five of our patients (5%), only one of whom had received adjunct bone marrow. This was confirmed by immunohistochemical studies visualizing donor cell infiltration into the lesions on two occasions. One child died with hereditary immunoglobulin (IgG and IgM) deficiency,<sup>42</sup> and one adult had a complex chronic GVHD in association with PTLD. All other cases have been self-limited and resolved spontaneously.

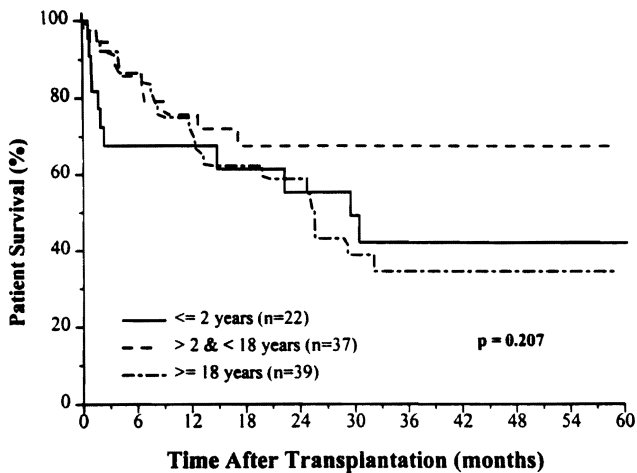
### Present Status and Future

The causes of graft and patient loss are invariably multifactorial and complex. The evolution of technical and clinical management factors have improved outcome. However, the interplay between the need for high levels of immunosuppression, the high incidence of immunosuppression, the high incidence of rejection, and the opportunistic infections consequent to this remain the major stumbling blocks to further progress.

The experience accumulated over the last 8 years of this study has allowed the development of clinical and surgical strategies that has benefited a very clinically complex group of patients. Our reserved optimism is taken in light of previous experience with intestinal transplantation as well as the grim outcome of patients not receiving transplants. Nonetheless,



**Figure 184-8.** A. Endoscopic appearance of cytomegaloviral enteritis is characterized by hyperemic erosions. B. The diagnosis was confirmed histologically by the presence of characteristic inclusions, by staining for viral antigens, or both. Note the focal neutrophilic inflammation. (Immunoperoxidase for cytomegalovirus antigens,  $\times 350$ .) (See Color Plate.)

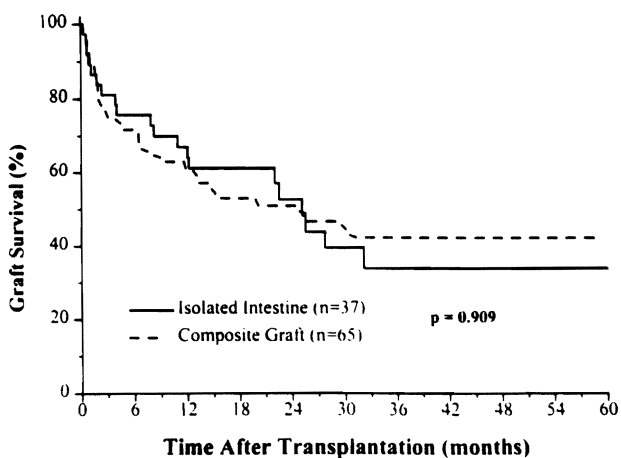


**Figure 184-9.** Patient survival with age distribution. (From Abu-Elmagd K, Reyes J, Todo S, et al: Clinical intestinal transplantation: New perspectives and immunologic considerations. *J Am Coll Surg* 1998; 186:512-527.)

the overall actuarial survival at 1 and 5 years has been 72% and 48%, respectively, with full nutritional support having been achieved in 91% of surviving patients. Improved results were achieved in the pediatric population between 2 and 18 years of age (65% at 5 years)<sup>36</sup> (Fig. 184-9).

The transplantation of the isolated intestinal graft has provided better patient survival at all follow-up times. However, because of a higher incidence of rejection with this type of graft, the long-term outcome of all types of grafts (isolated intestine or composite grafts) has been similar and is estimated at about 40% at 5 years<sup>30, 36</sup> (Fig. 184-10).

Although the augmentation of donor leukocyte chimerism with bone marrow infusion did not alter patient or graft survival, it was not responsible for any significant morbidity, thus establishing its safety as an adjunct procedure. It has provided insights into the fate of the coexisting leukocyte populations (donor or recipient); however, further immunomodulatory strategies will be necessary to advance the field of intestinal transplantation.



**Figure 184-10.** Graft survival with intestine alone, or as a composite with the liver allograft. (From Abu-Elmagd K, Reyes J, Todo S, et al: Clinical intestinal transplantation: New perspectives and immunologic considerations. *J Am Coll Surg* 1998; 186:512-527.)

Under the best of circumstances, the outlay of financial and time expenditures in composite and isolated small-bowel transplant recipients is impressive. For best possible results, candidates who have optimal nutritional status and who are free of active infection should be selected. Donor organs should be discarded if they are less than perfect. Even with technically perfect operations, the managing physician should expect a panoply of postoperative difficulties and should be prepared to support these patients fully for an indefinite period. Managing the balance between excessive and inadequate immunosuppression in the face of potentially virulent infections, the pursuit of rejection and sources of infection, and maintenance of comprehensive critical care support are the most challenging tasks.

## References

- Grant D: Intestinal transplantation: Current status. *Transplant Proc* 1989; 21:2869-2871.
- Lillehei RC, Goot B, Miller FA: The physiologic response of the small bowel of the dog to ischemia including prolonged in vitro preservation of the bowel with successful replacement and survival. *Ann Surg* 1959; 150:543-560.
- Starzl TE, Kaupp HA Jr: Mass homotransplantation of abdominal organs in dogs. *Surg Forum* 1960; 11:28-30.
- Billingham RE: Reactions of grafts against their host; transplantation immunity works both ways—hosts destroy grafts and grafts may harm hosts. *Science* 1959; 130:947-953.
- Monchik GJ, Russell PS: Transplantation of the small bowel in the rat: Technical and immunologic considerations. *Surgery* 1971; 70:693-702.
- Starzl TE, Rowe M, Todo S, et al: Transplantation of multiple abdominal viscera. *JAMA* 1989; 261:1449-1457.
- Starzl TE, Todo S, Tzakis A, et al: Abdominal organ cluster transplantation for the treatment of upper abdominal malignancies. *Ann Surg* 1989; 210:374-386.
- Calne RY, Sells RA, Pena JR, et al: Introduction of immunologic tolerance by porcine liver allograft. *Nature* 1969; 223:472-474.
- Kamada N, Davies HS, Wight D, et al: Liver transplantation in the rat: Biochemical and histological evidence of complete tolerance induction in nonrejector strains. *Transplantation* 1983; 35:304-311.
- Grant D, Wall W, Mimeault R, et al: Successful small-bowel/liver transplantation. *Lancet* 1990; 335:181-184.
- Deltz E, Schroeder P, Gebhard H, et al: Successful clinical small bowel transplantation: Report of a case. *Clin Transplant* 1989; 3:89.
- Goulet OK, Revillon Y, Jan D, et al: Small-bowel transplantation in children. *Transplant Proc* 1990; 22:2499-2500.
- Murase N, Demetris AJ, Mutsuzaki T, et al: Long survival in rats after multivisceral versus isolated small bowel allotransplantation under FK506. *Surgery* 1991; 110:87-98.
- Todo S, Tzakis AG, Abu-Elmagd K, et al: Cadaveric small bowel and small bowel-liver transplantation in humans. *Transplantation* 1992; 53:369-376.
- Starzl TE, Demetris AJ, Trucco M, et al: Cell migration and chimerism after whole-organ transplantation: The basis of graft acceptance. *Hepatology* 1993; 17:1127-1156.
- Starzl TE, Demetris AJ, Murase N, et al: The lost chord: Microchimerism and allograft survival. *Immunol Today* 1996; 17:577-584.
- Howard L, Ament M, Fleming RC, et al: Current use and clinical outcome of home parenteral and enteral nutrition therapies in the United States. *Gastroenterology* 1995; 109:355-365.
- Casella JF, Lewis JH, Bontempo FA, et al: Successful treatment for homozygous protein C deficiency by hepatic transplantation. *Lancet* 1988; i:435-438.
- Starzl TE, Todo S, Tzakis A, et al: The many faces of multivisceral transplantation. *Surg Gynecol Obstet* 1991; 172:335-344.
- Tzakis A, Todo S, Starzl TE: Piggyback orthotopic liver transplantation with preservation of the inferior vena cava. *Ann Surg* 1989; 210:649-652.
- Todo S, Tzakis A, Abu-Elmagd K, et al: Intestinal transplantation in composite visceral grafts or alone. *Ann Surg* 1992; 216:223-234.

22. Takaya S, Iwaki Y, Starzl TE: Liver transplantation in positive cytotoxic crossmatch cases using FK506, high dose steroids, and prostaglandin E<sub>1</sub>. *Transplantation* 1991; 54:927-933.
23. Starzl TE, Demetris AJ, Rao AS, et al: Spontaneous and iatrogenically augmented leukocyte chimerism in organ transplant recipients. *Transplant Proc* 1994; 26:3071-3076.
24. Rao AS, Fontes P, Zeevi A, et al: Augmentation of chimerism in whole organ recipients by simultaneous infusion of donor bone marrow cells. *Transplant Proc* 1995; 27:210-212.
25. Fontes P, Rao A, Demetris AJ, et al: Augmentation with bone marrow of donor leukocyte migration for kidney, liver, heart, and pancreas islet transplantation. *Lancet* 1994; 344:151-155.
26. Karavias D, Jabbour N, Felekouras E, et al: Right diaphragmatic paralysis following orthotopic liver transplantation. Submitted.
27. Reyes J, Abu-Elmagd K, Tzakis A, et al: Infectious complications after human small bowel transplantation. *Transplant Proc* 1992; 24:1249-1250.
28. Sigurdsson L, Green M, Putnam P, et al: Bacteremia frequently accompanies rejection following pediatric small bowel transplantation (Abstract). *J Pediatr Gastroenterol Nutr* 1995; 21:356.
29. Bueno J, Green M, Kocoshis S, et al: Cytomegalovirus infection after intestinal transplantation in children. *Clin Infect Dis* 1997; 25:1078-1083.
30. Reyes J, Bueno J, Kocoshis S, et al: Current status of intestinal transplantation in children. *J Pediatr Surg* 1998; 33:243-254.
31. Garau P, Orenstien SR, Neigut DA, et al: Role of endoscopy following small intestinal transplantation in children. *Transplant Proc* 1994; 26:136-137.
32. Reyes J, Tzakis AG, Todo S, et al: Nutritional management of intestinal transplant recipients. *Transplant Proc* 1993; 25:1200-1201.
33. Abu-Elmagd K, Tzakis A, Todo S, et al: Monitoring and treatment of intestinal allograft rejection in humans. *Transplant Proc* 1993; 25:1202-1203.
34. Lee RG, Nakamura K, Tsamada ACm, et al: Pathology of human intestinal transplantation. *Gastroenterology* 1996; 1820-1834.
35. White FV, Reyes J, Jaffe R, et al: Pathology of intestinal transplantation in children. *Am J Surg Pathol* 1995; 19:687-698.
36. Abu-Elmagd K, Reyes J, Todo S, et al: Clinical intestinal transplantation: New perspectives and immunologic considerations. *J Am Coll Surg* 1998; 186:512-527.
37. Kang YG, Martin DJ, Marquez JM, et al: Intraoperative changes in blood coagulation and thromboelastographic monitoring in liver transplantation. *Anesth Analg* 1985; 64:888-896.
38. Stahl RL, Duncan A, Hooks MA, et al: A hypercoagulable state follows orthotopic liver transplantation. *Hepatology* 1990; 12:553.
39. Green M, Reyes J, Nour B, et al: Early infectious complications of liver-intestinal transplantation in children: Preliminary analysis. *Transplant Proc* 1994; 26:1420-1421.
40. Manez R, Kusne S, Green M, et al: Incidence and risk factors associated with the development of cytomegalovirus disease after intestinal transplantation. *Transplantation* 1995; 59:1110-1114.
41. Reyes J, Tzakis A, Bonet H, et al: Lymphoproliferative disease after intestinal transplantation under FK506 immunosuppression. *Transplant Proc* 1994; 26:1426-1427.
42. Reyes J, Todo S, Green M, et al: Graft-versus-host disease after liver and small bowel transplantation in a child. *Clin Transpl* 1997; 11:345-348.

# 185

## Future of Transplantation (Including Xenografting)

John J. Fung, MD, PhD • Abdul S. Rao, MD, DPhil  
Ernesto P. Molmenti, MD • S. Forrest Dodson, MD  
Ake Grenvik, MD, PhD, FCCM • Thomas E. Starzl, MD, PhD

In Chapter 175, a detailed history of organ transplantation is provided. In order to foster the appreciation and understanding of the forces that will drive advances in transplantation into the next century, this chapter focuses on a few of the past developments in transplantation that have helped to shape current transplant practices (Fig. 185-1). The beginning of solid-organ transplantation can be traced back to the technical achievement of Alexis Carrel<sup>1</sup>; in 1902, he described the techniques of vascular anastomosis, thus ushering in accounts of autologous and homologous transplantation. Although a number of animal-to-human kidney transplants were reported in the ensuing three decades, a human donor organ was not used until 1933, by the Russian surgeon Voronoy.<sup>2</sup> This and other attempts at using human kidneys for transplantation failed owing to acute tubular necrosis and rejection. The first successful human transplant was performed on December 23, 1954, by the Boston team of Moore, Murray, Merrill, and Harrison.<sup>3</sup> The transplantation of an identical twin kidney from one brother to another was the immunologic advantage that distinguished the early successes in kidney transplantation from those that otherwise were doomed to fail.

Gibson and Medawar<sup>4</sup> ascribed an immunologic basis to the rejection of tissues between genetically nonidentical individuals. In 1960, Calne and Murray<sup>5</sup> used azathioprine, developed several years earlier by Burroughs-Wellcome, in attempts to gain success in unrelated kidney transplantation using immunosuppressive agents. Starzl and colleagues<sup>6</sup> then modified the immunosuppressive regimen by adding corticosteroids for rejection and began routinely to achieve success. This success led to growing attempts at human kidney transplantation, aggravating the shortage of organs to use for transplantation. A number of animal-to-human transplantations were attempted. The longest survivor was a 23-year-old woman who lived for 9 months after receiving kidneys from a chimpanzee.<sup>7</sup>

In 1968, the Ad Hoc Committee of the Harvard School of Medicine proposed the concept of "irreversible coma."<sup>8</sup> Further clarification of the pathophysiology of irreversible brain stem injury and subsequent somatic death followed, as did objective criteria to document irreversible brain injury. The brain death concept has eventually been accepted throughout the United States (see Chapter 174). The details of brain death evaluation and certification vary from state to state but require a clinical picture of (1) coma not due to drug overdose (e.g., alcohol) or to physical reasons (e.g., hypothermia) and (2) lack of cranial nerve reflexes. Confirmatory tests are used to document the absence of blood flow to the brain and the lack of cerebral and brain stem electric activity. The use of brain-dead donors, with optimal hemodynamic parameters, offers the possibility of better-quality organs with minimum damage from warm ischemia. It has also allowed procurement of extrarenal organs in a systematic manner.<sup>9</sup> Another improvement in the area of donor management was the development of preservation solutions, first Collins solution<sup>10</sup> and currently