

- planted kidney as a source of hepatitis B infection. *Ann Intern Med* 1979; 91: 412.
7. Chan MK, Chang WK. Renal transplantation from HBsAg positive donors to HBsAg negative recipients. *Br Med J* 1988; 297: 522.
 8. Lutwick LI, Sywassink JM, Corry RJ, Shorey JW. The transmission of hepatitis B by renal transplantation 1983; 19: 317.
 9. Douglas DD, Rakela J, Mamish D, Wright TL, Krom RAF, Wiesner RH. Transmission of Hepatitis B Virus (HBV) infection from orthotopic donor livers. *Hepatology* 1992; 16: 49A.
 10. Robinson WS. Biology of human hepatitis viruses. In: Zakim D, Boyer TD, eds. *Hepatology—a textbook of liver disease*. Philadelphia: Saunders, 1990: 890.
 11. Hoofnagle JH, Seeff LB, Bales ZB, et al. Serologic responses in hepatitis B. In: Vyas GN, Cohen SN, Schmid R, eds. *Viral hepatitis: a contemporary assessment of etiology, epidemiology, pathogenesis and prevention*. Philadelphia, Franklin Institute, 1978: 219.
 12. Krugman S, Overby LR, Mushahrwar IK, et al. Viral hepatitis type B: studies on natural history and prevention reexamined. *N Engl J Med* 1979; 300: 101.
 13. Kitchen AD, Harrison TJ, Meacock TJ, Zuckerman AJ, Harrison JF. Incidence and significance of hepatitis B core antibody in a healthy blood donor population. *J Med Virol* 1988; 25: 69.
 14. Brechot C, Kremsdorf D, Paterlini P, Thiers V. Hepatitis B virus DNA in HBsAg-negative patients: molecular characterization and clinical implications. *J Hepatol* 1991; 13: S49.
 15. Chazouilleres O, Mamish D, Kim M, et al. "Occult" hepatitis B virus as a source of infection in liver transplant recipients. *Lancet* 1994; 343: 142.
 16. Kadian M, Hawkins L, Nespral J, Schwartz M, Miller C. Use of hepatitis B core antibody positive multiorgan donors. Presented at the Second International Congress of the Society for Organ Sharing Vancouver, British Columbia, 1993.
 17. Naumova AK, Kisselev LL. Biological consequences of interactions between hepatitis B virus and human nonhepatic cellular genomes. *Biomed Sci* 1990; 1: 233.
 18. O'Grady JG, Sutherland S, Harvey F, et al. Cytomegalovirus infection and donor/recipient HLA antigens. *Lancet* 1988; 11: 302.
 19. Nagington J, Cossart YE, Cohen BJ. Reactivation of hepatitis B after transplantation operations. *Lancet* 1977; 1: 588.
 20. Sagnelli E, Manzillo G, Maio G, et al. Serum levels in hepatitis B surface and core antigens during immunosuppressive treatment of HBsAg-positive chronic active hepatitis. *Lancet* 1980; 2: 395.
 21. Samuel D, Rainer M, Graeme A, et al. Liver transplantation in European patients with the hepatitis B surface antigen. *N Engl J Med* 1993; 329: 1842.

Received 26 May 1994.

Accepted 13 July 1994.

0041-1337/95/5902-234\$03.00/0
TRANSPLANTATION
Copyright © 1995 by Williams & Wilkins

1625

Vol. 59, 234-240, No. 2, January 27, 1995
Printed in U.S.A.

ABDOMINAL MULTIVISCERAL TRANSPLANTATION^{1,2}

SATORU TODO, ANDREAS TZAKIS, KAREEM ABU-ELMAGD, JORGE REYES, HIROYUKI FURUKAWA, BAKR NOUR, JOHN FUNG, ANTHONY DEMETRIS,³ AND THOMAS E. STARZL⁴

The Pittsburgh Transplantation Institute and the Department of Pathology, University of Pittsburgh Medical Center, Pittsburgh, Pennsylvania 15213

Under FK506-based immunosuppression, 13 abdominal multivisceral transplantations were performed in 6 children and 7 adults. Of the 13 recipients, 7 (53.8%) are alive and well with functioning grafts after 9 to 31 months. Six recipients died: three from PTLD, one from rejection, one from sepsis, and one from respiratory failure. In addition to rejection, postoperative complications occurring in more than isolated cases included PTLD (n=6), abdominal abscess formation (n=5), pancreatitis (n=3), and ampullary dysfunction (n=2). In addition, infection by enteric microorganisms was common during the early postoperative period. Currently, all 7 survivors are on an oral diet and have normal liver function. Two recipients (one insu-

lin-dependent) require antidiabetes treatment, in one case following distal pancreatectomy and in the other after two episodes of pancreatic rejection. Thus, abdominal multivisceral transplantation is a difficult but feasible operation that demands complex and prolonged posttransplantation management. It is not yet ready for application and awaits a better strategy of immune modulation.

Abdominal multivisceral transplantation was developed experimentally more than 30 years ago (1, 2). The procedure was extremely difficult, yielding >5-day survival in only 5 of 39 untreated animals. No clinical application of multivisceral transplantation could be envisioned at that time. In 1989, we first reported multivisceral transplantation in two children who had short bowel syndrome and total parenteral nutrition (TPN)* induced liver failure (3). The first patient died during

¹ Presented at the 20th Annual Meeting of the American Society of Transplant Surgeons, May 18-20, 1994, Chicago, IL.

² Aided by Project Grant DK-29961 from the National Institutes of Health, Bethesda, MD.

³ Department of Pathology.

⁴ Address correspondence to Thomas E. Starzl, M.D., Ph.D., 4C Falk Clinic, 3601 Fifth Avenue, Pittsburgh, PA 15213.

* Abbreviations: GVHD, graft-versus-host disease; PTLD, post-transplant lymphoproliferative disorder; TPN, total parenteral nutrition.

the immediate postoperative period, but the second patient survived under cyclosporine-based immunosuppression with well-functioning organs for 192 days. Including these two cases, eight attempts (4-6) at abdominal multivisceral transplantation under cyclosporine-based immunosuppression have been reported. All eight patients died, with the longest surviving 320 days.

With the advent of a new immunosuppressive agent, FK506, a clinical trial of intestinal transplantation was instituted at our center in May 1990 (7). Promising results with these initial cases prompted us once again to attempt abdominal multivisceral transplantation (8, 9). From October 1991 to the end of 1993, 13 patients underwent multivisceral transplantation at our center, 10 as a primary procedure and 3 for the attempted rescue of recipients of less-complex multivisceral grafts that had failed. Seven recipients are currently alive for 8 to 30 months.

MATERIALS AND METHODS

Patients. The 13 patients included 6 children who were 5.4 ± 3.9 years old and 7 adults with a mean age of 32.0 ± 7.1 years (age range 1.6 years to 44.8 years). Ten were primary recipients, and the other 3 had already failed a lesser intraabdominal transplant procedure. The procedure had to be abandoned in 2 additional candidates because of excessive bleeding during preliminary dissection of the native organs; both died. The indications for the 10 primary recipients included short bowel syndrome with ($n=4$) or without ($n=3$) TPN-related liver failure, mesenteric venous thrombosis with end-stage liver failure ($n=1$), juvenile polyposis ($n=1$), and malignant endocrine tumor ($n=1$). Although isolated intestine or combined intestine and liver grafting was considered for the short bowel patients, multivisceral transplantation was chosen because of the existence of thromboses of both the celiac axis and the superior mesenteric artery ($n=3$), TPN-related liver and pancreas failure ($n=3$), and pseudo-obstruction affecting the entire gastrointestinal tract ($n=1$). The 3 patients undergoing rescue multivisceral transplantation had undergone graft removal 2 months previously due to rejection of an isolated intestinal graft ($n=1$) or were bearing a rejecting intestine-liver ($n=1$) or liver ($n=1$) graft. The last patient also had intestinal

pseudo-obstruction since birth and should have undergone a multivisceral transplantation on the first occasion. The features of the 13 recipients are summarized in Table 1.

Donor operation. The grafts were obtained for ABO-blood type identical cadaveric donors with a mean age of 3.3 ± 3.4 years for the children and 21.6 ± 10.2 for the adults, ranging from 0.6 to 39 years. Lymphocytotoxic crossmatch was strongly positive in 2 recipients: one survives after 14 months and the other died of intractable cellular rejection after 58 days. HLA matching was random. Immediately after the donors were accepted, selective bacterial decontamination was initiated by the method described previously (8). Immunomodulation of donors or grafts by irradiation, ALG, or anti-T cell monoclonal antibody (OKT3) administration was not attempted.

The techniques for multivisceral graft harvesting have been described before (8, 10). En bloc retrieval of the multivisceral grafts includes four steps: dissection from the retroperitoneum of the stomach, liver, pancreas, spleen, duodenum, small bowel, and varying lengths of the colon; transection of the vena cava above and below the liver; removal of the celiac axis and the superior mesenteric artery in continuity with the anterior wall of the abdominal aorta; and transection of the gastrointestinal tract at the abdominal esophagus or proximal stomach and at the descending colon distally. University of Wisconsin solution (1-2 L) was flushed through the abdominal aorta for graft preservation. Splenectomy, Heineke-Mikulicz pyloroplasty, and luminal irrigation with 1-2 L cold lactated Ringer's solution were performed on the back table. Cold ischemia time from clamping of the donor aorta until graft revascularization in the recipient varied from 4.1 hr to 10.8 hr, with a median of 8.3 hr.

Recipient operation. The operative procedure was similar to that used originally in experimental animals 30 years ago (1, 2) and in the early clinical cases (3). In brief, arterial reconstruction was performed by end-to-side anastomosis of the Carrel patch containing both the celiac axis and the superior mesenteric artery to the side of the host infrarenal abdominal aorta. The donor thoracic aorta was used as an arterial graft. Venous outflow from the graft was via the hepatic graft, which was transplanted using the piggy-back method (11). Proximal gastrointestinal continuity was reconstructed by anastomosing the distal end of the recipient esophagus or the gastric stump to the anterior wall of the graft stomach. The terminal ileum ($n=3$) (Fig. 1A), or ascending, transverse, or descending colon ($n=10$) of the grafts was anastomosed in a side-to-side or end-to-side fashion

TABLE 1. Demographics of the 13 abdominal multivisceral transplant recipients

Patient	Age	Indication ^a	Preoperative TPN ^b		Graft ^c	Hospitalization		Survival ^d (days)	Cause of death
			Duration (months)	Total bilirubin (mg/dl)		ICU (days)	Discharge (days)		
1	32.6	CA & SMA thrombosis	36	0.5	MV without colon	60	196	>944	
2	24.3	CA & SMA thrombosis	3	1.3	MV without colon	11	119	>717	
3	4.2	Failed liver/intestine transplantation	50	23	MV with kidney	23		57	PTLD
4	31.5	Volvulus	15	4.6	MV without colon	43	111	>641	
5	4.5	Pseudoobstruction	54	26.1	MV	30	151	>559	
6	44.8	Malignant neuroendocrine tumor	0	0.7	MV	21		49	PTLD
7	1.8	Juvenile polyposis	22	0.5	MV without liver	17	87	>420	
8	32.6	Budd-Chiari syndrome	0	3.7	MV	120		197	Respiratory failure
9	10.9	Pseudoobstruction (after liver transplantation)	19	0.4	MV	7	76	>355	
10	9.3	Volvulus	24	8.3	MV	26	110	198	PTLD
11	34.9	Gardner's syndrome	26	18.1	MV	41	70	>281	
12	23.4	Failed intestine transplantation	163	1.2	MV	91		147	Sepsis
13	1.6	Intestinal atresia	19	58.2	MV	58		58	Rejection

^a CA: celiac axis; SMA: superior mesenteric artery.

^b TPN: total parenteral nutrition.

^c MV: multivisceral grafts include the stomach, liver, pancreas, intestine, and colon.

^d As of May 15, 1994.

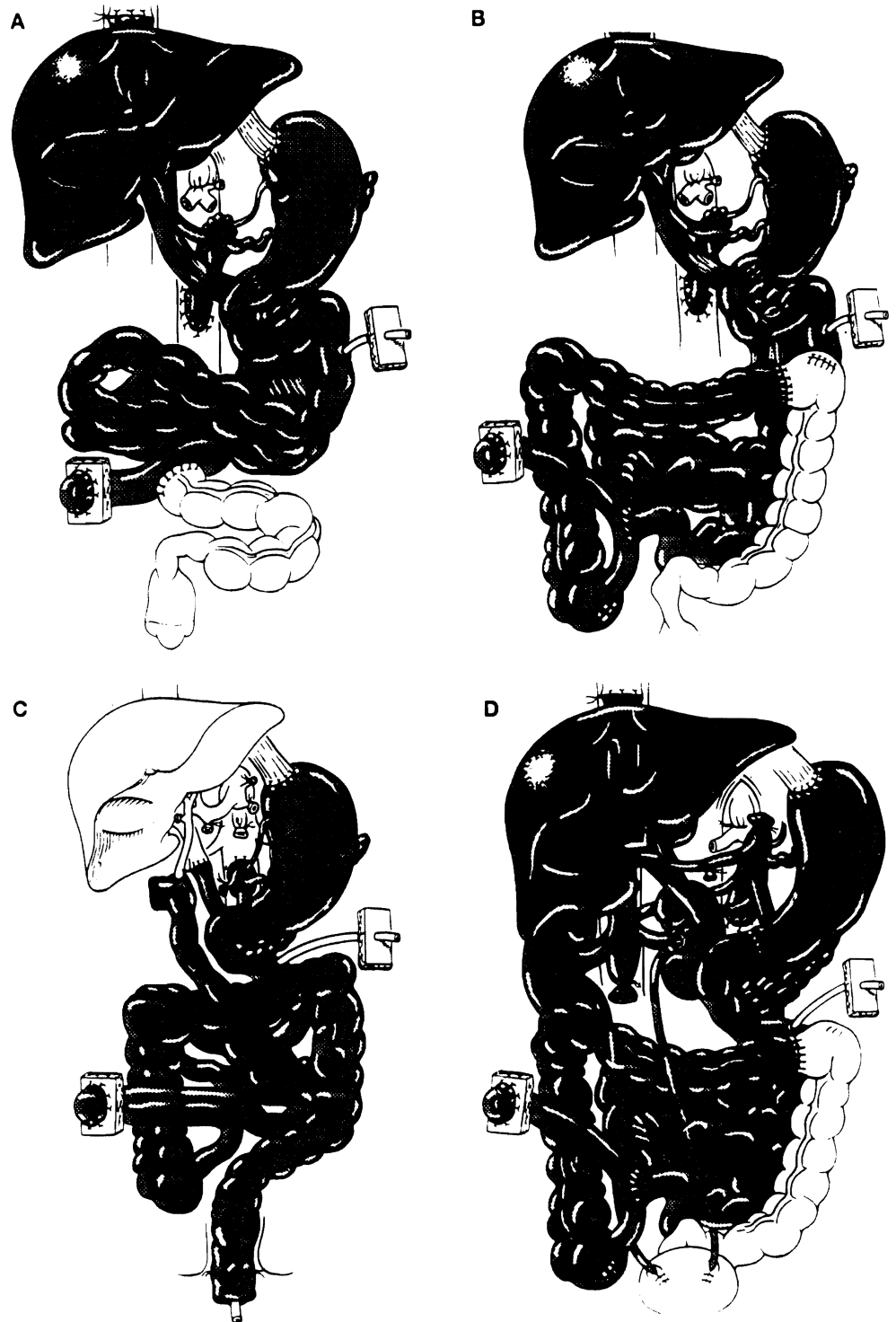


FIGURE 1. Scheme of multivisceral transplantation: (A) Multivisceral transplantation without colon; (B) Multivisceral transplantation with colon; (C) Multivisceral transplantation without liver and with rectal reconstruction by a pull-through technique; (D) Multivisceral transplantation with bilateral kidneys.

to the proximal end of the remaining recipient colon (Fig. 1B). Cholecystectomy was carried out in all cases, and a catheter was introduced via the cystic duct into the common bile duct for biliary decompression and postoperative cholangiogram. A tube jejunostomy, with terminal ileostomy ($n=5$), colostomy ($n=2$), or Bishop-Koop ileostomy ($n=6$), was made for enteric decompression, enteral feeding, and a route for endoscopic examination.

Modification of the procedure was required in some cases. Because of the profuse hemorrhage that precluded the operation in two patients with mesenteric venous thromboses, the celiac axis and the superior mesenteric artery were occluded in Case 8 by angiographic placement of intraaortic balloons immediately before starting the

procedure. This adult patient tolerated this modification and survived the operation with a blood loss of 26 units. In a pediatric patient with juvenile polyposis and a normal liver, the liver was omitted from the multivisceral graft (Fig. 1C). Her rectum was reconstructed by a pull-through technique. Kidneys were included with the multivisceral grafts in another pediatric patient who had renal insufficiency (Fig. 1D).

Postoperative management. Management of multivisceral transplant recipients after transplantation was the same as for isolated intestinal recipients, including methods of nutritional management and prevention of infection. FK506, steroids, and prostaglandin E1 (Prostin) were used for immunosuppression. Intravenous FK506 (0.1

to 0.15 mg/kg/day) was started intraoperatively, and was then switched to oral FK506 (0.3 mg/kg/day or slightly less) when the patient became tolerant to enteral feeding. Trough plasma levels of FK506 were maintained at 2–3 ng/ml for the first month, 1–2 ng/ml until the third month, and 1 ng/ml thereafter (Fig. 2). Methylprednisolone 1 g in adults or hydrocortisone in children was given intravenously immediately after the grafts were revascularized and was followed by rapid tapering of predonisone over 5 days after transplantation. Maintenance prostaglandin E₁ (0.6 to 0.8 µg/kg/hr) was continued until intravenous FK506 was stopped.

Monitoring of intestinal graft rejection was based on clinical findings, endoscopic examination, and histopathological study of endoscopy-guided biopsies. Treatment of intestinal rejection depended upon its severity as described before (8). Routine liver function tests were used to monitor liver rejection, and liver biopsies were taken if needed. Frequent measurements of amylase and lipase levels in blood and/or fluid in Jackson-Pratt drains were used to monitor pancreas rejection.

Assessment of graft function. Body weight, volume of stool output, frequency and nature of the stool, and dependency on TPN, enteral feeding, and/or oral diet were repeatedly evaluated to assess intestinal graft function. In addition, absorptive function was directly measured by D-xylose test and by 72-hr fecal fat secretion. Measurements of gastric emptying by radiolabeled test meals, intestinal transit time by a barium follow-through, and contractile activity by manometry were performed periodically to determine the motility of the gastrointestinal tract. Graft function of the liver and the pancreas was determined by serial determination of blood chemistries. Pancreatic endocrine function was periodically studied in long-term survivors by measuring blood glucose and c-peptide levels after intravenous injection of 0.5 g/kg glucose.

RESULTS

Survival. Of the 13 patients, 6/10 given primary grafts and 1/3 in which the multivisceral procedure was secondary are currently alive and well with follow-up of 9 to 31 postoperative months (Tables 1 and 2). Six are at home while one pediatric patient is currently hospitalized for the treatment of posttransplant lymphoproliferative disease (PTLD); this last patient's antidonor lymphocytotoxic crossmatch was

positive. With an actual patient survival of 7/13 (53.8%), the actuarial patient survival rates by the life-table method at 3 months, 6 months, one year, and 2 years are 76.9%, 69.2%, 53.8%, and 53.8%, respectively.

Causes of mortality. The 6 deaths occurred 1.5, 2, 2, 5, 6.5, and 6.5 months after the multivisceral transplantation (Table 1). Three of the 6 deaths were caused by PTLD, one by respiratory failure, one by rejection, and one by sepsis (Table 1). Two of the 3 deaths caused by PTLD occurred at 49 days and 198 days after primary transplantation; the third was 57 days after replacement of a rejected combined liver-intestine graft. In the last case, the rejection had followed reduction of immunosuppression at 10 months for the treatment of PTLD in the donor colon after the primary transplantation. At the time of the rescue multivisceral transplantation 15 months following the primary procedure, no PTLD lesions were detectable in the specimen or elsewhere.

Patient 8, who died from cytomegalovirus (CMV) infection, was CMV seronegative pretransplant and received grafts from a CMV-seropositive donor; although the infection was controlled, the lungs were destroyed. Patient 12, who was rescued from rejection of her isolated intestinal graft, was found to have a resistant intraabdominal infection with *Torulopsis glabrata* in the abdominal cavity at the time of retransplantation and died from this 5 months later.

Rejection. Ileal biopsies collected via the terminal ileostomy or the Bishop-Koop ileostomy showed rejection in 11 (84.6%) of the 13 recipients. On 162 occasions, the ileal biopsies were taken simultaneously with sampling from other sites: stomach (n=50), duodenum and/or jejunum (n=27), or colon (n=85). When the ileum had histological evidence of acute rejection, rejection was also found at the aforementioned sites at 0% (0/3), 25% (2/8), and 43.7% (7/16), respectively. Isolated rejection at these sites was found only once, at the jejunum in patient 7. Acute rejection of the stomach was never seen.

Rejection of the liver and the pancreas was less frequent

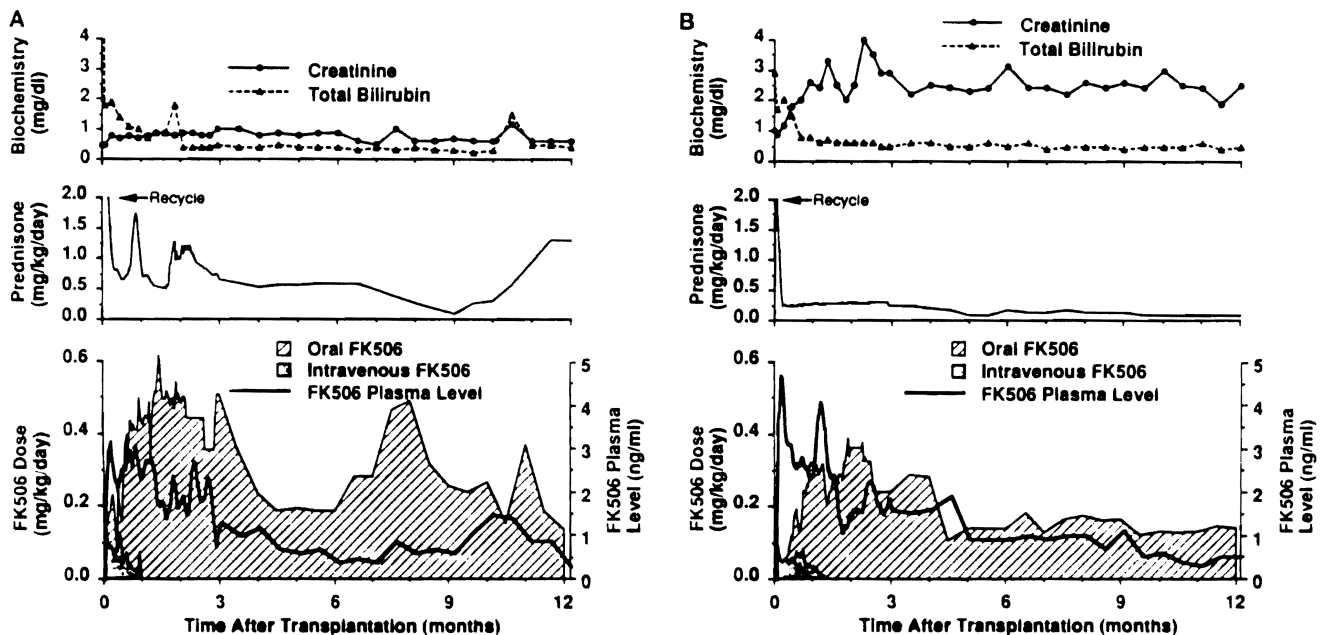


FIGURE 2. Immunosuppression and liver and kidney function. Values expressed as median. (A) Pediatric patients; (B) Adult patients.

TABLE 2. Current status of 7 survivors

Case ^a	Age	Survival ^b (days)	Location	Graft function							
				Gastrointestine				Liver		Pancreas	
				TPN	Stool	d-xylose (mg/dl)	fecal fat excretion (%)	GOT (U/L)	T. bil (mg/dl)	Blood sugar (mg/dl)	Treatment
1	32.6	994	Home	Free	Formed	32.5	48.2	30	0.5	121	Anti-DM agent
2	24.3	717	Home	Free	Formed	23.7	62.6	23	0.3	225	
4	31.5	641	Home	Free	Formed	34.1	23.5	44	1.0	72	
5	4.5	559	Home	Free	Formed	26.9	15.9	85	0.5	78	Insulin (15 U/day)
9	1.8	420	Hospital ^c	Free	Formed	32.8		50	0.3	75	
11	10.9	355	Home	Free	Formed		26.4	28	0.2	53	
12	34.9	281	Home	Free	Formed			39	0.6	126	

^a As shown in Table 1.

^b As of May 15, 1994.

^c Under treatment for PTLD.

and serious, with an incidence by clinical criteria of 46.2% (6/13) for the liver and 30.1% (4/13) for the pancreas. Increased immunosuppression for liver rejection was not required, but severe acute pancreatitis was caused by rejection in one patient after immunosuppression had been reduced.

No evidence of graft-versus-host disease (GVHD) was detected clinically or in the tissue samples (including 3 post-mortems) in any of the cases.

Complications. All recipients, except patient 9, had significant or life-threatening complications (Table 3), of which the 6 examples of PTLD were the most common. Of the 3 patients who survived PTLD, 2 have resolved lesions and the third is improving. The 5 intraabdominal abscesses were caused by leakage from the gastrostomy site (n=1), enteric perforation (n=2), and necrotizing pancreatitis (n=2). The pancreatic abscesses were apparently caused by preservation; one patient underwent total pancreatectomy (patient 8) and the other distal pancreatectomy (patient 11). Patient 12, who had necrosis and scarring at the muscle layer of the intestinal wall, required 5 separate enteric resections after each of 5 perforations over a time span of 1.5 months. Two adult recipients required transient dialysis for renal failure to which FK506 and nephrotoxic antibiotics appeared to be contributory (Figure 2). A persistent elevation of cannicular enzymes from ampullary dysfunction in patient 2 was relieved with endoscopic papillotomy, while another patient with this complication did not require intervention.

During the early postoperative period, enteric microorganisms, including *Enterococcus faecium*, *Enterococcus faecalis*,

Escherichia coli, and *Klebsiella*, were cultured from the peritoneal fluid and/or wound discharge of 12 (92.3%) of the 13 patients, in the sputum and/or bronchoalveolar lavage of 9 (69.2%), and in the blood and/or catheters of 12 (92.3%). All of the recipients who survived for more than 2 months after surgery developed a normal bacterial flora of the stool with bacterial overgrowth with >10⁹ colony forming units/ml.

Graft function. All 7 surviving recipients as well as patients who died after more than 3 months gained or maintained their body weight exclusively on an unrestricted oral diet (Table 2). Among the current survivors, the latest D-xylose absorption test was normal in all studied, but fecal fat excretion was universally elevated, especially in patient 2 who had 2 episodes of pancreas rejection. Motility function of the gastrointestinal tract was highly variable, and was influenced by the duration of follow-up. The trend in long survivors suggested recovery of normal gastric emptying and intestinal transit after one year (Fig. 3). However, manometric studies commonly showed that antral and intestinal contractions were hypoactive during fasting and after feeding, with absent migrating motor complex propagation, even later than one year.

Liver function is normal or near-normal in all of the surviving patients. Two of them require treatment for hyperglycemia caused by distal pancreatectomy (patient 11) or pancreas rejection (patient 2)—one with insulin and the other without. Changes in blood glucose and C-peptide in these 2 patients during an intravenous glucose tolerance test are shown in Figure 4.

TABLE 3. Complications

	Patients (%)	Comments (case) ^a
Major:		
PTLD	6 (46.2%)	Died (cases 3, 7, & 12), resolved (cases 2 & 5), resolving (case 9)
Abdominal abscess	5 (38.5%)	Due to intestinal perforation (cases 9 & 14), pancreatitis (cases 10 & 13), intestinal leakage (case 7)
Renal failure	3 (23.1%)	Required transient dialysis (cases 1 & 4)
Pancreatitis	3 (23.1%)	Due to preservation injury (cases 10 & 13), rejection (case 2)
Ampullary dysfunction	2 (15.4%)	Required endoscopic papillotomy (case 2)
Infectious: ^b		
Abdomen	12 (92.3%)	Wound, J-P drain, or discharge
Lung	9 (69.2%)	Sputum or bronchoalveolar lavage
Blood	12 (92.3%)	Blood or lines
Bacterial overgrowth	11 (84.6%)	>10 ⁹ CFU/ml by stool culture

^a Cases are shown in Table 1.

^b Positive culture of enteric microorganisms.

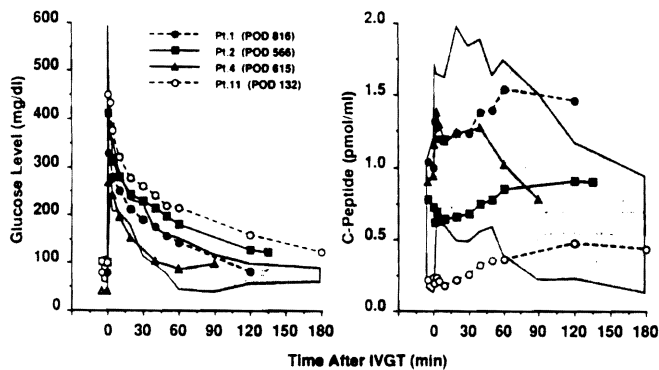


FIGURE 3. Blood level of glucose and C-peptide after intravenous glucose tolerance test. Glucose was given at a dose of 0.5 mg/kg. Shaded areas indicate range obtained from 5 normal controls. POD: postoperative days.

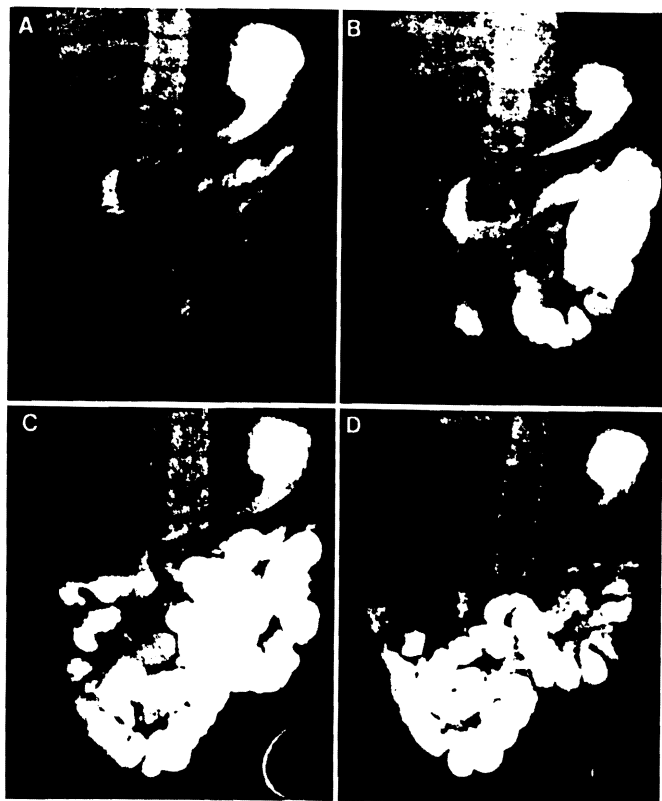


FIGURE 4. Barium follow-through of multivisceral recipient (patient 10). (A) 30 min; (B) 2 hr; (C) 3 hr; (D) 4 hr.

DISCUSSION

Our experience and that of others with multivisceral (3-6, 8, 9), liver-intestinal (7, 8, 12), and isolated intestinal (13-15) transplantation have delineated what can and cannot be achieved with all 3 of these procedures using current management methods. As with liver transplantation through the 1970s, the procedures that include intestine are feasible but impractical means of therapy that are not yet ready for general use. Although half the multivisceral recipients were restored to near normal health, including relatively complete dietary rehabilitation, the early and late mortality was ex-

cessive, with a lengthy list of complications even for patients who successfully ran the gauntlet of the first postoperative year.

The problems were much the same as those still seen with conventional liver transplantation, but they have been far more frequent and serious: incomplete control of rejection with consequent bacterial translocation throughout the damaged intestinal graft, a high rate of lethal septic complications, and the extraordinary 46% incidence of lymphoproliferative disorders. The most encouraging notation was the total absence of GVHD, which was feared at one time to make the intestine a forbidden organ for transplantation unless there was a perfect MHC match (16).

The next large advance is predicted to turn on a strategy that would have been an inconceivable proposal with the previous paradigm of transplantation immunology. However, the freedom from GVHD of these and other kinds of human intestinal recipients (7-9) can now be explained by the mutually canceling interactions of the coexisting cell populations following the transplantation of any whole organ that we have postulated to be the seminal mechanism of graft acceptance (17, 18). Lymphoid depletion of the graft, which was the consensus of workers in the intestinal transplantation field until recently (19-22), unbalances the graft-host-immunologic relation and appears to us to be unnecessary and probably contraindicated. When T cell depletion of the intestine was attempted in earlier clinical cases, there was an almost universal incidence of B cell lymphomas (3, 4, 6).

Armed with the realization that persistent spontaneous chimerism begins within minutes by migration of donor non-parenchymal cells from all grafts, and most dramatically from organs with a large hematolymphopoietic constituency, this timing has been simulated by perioperative infusion of 3×10^8 /kg unaltered bone marrow cells in 45 consecutive unconditioned human recipients of kidneys, livers, hearts, and lungs under conventional FK506-prednisone immunosuppression. The freedom of these patients from GVHD (trivial only in 2), their benignancy of recovery (all are well), and the demonstration of stable macrochimerism in the first 18 after 4 to 17 months (23) has generated plans to use the same treatment protocols for future intestinal recipients.

REFERENCES

1. Starzl TE, Kaupp HA Jr. Mass homotransplantation of abdominal organs in dogs. *Surg Forum* 1960; 11: 28.
2. Starzl TE, Kaupp HA Jr, Brock DR, Butz GW, Linman JW. Homotransplantation of multiple visceral organs. *Am J Surg* 1962; 103: 219.
3. Starzl TE, Rowe M, Todo S, et al. Transplantation of multiple abdominal viscera. *JAMA* 1989; 26: 1449.
4. Williams JW, Sankary HN, Foster PF, Lowe J, Goldman GM. Splanchnic transplantation: an approach to the infant dependent on parenteral nutrition who develops irreversible liver disease. *JAMA* 1989; 261: 1458.
5. Margreiter R, Konigsrainer A, Schmid T, et al. Successful multivisceral transplantation. *Transplant Proc* 1992; 24: 1226.
6. Grant DR. Small bowel transplantation. *Gastrointest J Club* 1992; 1: 3.
7. Todo S, Tzakis A, Abu-Elmagd K, et al. Cadaveric small bowel and small bowel-liver transplantation in humans. *Transplantation* 1992; 53: 369.
8. Todo S, Tzakis A, Abu-Elmagd K, et al. Intestinal transplanta-

- tion in composite visceral grafts or alone. *Ann Surg* 1992; 216: 223.
9. Abu-Elmagd K, Todo S, Tzakis A, et al. Intestinal transplantation: three years experience. *J Am Coll Surg* 1994; 179: 385.
 10. Starzl TE, Todo S, Tzakis A, et al. The many faces of multivisceral transplantation. *Surg Gynecol Obstet* 1991; 172: 335.
 11. Tzakis A, Todo S, Starzl TE. Orthotopic liver transplantation with preservation of the inferior vena cava. *Ann Surg* 1989; 210: 649.
 12. Grant D, Wall W, Mimeault R, et al. Successful small bowel/liver transplantation. *Lancet* 1990; 335: 181.
 13. Todo S, Tzakis A, Reyes J, et al. Small intestinal transplantation in humans with or without the colon. *Transplantation* 1994; 57: 840.
 14. Deltz E, Schroeder P, Gebhardt H, et al. Successful clinical small bowel transplantation: report of a case. *Clin Transplant* 1989; 3: 89.
 15. Goulet O, Revillon Y, Brousse N, et al. Successful small bowel transplantation in an infant. *Transplantation* 1992; 53: 940.
 16. Monchik GJ, Russell PS. Transplantation of small bowel in the rat: technical and immunological considerations. *Surgery* 1971; 70: 693.
 17. Starzl TE, Demetris AJ, Murase N, Ildstad S, Ricordi C, Trucco M. Cell migration, chimerism, and graft acceptance. *Lancet* 1992; 339: 1579.
 18. Starzl TE, Demetris AJ, Trucco M, et al. Cell migration and chimerism after whole organ transplantation: the basis of graft acceptance. *Hepatology* 1993; 17: 1127.
 19. Pomposelli F, Maki T, Gaber L, Balogh K, Monaco AP. Induction of graft versus host disease by small intestinal allotransplantation. *Transplantation* 1985; 40: 343.
 20. Shaffer D, Maki T, DeMichele SJ, et al. Studies in small bowel transplantation: prevention of graft versus host disease with preservation of allograft function by donor pretreatment with antilymphocyte serum. *Transplantation* 1988; 45: 262.
 21. Shaffer D, Ubhl CS, Simpson MA, et al. Prevention of graft vs. host disease following small bowel transplantation with polyclonal and monoclonal antilymphocyte serum: effect of timing and route of administration. *Transplantation* 1991; 52: 948.
 22. Diflo T, Monaco AP, Balogh K, Maki T. The existence of graft-versus-host disease in fully allogeneic small bowel transplantation in the rat. *Transplantation* 1989; 47: 7.
 23. Fontes P, Rao AS, Demetris AJ, et al. Augmentation with bone marrow of donor leukocyte migration for kidney, liver, heart, and pancreas islet transplantation. *Lancet* (in press).

Received 26 May 1994.

Accepted 13 July 1994.

0041-1337/95/5902-240\$03.00/0

TRANSPLANTATION

Copyright © 1995 by Williams & Wilkins

Vol. 59, 240-244, No. 2, January 27, 1995

Printed in U.S.A.

CENTRAL NERVOUS SYSTEM LYMPHOMAS IN ORGAN ALLOGRAFT RECIPIENTS^{1,2}

ISRAEL PENN³ AND GIL PORAT

Department of Surgery, University of Cincinnati Medical Center, Cincinnati, 45267-0558; and Cincinnati Veterans Affairs Medical Center, Cincinnati, Ohio 45220

Central nervous system (CNS) involvement occurred in 289 of 1332 patients (22%) with posttransplant non-Hodgkins lymphomas. The average time of appearance was 33 months (range 3 weeks to 248.5 months) posttransplantation. Lesions were confined to the CNS in 159 patients (55%), while 130 (45%) had involvement of other organs. Lesions involved the brain in 254 patients (88%), the brain and spinal cord in 5 (2%), the spinal cord in 2 (1%), unspecified locations in the CNS in 13 (4%), the meninges in 8 (3%), and the cerebrospinal fluid (CSF) in 7 (2%). All patients whose only involvement of the CNS was of the meninges or CSF had lymphomas involving multiple organs. Many tumors (48%) appeared within one year after transplantation. Brain lesions were frequently multicentric in distribution. Ninety-one (31%) of the 289 patients had no treat-

ment and died, 70 (77%) of their malignancies and 21 (23%) from other causes. Of 198 patients who received treatment 124 (63%) died of their malignancies; 40 (20%) died of other causes, including 17 patients who had had complete remissions following treatment; 22 (11%) are currently alive and in complete remission; and 12 (6%) are alive and still undergoing therapy. The treatment of choice is local radiotherapy to the brain, which either alone (18 patients) or in combination with other modalities (14 patients) caused 32 of the 39 (82%) complete remissions. Ten of 30 patients with disease localized to the CNS survived more than 5 years, including 6 who survived more than 10 years. CNS lymphomas should be suspected whenever a transplant patient has neurologic symptoms however minor, and prompt work-up is essential to eliminate other possible causes. The dismal prognosis can be improved only by early diagnosis and prompt therapy.

¹ Presented at the 20th Annual Meeting of the American Society of Transplant Surgeons, May 18-20, 1994, Chicago, IL.

² Supported in part by a grant from the Department of Veterans Affairs.

³ Address correspondence to Israel Penn, M.D., Dept. of Surgery, Univ. of Cincinnati, 231 Bethesda Ave., Cincinnati, OH 45267-0558.

The lymphomas are the most important group of all malignancies that occur de novo in organ transplant recipients. If nonmelanoma skin cancers and in situ carcinomas of the uterine cervix are excluded, as they are from most cancer