

1577

---

# Surgery of the Liver and Biliary Tract

---

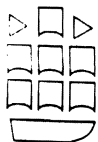
Edited by

**L. H. Blumgart** BDS MD FRCS (Edin) FRCPS (Glas) FRCS (Eng)

Enid A. Haupt Chair in Surgery,  
Diseases of the Liver and Biliary System,  
Memorial Sloan-Kettering Cancer Center,  
New York, USA  
Professor of Surgery,  
Cornell University Medical College,  
New York, USA

VOLUME 2

SECOND EDITION



CHURCHILL LIVINGSTONE  
EDINBURGH LONDON MADRID MELBOURNE NEW YORK AND TOKYO 1994

1577

---

# 129. Techniques of liver transplantation

*A. Casavilla R. D. Gordon T. E. Starzl*

---

Orthotopic liver transplantation is the treatment of choice for an expanding number of end-stage liver diseases (Gordon et al 1993). Although the first attempt at clinical application was made in 1963 and the first success was achieved at the University of Colorado in 1967, it was not until the introduction of cyclosporine at the beginning of the last decade that liver transplantation became accepted world-wide as an effective and preferred therapy for hepatocellular failure. In 1989, 1551 and 2160 grafts were transplanted in Europe and the USA, respectively, with 1-year patient survival rates exceeding 70% for most of the common indications for liver replacement (Gordon & Bismuth 1991). These results have continued to improve with better patient management and immunosuppressive protocols (Gordon et al 1991). Other factors that have contributed to success include improved patient selection and medical management prior to transplantation; non-invasive diagnostic methods including computed tomography (CT) scanning, Doppler ultrasound, and magnetic resonance imaging; new antibiotics, especially antiviral agents such as ganciclovir and acyclovir for control of opportunistic viral infections; improved donor selection and organ preservation; advances in anesthetic and peri-operative critical care; and, last but not least, improvements in surgical technique.

The technique of liver transplantation, as developed first at the University of Colorado in Denver and since January, 1981 at the University of Pittsburgh, is presented in this chapter. Many of these methods have been embraced by other liver transplant centers and provide the technical foundation for most of the liver transplantations being performed in the world today.

## THE DONOR OPERATION

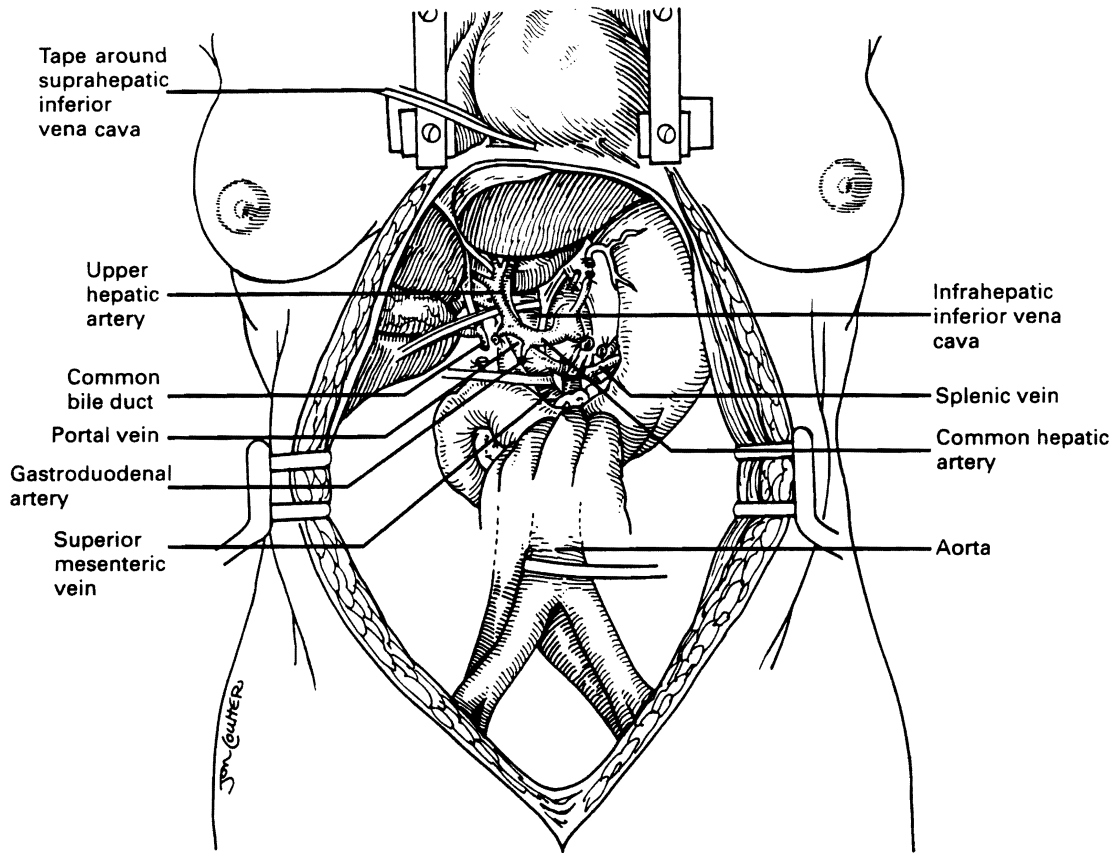
Procurement of a whole liver graft from a heart-beating, but brain-dead, cadaver donor remains the standard method of liver procurement and is usually carried out as part of a multiple organ retrieval that also includes the kidneys, pancreas, and thoracic organs. Cornea and other

tissues are often obtained, and occasionally intestinal grafts are being recovered (Casavilla et al 1992).

Multiple organ retrieval must be performed in a systematic way in heart-beating cadavers, using techniques of hemostasis and tissue handling that are no different from those utilized in routine general surgery. Among the factors that have improved liver procurement in recent years are the development of rapid modifications of the standard procurement method developed at the University of Pittsburgh in the early 1980s and the development by Belzer and associates of a new preservation solution, the University of Wisconsin (UW) solution (Starzl et al 1984, Kalayoglu et al 1988). Essential components of this solution include lactobionate, raffinose, hydroxyethyl starch, allopurinol, adenosine, and glutathione. These ingredients provide for membrane stabilization of both the hepatocytes and cells of the liver microvasculature, and provide osmotic conditions that prevent cellular swelling. With this new solution, preservation of the liver can be extended safely for at least 18 h. The development of UW solution has affected the logistical aspects of liver transplantation, and it has permitted a more accurate assessment of the liver graft using histologic and metabolic measurements which are now feasible because of the time made available for their application.

## The standard liver procurement and its modifications

The basic principle of the 'standard' procedure for liver retrieval is to carry out a complete mobilization of the liver with dissection of all of the vascular structures of the hepatic hilum, including the celiac axis and its tributaries, the superior mesenteric artery, the extrahepatic portal vein at the junction of superior mesenteric and splenic veins, and even the supra- and infra-hepatic segments of the vena cava (Fig. 129.1). The liver is precooled by infusion of cold preservation solution through the portal vein before cross-clamping the aorta. Throughout the dissection, unintentional ischemia may be caused by vascular



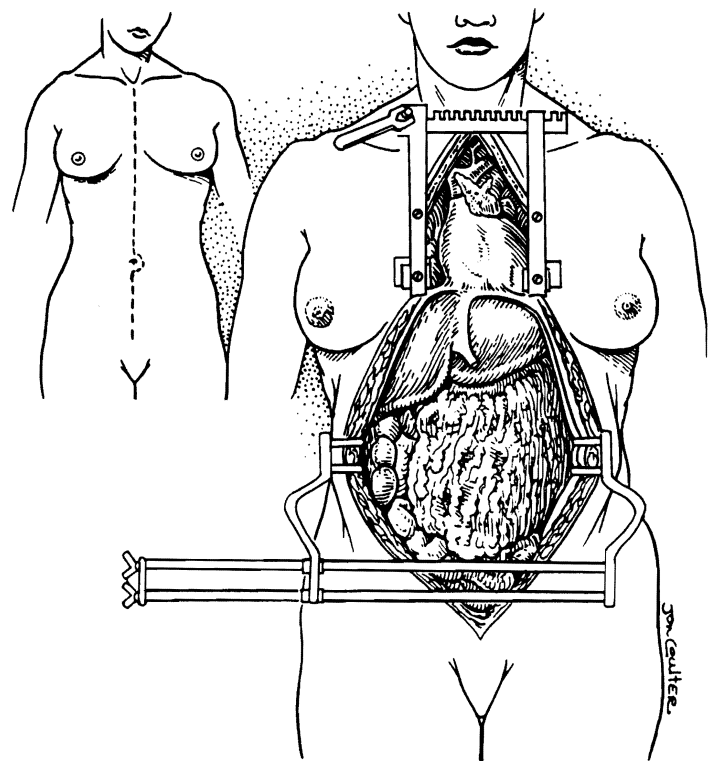
**Fig. 129.1** The 'standard technique' for liver retrieval. A complete dissection of the hepatic hilum is performed including ligation of the branches of the celiac axis and common hepatic artery.

compression or vasospasm occurring as a result of handling of the portal vein and hepatic artery. This time-consuming dissection is not possible in hemodynamically unstable donors. Moreover, it delays the procurement of other organs, especially the heart. Therefore, this tedious operation has been abandoned by the majority of liver transplant centers in favor of a more rapid technique.

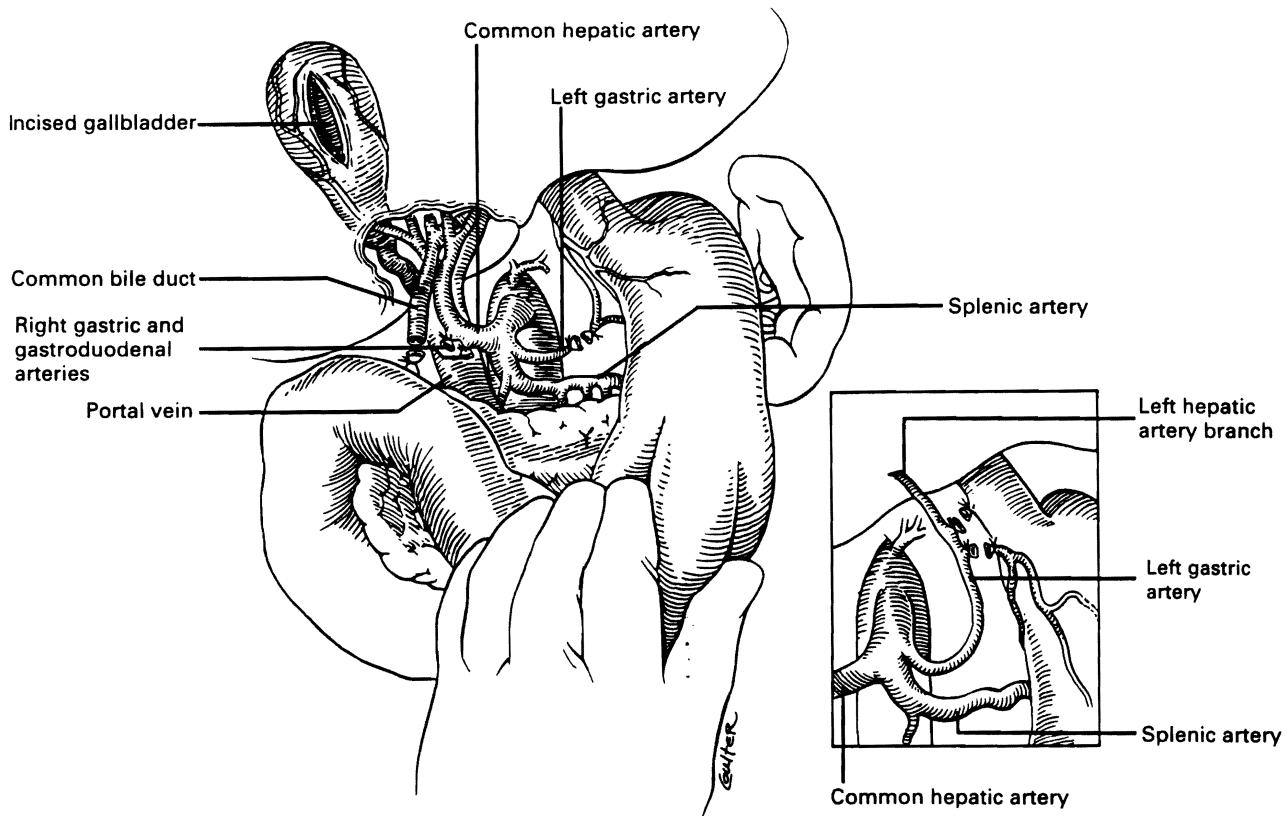
At the University of Pittsburgh, the 'modified' technique is the procurement method of choice in stable donors. It enables the teaching and training of relatively inexperienced surgeons in the performance of a donor hepatectomy without necessitating a lengthy dissection. Once this technique of organ extirpation and cooling is mastered, faster methods can be learned and later used if necessitated by the clinical situation. The basic principles are the same for all procedures.

*The modified operation*

A midline incision is made from the suprasternal notch to the pubis (Fig. 129.2). After it has been verified that the liver has a normal consistency and color, the left suspensory ligament is incised. This allows the left lobe to be retracted to the right, thereby exposing the upper part of the gastrohepatic ligament. There is often a left hepatic arterial branch within the gastrohepatic ligament



**Fig. 129.2** A midline incision from the sternal notch to the pubis is routinely used for exposure of the thorax and abdomen in the cadaver organ donor.



**Fig. 129.3** Hilar dissection in the 'modified donor hepatectomy'. The left gastric artery may send a terminal branch to the left lateral segment of the liver and this branch should be preserved (inset). The right gastric and gastroduodenal arteries are divided. The common bile duct is divided distally and the gallbladder is incised to flush the biliary tree.

originating from left gastric artery which, if present, must be preserved in continuity with the main left gastric artery and the celiac axis (Fig. 129.3, inset). By lifting the stomach anteriorly (Fig. 129.3), the left gastric artery can be easily ligated and divided. More distally, the right gastric and gastroduodenal arteries are also ligated and divided. If this succession of steps is followed, subsequent dissection of the common duct and the portal vein is rendered nearly bloodless; otherwise, the richly vascularized pancreas and duodenum bleed throughout the dissection.

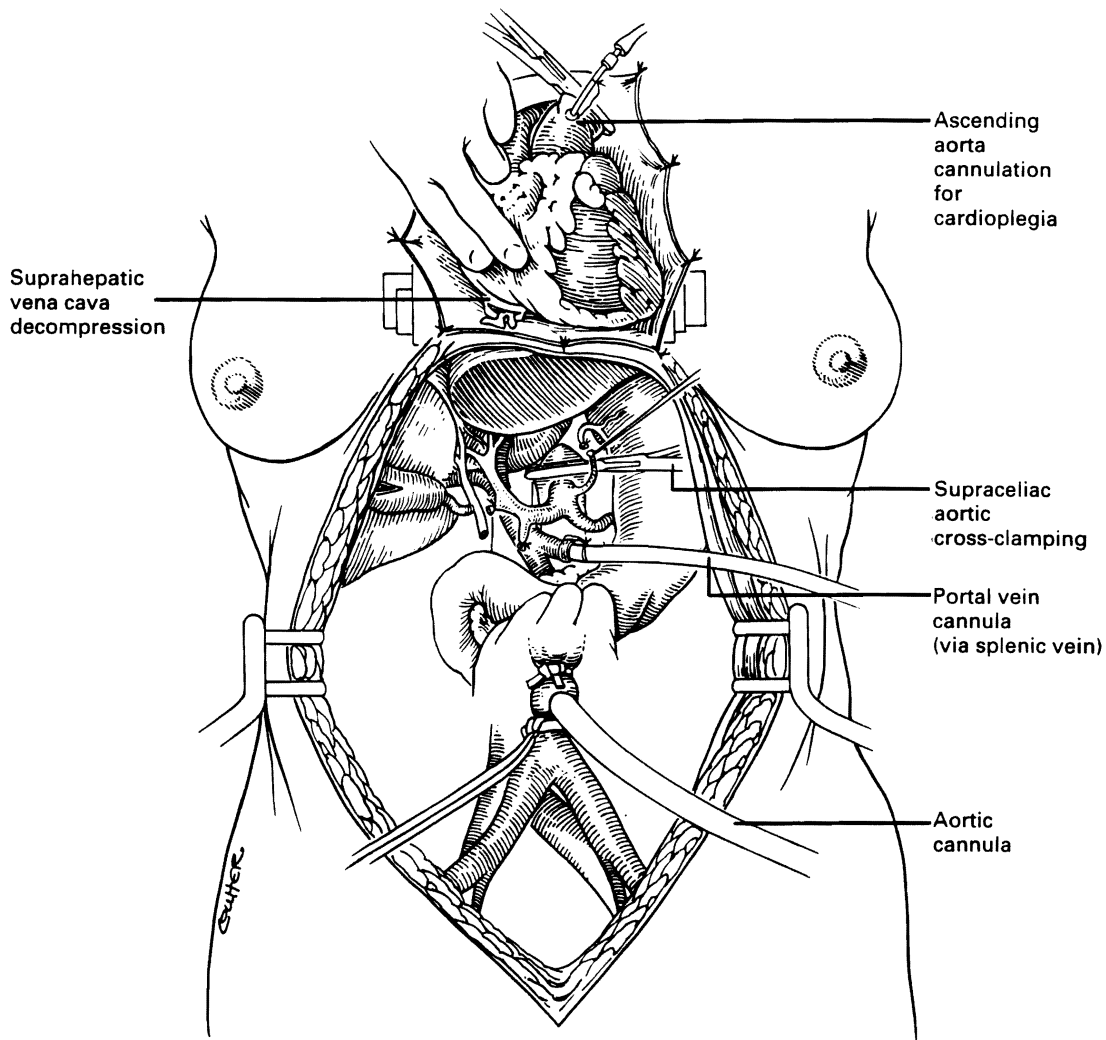
The common duct is transected as far distally as possible. The gallbladder is incised, permitting the bile to be washed out to avoid autolysis of the extrahepatic and intrahepatic bile duct epithelium during storage. The portal vein is then dissected inferiorly until the confluence of the splenic and superior mesenteric vein is reached. The aorta, both at its passage through the diaphragm and just proximal to its bifurcation, is dissected free and encircled. Next, cannulas for infusion are placed into the splenic vein and, after total body heparinization, into the distal aorta (Fig. 129.4).

When all teams are ready, the diaphragmatic portion of the aorta is cross-clamped along with the ascending aorta by the liver and cardiac surgeons, respectively. Then, moderately rapid infusion of cold UW solution into the splenic vein and terminal aorta is started, while

cardioplegic solution is infused into the midportion of the ascending aorta. Simultaneous decompression of the liver is achieved by bleeding the suprahepatic inferior vena cava into the pericardium (Fig. 129.4)

In adults, the liver will usually feel cool after 1 l of infusion through both the splenic vein and aorta. In children, smaller volumes are used. Once the liver becomes palpably cold and free of blood, and the heart has been removed, further dissection to complete the hepatectomy can be carried out. This portion of the operation must be performed expeditiously and methodically. The splenic artery is ligated and divided behind the body of the pancreas which is retracted caudally. The proximal segment of the splenic artery should be preserved with the hepatic arterial supply, since it may be required for reconstruction of an anomalous right hepatic artery, if present (see Fig. 129.10).

Next, the left gastric and splenic arteries are followed as far proximal as possible, the superior mesenteric and splenic veins are cut near their junction, preserving the splenic cannula, and the portal vein is freed completely. The three vascular structures (left gastric artery, splenic artery and portal vein) are rotated to the right upper quadrant and the duodenum and pancreas are mobilized using a Kocher maneuver. This exposes the area posterior to the portal vein, which must be inspected carefully for



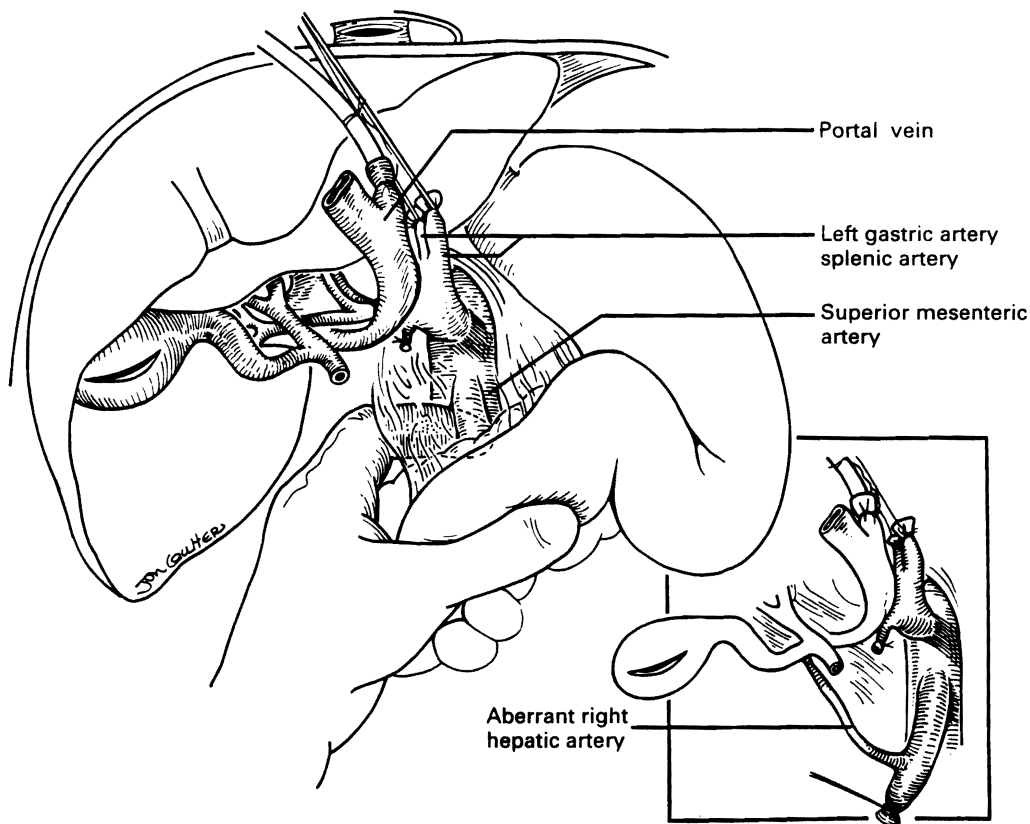
**Fig. 129.4** In situ infusion technique used when the heart, kidneys and liver are removed from the same donor. University of Wisconsin preservation solution is infused into the splenic vein and distal aorta with simultaneous venting of the suprahepatic inferior vena cava into the pericardium. The cannulation and cross-clamping of the thoracic aorta for cardioplegia are also shown.

the presence of an aberrant right hepatic artery originating from the superior mesenteric artery (SMA) (Fig. 129.5, inset). This is approached by retracting the duodenum and pancreas caudally with the left hand in supination; the SMA is felt as a tense cord behind the pancreas (Fig. 129.5).

If the pancreas is not to be recovered, the SMA is identified and transected as far distally as possible in a retropancreatic location; then, it is traced with sharp dissection to its aortic origin along the left lateral and inferior aspects, and removed with a Carrel patch containing the celiac axis. Alternatively, the right lateral aspect of the SMA can be dissected toward the aorta; if a right hepatic artery is present, the steps discussed above must be followed (Fig. 129.5, inset). If no aberrant right hepatic artery branch is found, further dissection of the

superior mesenteric artery is unnecessary and only the origin of the celiac axis is detached from the aorta with a Carrel patch.

At this point, the infrahepatic vena cava is cleaned and transected above the entry of the left and right renal veins (Fig. 129.6). As a final step, a patch of diaphragm surrounding the suprahepatic inferior vena cava is incised. Care must be taken not to injure the esophagus on the left side, or the upper pole of the right kidney, while splitting the right adrenal gland on the right posterior side of the liver. The latter is facilitated by lifting the liver cephalad and anteriorly (Fig. 129.6). The liver is then removed with a piece of diaphragm and with part of the right adrenal gland. The graft is immediately placed in a preservation solution-filled bag which is packed in ice until the liver is ready to be used.



**Fig. 129.5** The left gastric and splenic arteries and the distal portal vein are transected and mobilized to the right upper quadrant. A Kocher manoeuvre is performed to free up the duodenum and head of the pancreas. The surgeon inspects and palpates for the presence of an anomalous right hepatic artery originating from the superior mesenteric artery (inset) in the tissues behind the portal vein.

### *The 'rapid' and 'super rapid' techniques*

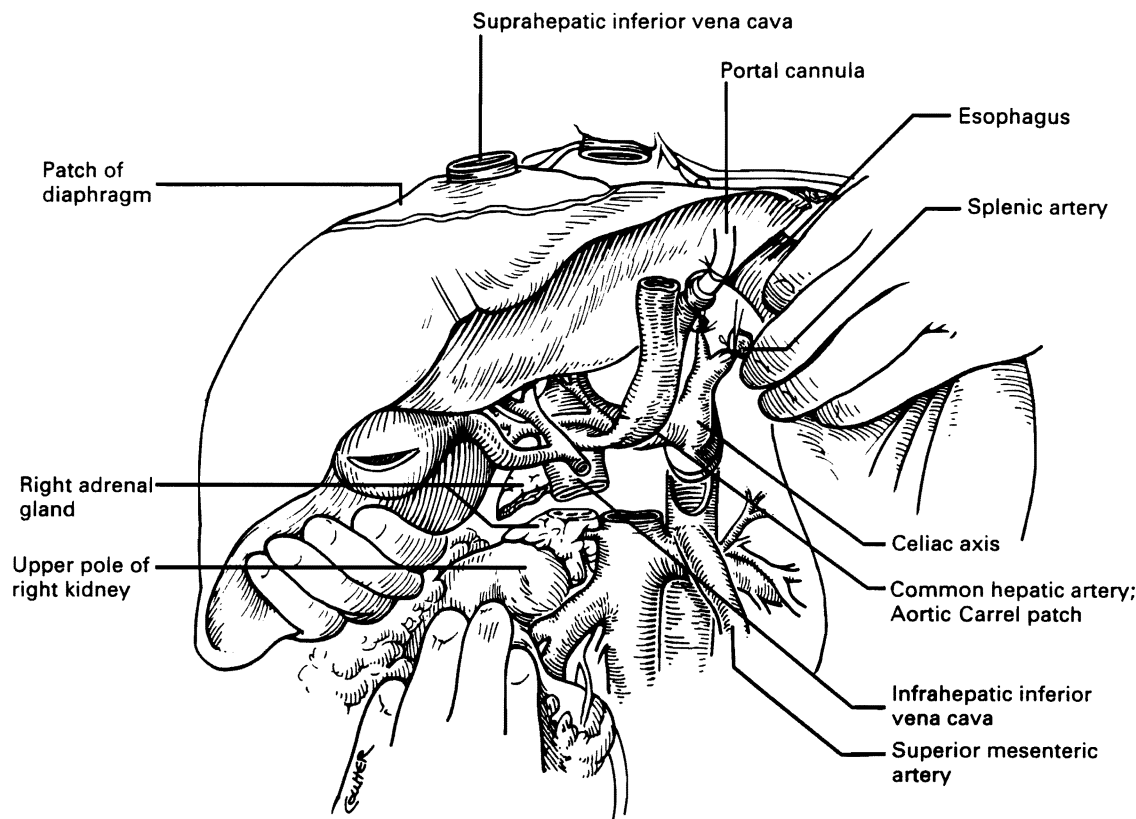
Although completion of the 'modified' technique requires only 30–45 min of an experienced surgeon's time, it may not be quick enough for procurement in donors who become unstable prior to or during the dissection. Once the basic 'modified' operation has been mastered, the 'rapid' and 'super rapid' techniques are easily learned. With the former, no preliminary dissection is done except for encirclement of the supraceliac aorta followed by ligation and cannulation of the inferior mesenteric vein and terminal aorta.

If the heart is to be removed, the cardiac surgeon proceeds as if no other organs are to be harvested, but gives a warning when the circulation is stopped. At that moment, the aorta is cross-clamped at the diaphragm, and an infusion of cold UW solution is started in both the inferior mesenteric vein and the distal aorta (Fig. 129.7). The liver blanches free of blood with surprising rapidity, provided the vena cava is decompressed by bleeding off infusate into the pericardium.

In adults, approximately 2 l of cold preservation solution are infused into both the mesenteric venous and

systemic arterial systems to chill the liver; then the infusions are slowed. The main vessels of the celiac axis can be ligated swiftly and the hilar dissection can be completed in a matter of minutes. The portal vein is cleaned inferiorly to the junction of the splenic and superior mesenteric veins and these individual tributaries are divided. After lifting the portal vein anteriorly, the surgeon promptly excludes the possibility of a missed right hepatic artery coming from the superior mesenteric artery. The liver is then excised by the same technique as described previously, taking fragments of the diaphragm and right adrenal gland with the specimen. Cold perfusion of the kidneys via the aorta can be continued slowly as the nephrectomies are performed.

With the ability to perform all dissections in a bloodless field using the 'rapid' method, it is possible to carry out multiple organ removal including the heart, liver and both kidneys in about half an hour. In arrested or non-heart-beating donors, such as those in countries which do not have 'brain death' laws or in special (legal, religious, etc.) circumstances, an even quicker procedure is necessary to procure satisfactory organs. The 'super rapid' technique involves immediate cannulation of the distal



**Fig. 129.6** The suprahepatic vena cava is included in a generous patch of diaphragm removed with the liver. The liver is retracted towards the thorax and the infrahepatic vena cava is divided just above the origin of the renal veins. The esophagus and right kidney are retracted laterally and caudally, respectively. The celiac axis is removed as a Carrel patch including anterior aorta. If an anomalous right hepatic artery originating from the superior mesenteric artery is present, the origin of the superior mesenteric artery is also included in the Carrel patch (see Fig. 129.10B).

aorta and initiation of cold perfusion with preservation solution when no effective circulation is present. Subsequently, sternal splitting, thoracic aorta cross-clamping and severance of the suprahepatic inferior vena cava for hepatic decompression are performed, followed by cannulation of the inferior mesenteric vein and cold perfusion of the portal system (Fig. 129.8). The next steps resemble those of the 'rapid technique'. With this 'super rapid' technique, satisfactory liver grafts can be removed from donors that have lost their heart beat within minutes of initiating the preperfusion dissection. However, a much higher level of skill is required to do this operation.

#### Backtable procedure and vascular reconstructions

Final preparation of the liver to be transplanted is accomplished in a basin containing sterile ice slush (Fig. 129.9). This entails:

- Dissection and removal of extraneous tissue, such as diaphragm, adrenal gland, lymph nodes, pancreatic, peripancreatic and ganglionic tissue
- Preparation of all vascular cuffs, including suprahepatic and infrahepatic vena cava, portal vein, and artery(ies), as well as the bile duct for anastomosis

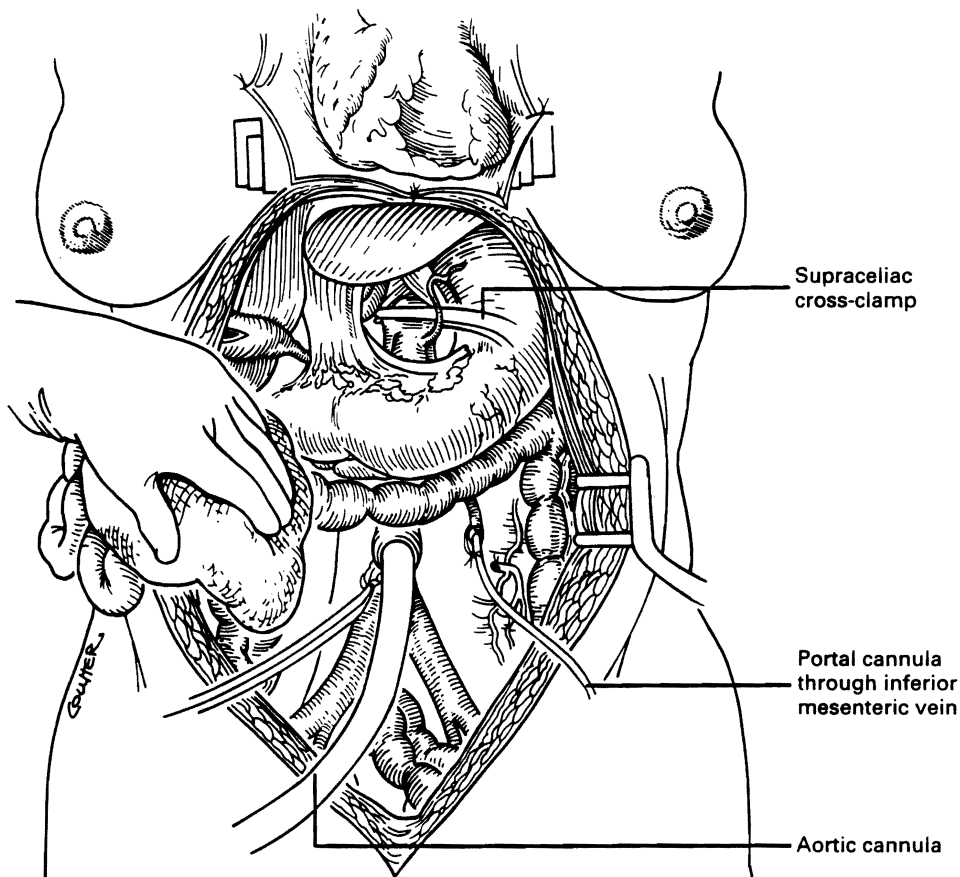
- Verification of secure ligatures on small retrohepatic caval, portal vein, and hepatic arterial branches.

Several methods of vascular reconstruction have been designed to repair technical accidents, aberrant vessels or congenital anomalies. Regardless of the circumstances, these must be repaired at this stage so that the graft is completely ready for implantation when it is brought up to the recipient operative field. Failure to do so may result in irreversible damage to the graft and a failed recipient operation.

If an anomalous right hepatic artery arising from the superior mesenteric artery is present, the technique of reconstruction most often used is an end-to-end anastomosis between a patch of superior mesenteric artery surrounding the origin of the right branch and the splenic artery (Fig. 129.10).

#### Simultaneous liver and pancreas procurement

The pancreas can be retrieved either independently or together with the liver. Prior to starting the procurement, the operation should be discussed by both the liver and pancreas surgeons, so that all factors (organ priority, type and amount of preservation solution to be used, presence



**Fig. 129.7** In the 'rapid' technique of retrieval, the initial dissection is limited to the exposure needed for the insertion of perfusion cannulas in the inferior mesenteric vein and distal aorta, and for cross-clamping of the aorta at the diaphragm.

of aberrant hepatic arteries, length of the portal vein, and the choice of which organ retains the celiac axis) are considered in advance of the actual procurement procedure.

In principle, the guidelines are as follows:

1. Long segments of iliac arteries and veins must be removed, since they can be used as vascular grafts to reconstruct the blood supply of the liver or pancreas.

2. The liver should retain almost all of the portal vein while the short portal vein of the pancreatic graft is lengthened, if necessary, with an iliac vein graft from the donor.

3. If no anomalous hepatic artery is found, the proximal common hepatic artery is transected. The pancreas retains the celiac axis and superior mesenteric artery, and the common hepatic artery is retained with the liver and lengthened, if required, with a free iliac artery graft.

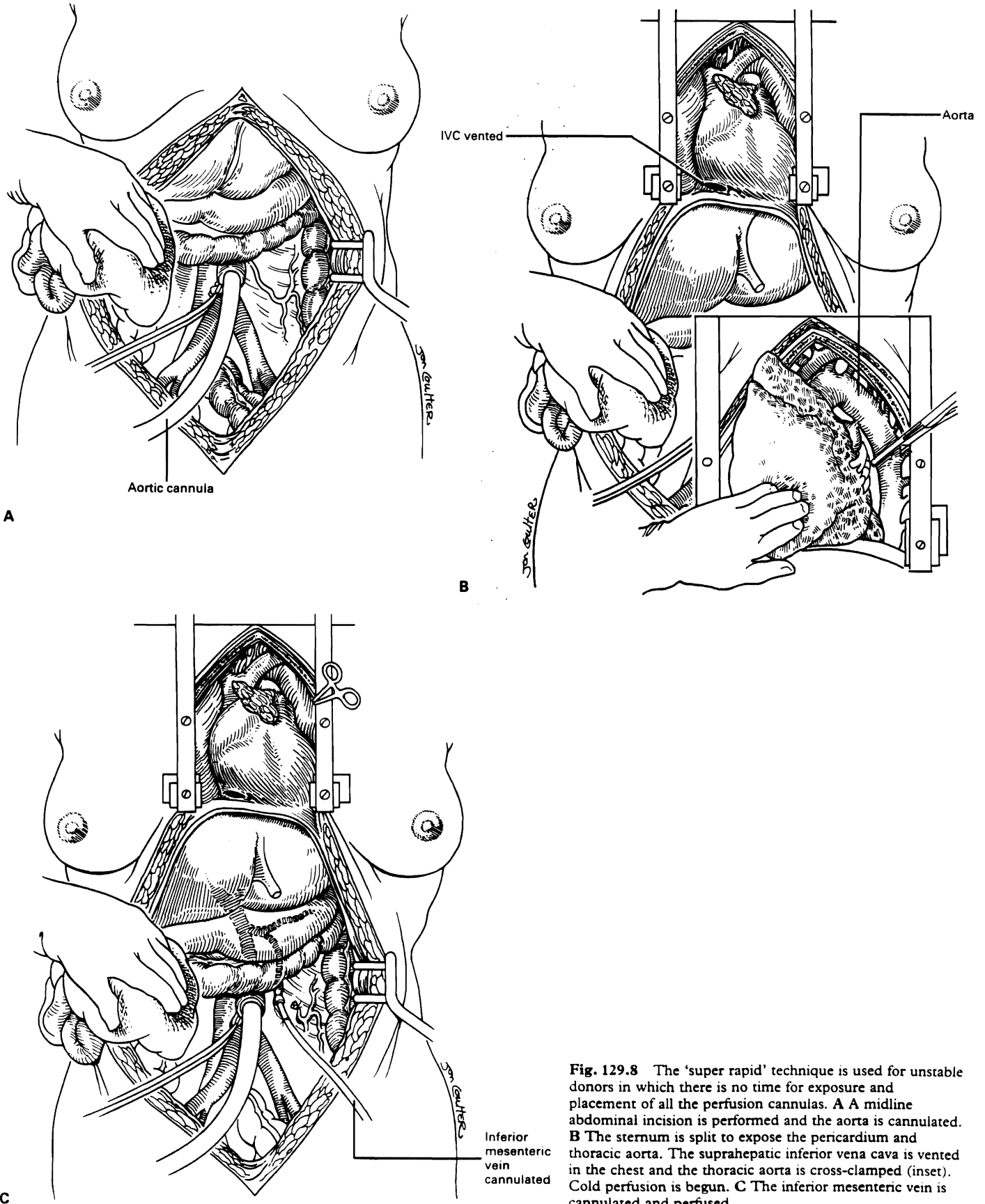
4. If an aberrant left hepatic artery is present, retention of the celiac axis with the liver is mandatory. The splenic artery must be transected near its origin from the celiac axis. The addition of a common iliac artery graft at its bifurcation can be used for extending both the splenic and superior mesenteric arteries.

5. Under special circumstances, in the presence of an aberrant right hepatic artery, pancreas retrieval for whole organ implantation is precluded, unless the anomalous artery is so small that it can be disregarded or its considerable size permits later reconstruction with a vascular graft without jeopardizing the viability of the liver.

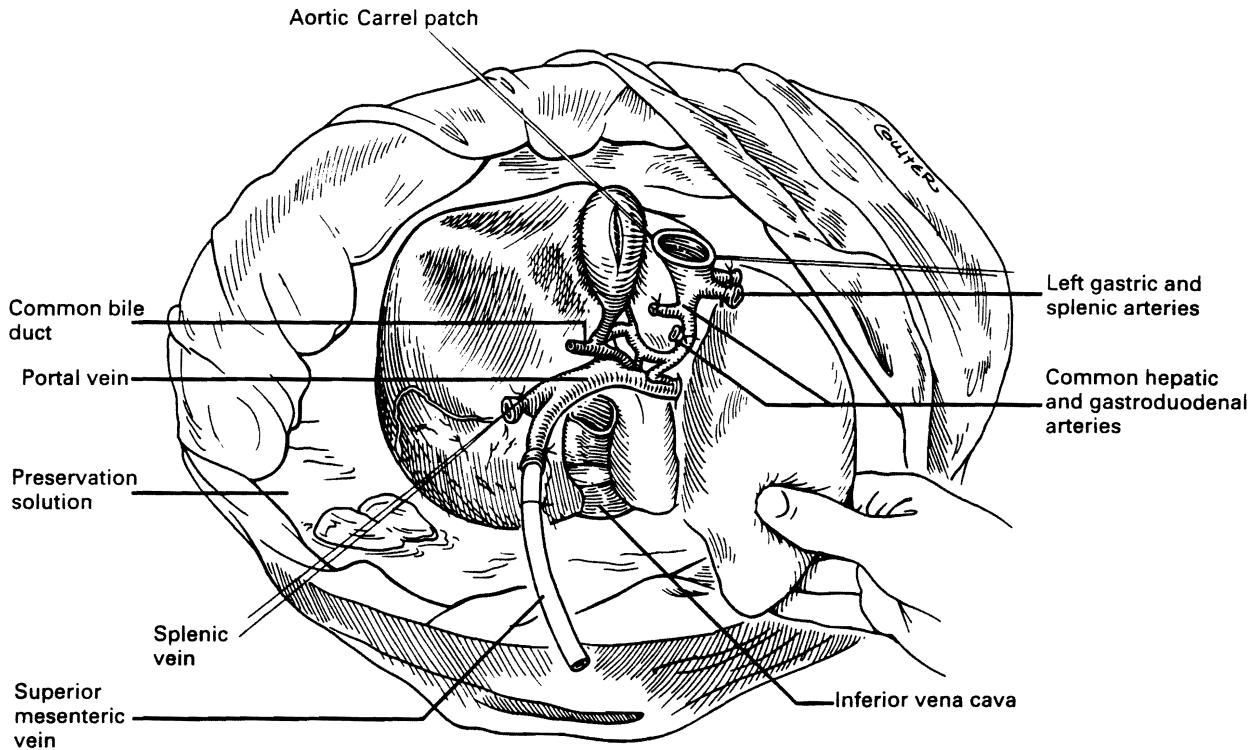
#### THE RECIPIENT OPERATION

The recipient procedure tends to be long and physically demanding. Its different parts are so remarkably dissimilar that a single surgeon operating from 'skin to skin' may find it difficult to change emotional and intellectual gears to keep pace with the changing events. For example, removal of the diseased liver may be one of the most difficult challenges a surgeon will face. Yet, the vascular anastomoses can be among the most delicate and sophisticated procedures one performs, especially in very small children. Achieving perfect hemostasis after the donor liver has been revascularized is crucial, since failure can ruin all that has been accomplished, but it is often a tedious exercise faced after many hours of demanding surgery. Lastly, the biliary tract reconstruction becomes the final thread on which the whole enterprise is suspended.

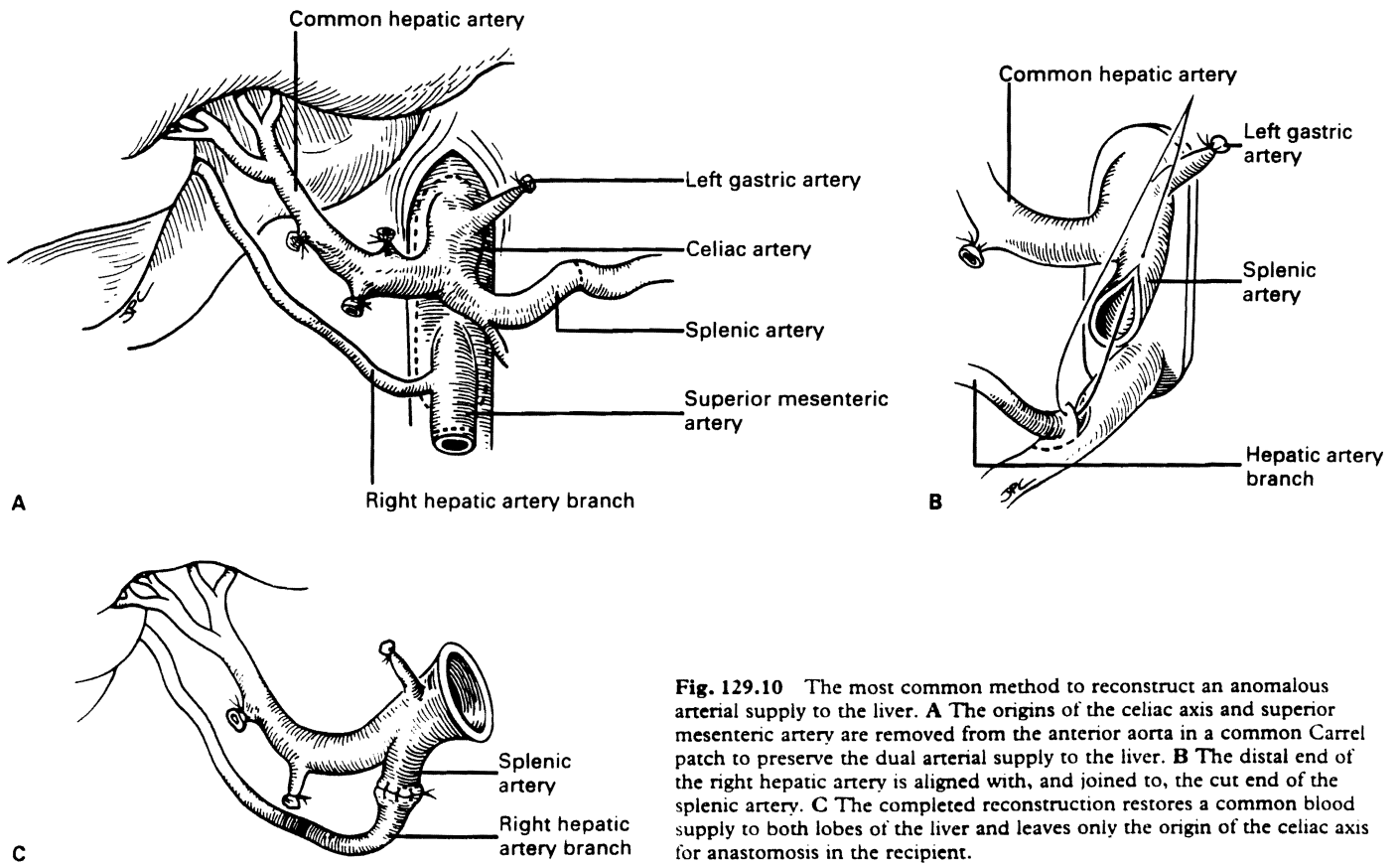




**Fig. 129.8** The 'super rapid' technique is used for unstable donors in which there is no time for exposure and placement of all the perfusion cannulas. **A** A midline abdominal incision is performed and the aorta is cannulated. **B** The sternum is split to expose the pericardium and thoracic aorta. The suprahepatic inferior vena cava is vented in the chest and the thoracic aorta is cross-clamped (inset). Cold perfusion is begun. **C** The inferior mesenteric vein is cannulated and perfused.



**Fig. 129.9** The liver graft is placed in a basin containing iced preservation solution for backtable preparation. The vascular cuffs are debried of excess tissue and any needed arterial reconstruction is performed (see Fig. 129.10).



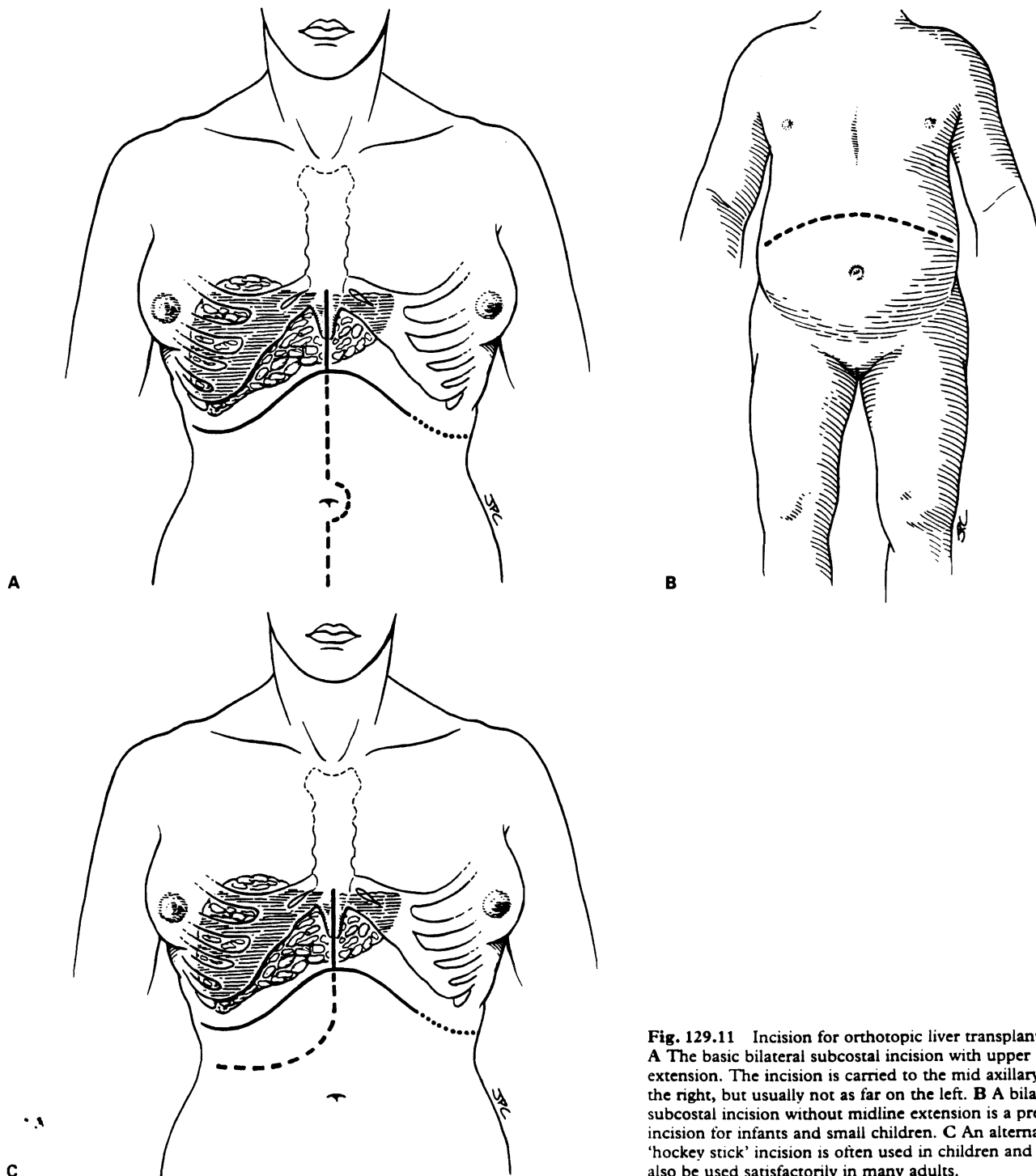
**Fig. 129.10** The most common method to reconstruct an anomalous arterial supply to the liver. **A** The origins of the celiac axis and superior mesenteric artery are removed from the anterior aorta in a common Carrel patch to preserve the dual arterial supply to the liver. **B** The distal end of the right hepatic artery is aligned with, and joined to, the cut end of the splenic artery. **C** The completed reconstruction restores a common blood supply to both lobes of the liver and leaves only the origin of the celiac axis for anastomosis in the recipient.

### Abdominal incision and exposure

The exact location of the incisions is dictated by any previous right upper quadrant surgery, the presence of an ileostomy, and by the size and configuration of the liver. A bilateral subcostal incision, extending on the right to just beyond the midaxillary line and on the left to just short of the anterior axillary line, with an upper midline extension and excision of the xiphoid process, is the

most commonly used incision (Fig. 129.11A). A lower midline extension may be needed, such as in patients with extensive prior surgery or multiple adhesions, in patients requiring exposure of the infrarenal aorta for reconstruction of the hepatic arterial supply, and in tumour patients in whom an extended dissection with upper abdominal exenteration is to be performed. Thoracic extensions are rarely needed.

The preferred incision in infants and small children is



**Fig. 129.11** Incision for orthotopic liver transplantation. **A** The basic bilateral subcostal incision with upper midline extension. The incision is carried to the mid axillary line on the right, but usually not as far on the left. **B** A bilateral subcostal incision without midline extension is a preferred incision for infants and small children. **C** An alternative 'hockey stick' incision is often used in children and can also be used satisfactorily in many adults.

a bilateral subcostal incision (Fig. 129.11B). The upper midline extension used in adults is usually not necessary. In pediatric patients and in many adults an upper midline incision with extension at a level just above the umbilicus to just beyond the right midaxillary line may be used (Fig. 129.11C) instead of the traditional subcostal approach. This provides better access to the infrarenal aorta when exposure is needed for reconstruction of the hepatic artery and is less disfiguring than the standard bilateral subcostal incision. However, in patients with a massively enlarged liver or a large left lobe, extensive prior abdominal surgery, or in those requiring concomitant splenectomy, such as to interrupt a prior splenorenal shunt, the incision may need to be extended to the left or the standard incision used instead.

Adequate exposure can usually be achieved with these incisions and the use of the Rochard or other rib retraction device retractor which permit access to the hepatic veins and suprahepatic vena cava (Fig. 129.12).

Making the incision and obtaining exposure of the hepatic hilum and vena cava can be a formidable task, particularly if there have been previous upper abdominal operations. It may be necessary to abandon delicate conventional techniques with meticulous hemostasis and resort to continuous hemostatic suturing along the cut edges of the fascia and preperitoneum. Once the abdomen is entered, an effort must be made to find a plane of dissection just outside the liver capsule. Movement away from this plane risks an encounter with major venous

collaterals, which can result in disastrous hemorrhage early in the operation.

### General assessment and determination of surgical strategy

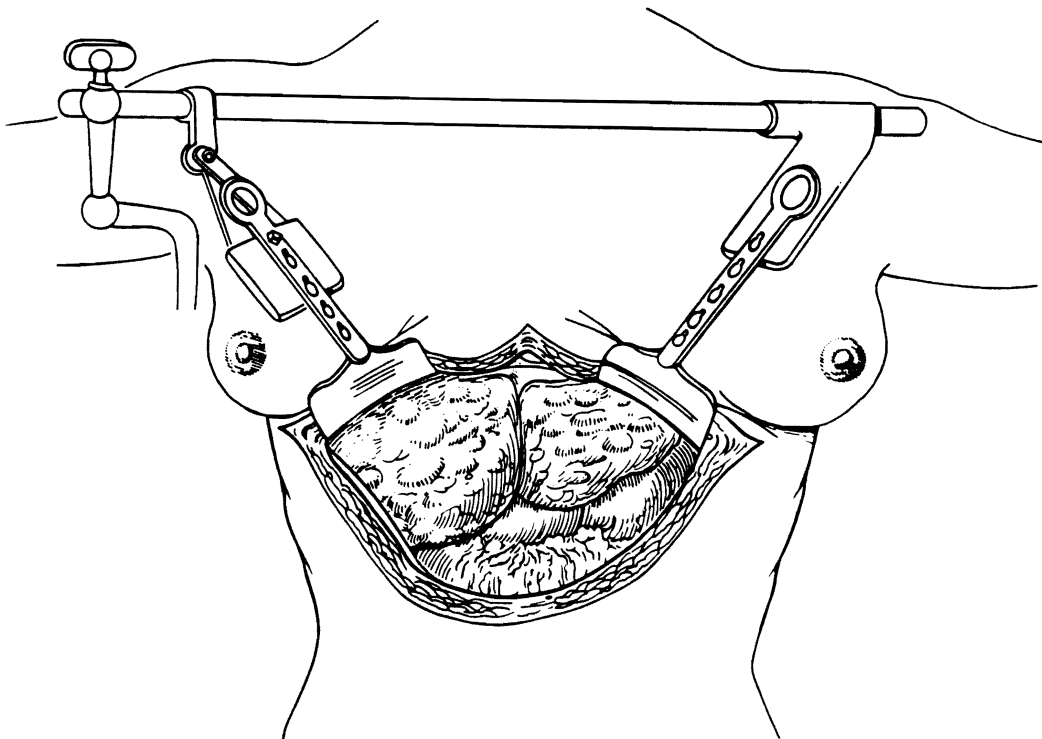
There is no single best way to remove a diseased native liver. Once exposure has been obtained, it is important to assess the pathology and decide upon whatever technical approach best fits the situation. A surgeon who insists upon following the same steps in unvarying order for all recipient hepatectomies will suffer unnecessary hardship. The following is a description of the basic technique of recipient hepatectomy.

#### *Hilar dissection*

The individual structures of the hilum are skeletonized. The hepatic artery and common duct are ligated as near to the liver as possible. The hepatic artery is skeletonized to a level proximal to the gastroduodenal take-off. Mobilization of the hepatic artery facilitates exposure of the proximal portal vein. The suprapancreatic extrahepatic portal vein is completely freed. Once the hilar dissection is accomplished (Fig. 129.13), veno-venous bypass is initiated.

#### *Venovenous bypass*

The most critical stage of the recipient operation is the



**Fig. 129.12** Exposure is facilitated by the use of self retaining retractors, such as the Rochard device shown here, applied to the costal margins.




Fig. 129.13 The hilar dissection in the liver recipient.

anhepatic phase, during which removal of the diseased liver is carried out. Interruption of the portal vein and vena cava results in complete blockage of the venous outflow from the splanchnic bed and lower body. The consequences of this maneuver, including renal, splanchnic and systemic venous hypertension and congestion, can be devastating unless a decompression device is used.

During the early 1980s, a venovenous bypass system, used without recipient heparinization, was developed (Fig. 129.14) (Denmark et al 1983). Outflow cannulas are inserted into the portal and the femoral veins (via a cut-down on the saphenous vein), allowing both splanchnic and systemic blood to return to the heart by way of an inflow cannula placed in the axillary vein. A centrifugal-force pump is used to maintain adequate flow rates (usually 1500–3000 cm<sup>3</sup>/min). This permits the hepatectomy to be completed in a controlled physiological environment with significant reduction in blood loss, intestinal edema, and postoperative renal failure.

Venovenous bypass has been routinely used only for patients of adult size. Infants and small children weighing less than 15 kg tolerate venous occlusion reasonably well. This is because collateral circulation secondary to portal hypertension modulates the decrease in preload to the heart from the infradiaphragmatic portion of the body. The risks of low rates of blood flow and of pulmonary emboli outweigh the benefits of bypass in the majority of pediatric cases.

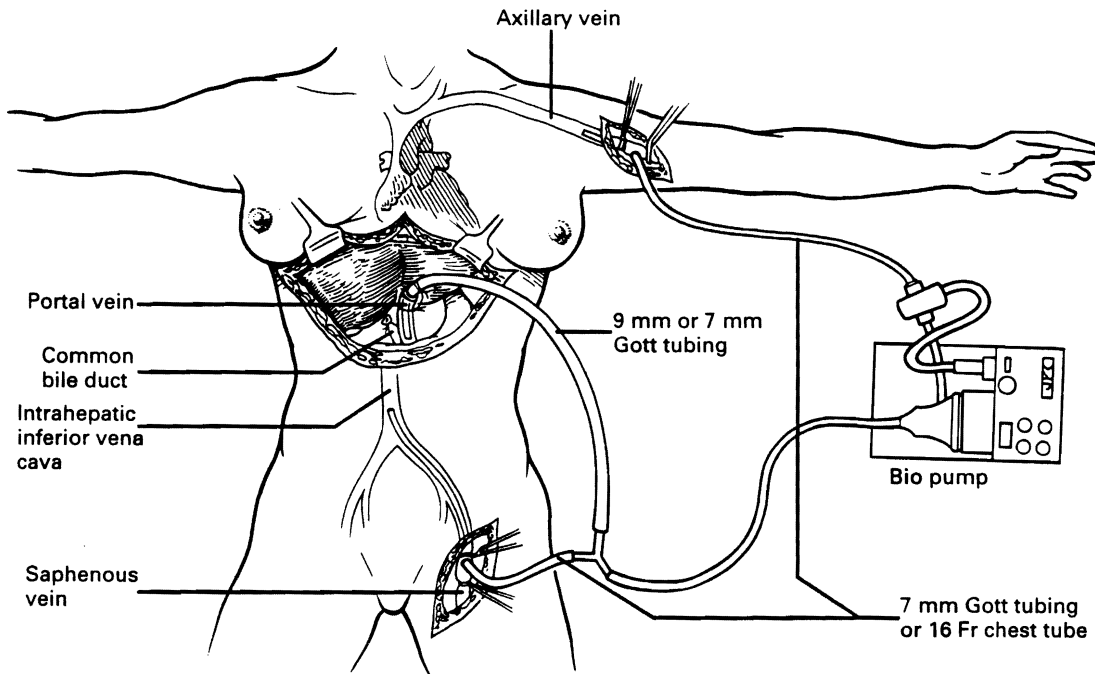
#### *Hepatectomy on bypass*

The extent of preliminary dissection can be greatly reduced if the venovenous bypass is to be used. With the hemodynamic stability afforded by the venovenous bypass, it is possible systematically to divide all other structures which hold the liver in place. The triangular ligaments (if these have not been incised already), and the leaves of peritoneal reflection which make up the coronary ligament are cut. The bare areas are entered on both the right and left sides. Next, the inferior vena cava, just below and above the liver, is encircled and clamped. The liver can then be shelled out of the stalk defined by the vena caval connection (Fig. 129.15A). By dissecting the liver off the occluded vena cava, leaving most or all of the retrohepatic vena cava temporarily behind, careful identification and ligation of the adrenal vein and any posterior venous branches can be achieved (Fig. 129.15B) and adequate caval cuffs for anastomosis can be developed (Fig. 129.15C). This technique minimizes the extent of retroperitoneal dissection required to remove the liver.

Once the liver has been removed, hemostasis is obtained by closing or oversewing the edges of the exposed bare area with a continuous monofilament suture (Fig. 129.15D).

#### *Other methods of hepatectomy*

In some patients, efforts to dissect the liver hilum in the



**Fig. 129.14** The pump driven venovenous bypass is used to decompress the systemic and splanchnic venous beds during the anhepatic phase of the operation. Outflow lines to the pump are placed in the iliofemoral system via a cutdown on the saphenous vein and a return cannula is placed in the axillary vein.

usual way may be impossible because of scarring or the presence of varices. In these situations, the suprahepatic vena cava can be approached first and antegrade removal of the liver can be performed, from cephalad to caudad, after cross-clamping and transecting the upper vena cava. The hilar structures are then approached from behind, where they are usually free of adhesions (Fig. 129.16).

If difficulty is encountered during dissection of the suprahepatic vena cava, the liver can also be removed by a retrograde approach after transection of the infrahepatic inferior vena cava and hilar structures (Fig. 129.17).

A transhepatic approach can be used if severe adhesions are present around the liver, including the upper and lower vena cava. The liver parenchyma is transected longitudinally until the plane between the liver and the inferior vena cava is reached. Once bleeding from the split surfaces is controlled by continuous sutures of the raw surfaces, the two hepatic halves are stripped away from the surrounding structures (Fig. 129.18).

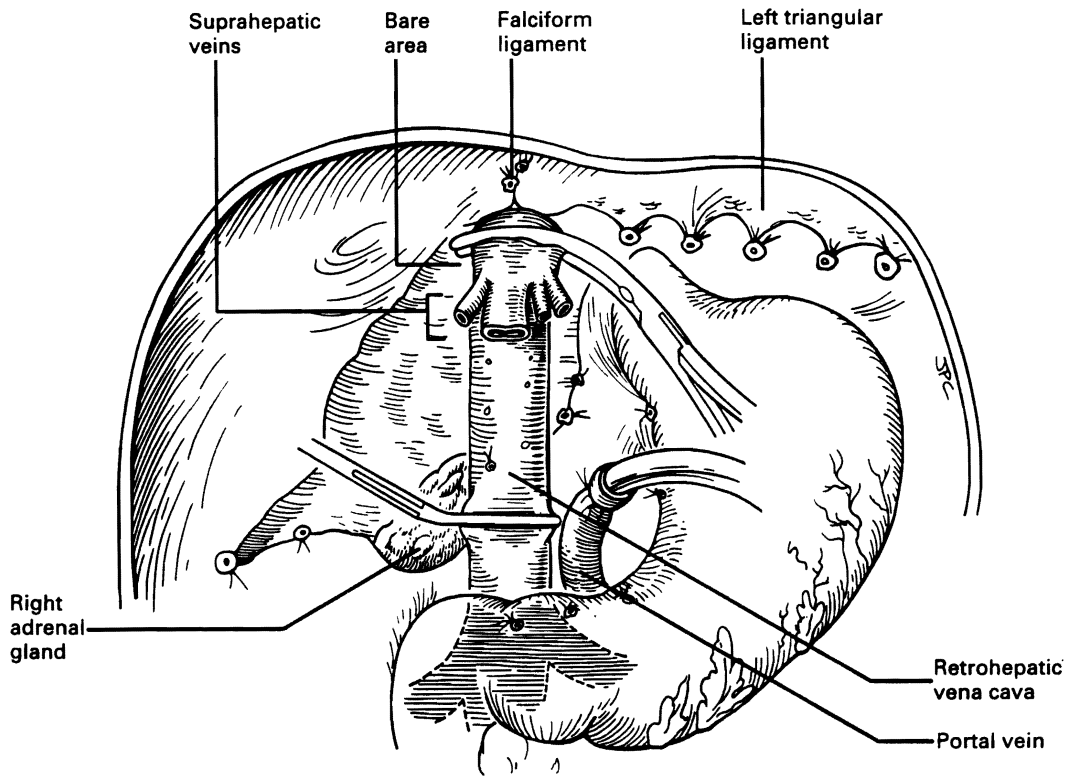
All of these variations of the basic technique of hepatectomy are feasible when venovenous bypass is used during the hepatectomy. The bypass maintains cardiodynamic stability while the major venous structures are occluded and enables the surgeon to perform these various maneuvers safely.

Another alternative, the 'piggyback' technique, can often be accomplished without the use of a venous bypass. For this approach, the liver is detached completely from the retrohepatic vena cava with ligation of retrohepatic veins, but without interrupting vena cava flow. The main

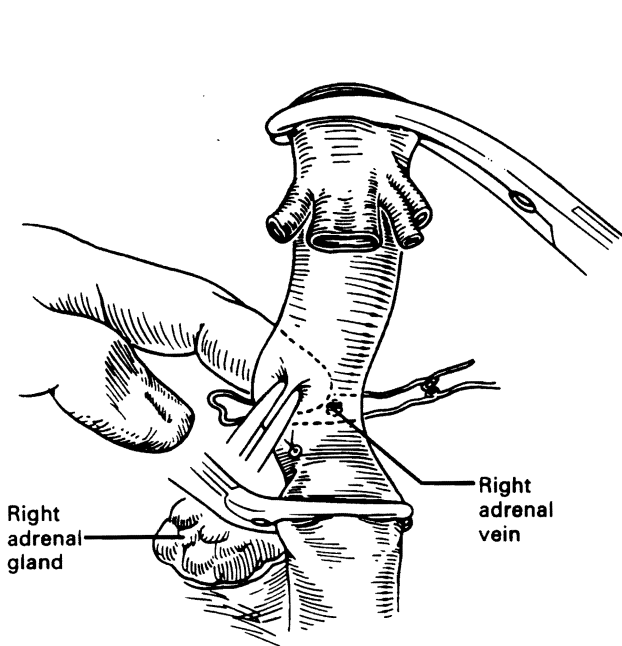
suprahepatic veins are cross-clamped (Fig. 129.19A) and a common cloaca is fashioned by dividing the intervening septa (Fig. 129.19B). Donor liver outflow is achieved by anastomosing the donor upper cava to this common funnel. A lower caval anastomosis is not necessary and the donor lower cava is either ligated or oversewn (Fig. 129.19C). If the recipient vena cava is never interrupted, complete venous bypass can be avoided. The portal vein is divided as late as possible to minimize the period of splanchnic venous congestion. This piggy back technique is employed in selective cases, including situs inversus, reduced-size liver graft implantation, large size discrepancy between donor and recipient liver, contraindications to venous bypass such as thrombosed subclavian veins, and for patients with a patent end-to-side portocaval or mesocaval shunt.

#### *The vascular anastomoses*

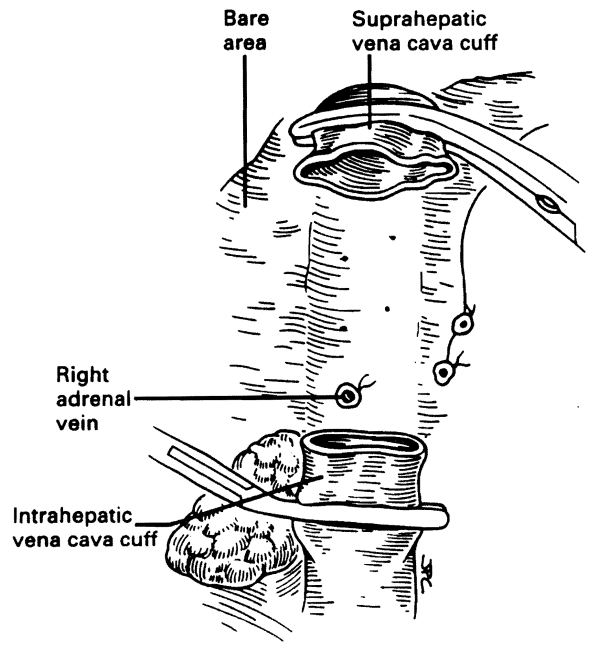
It is essential that surgical field, including preparation of adequate venous cuffs, be completely ready before the graft is brought onto the operative field. The liver allograft is implanted by first anastomosing the suprahepatic cava, then the infrahepatic cava, followed by the portal vein. Finally, after unclamping these three vessels and restoring the blood flow to the new liver, the hepatic arterial anastomosis is performed. If the anatomy is favorable and the operative field is dry, an experienced surgeon may prefer to perform the arterial anastomosis before the portal vein reconstruction. All the vascular anastomoses are



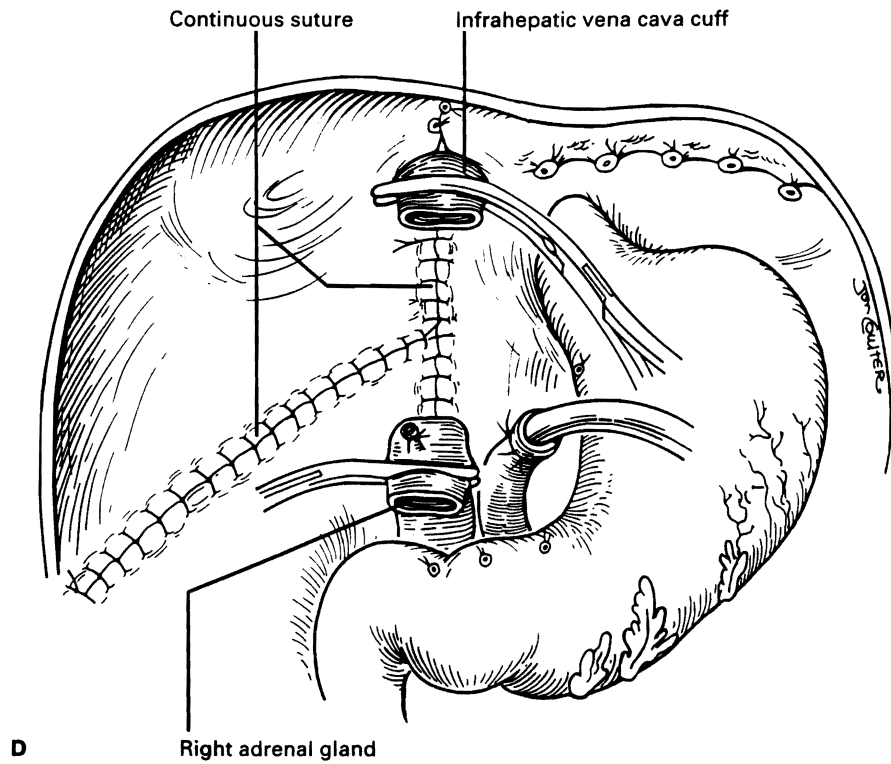
A



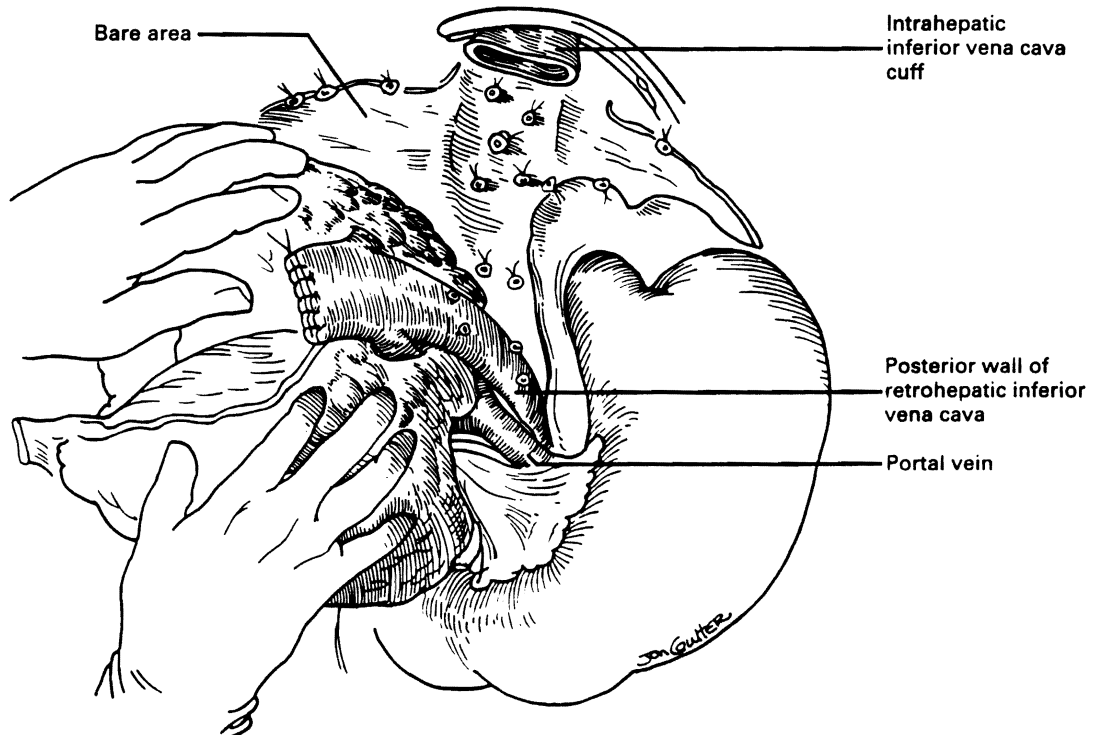
B



C



**Fig. 129.15** Completion of the recipient hepatectomy while on venovenous bypass. **A** Dissection of all the structures which hold the liver in place. **B** Supra- and infra-hepatic portions of the vena cava are clamped and the liver is dissected off the vena cava leaving all or most of the retrohepatic vena cava behind. The adrenal vein and any lumbar branches are ligated. This minimizes the extent of retroperitoneal dissection. **C** The upper and lower cuffs of vena cava are trimmed in preparation for anastomosis to the graft. **D** Prior to beginning the implantation of the graft, the raw edges of the bare area are oversewn to provide hemostasis.



**Fig. 129.16** The technique of antegrade removal of the recipient liver.



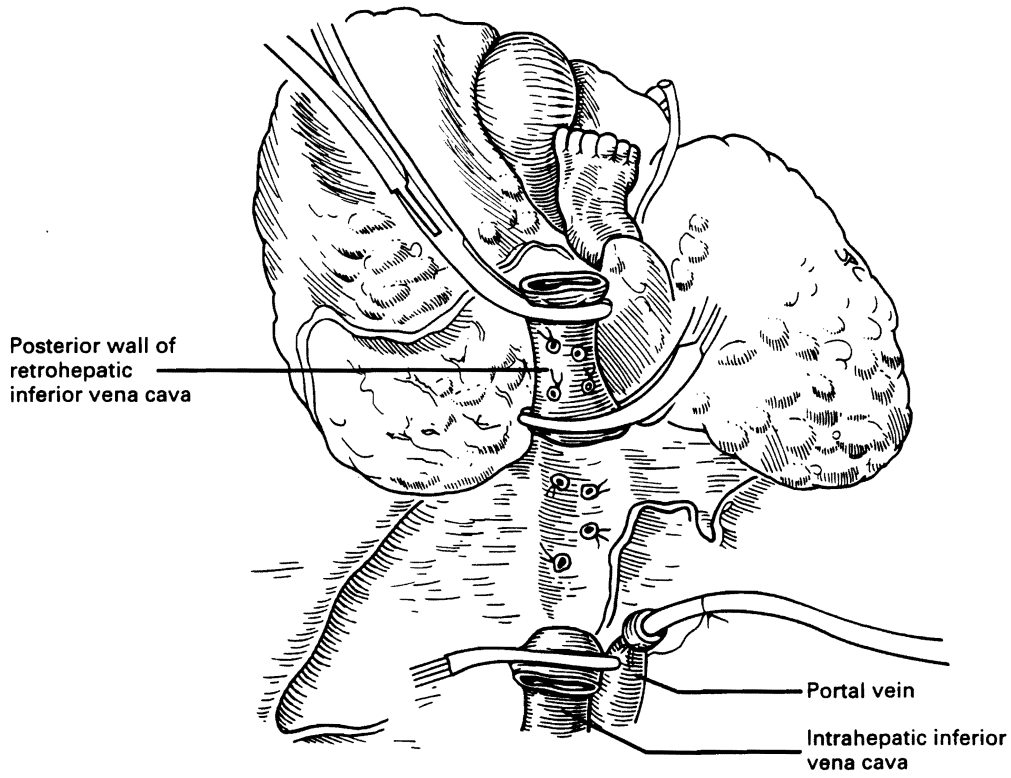


Fig. 129.17 The technique of retrograde removal of the recipient liver.

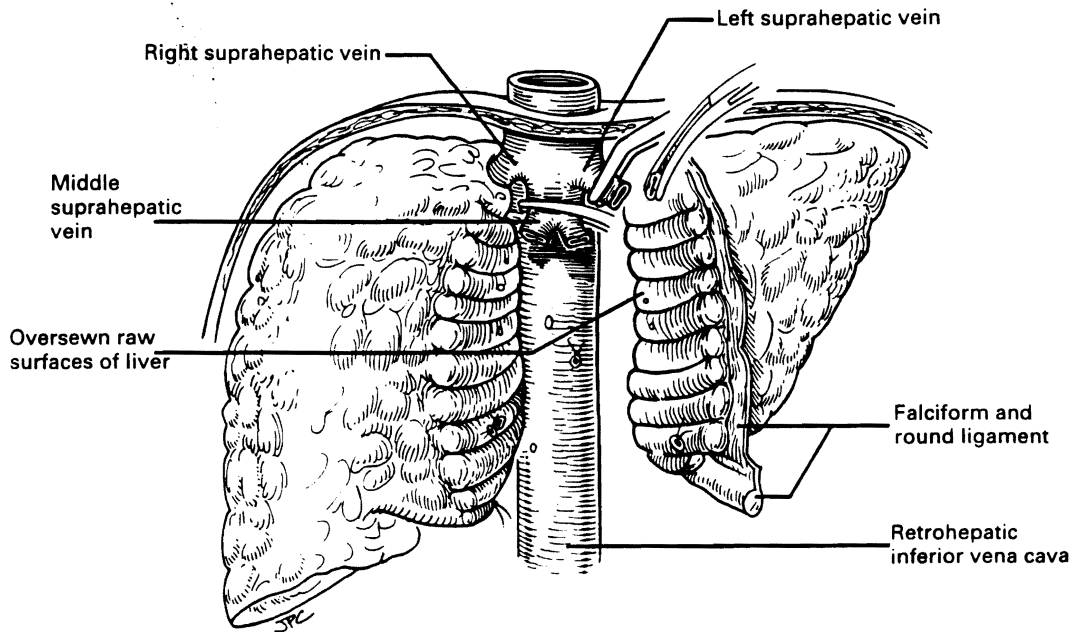
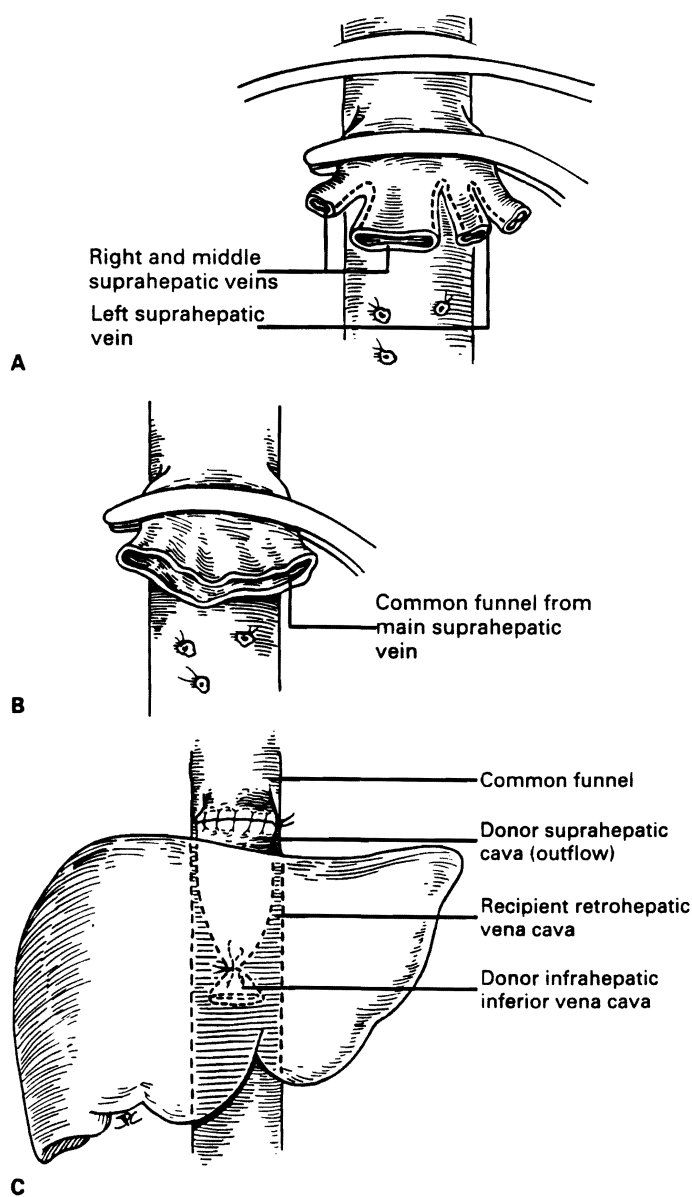
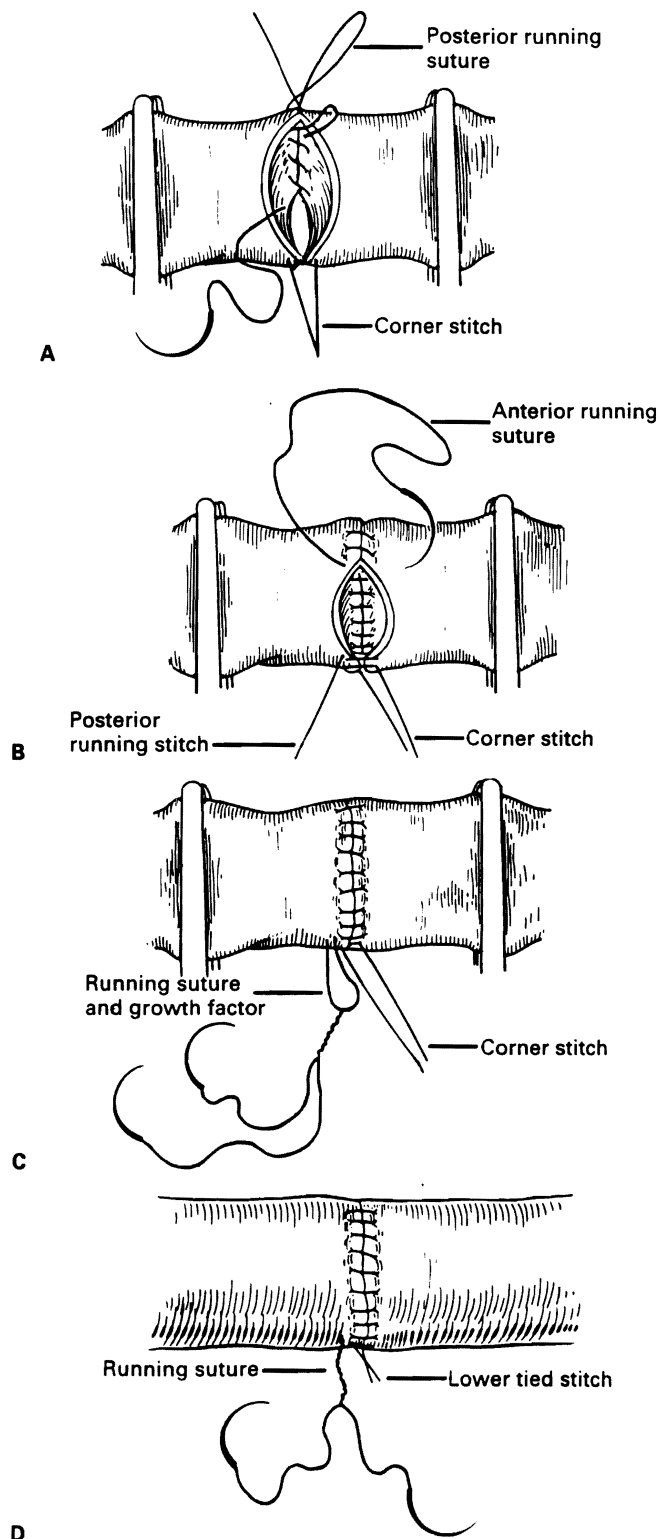


Fig. 129.18 The 'splitting' technique for recipient hepatectomy.

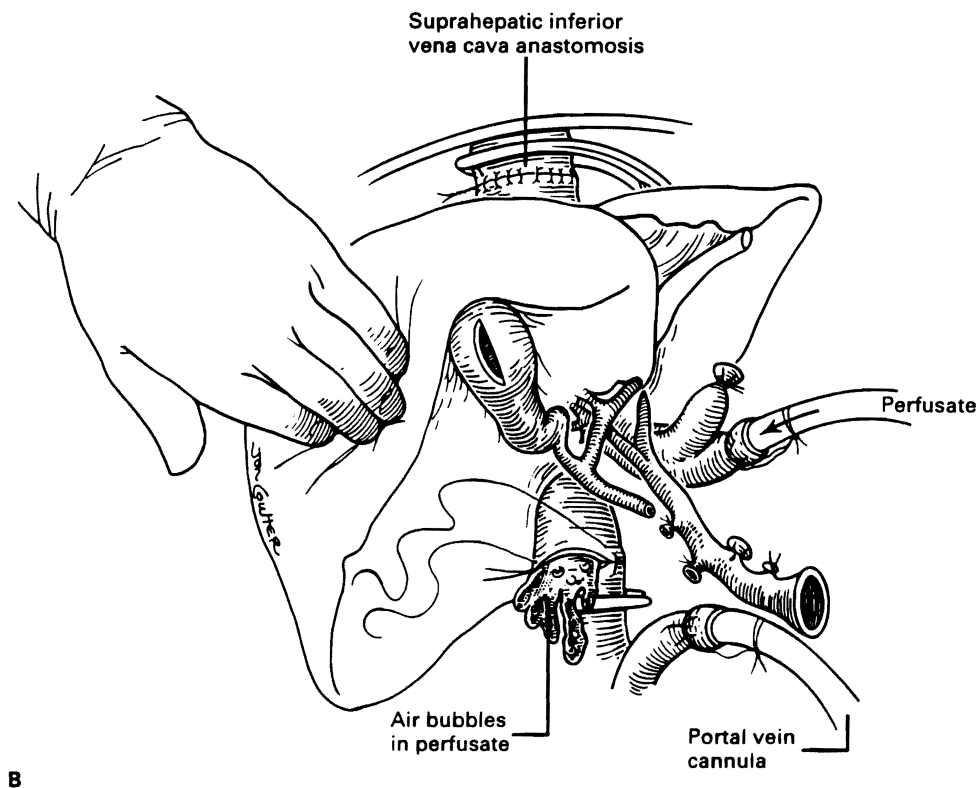
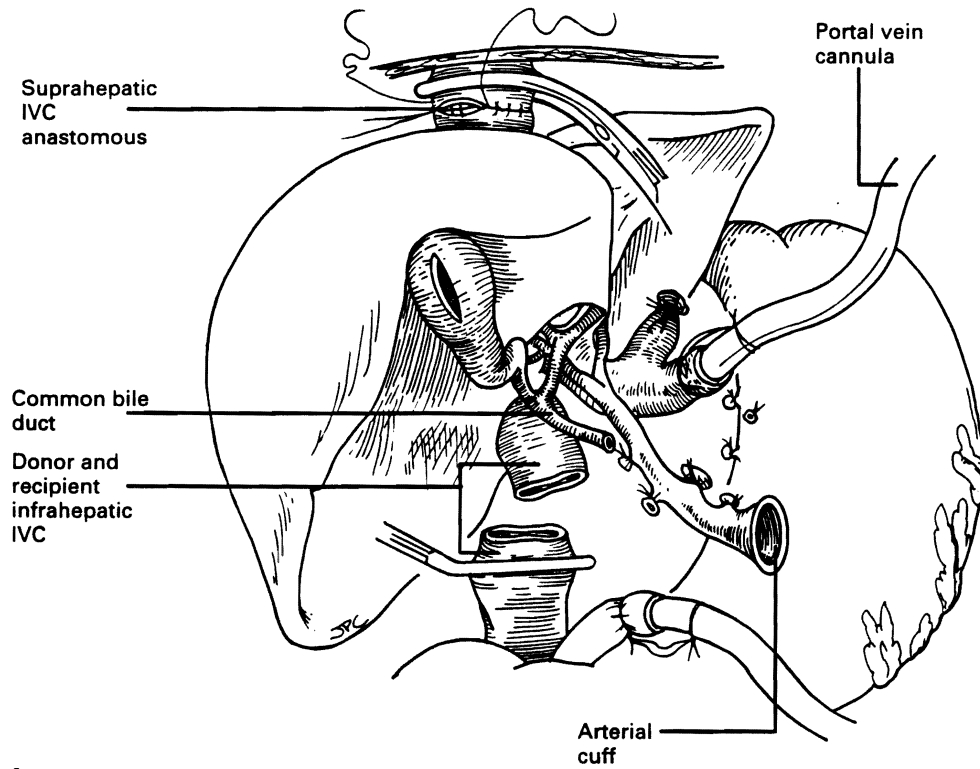


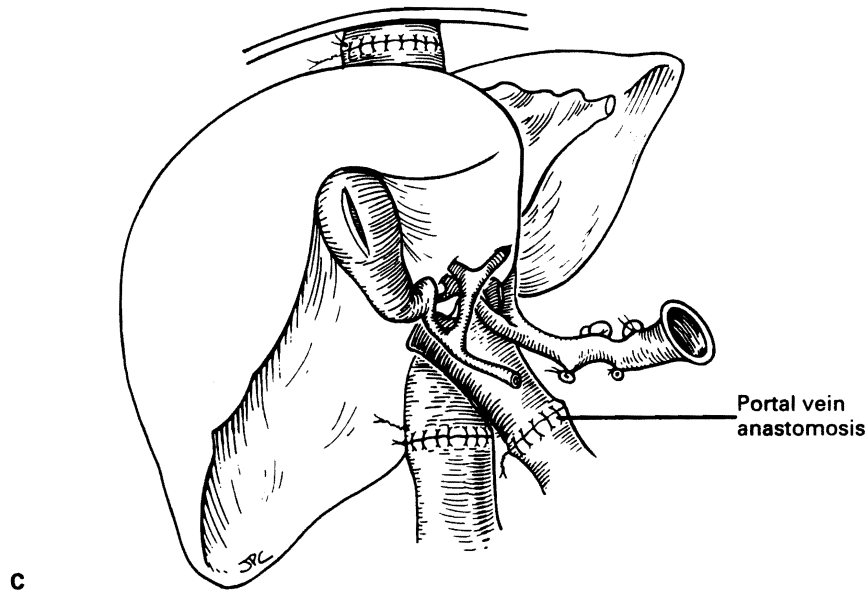
**Fig. 129.19** The 'piggy back' method of graft implantation. **A** The recipient vena cava is left intact and a clamp is applied across the origin of the major hepatic veins. **B** A cuff is prepared by joining the origins of the middle and left hepatic veins. The right hepatic vein (not shown here) is usually tied off. **C** The suprahepatic vena cava of the graft is sewn to the funnel of the hepatic veins and the infrahepatic cava of the graft is simply tied off. The liver rests on top of the recipient vena cava.

performed with continuous prolene sutures with special techniques previously described to prevent anastomotic strictures. A 'growth factor' is left by tying the sutures at a considerable distance from the vessel wall (Starzl et al 1984). After the flow is restored through the anastomosis, the excess prolene recedes back into the vessel and redistributes itself throughout the circumference of the suture line (Fig. 129.20). This technique is applied routinely to the portal vein and hepatic artery anastomoses, but may also be used for the vena cava, especially in children.



**Fig. 129.20** The technique of venous anastomosis. **A** Traction sutures are placed at each corner. One end of the far suture is brought to the inside and run in continuous fashion to approximate the back wall. **B** The other end of the far suture is then used from the outside to approximate the anterior wall. **C** The continuous suture is tied away from the vein wall to allow for a 'growth factor'. The near corner suture is tied next to the running suture to prevent separation of the vessel. **D** The excess suture soaks into the vessel when it expands and blood flow is restored.





**Fig. 129.21** Steps in the implantation of an orthotopic liver graft. **A** Completion of the suprahepatic vena cava anastomosis. **B** Completion of the infrahepatic vena cava anastomosis. The portal vein is flushed with cold albumin or electrolyte solution to wash out the high potassium containing preservation fluid and to eliminate air in the vena cava. **C** The portal vein bypass cannula is removed and the portal vein anastomosis is completed.

**Vena cava reconstruction.** If adequate cuffs have been developed, the anastomoses of the vena cava above and below the liver can be performed easily (Fig. 129.21A, B). During anastomosis of the lower vena cava, the liver is flushed with lactated Ringer's solution (some surgeons prefer albumin) to remove air and to rid the graft of the high potassium solutions used for organ preservation (Fig. 129.21B). Failure to perform this flush can result in either air embolism or hyperkalemic cardiac arrest.

**Portal vein reconstruction.** Once the infrahepatic caval anastomosis has been completed, the portal cannula is clamped and removed. Recipient and donor portal veins are trimmed to the appropriate length and the anastomosis, leaving a one diameter growth factor in the suture line, is performed. Subsequently, all clamps are removed and the liver is revascularized (Fig. 129.21C).

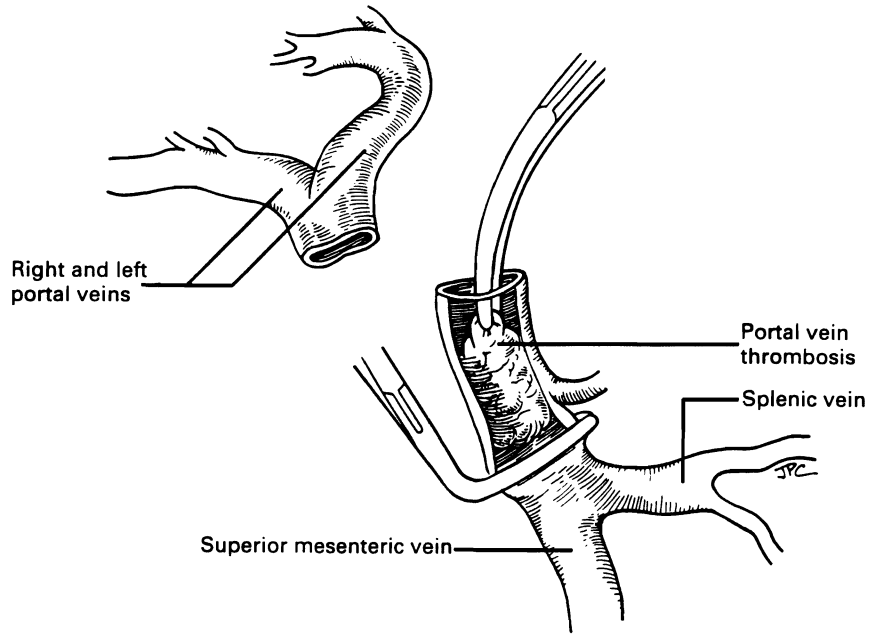
Long-standing portal hypertension may lead to thrombosis of the portal vein and other pathological changes in the vein wall. Until recently, unsuitability of the portal vein for anastomosis has been a contraindication to liver transplantation. Organized thrombosis, atrophy, friability or cavernous transformation of the portal vein may make the main portal vein unusable. Several techniques have evolved to surmount these problems (Stieber et al 1991). In some cases, declotting of the portal vein may be attempted (Fig. 129.22A). If this is not feasible and the confluence of the mesenteric and splenic veins is patent, an interposition vein graft (usually iliac vein from the liver donor) may be used to connect the gap between the

donor and recipient portal vein, if the donor portal vein is not long enough (Fig. 129.22B).

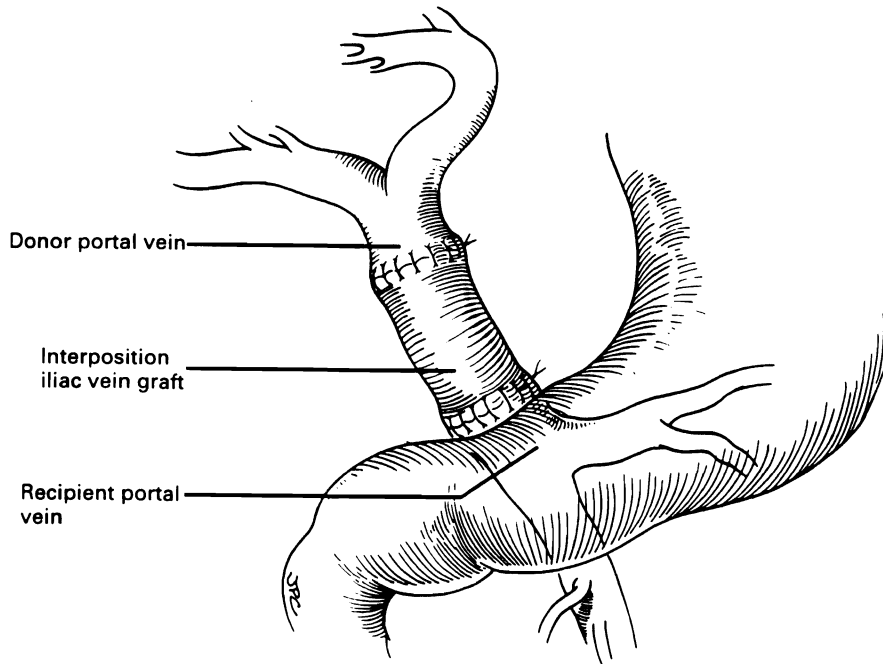
If neither the portal vein nor the confluence can be used, a new portal vein can be constructed using a mesoportal 'jump graft' of donor iliac vein (Shiel et al 1987, Tzakis et al 1989a). The graft is anastomosed end-to-side to the superior mesenteric vein. It is then tunneled through the transverse mesocolon and passed in an avascular plane anterior to the pancreas and anterior or posterior to the stomach to reach the hepatic hilum for end-to-end anastomosis to the donor portal vein (Fig. 129.22C).

**Hepatic artery reconstruction.** The various techniques used for reconstruction of the hepatic arterial supply are summarized in Fig. 129.23. The usual method is an end-to-end anastomosis of the donor celiac trunk to the recipient common hepatic artery at the level of the gastroduodenal artery takeoff. During the recovery of the donor liver, a Carrel patch of aorta is preserved with the celiac axis. A 'pseudo' Carrel patch can also be created for the recipient artery using the origin of the gastroduodenal artery (Fig. 129.23A, inset).

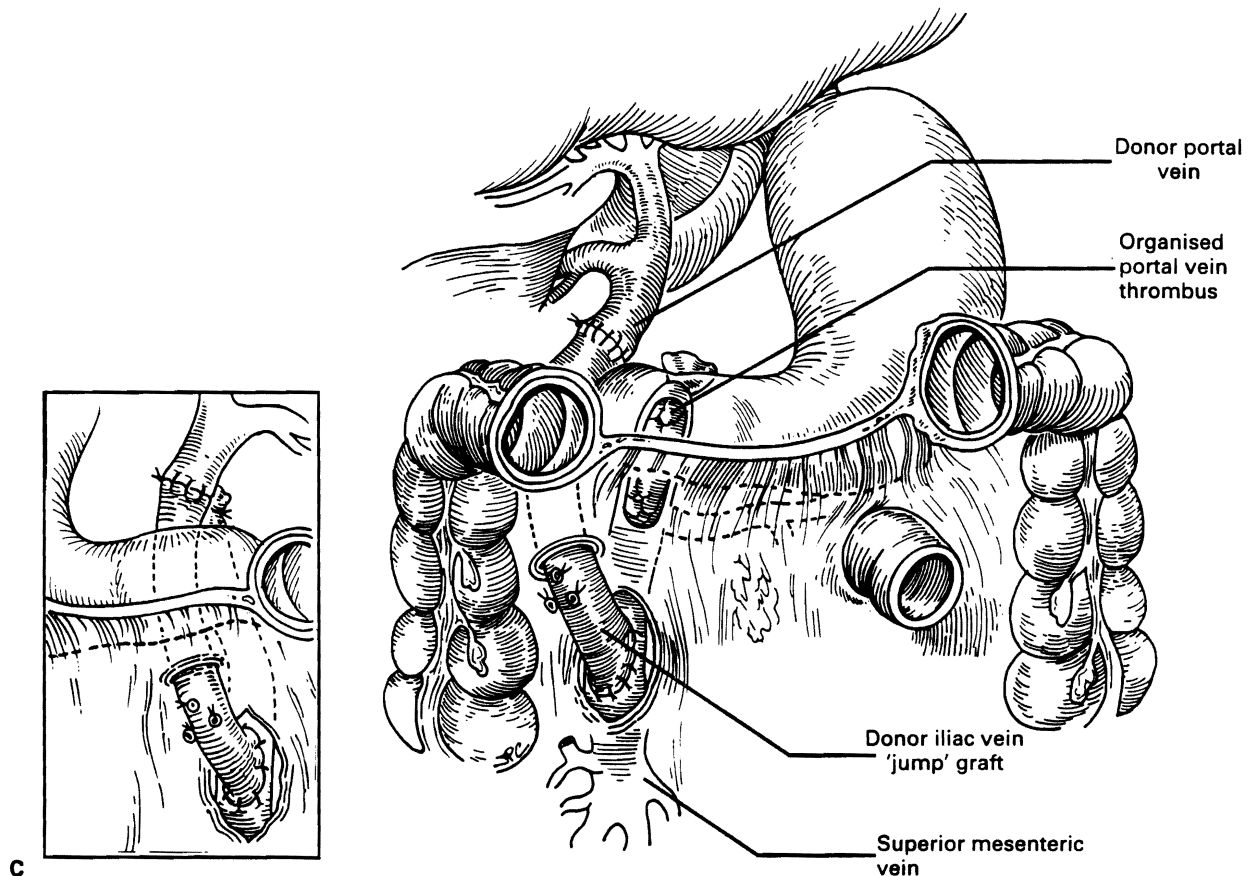
When a direct anastomosis to the recipient hepatic artery or celiac trunk is not possible, an interposition graft of donor iliac artery, carotid artery or aortic conduit can be used to create a new inflow vessel (Tzakis et al 1989b). The location of choice for origination of the graft is end-to-side anastomosis to the infrarenal aorta. The graft is then tunneled through the transverse meso-



A



B



**Fig. 129.22** Methods for management of recipient portal vein thrombosis. **A** Thrombectomy of the recipient portal vein. **B** Use of an interposition graft of donor iliac vein to bridge the gap between donor portal vein and the confluence of the mesenteric and splenic veins. **C** Use of a jump graft of donor iliac vein from the superior mesenteric vein to the donor portal vein. The graft is tunneled through the transverse mesocolon, anterior to the pancreas and stomach, to reach the hepatic hilum. Alternatively, the graft can be tunneled posterior to the stomach (inset).

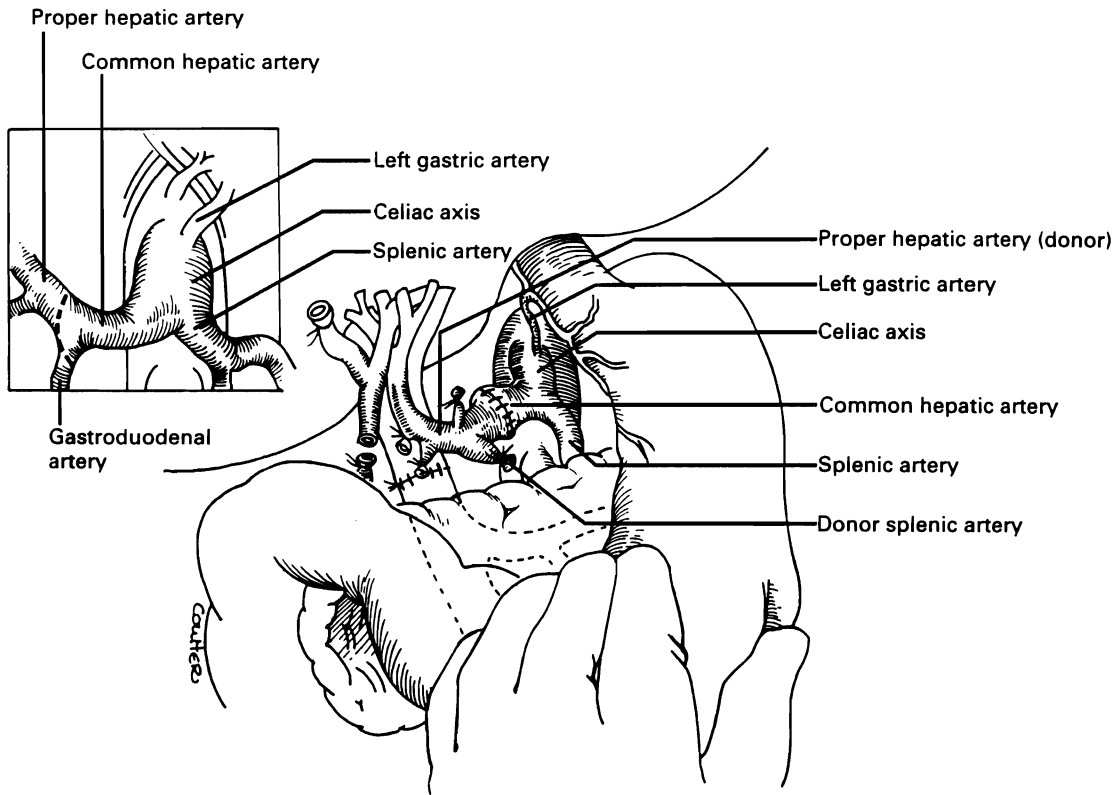
colon and passed in an avascular plane anterior to the pancreas and posterior to the stomach to reach the hepatic hilum for end-to-end anastomosis to the donor hepatic artery (Fig. 129.23B). The graft can also be passed in a deep retroperitoneal tunnel anterior to the renal vein and either anterior (Fig. 129.23C) or posterior (Fig. 129.23C, inset) to the superior mesenteric artery. The graft travels posterior to the pancreas and duodenum to emerge in the hepatic hilum posterior to the portal vein and anterior to the infrahepatic vena cava. However, these tunnels, which are more difficult to make and offer limited exposure for anastomosis of the graft to donor hepatic artery, are rarely used now. Care must be taken when making tunnels for vascular grafts not to injure the pancreas. Postoperative pancreatitis has a high morbidity and mortality after liver transplantation.

Alternative sites for origination of the arterial graft are the supraceliac aorta and the right iliac artery (Fig. 129.24).

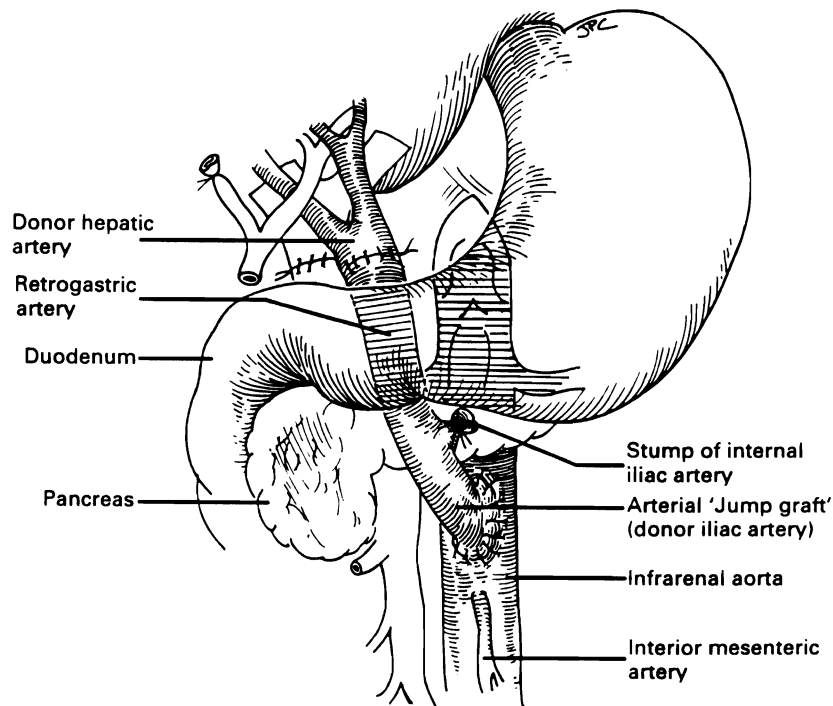
### *Hemostasis*

Perfect hemostasis must be achieved before the biliary reconstruction is started. In difficult cases, especially in patients with severe portal hypertension or extensive prior surgery, many hours of tedious surgery may be required. Such efforts are essential and eventually are rewarded with complete hemostasis, good postoperative renal function, and avoidance of re-exploration.

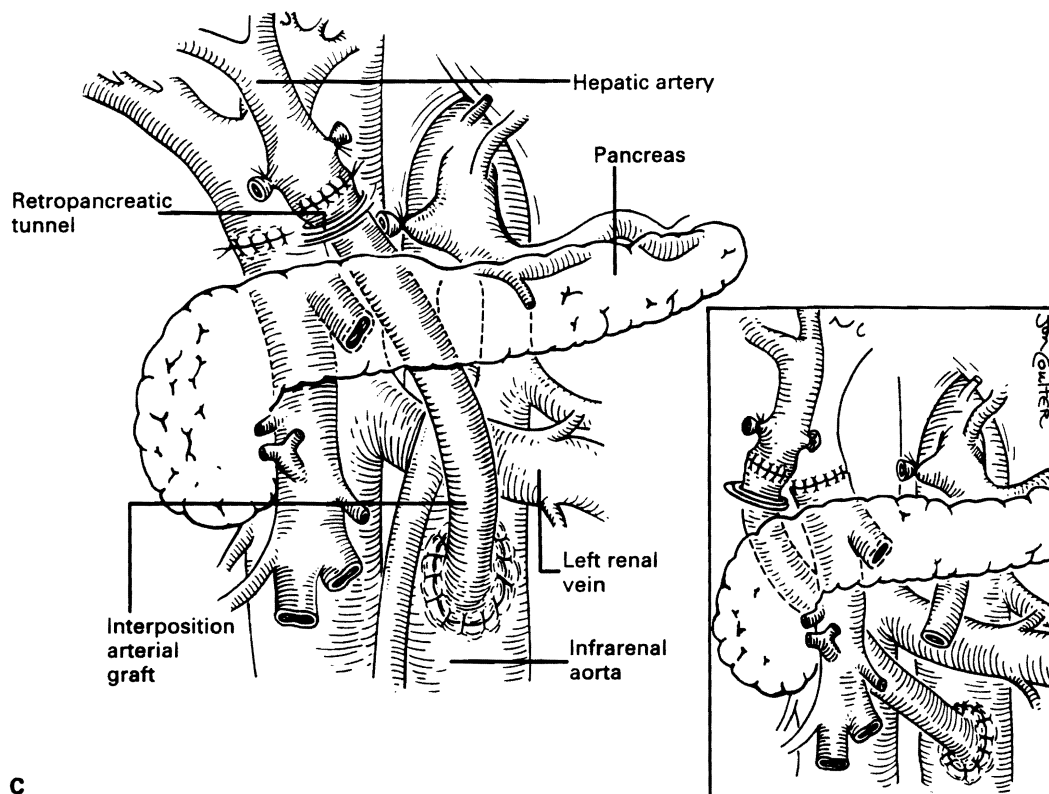
We have found the Argon Beam Electrosurgical Generator (Britcher, Irvine, CA) and the Rapid Infusion System (Haemonetics Corporation, Braintree, MA) to be of great value in control of bleeding and in maintaining blood volume during liver transplantation. The Argon Beam Electrosurgical Generator is a very useful coagulator for controlling the ooze that occurs from the raw surfaces of the diaphragm, retroperitoneum, and liver. The Rapid Infusion System is capable of infusing warm,



A



B



C

**Fig. 129.23** Hepatic artery reconstruction. **A** In most cases, the donor celiac trunk is anastomosed to the common hepatic artery of the recipient at the level of the takeoff of the recipient gastroduodenal artery. A cuff of recipient artery can be created by incorporating part of the origin of the gastroduodenal takeoff in the cut end of the recipient common hepatic artery (see inset) to facilitate anastomosis to a Carrel patch of donor aorta. **B** When the recipient hepatic artery cannot be used, a new hepatic inflow is created using a jump graft of donor iliac artery placed on infrarenal aorta just below the left renal vein. The graft is passed through the transverse mesocolon, anterior to the pancreas, and posterior to the distal stomach to emerge at the hepatic hilum anterior and medial to the portal vein. **C** Alternative retroperitoneal tunnels can be created either by passing directly over the left renal vein anterior to the superior mesenteric artery and posterior to the pancreas, or posterior to the superior mesenteric artery (inset) passing anterior to the vena cava and behind the pancreas to emerge between the portal vein and vena cava. The tunnel posterior to the superior mesenteric artery is usually easier to create and less likely to encounter collateral veins, but both of these routes are more difficult than the methods shown in **B** and are rarely used.

filtered blood products at rates of up to 2 l/min through two conventional large caliber percutaneous intravenous catheters.

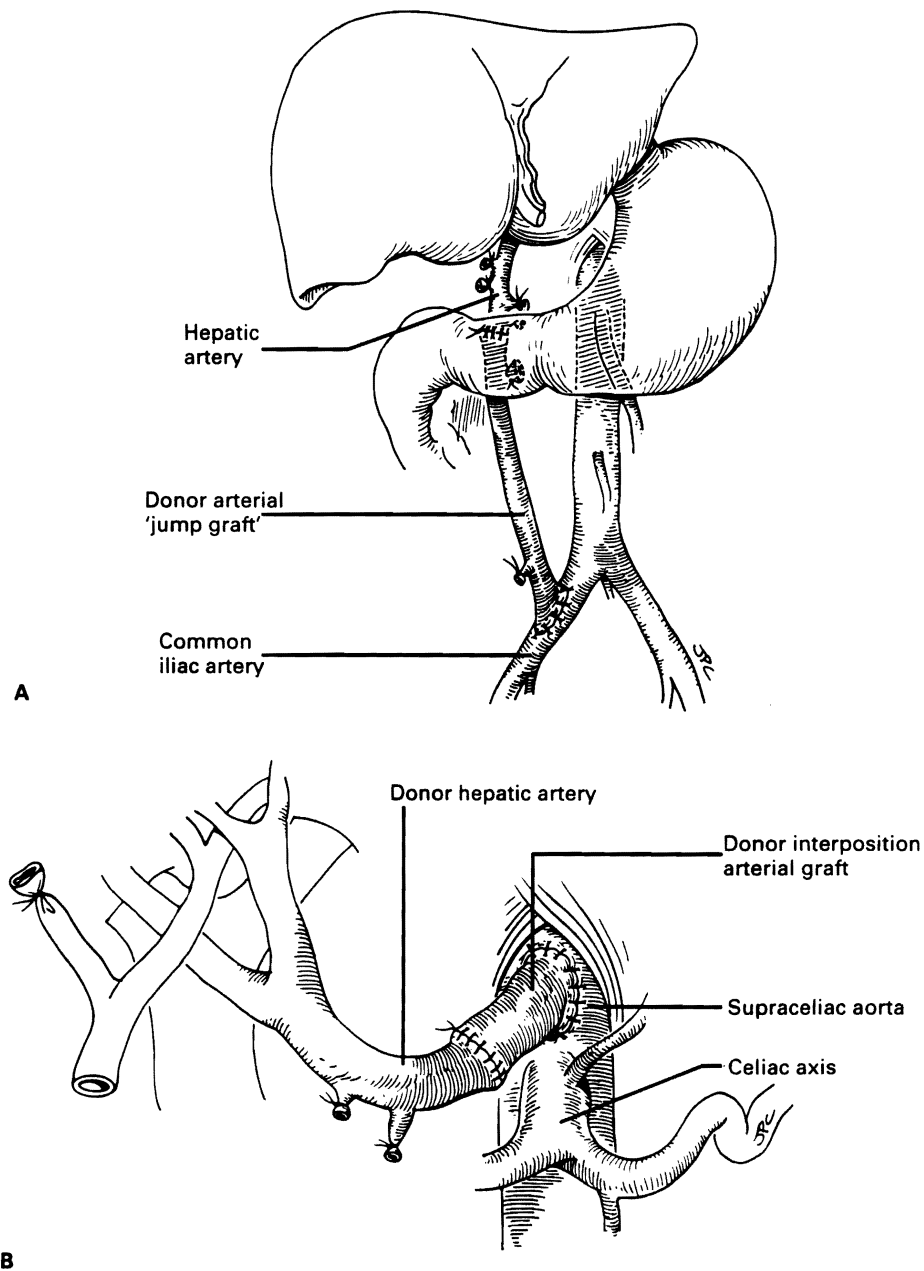
#### *The biliary tract reconstruction*

Once hemostasis has been achieved, the biliary reconstruction is performed. If the recipient duct is free of disease and there is no significant size mismatch between the donor and recipient ducts, an end-to-end anastomosis of the ducts is performed over a T-tube stent (Fig. 129.25). The T-tube is brought out through a stab incision on the lateral side of the distal recipient duct. The anastomosis is usually performed with eight to ten interrupted absorbable sutures such as 5-0 or 6-0 polyglycolic acid. Adequate blood supply of the duct

rather than number of sutures is what determines the integrity of the anastomosis. The recipient duct should be trimmed back as much as is feasible to maximize the blood supply. A small purse-string suture is usually placed around the T-tube exit site to prevent leakage.

In patients in whom the recipient duct is diseased or otherwise inadequate for direct anastomosis, a choledochojejunostomy is performed. An 18-in. Roux-en-Y limb of proximal jejunum is brought up (usually antecolic) to the hepatic hilum and the donor duct is anastomosed end-to-side to the jejunal limb using a running or interrupted 5-0 or 6-0 absorbable polyglycolic acid suture over a small internal silastic stent (Fig. 129.25, inset). The stent is secured in place with a rapidly absorbed fine cat-gut suture and will later pass out of the intestinal tract spontaneously in the stool. Infrequently, the stent





**Fig. 129.24** Alternative sites for the origination of an arterial jump graft include the right iliac artery (A) and the supraceliac aorta (B).

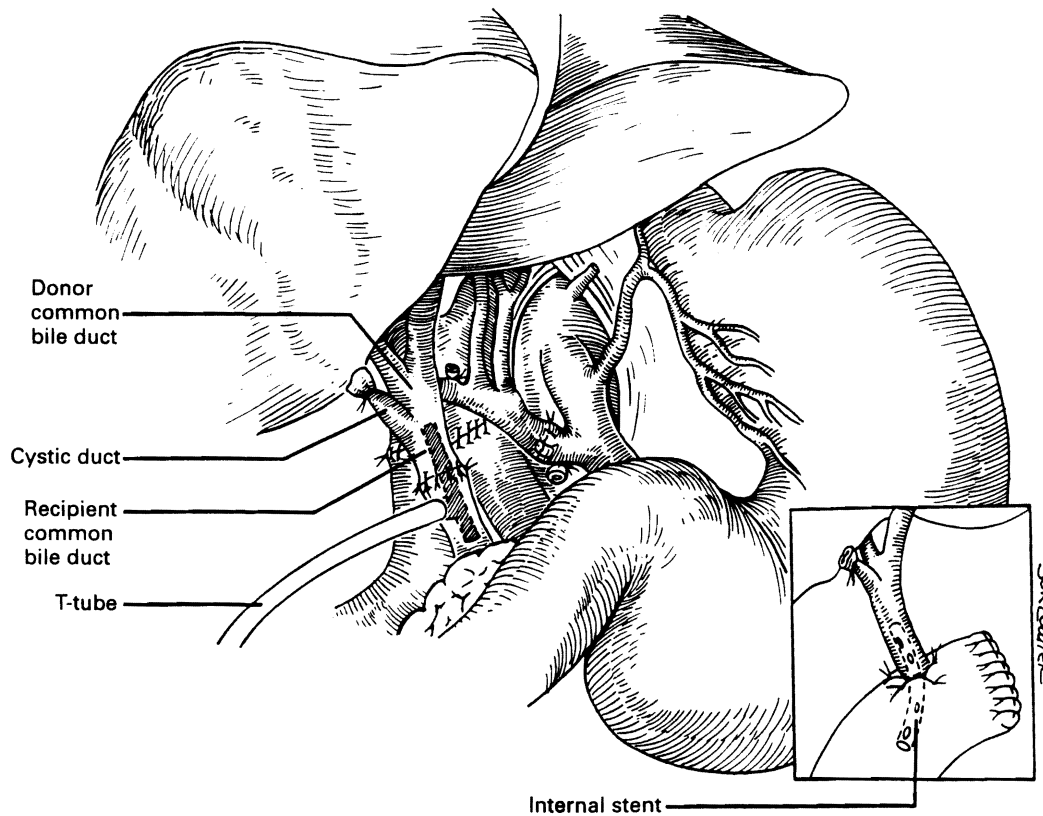
becomes stuck in the duct and must later be pushed out by the interventional radiologist or, rarely, removed at laparotomy.

### REDUCED SIZE LIVER TRANSPLANTATION (Ch. 125)

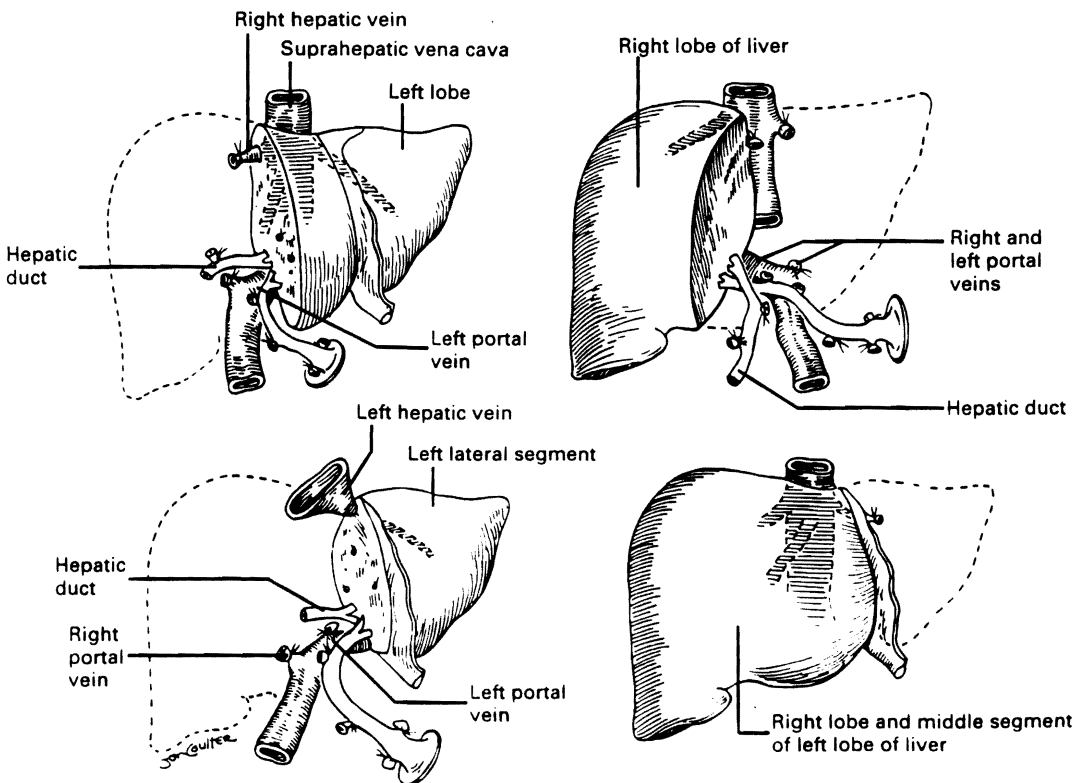
The scarcity of pediatric donors and the constraints of size-matching often prohibit transplantation of a whole donor liver in either a child or a small adult. A liver fragment was first used in 1975 at the University of Colorado for transplantation into a 23-month-old boy

with biliary atresia and multiple congenital anomalies, including an absent inferior vena cava. The left hepatic vein of the graft was sewn to a cloaca left by the hepatic veins of the native liver, similar to the piggyback technique described above. More recently, at centers in Brussels, Chicago, Hanover and Paris, the method has been reintroduced and shown to produce results approaching those achievable with whole liver transplantation (Broelsch et al 1988, Strong et al 1988, Otte et al 1990).

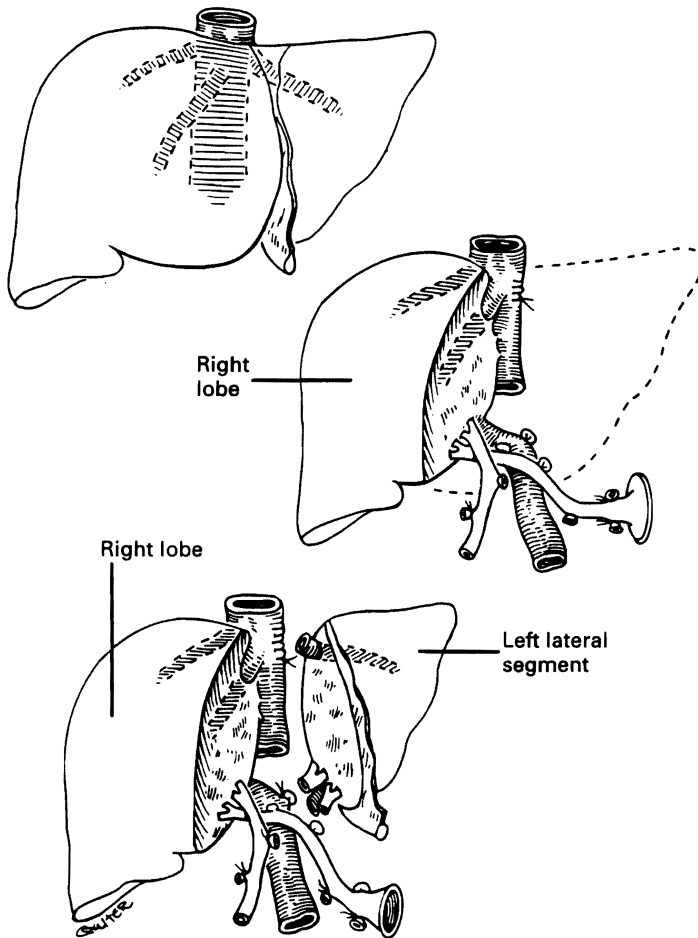
In such cases, the donor operation is performed using the conventional technique described for multiple organ procurement. The donor/recipient weight ratio is crucial



**Fig. 129.25** The biliary reconstruction. If the recipient duct is normal and closely matches the donor duct in caliber, an end-to-end reconstruction over a T-tube is performed using interrupted 5-0 or 6-0 polyglycolic acid suture. In cases in which the anatomy is not favorable for this technique, an eighteen inch Roux-en-Y limb of jejunum is created and an end-to-side choledochojejunostomy over an internal silastic stent is performed using running 5-0 or 6-0 polyglycolic acid suture (inset).



**Fig. 129.26** Reduced liver grafting using left lobe, right lobe, or left lateral segment grafts are being used to expand the donor supply for infants and small children, for whom there is a severe shortage of available donors.



**Fig. 129.27** In selected cases, the right lobe and left lateral segment may each be preserved and transplanted into different recipients. This 'split liver' technique is very demanding and usually requires a complex arterial and venous reconstruction for at least one of the two reduced grafts.

#### REFERENCES

- Broelsch C E, Emond J C, Thistlethwaite J R et al 1988 Liver transplantation with reduced size organs. *Transplantation* 45: 519-524
- Casavilla A, Selby R, Abu-Elmaged K, Tzakis A, Todo S 1992 Logistics and technique for combined hepatic-intestinal retrieval. *Annals of Surgery* 216: 605-609
- Denmark S W, Shaw Jr B W, Griffith B P, Starzl T E 1983 Venous-venous bypass without systemic anticoagulation in canine and human liver transplantation. *Surgery Forum* 34: 380-383
- Gordon R D, Bismuth H 1991 Liver transplant registry report. *Transplantation Proceedings* 23: 58-60
- Gordon R D, Fung J, Tzakis A et al 1991 Liver transplantation at the University of Pittsburgh from 1984-1990. In: *Clinical transplants* Teraski P, Cecka J M (eds). UCLA Tissue Typing Laboratory, Los Angeles, CA
- Gordon R D, Van Thiel D, Starzl T E 1993 Liver Transplantation. In: Schiff L, Schiff E R (eds) *Diseases of the liver*, 7th edn. J. R. Lippincott, Philadelphia
- Kalayoglu M, Sollinger H W, Stratta R J et al 1988 Extended preservation of the human liver for clinical transplantation. *Lancet* i: 617-619
- Otte J B, Ville de Coyet J, Sokal E et al 1990 Size reduction of the donor liver is a safe way to alleviate the shortage of size-matched organs in pediatric liver transplantation. *Annals of Surgery* 211: 146-157
- Shiel A G R, Thompson J F, Stevens M S et al 1987 Mesoportal graft from thrombosed portal vein in liver transplantation. *Clinical Transplants* 1: 18-20
- Starzl T X, Hakala T R, Shaw Jr B W et al 1984 A flexible procedure for multiple cadaveric organ procurement. *Surgery, Gynecology and Obstetrics* 158: 223-230
- Starzl T E, Iwatsuki S, Shaw Jr B W 1984 A 'growth factor' in fine vascular anastomoses. *Surgery, Gynecology and Obstetrics* 159: 164-166
- Stieber A C, Zetti G, Todo S et al 1991 The spectrum of portal vein thrombosis in liver transplantation. *Annals of Surgery* 214: 199-206
- Strong R, Ong T H, Pillway P et al 1988 A new method of segmental orthotopic liver transplantation in children. *Surgery* 104: 104
- Tzakis A G, Todo S, Stieber A, Starzl T E 1989a Venous jump grafts for liver transplantation in patients with portal vein thrombosis. *Transplantation* 48: 530-531
- Tzakis A G, Todo S, Starzl T E 1989b The anterior route for arterial graft conduits in liver transplantation. *Transplant International* 2: 121

in reduced-size grafts if the technique is to be used with success and must not exceed 4 to 1. The decision as to which portion of the liver is to be used as the graft is made after assessing the gross configuration of the donor liver and recipient size. The hepatic reduction (right or left hepatic lobectomies or left lateral segmentectomy) is performed utilizing established techniques for the hilar dissection (Fig. 129.26). The hepatic parenchyma is transected using a blunt instrument and fine silk ties. The major hepatic veins are identified and sutured. Meticulous attention must be paid to identifying leaks from the cut surface of the liver by distending the major vessels with perfusate.

In reduced-size graft liver transplantation, the recipient hepatectomy is almost always performed with preservation of the entire vena cava. Implantation of the reduced liver is performed 'piggy back' as previously described. Alternate methods of arterial or portal venous reconstruction are often required with reduced-size grafts. Thus, the retrieval of good quality venous and arterial grafts is essential.

The technique of reduced liver grafting has been extended in a small number of cases in which two liver fragments from a single donor have been implanted in separate recipients (Fig. 129.27). At least one of the grafts will require use of the special methods of vascular reconstruction previously described. The 'split liver' graft is a very demanding technique and it remains to be established whether the incidence of technical complications and the durability of both fragments justifies this approach.