

Chapter 41

LIVER TRANSPLANTATION

Andreas G. Tzakis, M.D.
and Thomas E. Starzl, M.D., Ph.D.

Orthotopic liver transplantation has emerged as a universal treatment of end-stage liver disease for several reasons. We describe this complex undertaking starting with the better understood technical considerations, proceeding to the less well understood immunologic considerations, and concluding with descriptions of some unresolved issues. We also discuss how liver transplantation applies to the treatment of specific hepatic diseases and how it has influenced the strategy of therapy for those disorders. The issue of auxiliary transplantation is discussed as well as transplantation of organ combinations, including multivisceral grafts. Developmental procedures that are as yet of unknown value are referred to. The literature of this field has been so thoroughly catalogued in reviews and other books that detailed annotation is unnecessary here. Selected references are provided at the end of the chapter, with brief annotations.

The surgical and anesthetic components of the transplantation team play a more central role with liver transplantation than with transplantation of any other organ. This is not only caused by the difficulty and complexity of the operative and perioperative treatment, but also by the high intensity of surgical care required for a long time afterward. From the time this procedure was introduced 27 years ago until the early 1980s, liver transplantation was a surgical decathlon, with standards only a few surgeons in the world could fulfill. It required a combination of skill, strength, and speed throughout a race against the clock.

Although these qualities are still required in some cases, the intensity of effort by any single person has been reduced by several factors. Responsibilities can now be shared, for these procedures are usually done in medical centers with teams. The liver allograft is frequently shipped in by other teams. Intensive care, infectious disease, and other medical specialists meld with the anesthesiologists and surgeons imperceptibly, as the patient moves from the operating room, through the intensive care unit, and onto the wards.

The transplantation procedure can be divided into two parts: the donor operation and the recipient procedure.

DONOR OPERATION

Size Factors

The donor team must provide moment-to-moment information to the recipient surgeons. A liver graft, in order to be implanted, has to be similar in size to the diseased liver being removed. Thus, optimally, a fairly close age match, but especially an organ size match, of the donor and recipient would be desirable if the whole organ is to be used. Deviations from this rule are permissible; such cases usually involve placing smaller organs into larger recipients.

The shortage of pediatric donors and the great variability in the needed size led to the utilization of reduced-size livers. Liver fragments from donors three to four times larger (or even greater) than the recipient can be made to fit, if the appropriate size reduction procedure is selected. These operations are, in fact, formal hepatectomies, performed in the bloodless field of the back table. The ones most commonly used are a right lobectomy, right trisegmentectomy, and left lateral segmentectomy. The resected portion usually is discarded. Transplantation of liver fragments is thought to be associated with a lower incidence of hepatic artery thrombosis, because of the larger size of the donor artery. The main disadvantage involves complications from the raw surface, of which hemorrhage, biliary fistula, and infections are the most common.

Graft Assessment

The American and European experience both show that the use of perfect donors with hemodynamic stability and normal blood biochemistry values does not ensure a great advantage in graft and patient survival. Insistence on these ideal donor conditions would lead to a waste of an already scarce resource. The judgment of whether a graft is transplantable is a complex clinical one. The single most important item for a final decision is the evaluation of the liver by the donor's surgeon. A needle biopsy and pathologic ex-

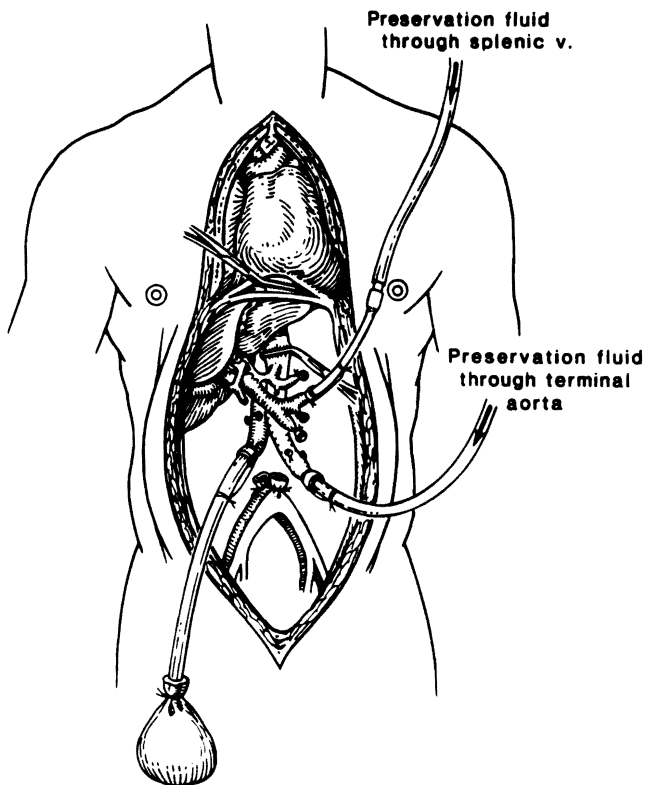


FIGURE 41-1. Principle of in situ cooling used for multiple organ procurement. With limited preliminary dissection of the aorta and the great splanchnic veins, cold solutions can be used to chill organs in situ. In this case, the kidneys and liver were removed. Note the aortic crossclamp above the celiac axis. Portal perfusion was performed through a splenic vein cannula.

amination might help in the case of doubt, by ruling out some suspected or unsuspected preexisting disease.

Harvesting Technique

Liver allografts are harvested as part of a multiple organ procurement, which usually involves renal and thoracic teams working in harmony. An inadequate performance by one participating group can ruin the grafts for all. Skillful liver procurement requires complete knowledge of the anatomy of the hepatic hilar structures and its normal variations. In the usual case in which the donor's condition is stable, a preliminary dissection of all the organs to be removed can be performed, and at this time the anatomy is defined. When this is completed, the organs are core cooled in situ by the rapid infusion of a chilled solution into the aorta. For the liver, additional perfusion is provided through a separate cannula inserted through the splenic vein or other major side branch of the portal vein. Venous congestion must be prevented by venting the vena cava (Fig. 41-1).

If the donor is unstable, cooling through the aorta can be performed urgently (Fig. 41-2) and the organs removed rapidly. In addition to the other organs removed, the iliac vessels and, in small children, the carotid arteries of the donor are procured to serve as vascular grafts, if needed in the recipient.

Liver Preservation

Special solutions to prolong the duration of refrigeration have been used since 1976. The best one currently was developed at the University of Wisconsin (UW) by Belzer and his associates. This solution provides safe preservation of the liver for at least 12 to 16 hours, compared with 6 to 8 hours with other solutions. The ingredients of the UW solution include lactobionate, raffinose, starch, allopurinol, adenosine, and glutathione. Beyond the important benefit of hypothermia provided by any cold infusate, these ingredients are thought to act by controlling the oncotic ambience of the cells, by membrane stabilization, and by enrichment or preservation of the ATP-dependent energy state of not only the hepatocytes but also the lining cells of the microvasculature. Although the exact role of the individual ingredients may be debatable, at-

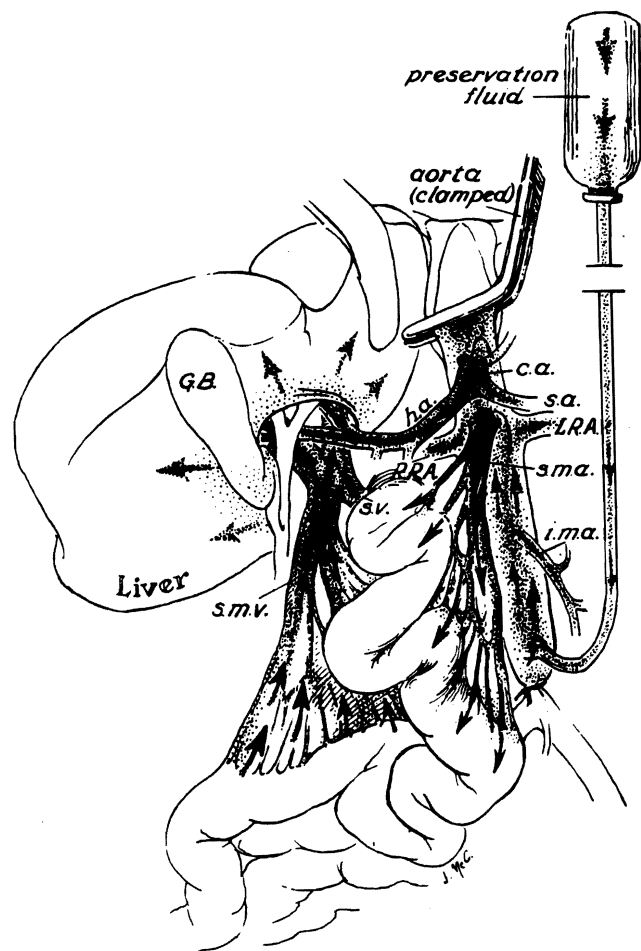


FIGURE 41-2. If there is no time to insert a splanchnic venous catheter for infusion, the rapid infusion of cold fluid into the aorta alone will promptly chill the liver because the superior mesenteric venous blood contributes to the hepatic cooling. All that is necessary is to insert the catheter into the distal aorta and to crossclamp the aorta at the diaphragm. GB, gallbladder; SMV, superior mesenteric vein; SV, splenic vein; ha, hepatic artery; ca, carotid artery; sa, splenic artery; LRA, [left renal artery]; sma, superior mesenteric artery; ima, inferior mesenteric artery; RRA, [right renal artery]. (From Starzl TE, Iwatsuki S, Shaw BW Jr, et al.: *Transplant Proc* 17:250-258, 1985.)

tempts to modify the original UW formula by removal of some of the constituents have reduced its effectiveness.

The UW solution has had a revolutionary effect on liver transplantation:

1. It has allowed country-wide and sometimes global sharing of liver grafts.
2. It has permitted the procedure to be performed semiselectively rather than urgently.
3. It has removed the tight time constraints that previously forced the surgeon to proceed with implantation of the graft even when the surgical field was suboptimally prepared.
4. It has facilitated the use of reduced-size organs by permitting back table procedures.

These advantages of the UW solution should not be construed as an invitation to a leisurely approach to liver transplantation. The margin of safety is rapidly decreased after 16 to 18 hours of preservation, with a nonlinear rise thereafter in primary graft nonfunction.

Vascular Grafts

Contrary to the experience with preserved vascular allografts, fresh vessels from the same donor provide effective and durable vascular conduits when they are needed. These free grafts can be preserved in a tissue culture medium and refrigerated for 1 or 2 days. It is best to utilize vascular grafts from donors of the same blood type as that of the recipient or, failing this, from donors with a compatible blood group. In the absence of cadaver vascular grafts, arterial grafts can be provided from the internal iliac artery of the recipient or the saphenous vein.

RECIPIENT PROCEDURE

The recipient procedure consists of four stages: (1) recipient hepatectomy, (2) anhepatic phase, (3) implantation, and (4) hemostasis.

Recipient Hepatectomy

The classic approach is through a bilateral subcostal incision with an upper midline extension. In pediatric cases, preoccupation by the surgeon with a rigid and an unvarying series of technical steps can be an invitation to disaster, because the normal anatomy is frequently distorted by previous Kasai's operations or other procedures. The previous surgery usually has been performed through a subcostal incision, and the sites of earlier dissection have involved the liver hilum and the subhepatic space. It is preferable to enter the abdomen through an unviolated area. This entry usually can be made by incorporating the old scar in a larger incision that includes unscarred tissue.

The hilum is exposed first, if this is simple, and the hepatic artery and common bile duct are dissected, ligated, and transected (Fig. 41-3). Particular care is

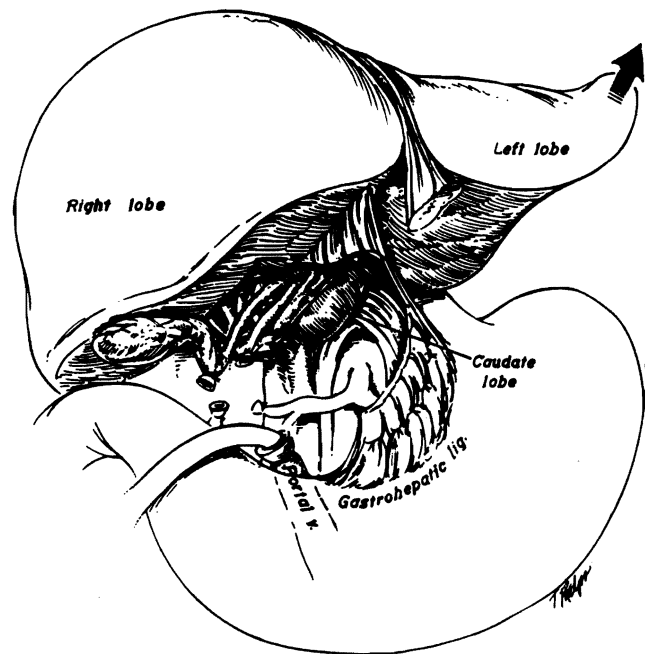


FIGURE 41-3. Recipient operation. The hilar structures are dissected, ligated, and divided. The portal vein is cannulated for the venovenous bypass. (From Tzakis A, Todo S, Starzl TE: *Ann Surg* 210:649-652, 1989.)

exercised to preserve these structures, because they are needed later for the anastomosis to the companion structures of the new graft.

If large enough, the patient is placed on venovenous bypass. With the native liver devascularized, the ligaments are severed, and mobilization is completed (Figs. 41-3 and 41-4). Control of the infrahepatic and suprahepatic vena cava is obtained, and the liver is removed after cross-clamping these large vessels.

Variations of the hepatectomy are too numerous to describe here. In principle, control of the hilum and the vena cava has to be obtained without damage to the transverse colon and duodenum, which are usually adherent to the undersurface of the liver from a previous operation. A useful approach to the hilum is through the lesser sac, whereby the left lateral segment is mobilized and the left portion of the gastrohepatic ligament is incised. The hilar structures can then be identified, as the index finger can be inserted behind them from the left side. In uncomplicated cases, the approach to the hilum is less difficult from the right side.

The hepatic artery and portal vein are ligated as superiorly as possible. When left from a Kasai's operation, the previously made Roux-en-Y loop is identified and ligated as superiorly as possible. At this point, the exact location of the colon and duodenum is better known, and they are separated from the liver. After devascularizing the liver, the inferior vena cava is controlled and clamped, and the liver is removed. The right adrenal vein, which enters the retrohepatic vena cava, must be ligated if the vena cava segment is removed.

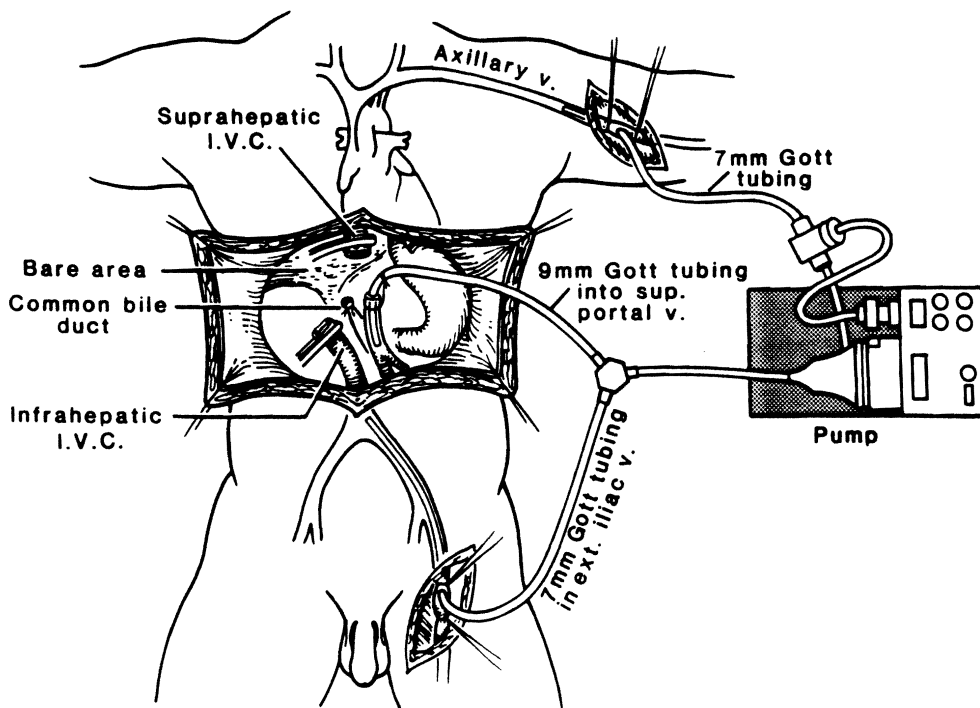


FIGURE 41-4. Pump-driven venovenous bypass, which allows decompression of the splanchnic and systemic venous beds without the need for heparinization.

The hilum of the liver is at times unapproachable from the inferior surface of the liver. In these cases, the suprahepatic cava can be dissected out first and clamped. The liver side of the cava is occluded by inserting the index finger (Fig. 41-5) or by oversewing. This maneuver allows the liver to be shelled out from above. As the liver comes down, it is attached to a stalk consisting of the retrohepatic vena cava and the hilar structures. These are increasingly accessible as the liver is mobilized from the wound and can be individually controlled and transected, as the liver is removed.

Anhepatic Phase

The anhepatic phase marks the time between the clamping of the portal vein and inferior vena cava and the revascularization of the new graft. During this time, systemic and portal venous beds are obstructed, unless a venovenous bypass is used. The consequent insult of venous hypertension is better tolerated by children than by adults, but even in children this is a time of urgency. It may be necessary to sew in the new liver in the presence of cardiovascular instability, which can be life-threatening.

VENOVENOUS BYPASS. The venovenous bypass was designed to avoid these dangerous changes. It consists of an extracorporeal circulation, whereby blood is pumped from the inferior vena cava and portal vein to the superior vena cava. The portal vein is cannulated directly through its transected end, whereas the inferior and superior venae cavae are cannulated through the saphenous and axillary veins (Fig. 41-4). Heparin-bonded shunts or chest tubes are employed as venous cannulas. Flow is maintained with a Biomedicus pump

(Biomedicus, Inc., Minneapolis, MN). With appropriate size selections of the tubing and pump head, a flow of 500 ml/min or more provides protection from clotting. Clotting abnormalities due to liver disease act as natural anticoagulants. With this technique, the portal venous return is interrupted only for the time required for construction of the portal anastomosis, during which time vena caval decompression is continued. Bypass usually can be done with children larger than 15 kg body weight, but it is an increasingly difficult and unreliable technique with children smaller than this.

PIGGYBACK LIVER TRANSPLANTATION. This technique is particularly helpful when venovenous bypass is not possible and allows the recipient vena cava to remain intact throughout the procedure. The liver is stripped off the vena cava (Fig. 41-6), ligating and dividing hepatic vein tributaries. An ostium is created to receive and transmit the venous outflow from the graft, by joining the mouths of the left and middle, the middle and right, or all the upper hepatic veins. The suprahepatic vena cava of the graft is anastomosed to this opening (Fig. 41-7). The stripping of the liver from the vena cava can be tedious and dangerous. Should this be the case, the segment of retrohepatic vena cava should be removed, and a conventional procedure is then performed with replacement of the vena caval segment (Fig. 41-8).

Maintenance of cardiovascular stability of the recipient with the venovenous bypass or with piggyback techniques has allowed liver transplantation to be performed in the most technically demanding cases. These techniques also allow hemostasis and preparation of the recipient field under more satisfactory circumstances.

FIGURE 41-5. Removal of the liver from above downward, preventing hemorrhage with a finger or fingers thrust down the lumen of the transected suprahepatic vena cava. The maneuver is indicated if it is difficult or impossible to safely encircle the inferior vena cava below the liver. This technique is specific for certain cases of biliary atresia with extensive subhepatic scarring in which the small size of these livers makes it possible to completely occlude the vena cava with a single finger.

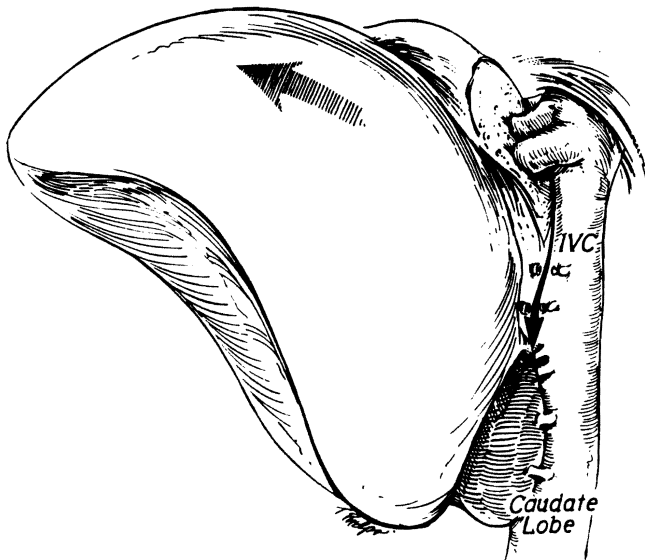
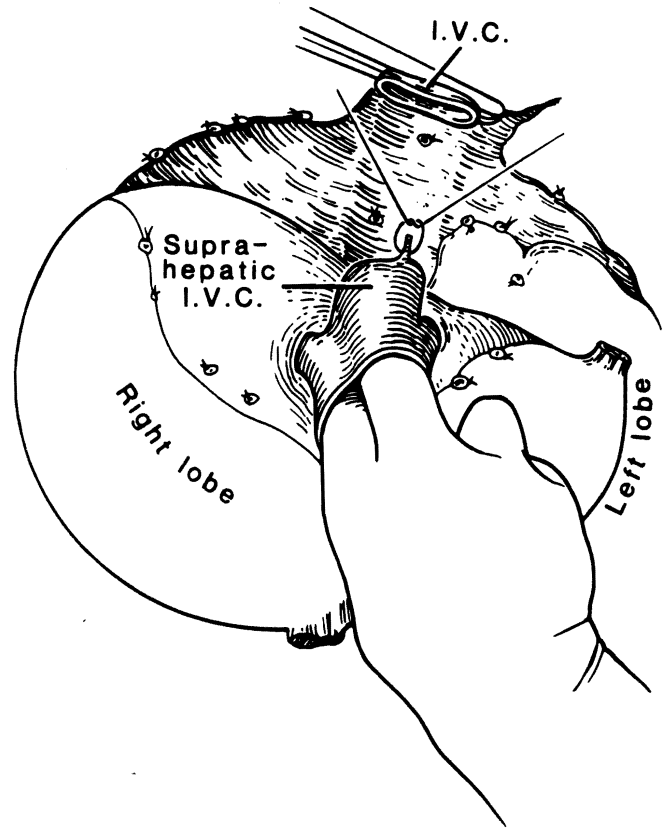


FIGURE 41-6. Steps in preparation of the recipient vena cava for the piggyback operation. All the small hepatic veins entering the retrohepatic vena cava are ligated and divided, and the large principal tributaries (right, middle, and left hepatic veins) are dissected free. IVC, inferior vena cava. (From Tzakis A, Todo S, Starzl TE: *Ann Surg* 210:649-652, 1989. Used by permission.)

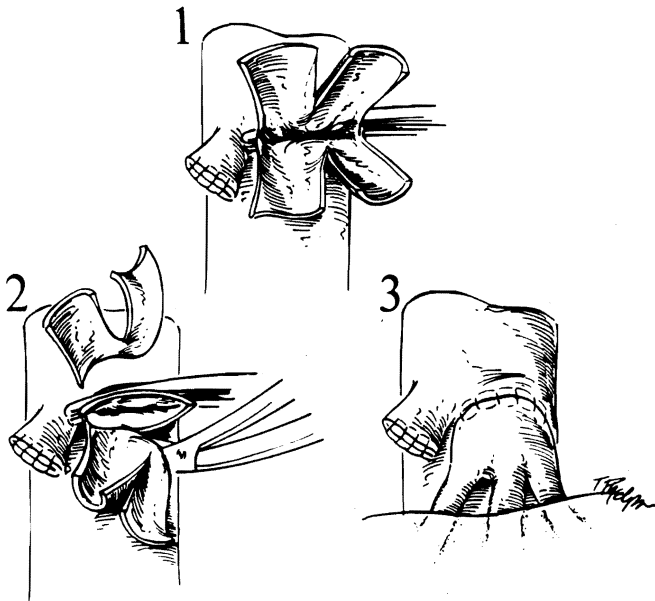


FIGURE 41-7. Cuffs are fashioned for the outflow anastomosis. (From Tzakis A, Todo S, Starzl TE: *Ann Surg* 210:649-652, 1989.)

Implantation

In the usual case, the suprahepatic vena caval anastomosis is performed first (Fig. 41-8). The infrahepatic vena caval anastomosis is then performed while the liver is flushed with cold lactated Ringer's solution to remove air and debris and the high potassium load that is in most preservation fluids. When the liver is placed piggyback, a lower caval anastomosis is not needed, and the stump is either ligated (Fig. 41-9) or oversewn.

The third anastomosis involves the portal vein (Figs. 41-8 and 41-9). When it is completed, the liver is perfused. The portal vein anastomosis is end to end. If the recipient portal vein is clotted or not usable, dissection of the recipient portal vein to the confluence

of the superior mesenteric vein and splenic vein may be needed. Reconstruction can be performed from this junction directly to the donor portal vein or indirectly, via an interposition venous graft. An alternative and usually simpler solution is a venous jump graft that is anastomosed to the side of the recipient superior mesenteric vein and led to the donor portal vein through an opening in the transverse mesocolon and behind the antrum of the stomach (Fig. 41-10).

The arterial anastomosis is performed as the final step of revascularization, although the surgeon may elect to perform it before the portal reconstruction. In that case, the liver can be perfused with arterial blood first. Alternatively, revascularization can be deferred until all vessels have been reconstructed.

Many permutations of the arterial reconstruction

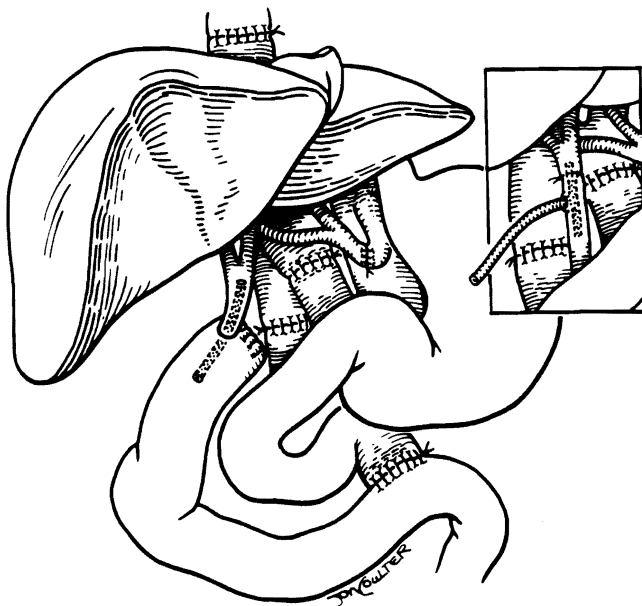
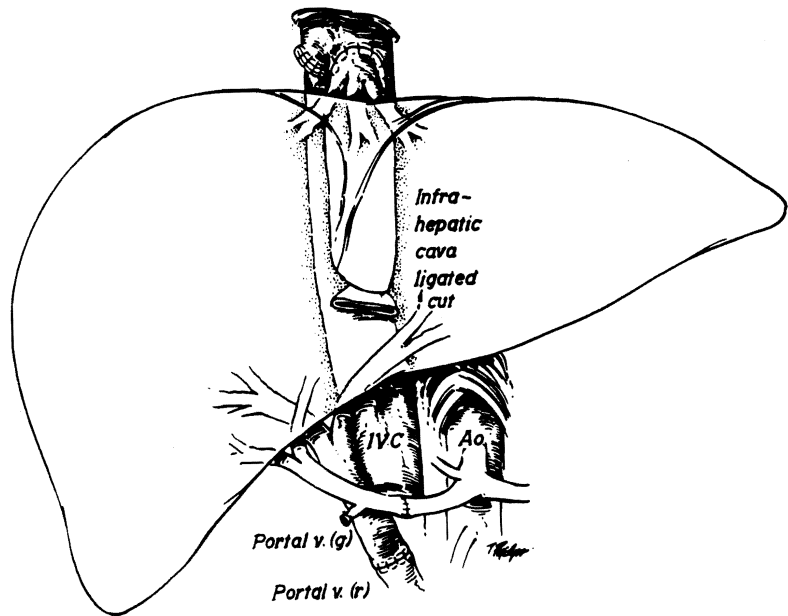


FIGURE 41-8. Orthotopic liver transplantation (liver replacement). Biliary tract reconstruction usually is with choledochojejunostomy (to a Roux-en-Y limb) or with choledochocholedochostomy (insert), which is stented with a T tube.

FIGURE 41-9. Transplantation of the liver piggyback onto the recipient inferior vena cava (IVC), which is preserved through its length. Note that the suprahepatic vena cava of the homograft is anastomosed to the anterior wall of the recipient vena cava. The retrohepatic vena cava of the homograft is sutured or ligated, leaving a blind sac into which numerous hepatic veins empty. Ao, aorta. (From Tzakis A, Todo S, Starzl TE: *Ann Surg* 210:649-652, 1989. Used by permission.)



have been described, because donor and recipient anomalies are so common. Significant donor variations, which are seen in about one third of the cases, include anomalous branches to the hepatic graft from the aorta directly or from the left gastric or superior mesenteric artery. Examples of reconstructions of the donor arterial abnormalities are shown in Figures 41-11 and 41-12. These usually are performed on the back table so that only a single arterial anastomosis to a recipient vessel or vascular graft is necessary, after the liver is brought into the operative field.

RECIPIENT VARIATIONS. The recipient arterial anatomy has the same anomalies. In addition, arterial disease or surgical damage may render the recipient vessel unusable for arterialization. This problem can be overcome with vascular grafts, which usually are "jumped" from the recipient infrarenal aorta (Fig. 41-13) and, occasionally, from the recipient suprarenal aorta or one of the iliac arteries.

BILIARY RECONSTRUCTION. If possible, an end-to-end choledochocholedochostomy with a T tube is performed (Fig. 41-8). If this procedure is not feasible, choledochojejunostomy with a defunctionalized Roux-en-Y limb is the alternative (Fig. 41-8). In children, the Roux-en-Y technique is required in more than 90% of cases.

TECHNICAL COMPLICATIONS

Liver transplantation is an unforgiving procedure. Perioperative bleeding is a constant threat, which may be compounded by existing coagulopathy in graft dysfunction. Any major technical imperfection is almost certain to result in a complication or frequently a cascade of complications. The most serious complications are graft devascularization with gangrene and biliary fistulas or obstructions.

The clinical presentation of most technical complications can mimic rejection. If a technical complication is misdiagnosed as rejection, an unjustified increase in immunosuppression can amplify the intrinsic risk of the original misadventure. Consequently, rejection

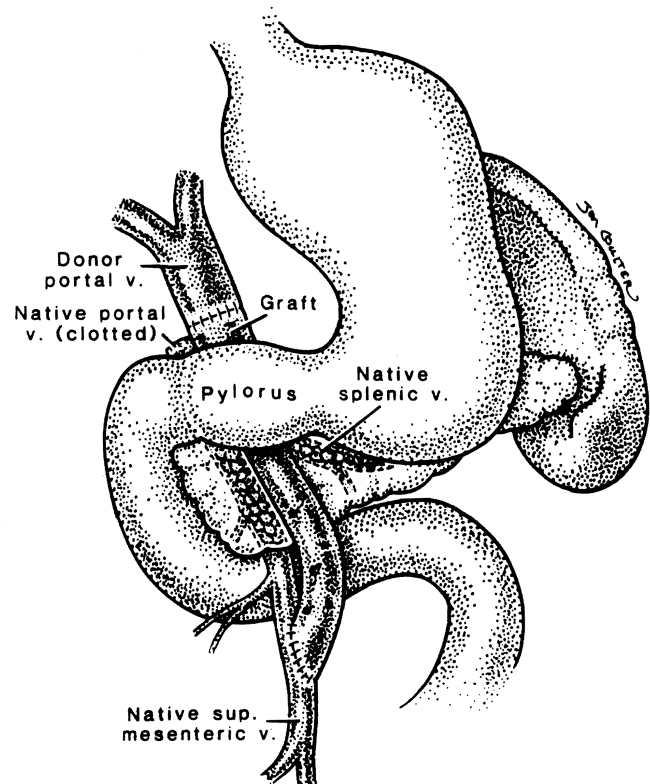


FIGURE 41-10. A vein graft for portal vein reconstruction when thrombosis of the recipient portal, splenic, or superior mesenteric vein precludes a standard operation. Note that the vein graft is jumped from the distal superior mesenteric vein through the transverse mesocolon over the pancreas and behind the pylorus.

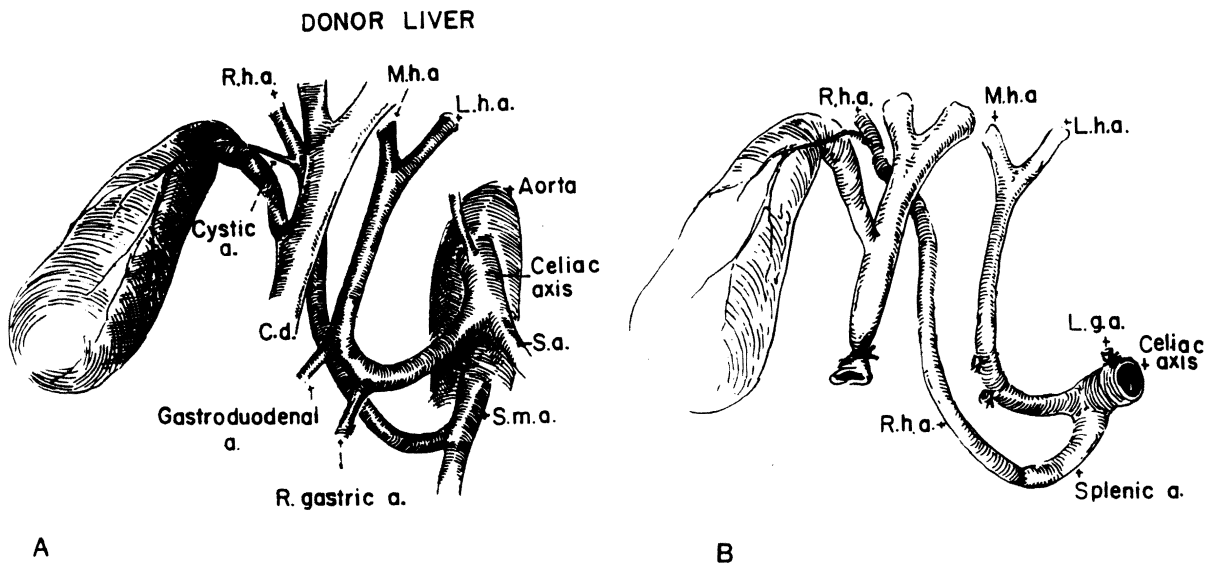


FIGURE 41-11. A, The hepatic arterial supply in this case comes from both the celiac axis and superior mesenteric artery of the donor liver.
 B, Reconstruction by anastomosis of the graft right hepatic artery rising from the superior mesenteric artery to the splenic artery.
 C. d. common duct; Lga, left gastric artery; Lha, left hepatic artery; Mha, middle hepatic artery; Rha, right hepatic artery; Sa, splenic artery; Sma, superior mesenteric artery.

should be confirmed only after the anatomic integrity of the graft has been established by the appropriate diagnostic steps.

Hepatic Artery Thrombosis

Hepatic artery thrombosis is the most common technical complication leading to graft failure or to death. Nontechnical factors causing thrombosis include exces-

sive intraoperative and perioperative clotting factors and platelet infusions. Protein C, which is a natural anticoagulant produced by the liver, may be deficient after liver transplantation.

Most hepatic artery thromboses occur within hours or days after liver transplantation. Color Doppler ultrasound is reliable for detecting the event, but it is less reliable in smaller children. Also, in cases of rejection, the hepatic artery is difficult to detect by the

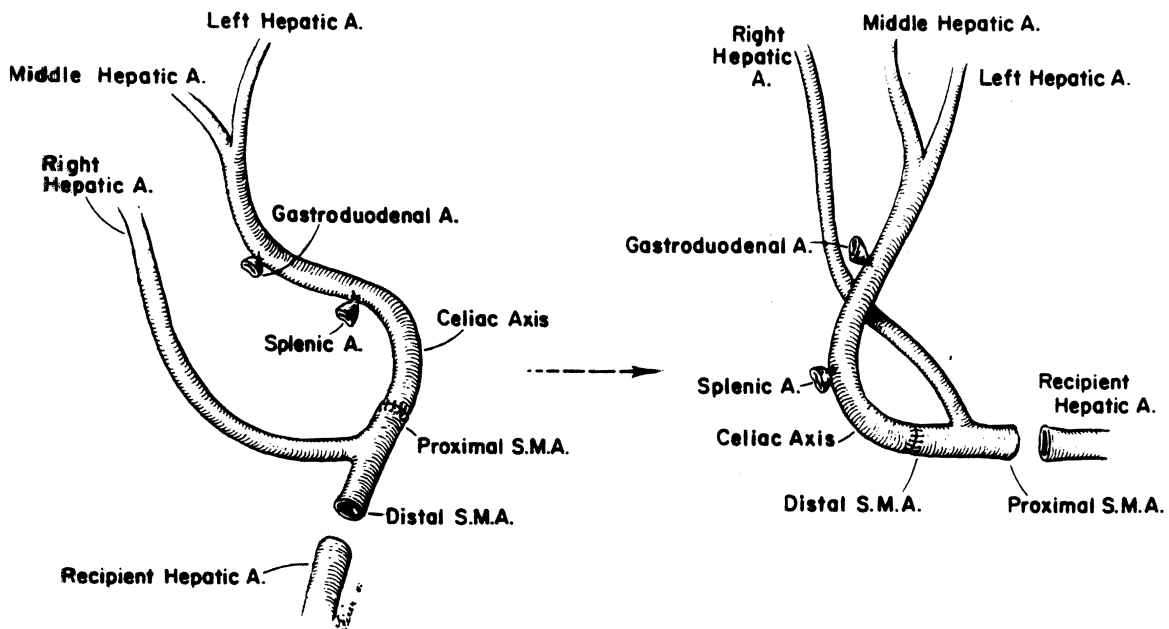


FIGURE 41-12. Alternative method of vascular reconstruction used for the anomaly shown in Figure 41-11. The homograft celiac axis is anastomosed to the homograft superior mesenteric artery. These versions differ only in that the opposite ends of the superior mesenteric artery are used for the anastomosis to the recipient vessels.

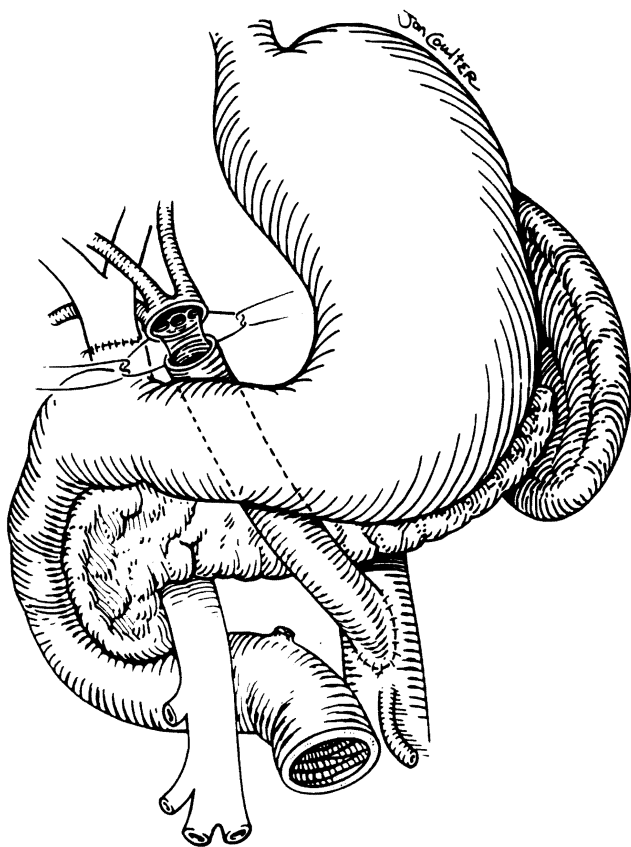


FIGURE 41-13. An antepancreatic route for a vascular graft placed onto the infrarenal abdominal aorta. The graft is brought either to the right or left of the middle colic vessels, anterior to the pancreas, and beneath the pylorus. (From Tzakis AG, Todo S, Starzl TE: *Transplant Int* 2:121, 1989. Used by permission.)

Doppler technique, because the arterial flow is dampened. The diagnosis can be made with certainty only with arteriography. The incidence of hepatic artery thrombosis in pediatric liver transplantation has been reported as 5 to 30% and is roughly inversely proportional to recipient size.

In about a third of cases with hepatic artery thrombosis, the patient is asymptomatic. Symptomatic thrombosis may occur in three forms, which can have some overlap: fulminant hepatic failure with liver gangrene, requiring immediate retransplantation; biliary complications, such as delayed bile leak or biliary strictures; and episodes of chronic bacteremia, with or without visible intrahepatic abscesses.

Although medical factors can be contributory, the role of seemingly minor technical errors in the etiology of hepatic artery thrombosis cannot be overemphasized. Perioperative administration of heparin and platelet aggregation inhibitors may be useful. In infants and smaller children, we administer these routinely for the duration of hospitalization.

Biliary Complications

Early and late biliary complications were once the greatest threat to liver transplantation. This threat has

been reduced by improved techniques, including avoidance of gallbladder conduit and cholecystenterostomy techniques. Now, only duct-to-duct or duct-to-Roux-en-Y limb reconstruction is used. Another ameliorating factor has been improved organ preservation. Nevertheless, biliary tract complications still occur at a rate of 10 to 15% and directly result in 2 to 10% of the global mortality rate in various reported series. In present-day practice, hepatic artery thrombosis is suspected whenever there is a biliary complication, because the principal blood supply of the graft bile duct is arterial.

Primary Graft Dysfunction

Approximately 10 to 15% of liver allografts have to be replaced within 2 months after transplantation, because they do not function adequately. In the extreme case of allograft nonfunction, survival for more than a few hours is not possible unless a second graft can be done. The most common reason for such a disaster is an imperfect donor or recipient operation, but there are numerous other reasons that may blight a seemingly perfect technical performance.

Humoral rejection should be suspected if the transplantation was with a positive cytotoxic crossmatch or with an ABO incompatible blood donor (discussed later). Endotoxemia, which can activate many of the same mediators involved in humoral immune reactions, has been suspected. Many other incompletely understood issues, including therapeutic errors, can contribute to primary graft dysfunction or nonfunction.

IMMUNOLOGIC CONSIDERATIONS

A perfect operation is only the beginning of a lifelong commitment to maintain the integrity of the graft against natural forces designed to destroy it by rejection, infection with viruses or other pathogens, or blood supply disruption or biliary drainage. In the long-range perspective, rejection still is the most common cause of graft loss.

It is known from animal observations that the liver, in relation to other organs, is naturally protected from humoral and cellular rejection. As a practical consideration, this advantage must be considered academic, as illustrated by the fact that consistently successful liver transplantation was not possible in humans until sophisticated and potent immunosuppression became available with the advent of cyclosporin A in 1980. For practical purposes, three forms of rejection have been defined: (1) humoral or hyperacute, (2) acute or cellular, and (3) chronic.

Humoral Rejection

The term humoral refers to the rejection by preformed antibodies. The resistance of the liver to preformed anti-graft antibodies is exemplified by the fact that liver transplantation often can be carried out successfully

with ABO incompatibility. However, the penalty for violating ABO compatibility rules is an increased rate of graft loss. A blood group-incompatible graft should be accepted only if in the most extreme urgency. The offending antigraft antibodies are isoagglutinins of both IgG and IgM classes, which can cause clots that plug the liver microvasculature.

If livers are exposed to the cytotoxic antibodies that connote presensitization to histocompatibility and other antigens, the same disruption of the graft microvasculature can occur, although less commonly and more slowly than in heart or kidney grafts. Rats and monkeys presensitized with repeated donor skin grafts have been shown to reject livers within hours after transplantation. Pathologic findings include immunoglobulin deposits, arteritis, and ischemic necrosis of the graft. Similar observations have been made in humans, although this kind of fulminant rejection is not necessarily associated with demonstrable preformed antidonor cytotoxic antibodies. Nevertheless, a positive cytotoxic crossmatch degrades the prognosis. Although not invulnerable to humoral rejection, the liver's relative resistance to this process is not understood. The liver graft may neutralize existing antibodies by Kupffer's cell action, or by secretion of soluble class I major histocompatibility complex (MHC) antigens, which neutralize or alter the antibodies.

The price of carrying out liver transplantation with a positive lymphocytotoxic crossmatch is an early graft failure rate that may be as high as 30%. In spite of this, we do not allow a positive crossmatch to deter transplantation if there is overriding need. Patients with wide-ranging cytotoxic antibodies usually react against all donors, and if their need for a new liver is great, they will die while waiting for a negative crossmatch donor.

Acute or Cellular Rejection

Acute or cellular rejection is characterized by the invasion of mononuclear cells, which are concentrated heavily in the portal triads. The intrahepatic bile ducts are the most specific targets of destruction, but the arteries and portal veins are also attacked. Consequently, a decline in total hepatic blood flow is characteristic during rejection. The central veins also can be invaded, leading to obliterative endophlebitis and subsequent outflow block, as in the Budd-Chiari syndrome. Graft edema, intrahepatic cholestasis, and various degrees of parenchymal damage are other findings.

Successful treatment can result in complete resolution of these findings. Failure to control the process results in early destruction of the graft or, if incompletely treated, in chronic rejection.

Chronic Rejection

Chronic rejection is characterized by occlusive arterial disease, disappearance of the intrahepatic bile ducts (disappearing bile duct syndrome), and varying degrees of fibrosis. A sparse but strategically located cellular infiltrate in the portal tracts is characteristic. Antibod-

ies also may play a role. Chronic rejection is most frequently manifested by obstructive jaundice progressing to liver failure after an initial period of relatively good preservation of synthetic and other parenchymal function.

The clinical presentation occurs hours or days after transplantation in the case of humoral rejection. Acute rejection can occur at any time but usually is days or weeks after transplantation. The pathologic findings of chronic rejection are usually evident in biopsy samples obtained months or years after transplantation but have been recorded as soon as 3 or 4 weeks. Efforts at such clear categorization may be fruitless, because acute rejection can follow a sublethal humoral rejection, and chronic rejection usually is the consequence of a partially treated or neglected acute rejection.

Graft vs. Host Disease

The liver graft is not only the target of immune attacks but also is capable of mounting immunologic reactions against the host, resulting in graft vs. host disease (GVHD). The incidence of GVHD is not known precisely, because it can be mild and therefore difficult to recognize. A special kind of GVHD is that seen after transplantation of the liver from a donor of a compatible but not identical major blood group (O to A, for example). Under these circumstances, hemolysis can be caused by isoagglutinins produced by lymphoid elements in the graft or migrating from it, which bind to and destroy recipient red blood cells.

IMMUNOSUPPRESSION

This discussion is limited to drugs that are currently utilized for clinical liver transplantation.

Glucocorticoids

Glucocorticoids were the first drugs in liver transplantation to reduce the body's immune defenses. They are given in combination with other immunosuppressants as maintenance treatment for prevention of rejection. They may be administered in much higher doses for single-dose bolus or short-course therapy. Prednisone and methylprednisolone are the principal agents.

The steroids are the most dose-maneuverable of all the immunosuppressive agents. Their action on the immune system is diffuse. Long-term high-dose steroid therapy will stunt growth in children and produce intolerable cosmetic deformation, including moon facies, buffalo hump, abdominal striae, and bone abnormalities. Steroids also create a fertile soil for opportunistic infections. Steroid therapy has thus been called the curse of survival.

Azathioprine

This purine antimetabolite, a derivative of 6-mercaptopurine, is useful for the prevention of rejection but not for its reversal. It was the first commonly admin-

istered chemotherapeutic agent, beginning in 1962, but now is employed as an adjuvant agent in drug cocktails based on cyclosporine, or FK 506, and prednisone. Azathioprine is used as a means of reducing the necessary doses of cyclosporine and the threat of cyclosporine nephrotoxicity. It is myelotoxic and must be monitored with frequent white blood cell count determinations. Azathioprine diffusely weakens immune defenses, in contrast to the more specific action of cyclosporine and FK 506.

Antilymphocyte Globulin

Antilymphocyte globulins (ALGs) are polyclonal or monoclonal antilymphoid antibodies designed to eliminate lymphocytes from the circulation and lymphoid depots of the recipient. They are given for treatment of rejection or from the time of operation for prophylaxis. The first ALGs were raised by immunizing rabbits, horses, or goats with lymphoid tissue (splenic, lymph node, thymic, or thoracic duct lymphocytes) and by purifying the IgG fraction in which the desired antibodies were found. Using cultured B lymphocytes as the immunizing antigen produced a more predictable product. However, all the ALGs represent a complex (polyclonal) response of the immune apparatus of the immunized animal, and thus, they have as their target a diffuse collection of recipient lymphoid and usually other cells.

With the hybridoma technique pioneered by Kohler and Milstein of England, a more sophisticated ALG, called OKT3, was developed which is produced by a single (monoclonal) immortalized cell. The target of OKT3 is the mature T lymphocyte. Since the clinical introduction of OKT3 by Cosimi of Boston, increasingly specific monoclonal ALGs have been produced by different hybridomas. These newer products can target lymphocyte subpopulations of T lymphocytes or sites of cytokine binding (interleukin-2 binding sites, for example). Their clinical use is still under investigation.

The efficacy of the established preparations of ALGs is beyond doubt but has been attended by a high rate of infection, particularly by viruses such as cytomegalovirus (CMV). In addition, the animal origin of the immunoglobulin (even the monoclonal preparations, raised with mouse hybridomas) led to rapid sensitization; immune elimination of the foreign proteins with

progressive loss of biologic potency; and potential for foreign protein reactions, such as anaphylaxis and serum sickness nephritis. Consequently, ALGs can be provided for only a limited time.

Cyclosporine

Cyclosporine is produced from a soil fungus *Trichoderma polysporum*. Unlike the immunosuppressive drugs that preceded it, cyclosporine is selective. It inhibits the activation of T-helper lymphocytes and suppresses the synthesis and expression of interleukin-2, gamma interferon, and other cytokines. The value of this specificity is partly lost, because the doses that can be administered are limited by nephrotoxicity, hypertension, and other side effects. Consequently, cyclosporine is combined with nonspecific drugs, such as azathioprine, steroids, and ALGs. Nevertheless, cyclosporine has had a revolutionary impact on transplantation.

FK 506

The drug, produced from *Streptomyces tsukubaensis*, has been in clinical use since early 1989. Although it is unrelated chemically to cyclosporine and has a different binding site, its immunologic targets are similar to those of cyclosporine. It appears to have a better therapeutic margin, and although often given with steroids, it is potent enough to be given alone (monotherapy) in the majority of cases—within 1 to 3 months after liver transplantation. Avoiding steroid therapy thereby is an overriding advantage in pediatric transplantation. In addition, the distressing hirsutism and coarsening of facial features often observed with cyclosporine are not observed with FK 506. Although, like cyclosporine, it is nephrotoxic, hypertension has not been common.

Complications of immunosuppression are derivative from the loss of immunologic defenses and specific to the drugs. The most serious generic complications from immunosuppression are (1) opportunistic infections (viral, bacterial, fungal, and protozoal), (2) lymphomas, which usually are B-cell tumors associated with Epstein-Barr virus, and (3) high incidence of epithelial and other nonlymphoid and hematopoietic malignancies. Complications specific to the individual drugs are listed in Table 41-1.

TABLE 41-1. Toxicity of Immunosuppressive Agents Currently in Use

Complication	Prednisone	Azathioprine	ALG	Cyclosporine	FK 506
Myelotoxicity	-	+	?	-	-
Neurotoxicity	+	-	?	+	+
Nephrotoxicity	-	-	-	+	+
Diabetes	+	-	-	+	+
Hirsutism	+	-	-	+	-
Gum hyperplasia	-	-	-	+	-
Hypertension	+	-	-	+	-
Wound healing	+	-	-	+	-
Facial brutalization	+	-	-	+	-
Obesity	+	-	-	-	-

+ = potential complication; ? = potential for this reaction is unknown.

SPECIFIC PEDIATRIC DISEASES

Biliary Atresia

Biliary atresia is defined as the congenital absence or inadequacy of canalization of the extrahepatic biliary system. Its incidence is one in 8000 to 15,000 live births, with approximately 400 new cases reported in the United States per year. Portoenterostomy (Kasai's procedure), which was introduced 2 decades ago to surgically drain the intrahepatic ducts, was the first procedure to provide any hope for victims of this wretched disease. However, even with relief of jaundice following Kasai's operation, biliary cirrhosis develops with variable speed in most patients.

Grossly evident bile drainage can be seen at the time of Kasai's procedure in almost 90% of infants who have undergone operation before the age of 2 months. The prognosis is considered better if there is a significant duct or large ductules in the porta hepatis or if there is bile bilirubin that can be drained at greater than 6.8 mg/100 ml.

Kasai's procedure was like a beacon of light when it was introduced, because there was no alternative therapy. Under these circumstances, success understandably was judged by bile production, elimination or improvement of jaundice, prolongation of life beyond a few months, and signs of physical or mental growth. All too often, the procedure merely prolonged a morbid life in a child deprived of normal growth and activities, whether jaundiced or not. Few patients have grown to normal teenage or adult life. Even those with successful Kasai's operations usually have died after a number of years or eventually have required transplantation.

Prior portoenterostomy can complicate the liver transplantation. In most cases, technical problems caused by previous operations are manageable by skilled teams. In a significant number of patients the combination of portal hypertension and dense surgical scarring makes the liver transplantation complicated and among the most dangerous procedures in pediatric surgery. Consequently, the role of Kasai's operation is being evaluated critically.

It may be that an attempt to drain the biliary system with Kasai's operation by an experienced surgeon can be justified, if the liver still appears relatively undamaged and other conditions are propitious. However, when the liver is damaged or cirrhotic, a portoenterostomy is more apt to be harmful than helpful. The argument has lost force that time can be bought with Kasai's operation to allow growth to a more reasonable size, not only because this is so often not achieved, but also because of greater success after transplantation in tiny recipients. Liver transplantation is the only treatment with which the disease is definitively rectified, with subsequent normal liver function, normal development, and complete rehabilitation. The attraction of transplantation as the primary therapy is increasingly difficult to resist.

Arteriohepatic Dysplasia

Arteriohepatic dysplasia (Alagille's syndrome) is a genetic disorder transmitted via an autosomal dominant gene with variable expression and penetrance. It is characterized by the combination of a broad forehead, pointed chin, vertebral defects, pulmonary artery stenosis, and cholestasis. Kasai's operation is not indicated. Characteristically, the liver disease has a fairly slow progress compared with biliary atresia. Transplantation is usually needed eventually. Cardiac angiography is often necessary for the evaluation.

Inborn Errors of Metabolism

Patients with liver-based inborn errors of metabolism can be treated by providing a phenotypically normal liver. Several products of hepatic synthesis permanently retain the original metabolic specificity of the donor after transplantation. These observations made it virtually certain that liver transplantation would become a decisive way to treat the inborn errors of metabolism that resulted partly or completely from deficiencies of specific liver enzymes or from abnormal products of hepatic synthesis.

This expectation has been fulfilled in many patients, some of whom have been followed for as long as 19 years after transplantation (Table 41-2). With other disorders in which the pathogenesis was not well understood, the transplantation itself became a powerful research tool by showing the extent of correction with a new liver and by elucidating the mechanisms by which correction was accomplished (see Table 41-2).

In the majority of recipients, the inborn error had itself been responsible for damage to the liver, and the conventional indications of liver failure or the development of malignant tumors prompted the liver replacement. However, an increasing number of transplantations have been carried out solely for the purpose of correcting the inborn error. In many of these patients (see Table 41-2), the excised liver has been anatomically normal.

Hepatitis Virus B

Although hepatitis virus B (HVB) can cause fulminant or chronic liver failure necessitating liver transplantation in children, the principal experience has been in adults. Such efforts have been plagued by disease recurrence in the new liver, often necessitating retransplantation. No reliable means exist to avoid recurrence. When serial retransplantations have been attempted, the progression of the disease in the new liver has been faster each time. Active and passive immunization and interferon- α therapy have not altered the outcome in most cases. However, about 20% of our patients have cleared the HVB surface antigen (HB_sAg) after transplantation. Almost all these successfully treated patients were operated on when there was minimal evidence of viral replication (HB_eAg negative).

TABLE 41-2. Inborn Errors of Metabolism Treated with Liver Transplantation

<i>Disease</i>	<i>Mechanism of Disease</i>	<i>Correction of Metabolic Defect</i>	<i>Longest Survival</i>	<i>Associated Liver Disease</i>
Alpha-antitrypsin deficiency	Structural abnormality of the protease inhibitor synthesized in liver	Yes	14 years*	Cirrhosis
Wilson's disease	Abnormal biliary copper excretion, decreased copper binding to ceruloplasmin, and copper accumulation in tissues; autosomal recessive gene mapped to chromosome 13	Yes	17.5 years*	Cirrhosis
Tyrosinemia	Fumarylacetoacetate hydrolase deficiency	Nearly complete	8.5 years*	Cirrhosis, hepatoma
Type I glycogen storage disease	Glucose-6-phosphatase deficiency	Yes	8 years*	Glycogen storage, fibrosis, tumors
Type IV glycogen storage disease	Amylo-1,4-transglucosidase (branching enzyme) defect	Incomplete†	6 years*	Cirrhosis
Cystic fibrosis	Unknown; pancreatic disease, liver often affected	Not known	6 years*	Cirrhosis
Nieman-Pick disease	Sphingomyelinase deficiency, sphingomyelin storage	Not known	2 years (patient died)	None
Sea-blue histiocyte syndrome	Unknown; neurovisceral lipochrome storage	No	8 years*	Cirrhosis
Erythropoietic protoporphyria	Hepatic ferrochelatase deficiency, ? overproduction of protoporphyrin by erythropoietic tissues	Incomplete	2.5 years	Cirrhosis
Crigler-Najjar syndrome	Glucuronyltransferase deficiency	Yes	5 years	None
Type I hyperoxaluria	Peroxisomal alanine: glyoxylate aminotransferase deficiency	Yes	8 months	None
Urea cycle enzyme deficiency	Ornithine carbamoyltransferase deficiency	Yes	2.5 years*	None
C protein deficiency	Defective C protein synthesis	Yes	3.25 years*	None
Familial hypercholesterolemia	LDL receptor deficiency, (patient died), LDL overproduction	Incomplete	6¾ years*	None
Hemophilia A	Factor VIII deficiency	Yes	4 years* (patient died of AIDS)	Cirrhosis, a complication of blood component therapy
Hemophilia B	Factor IX deficiency	Yes	6 months	Cirrhosis, a complication of blood component therapy

*Patients in University of Colorado-University of Pittsburgh series. Follow-up to January 1989.

†Amylopectin deposits found in heart biopsy 4 years after transplantation.

Modified from Starzl TE, Demetris AJ: *Liver Transplantation*. Year Book Medical Publishers, Chicago, IL, 1990.

Hepatitis C

Hepatitis C (non-A and non-B) is the leading viral cause of chronic active hepatitis leading to transplantation. The virus can also cause recurrent disease in an otherwise successfully transplanted liver allograft. Serologic tests that allow epidemiologic studies have been available only for about 1 year. However, these tests have helped establish the fact that interferon- α therapy can be effective in treating recurrent disease. If recurrent hepatitis is suspected, it must be differentiated from rejection. This is not always simple, even with biopsy studies.

Primary Hepatic Malignancies

Unsuspected tumors found during liver transplantation for end stage liver disease are called incidental. They have a low rate of recurrence.

Total hepatectomy and liver transplantation may be the only means of removing the kind of extensive

hepatic malignancy that is the primary reason for consideration of transplantation. Primary hepatic malignancies are relatively uncommon in the pediatric population and account for less than 5% of the liver transplant cases. The pediatric experience at the University of Pittsburgh is summarized in Table 41-3. The results were better with hepatoblastomas and incidental hepatomas than with large primary hepatomas. The patients with hepatoma often died later from metastases. Chemotherapy is thought to have an important role in the treatment of hepatoblastoma. The role of chemotherapy in the treatment of hepatomas is less clear and is under evaluation.

MULTIVISCERAL TRANSPLANTATION

Multivisceral transplants that include the liver have been used to treat a few patients who have experienced the failure of more than one visceral organ system, or in an effort to extirpate tumors beyond the field of a

TABLE 41-3. Liver Transplantation for Primary Hepatic Malignancies at the University of Pittsburgh

Pathology	No. of Pts.	No. of Pts. Alive	Mean Follow-up of Survivors	No. of Pts. Dead	Mean Time to Death	Cause of Death
Hepatocellular carcinoma						
Tumor size <2 cm*	7	6	6.15 years	1	3 years	Postsplenectomy sepsis
Tumor size >2 cm†	8	2	2.42 years	6	2 years	Recurrence in 5 patients‡; lymphoproliferative disease in 1 patient
Hepatoblastoma	6	5	19.6 months	1	2 months	Recurrence

*All tumors in this group were incidental; 5 occurred in tyrosinemia patients.

†Two patients in this group underwent upper abdominal exenteration and pancreatic islet transplantation and are excluded from the table.

‡Mean time to death from recurrence was 8 months.

standard total hepatectomy. With full multivisceral transplantation, all the intraabdominal organs except the spleen make up the allograft. Two children in the Pittsburgh experience lived for 36 and 192 days after this operation under cyclosporine immunosuppression, but both died of lymphoproliferative tumors (B cell lymphomas), which involved the liver and intestine. Margareiter of Innsbruck, Austria, has had survival of 8½ months after this operation in an adult patient who eventually died of recurrent carcinoma of the pancreas. Our longest surviving patient and Margareiter's patient had function of all the organs of their composite grafts. The feasibility of multivisceral transplantation is suggested by the lifetime survival in good health of rats at a result that is more easily achieved than that with transplantation of the intestine alone.

Less extreme variations of the multivisceral allograft have included the so-called cluster transplant in which the intestine and stomach are discarded. With this operation, the liver, pancreas, and a segment of duodenum are utilized to replace the recipient resection specimen, which includes the liver, pancreas, spleen, stomach, duodenum, and variable lengths of jejunum and colon (Fig. 41-14). The cluster operation was designed for extensive tumors involving the liver, pancreas, or other upper abdominal organs and has been used mainly in adults. However, one of our pediatric patients who underwent upper abdominal exenteration had whole organ replacement of the liver only but was also given pancreatic islets from the same donor (Fig. 41-15). She has been insulin-free and without tumor recurrence (hepatoma) for more than a year. She represents the first unequivocally successful case of pancreatic islet transplantation.

Two more children with absent intestines and liver failure secondary to massive perinatal enterectomy and hyperalimentation have had combined liver and intestinal transplantation (Fig. 41-16) under FK 506 with good results 2 and 7 months later. This operation was first performed successfully by Drs. David Grant and William Wall of London, Ontario. We also are following an adult who underwent this procedure, as well as another adult who underwent a complete small bowel homograft. Four of four patients provided with complete small bowel transplants using FK 506 are living.

The limited exploitation of the multivisceral procedures, especially those that include the intestine, may

change. The lymphoid components of these grafts, which have been feared as a cause of GVHD, actually undergo repopulation with recipient lymphoreticular cells. Previously, the appearance of recipient cells in these grafts was equated with rejection rather than construed as desirable. The repopulation without graft destruction was not consistently achieved or understood, until the more potent immunosuppression with FK 506 became available.

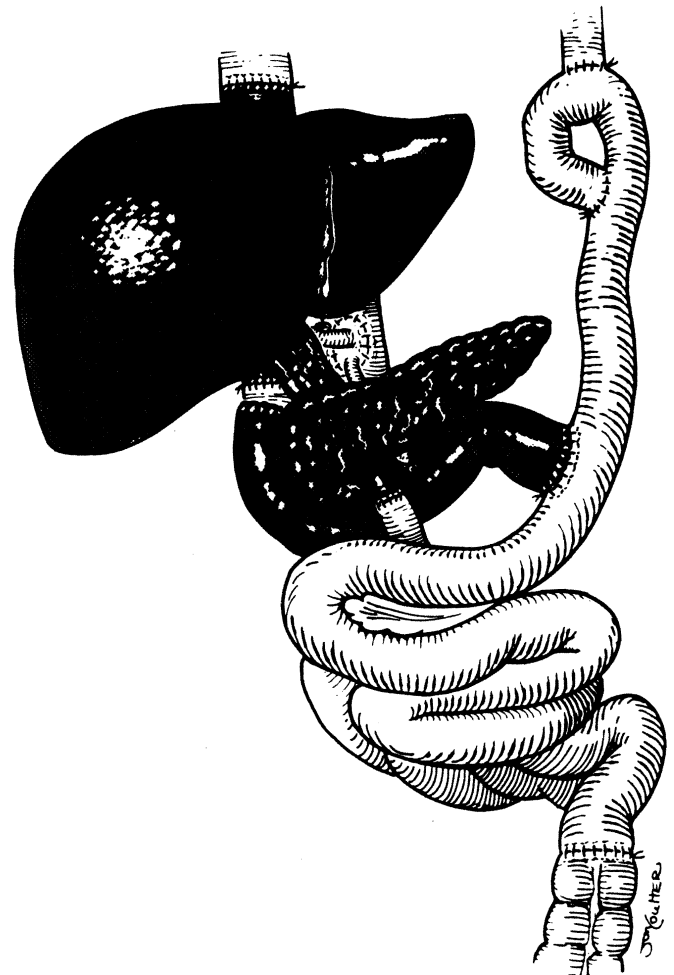
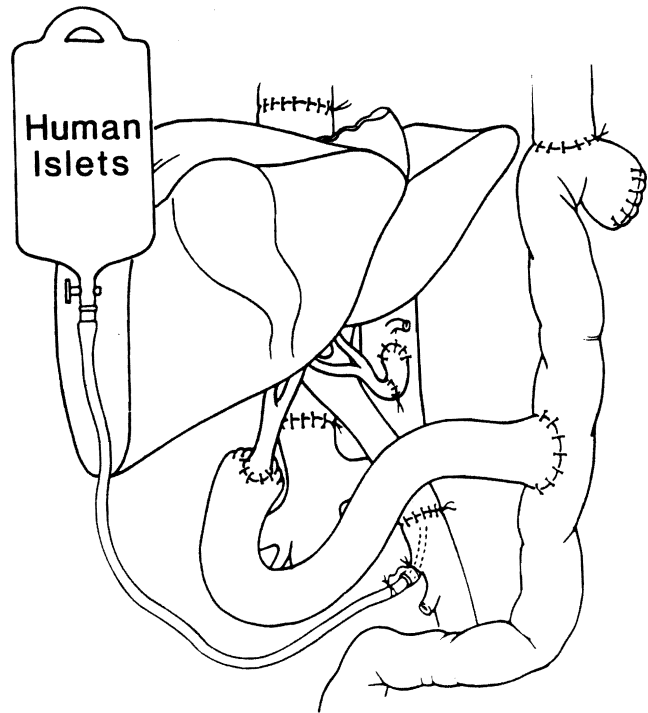


FIGURE 41-14. Completed cluster implantation after upper abdominal exenteration.

FIGURE 41-15. Liver and pancreatic islet transplantation after upper abdominal exenteration. (From Tzakis AG, Ricordi C, Alejandro R, et al.: *Lancet* 336:402-405, 1990.)



DONOR

RECIPIENT

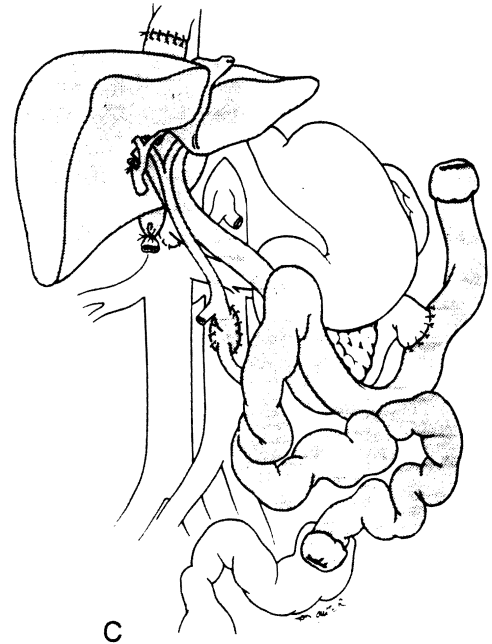
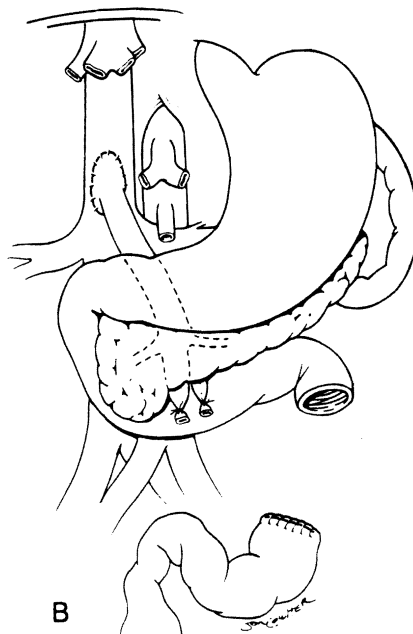
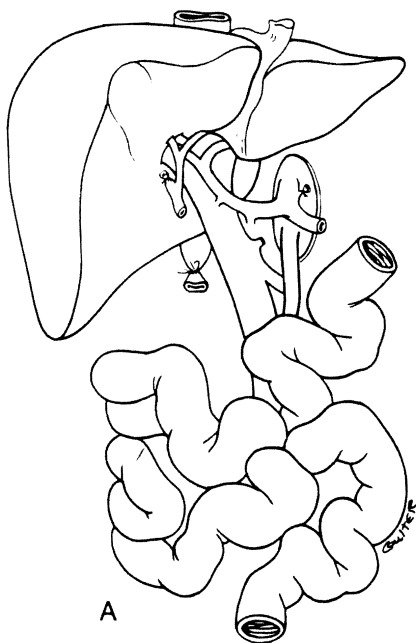


FIGURE 41-16. A, Graft used for combined liver and small intestine transplantation. B, Operative field after hepatectomy. Note that the recipient portal vein has been anastomosed to the vena cava for decompression of the viscera left behind. C, Completion of the liver-intestinal graft. At this time the previously placed portacaval shunt (see B) can be taken down and the recipient portal vein anastomosed to the side of the graft portal or superior mesenteric vein.

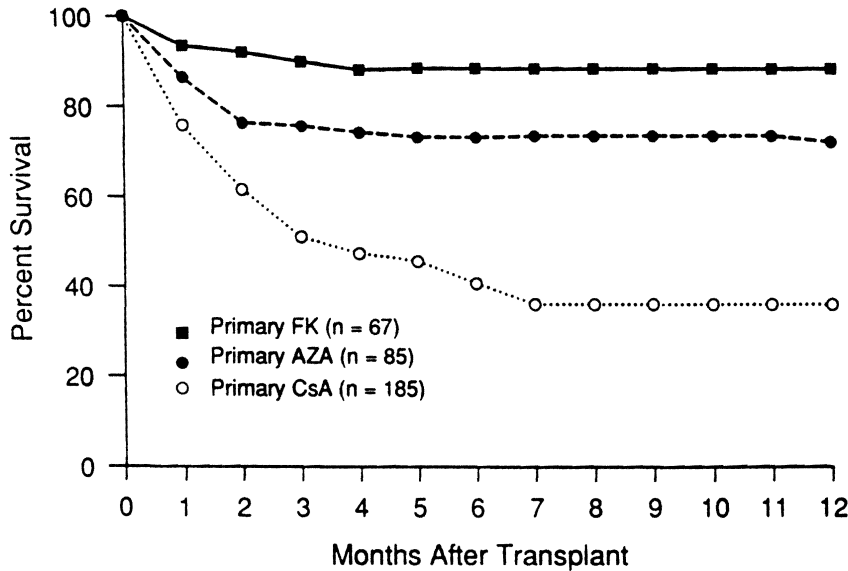


FIGURE 41-17. Pediatric liver transplantation recipient survival; FK 506 vs. cyclosporine vs. azathioprine.

RESULTS OF PEDIATRIC LIVER TRANSPLANTATION

Effect of Immunosuppression

The results of conventional liver transplantation can be categorized into three successive periods, which are defined by the immunosuppressive agents available during those periods. These periods have been called the (1) *azathioprine era*, in which azathioprine sometimes replaced with cyclophosphamide and prednisone (with or without ALG) were used; (2) *cyclosporine era*, in which cyclosporine and prednisone, with or without azathioprine and ALG (most frequently OKT3) were used; and (3) *FK 506 era*, in which FK 506 and prednisone, with or without ALG (always OKT3) were available. Each era has had a better patient (Fig. 41-17) and graft (Fig. 41-18) survival

rate than the one before it. It is thought that the advancements in immunosuppression were responsible for this improvement rather than nonspecific factors, such as the acquisition of more experience. Evidence other than raw survival supports this belief.

In another analysis, all FK 506-treated liver recipients were compared with recent historical control patients treated with cyclosporine. The controls were matched for underlying disease, age, and urgency status at the time of transplantation. The results in the first 40 consecutive liver recipients treated with FK 506 vs. 35 cyclosporine-treated controls 3 months after transplantation are shown in Table 41-4. In addition to improved survival in the FK 506 recipients, other significant advantages were the reduced incidence of fatal infections and the reduced dependence on prednisone, azathioprine, OKT3, and antihypertensive medication.

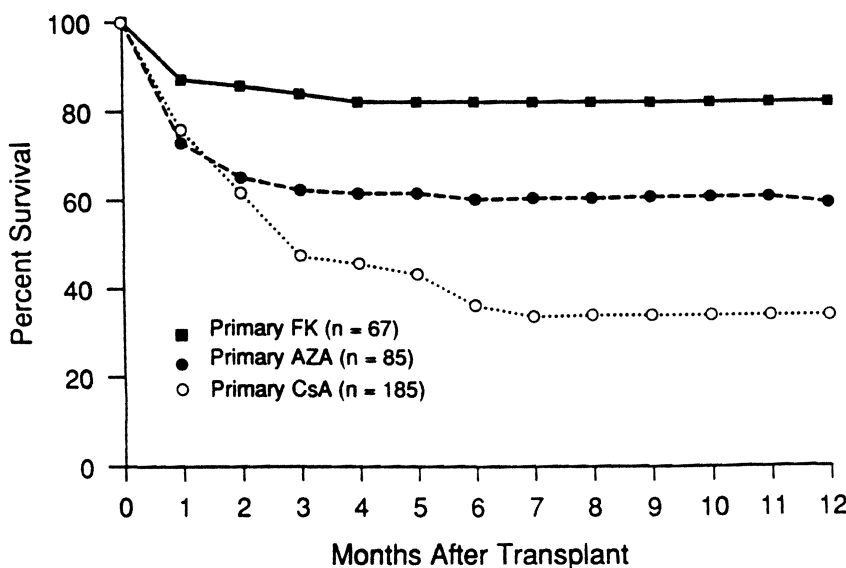


FIGURE 41-18. Graft survival in pediatric liver transplantation recipients; FK 506 vs. cyclosporine vs. azathioprine.

TABLE 41-4. Use of FK 506 in Pediatric Liver Transplantation: Comparison with Cyclosporine Historical Control Subjects at 90 Days

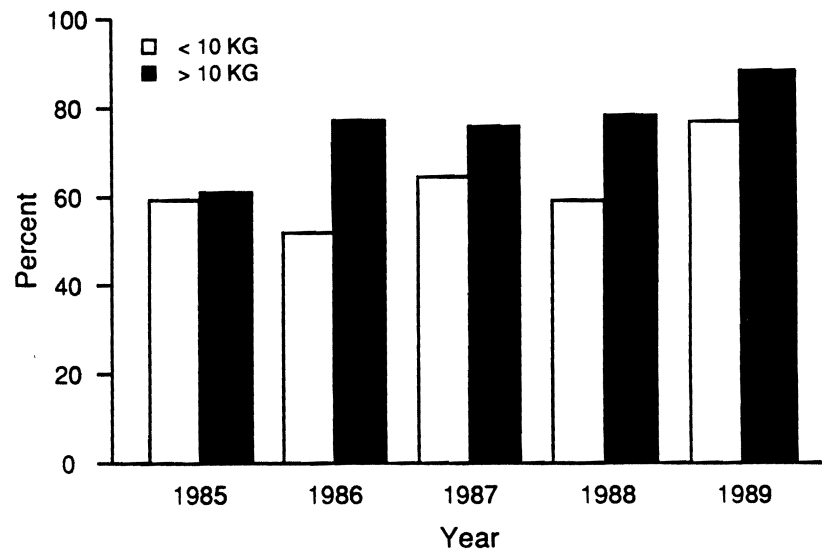
	FK 506	Cyclosporine
Number analyzed	40	35
Survival	36/40	26/35
Number of retransplantations	4/40	5/35
Days of first hospitalization*	29.5	42.0, p = .005
ICU days*	8.9	12.5
Rejection/pt*	0.5	0.7
Infection episodes/pt*	1.1	1.5
Deaths due to infection	1	6, p = .06
Patients receiving other drugs:		
Prednisone	10/36	26/26, p < 0.001
Antihypertensive agents	2/26	11/26, p < 0.001
OKT3	5/40	12/35, p = 0.04
Azathioprine	0/36	16/26, p < 0.001
BUN values:		
Maximum*	46.3	47.6
At discharge*	19	21
Creatinine levels		
Maximum*	1.1	1.1
At discharge*	0.38	0.47

*Mean values.

Effect of Recipient Size

Low body weight, especially in pediatric liver recipients, has been viewed in the past as a poor prognostic factor because of technical problems in anastomosing tiny hilar vessels. However, routine microsurgical techniques may have narrowed this gap. A possible trend toward the improved survival in infants under 10 kg may have occurred at our own center in that the 1-year survival rate, which was 59% in 1985, improved to 77% in 1989 (Fig. 41-19). In addition to better survival, the number of recipients weighing less than 10 kg has increased. Between 1981 and 1984, only 16% of our liver transplant recipients were under 10 kg. Since 1988, over 40% of recipients are this small (Fig. 41-20).

FIGURE 41-19. One-year survival in pediatric liver transplantation by body weight and year of transplant.



Previous Operation

Children with biliary atresia suffer higher than average perioperative morbidity and mortality rates, which may be attributed to difficulties caused by previous surgical procedures. At particular risk are children who have had multiple previous operations compared with those who have had a single Kasai's procedure (Fig. 41-21).

Prognosis

The better the patient's condition at the time of transplantation, the better the prognosis. This can be demonstrated graphically in cholestatic disease, in which jaundice is a reliable index of the patient's general condition (Fig. 41-22). This kind of information should influence the decision about when to proceed, a judgment that should include the parents, primary physician, and transplant surgeons. If the disease progresses to a terminal illness, finding an organ in time may be impossible. Even with an organ available, the penalty of the decision to procrastinate could make transplantation futile.

AUXILIARY LIVER TRANSPLANTATION

Auxiliary liver transplantation as an alternative to orthotopic liver transplantation (OLTx) has two theoretic advantages: (1) avoidance of the native hepatectomy with its technical complications and (2) retention of the residual function of the diseased native liver, which may be substantial in some diseases, such as biliary atresia. It is self-evident that in some disorders (e.g., malignant tumors and hepatic infection or necrosis) removal of the native liver is an essential requirement.

Auxiliary transplantation fell into disrepute, because of the overwhelming mortality rate following clinical

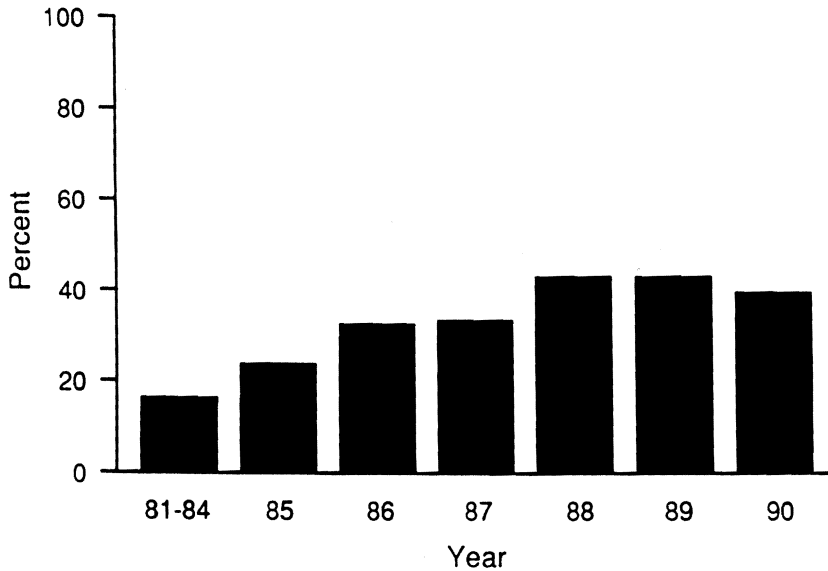


FIGURE 41-20. Percentage of pediatric liver transplants in patients under 10 kg by year.

trials. In addition, it was discovered that these heterotopic allografts required portal revascularization with blood from the hormone- and nutrient-rich blood returning from recipient viscera. The finding was thought to be due to competition for vital portal flow with the native liver. Finding a means of diverting portal flow through the graft presents its own set of difficulties.

Interest in auxiliary transplantation was reawakened in 1988 by a report from Holland of several successful cases. However, further trials by the Dutch group and additional unpublished experience in other medical centers have not resulted in optimistic follow-up claims.

AVAILABILITY OF ORGANS

The acceptance of liver transplantation as a conventional form of therapy was a phenomenon of the 1980s. Because its application will be or already has been

limited by the availability of organs, several strategies to increase the supply have been examined.

Living Donors

The left lobe or left lateral segment is removed from a parent or other adult live donor. After back table vascular reconstruction of the removed fragment, the complete left lobe or lateral segment is transplanted to the recipient in the orthotopic location. This procedure requires a high level of skill for both the donor and recipient operations. Apart from the technical problems, this tactic has raised the sensitive issue of live donation and its associated physical risks. Some have argued that it is virtually impossible to obtain informed consent, especially in cases of emergency in which the procedure would be most useful. To date, there have been no deaths after partial hepatectomy in these donors. Recipient survival has been comparable to that

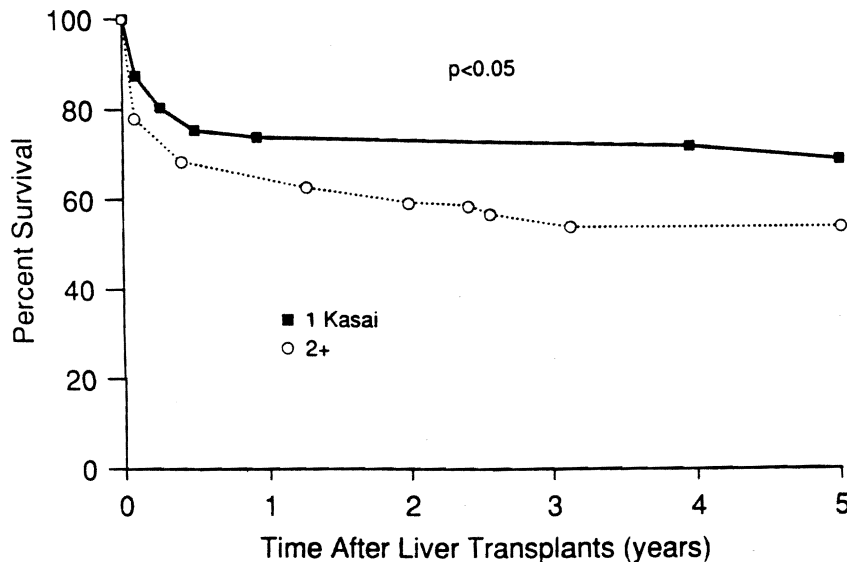


FIGURE 41-21. Survival in pediatric liver transplantation by number of previous Kasai's procedures.

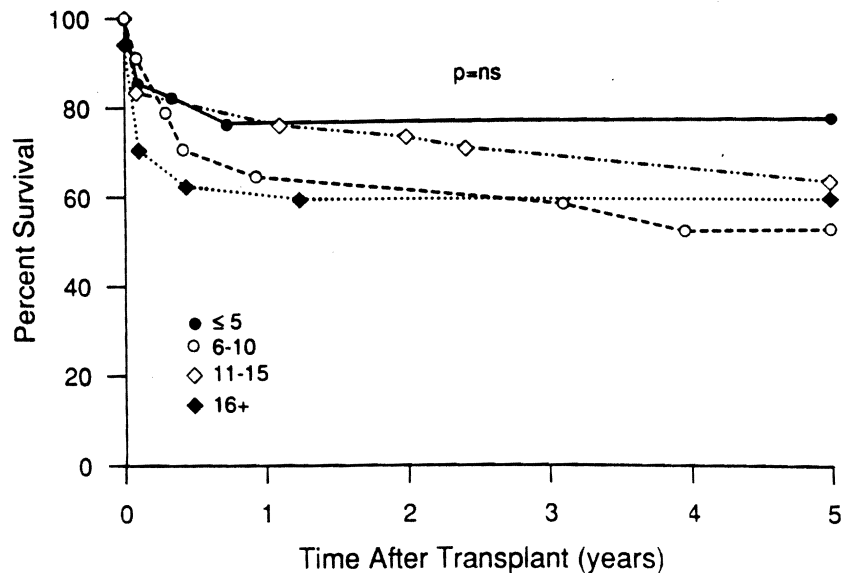


FIGURE 41-22. Survival in pediatric liver transplantation by bilirubin level (mg/dl).

of cadaveric liver transplantation. Experience has been limited to a few centers.

Donor Sharing

With the so-called split liver technique, one recipient, usually an adult, is given the right lobe of a cadaver liver and another, usually a child, is given the left lobe or lateral segment. The division is carried out on the back table where vascular reconstructions are usually required. Although promising, this technique has yielded inferior results for both members of the recipient pair.

Animal Organs

Liver heterotransplantation with chimpanzee donors was attempted three times, 18 or more years ago, with maximum survival of 9 days. The histopathologic findings at autopsy were not distinguishable from those in allografts at comparable times. No further attempts have been made utilizing modern immunosuppression, and they are not likely, because of the endangered status of chimpanzees and increasingly recognized human-like qualities. Whether the plentiful baboon with its seemingly more distant anthropomorphic separation might be more socially and ethically acceptable is a matter that has been, and will be, hotly debated, as exemplified by the outcry after earlier experience with baboon-to-human kidney heterotransplantation and the Baby Fae heart heterotransplantation.

Even granting the probability of baboon donor grafts, the current techniques of immunologic control probably are inadequate to permit the acceptance of such grafts. In all baboon organs transplanted so far, stigmata have been found of a delayed humoral rejection, which blocked the transplant blood supply after 7 to 60 days. This humoral antibody barrier becomes more extreme roughly in proportion to the degree of species

disparity, so that with widely divergent species (xenotransplantation) rejection occurs within a few minutes.

More than 25 years ago when dialysis was not available, Kuss of France, the pioneer transplant surgeon, attempted a pig-to-human renal transplantation. The kidney functioned well with azathioprine and prednisone immunosuppression but underwent hyperacute rejection. The dominant finding was the widespread thrombosis of the microvasculature, concentrated in the venules. Kuss' willingness to share this experience almost 3 decades later was important, because the pig has been suggested as a possible organ source for humans. It would be difficult today to acquire the kind of vitally needed information about the vigor and nature of pig xenograft rejection in humans, which Kuss obtained under different circumstances at an earlier time.

ANNOTATED READINGS

- Belzer FO, Southard JH: Principles of solid-organ preservation by cold storage. *Transplantation* 45:673-676, 1988. This is an outline of the principles of static preservation that led to the development of the UW solution.
- Bismuth H, Houssin D: Reduced-sized orthotopic liver graft in hepatic transplantation in children. *Surgery* 95:367, 1984. The first description of the reduced-size liver transplantation by the eminent French surgical team.
- Broelsch CE, Emond JC, Whittington TF, et al.: Application of reduced-size liver transplants as split grafts, auxiliary orthotopic grafts, and living related segmental transplants. *Ann Surg* 212:368-377, 1990. An updated account of the technique and personal experience using most of the known variations of the reduced-size liver transplantation, which the senior author popularized. A special feature is the description of the living donor transplantation.
- Calne RY (Editor). *Liver Transplantation: The Cambridge-King's College Hospital Experience*, second edition. Grune & Stratton, Orlando, volume 20, 1987. An account of the development and state of the art of liver transplantation by one of the most innovative surgeons in organ transplantation.

- Letourneau JG, Day DL, Asher NL: *Radiology of Organ Transplantation*. Mosby, St. Louis, MO, 1990. This is a look at liver transplantation from the perspective of the radiologists whose technologies and services have proved to be essential for optimal management.
- Macleod AM, Thomson AW: FK 506: An immunosuppressant for the 1990's? *Lancet* 337:25-27, 1991. A review of the basic biology of FK 506, its influence on cell-mediated immunity, and its potential future role in transplantation.
- Starzl TE, Demetris AJ: *Liver Transplantation*. Year Book Medical Publishers, Chicago, 1990. This book is a comprehensive report on liver transplantation with extensive literature citations on all points discussed in this chapter. For an earlier summary of the world literature through early 1969, the reader is referred to Starzl TE, Putnam CW: *Experience in Hepatic Transplantation*. WB Saunders Co, Philadelphia, 1969. Finally, the concept of hepatotropic factors and their relevance to auxiliary liver transplantation is reviewed in Starzl TE, Porter KA, Francavilla A: The Eck fistula in animals and humans. *Curr Probl Surg* 20:687-752, 1983.
- Williams JW (Editor): *Hepatic Transplantation*. WB Saunders, Philadelphia, pp. 1-245, 1990. A current account from the surgeon who established the second successful clinical program of liver transplantation in the United States and introduced innovative management techniques.