

Procurement of Liver Allografts From Non-Heart Beating Donors

K. Yanaga, S. Kakizoe, T. Ikeda, L.G. Podesta, A.J. Demetris, and T.E. Starzl

THE shortage of liver allografts continues to be a major limiting factor for the exploitation of liver transplantation. Although satisfactory function of allografts obtained from non-heart beating donors has been reported in kidneys¹ and livers,^{2,3} hepatic allografts have been procured almost exclusively from heart-beating donors.^{4,5} The purpose of this study was to determine the safety of liver allografts obtained from non-heart beating donors, and to evaluate the significance of histologic findings of these grafts.

MATERIALS AND METHODS

In a 14-month period between October 22, 1987, and December 31, 1988, 590 liver grafts were transplanted. All grafts were preserved by cold storage in University of Wisconsin (UW) solution. Seven of these grafts (1.2%) were procured from non-heart beating donors; five of these were procured during cardiopulmonary resuscitation. A rapid flush technique⁶ was used for quick cooling. Transplantation was performed with the use of standard techniques. Posttransplant immunosuppression consisted of CyA/steroids or CyA/azathioprine/steroids therapy. Severe allograft rejection was treated with Orthoclone OKT3 (Ortho Pharmaceutical Co, Raritan, NJ).

Procurement records were reviewed from the 7 non-heart beating donors. High-dose vasopressor support was defined as requirement of dopamine over 5 $\mu\text{g}/\text{kg}/\text{min}$ or an additional alpha-stimulatory agent to maintain stable hemodynamics of the donor. Diabetes insipidus was defined by the presence of polyuria as defined by the hourly urine output of over 5 ml/kg/h or the necessity to administer vasopressin to reduce massive urine output.

Liver biopsy specimens obtained from these 7 allografts prior to implantation (pretransplant biopsy) were obtained with a Trucut biopsy needle (Travenol Laboratories, Inc, Deerfield, IL). Additional biopsy specimens were taken before the abdominal closure (postreperfusion biopsy) in 2 grafts, and during a follow-up period in another 2. In 1 case, histologic findings were reviewed in a failed liver allograft which was removed. All biopsy specimens and routine sections of the failed allograft were fixed with 10% buffered formalin and stained with hematoxylin and eosin. For the postoperative follow-up, biopsy specimens and sections of the failed allograft were also stained with Masson trichrome and PAS diastase.

RESULTS

Table 1 lists donor data prior to organ recovery. All donors were young, with ages ranging from 16 months to 35 years (mean, 18.9 years). All but 1 were male. In 4 donors (Cases 1, 3, 5, and 6), cardiac arrest developed immediately prior to the initiation of the organ procurement, whereas Case 4 arrested immediately after median sternotomy and Case 2 developed ventricular fibrillation during preliminary dissection of the hepatic hilum. In Case 7, ventilatory support

was discontinued for irreversible brain damage with spinal cord palsy below C2 level, and the organs were procured immediately following cardiac standstill.

The donors were hospitalized for 1 to 7 days (mean, 2.9 days) and all but 1 were on high-dose vasopressor support (Cases 1-6). Hypokalemia and diabetes insipidus were present in all. Case 1 had diabetic ketoacidosis. Serum sodium level was abnormal in 3 (Cases 1, 2, 4), while adult respiratory distress syndrome was present in another 3 (Cases 2, 3, and 5). Two donors (Cases 2 and 4) underwent open cardiac massage, whereas 4 others (Cases 1, 3, 5, and 6) received closed followed by open cardiac massage. In Case 7, no massage was given. Heartbeat was restored in 2 donors (Cases 1 and 3). Factors contributing to the development of cardiac arrest consisted of hypokalemia in all, various changes associated with transfer of the donor from the intensive care unit to the operating room in 5 (Cases 1, 3-6), adult respiratory distress syndrome in 3 (Case 2, 3, and 5), diabetic ketoacidosis in 1 (Case 1), and cardiac catheterization in a hemodynamic unstable donor in 1 (Case 4).

Table 2 demonstrates clinical data pertinent to recipients who received liver allografts from the non-heart beating donors. Cold ischemia time ranged from 356 to 1,262 minutes (mean, 689 minutes). Blood loss during orthotopic liver transplantation varied from 2 to 53 units; Case 6 died of a massive blood loss due to perforation of the left renal vein while creating a retropancreatic tunnel for an aortohepatic interposition graft. Fibrinolysis was encountered in two; moderate in one and mild in another.

Postoperatively, liver function in two grafts (Case 2 and 3) exhibited a liver injury pattern with high SGOT and SGPT values. Case 3, however, demonstrated adequate synthetic function with a highest prothrombin time of 18.9 seconds. On the other hand, Case 2 went on to develop graft nonfunction, and had an emergency arteriogram for absent hepatic arterial doppler pulse that demonstrated a severe stenosis at the origin of the celiac axis with a sluggish flow through the hepatic artery. The hepatic artery was reconstructed the next day by obtaining an

From the Department of Surgery and Pathology, University Health Center of Pittsburgh, University of Pittsburgh, and the Veterans Administration Medical Center, Pittsburgh, PA.

Supported by Research Grants from the Veterans Administration and Project Grant No. AM 29961 from the National Institute of Health, Bethesda, MD.

Reprint requests should be sent to T.E. Starzl, MD, PhD, Department of Surgery, University of Pittsburgh School of Medicine, Falk Clinic 5C, 3601 Fifth Ave, Pittsburgh, PA 15213.

© 1990 by Appleton & Lange
0041-1345/90/\$3.00/+0

Table 1. Characteristics of Non-Heart Beating Donors

Case No.	Age (yr)/Sex	Days in ICU	High-Dose Vaso-pressor(s)	Other Pertinent Data	Duration of CPR (min)	Factors for Arrest
1	14/M	2	Yes	pH 7.08, K 1.6 Na 118, BS 1,078	12	Hypokalemia, ketoacidosis, transfer*
2	20/M	7	Yes	Po ₂ 63 (F _i O ₂ 0.8) K 1.7, Na 167 BS 636	15	Hypokalemia, ARDS
3	28/M	3	Yes	K 2.1	30	Hypokalemia, ARDS, transfer*
4	35/M	4	Yes	K 2.9, Na 160	21	Cardiac catheterization, transfer†
5	14/M	1	Yes	Po ₂ 63 (F _i O ₂ 1.0) K 2.6	13	ARDS, hemodynamic instability, transfer*
6	20/M	1	Yes	K 1.6	22	Hypokalemia, massive urinary loss, transfer*
7	16 mo/F	2	No	K 3.2	7‡	Apnea* (off respirator)

Abbreviations: ICU, intensive care unit; CPR, cardiopulmonary resuscitation; K, serum potassium (mEq/L); Na, serum sodium (mEq/L); BS, blood sugar (mg/dl); ARDS, acute respiratory distress syndrome.

*Donor arrested prior to procurement.

†Donor arrested during procurement.

‡Discontinuation of a respirator to cardiac standstill.

inflow from the infrarenal aorta; this failed to improve allograft function. The left kidney from the donor of the failed graft was transplanted after 24 hours of cold storage and exhibited immediate function. The patient underwent retransplantation on posttransplant day 4.

The histologic findings of the allografts from non-heart beating donors were not alarming. Case 2 exhibited a mild sinusoidal neutrophilia and moderate centrilobular steatosis on pretransplant biopsy (Fig 1a), findings that appeared worse in the postreperfusion biopsy. The right lobe of the failed allograft was infarcted, which was attributed to thrombosis of the right branch of the hepatic artery. The uninfarcted parts of the liver showed severe ischemic damage (Fig 1b). Case 4 demonstrated moderate sinusoidal neutrophilia pretransplantation (Fig 2a), and the postreperfusion and follow-up biopsy on posttransplant day 21 exhibited changes of moderate ischemic damage (Fig 2b). Pretransplant biopsies from Cases 1, 3, 5, and 6 showed mild sinusoidal neutrophilia, hepatocellular swelling, and/or microvesicular steatosis, findings commonly seen in pretransplant biopsies from organs that function normally

after transplantation. In other grafts, no pathologic changes were demonstrated on pretransplant biopsies.

Overall, five grafts (83%) demonstrated immediate function, while another, with poor arterial perfusion, failed to function.

DISCUSSION

When liver transplantation was first performed in humans, non-heart beating donors were used exclusively,⁷⁻⁹ and techniques were developed to quickly cool the liver following cardiac arrest.^{2,8} When warm ischemia was prolonged, fibrinolysis and exsanguinating hemorrhage followed revascularization of what proved to be necrotic organs.^{2,8,9} Nevertheless, most of the livers from this era functioned well despite the suboptimal conditions of procurement.

After the acceptance of brain death in the United States in 1968, almost all livers have been removed with an effective circulation. However, the possibility of swift removal of livers after cardiac arrest was reintroduced in

Table 2. Clinical Data of Recipients Who Received Liver Allografts From Non-Heart Beating Donors

Case No.	Age/Sex	CIT (min)	Anastomosis Time (min)	Blood Loss (U)	Fibrinolysis	Postoperative Data		Outcome
						SGOT/SGPT (IU/L)	PT (sec)	
1	40/M	390	37	2	None	237/229	16.3	D/C (24), A/W
2	46/M	1,262	40	15	Moderate	3,979/2,940	24.7	AHIG for arterial insufficiency (3), retransplanted* (4)
3	41/M	356	50	10	None	5,568/1,851	18.9	D/C (29), A/W
4	39/M	780	49	5	None	948/2,400	18.6	D/C (30), A/W
5	72/F	712	52	15	None	325/152	16.8	D/C (49), A/W
6	20/M	782	62	53	Mild	—/—	—	Died of technical failure in OR
7	5/F	540	45	2	None	630/258	18.9	D/C (50), A/W

NOTE. Numbers in parentheses designate number of posttransplant days.

Abbreviations: CIT, cold ischemia time; PT, prothrombin time (control, 11.8 seconds); D/C, discharged; A/W, alive and well; OR, operating room; AHIG, aorto-hepatic interposition graft.

*A kidney from the same donor demonstrated immediate function.

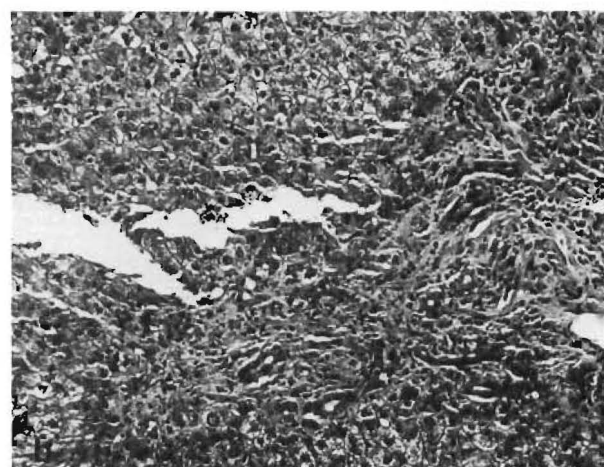
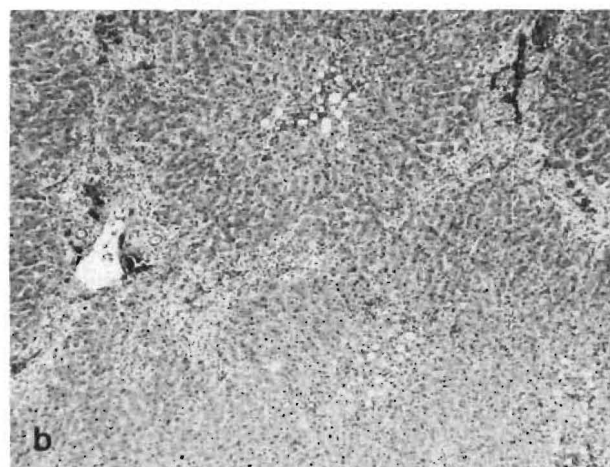
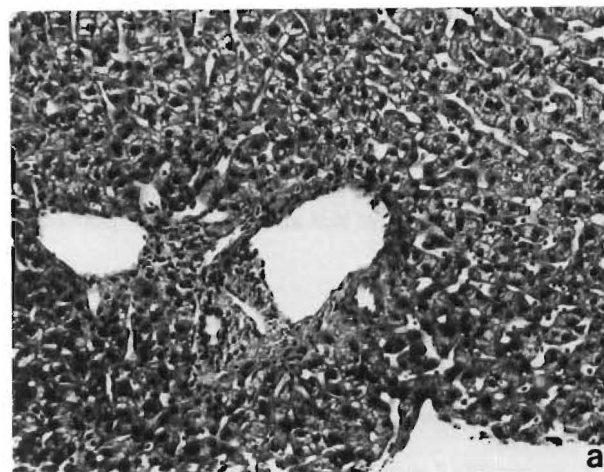
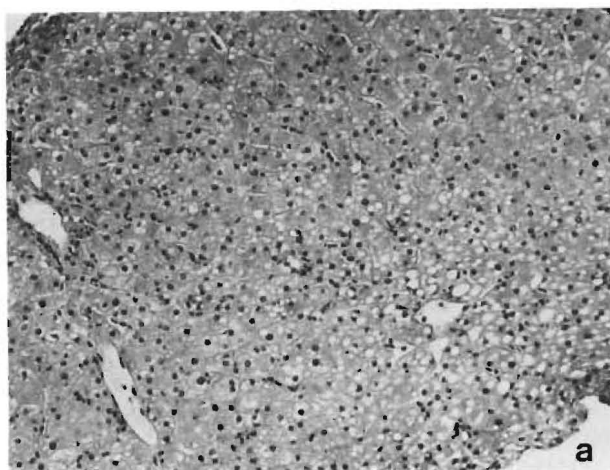


Fig 1. (A) Photomicrographic view of a pretransplant biopsy specimen from case no. 2. Mild neutrophilic infiltrate in the sinusoids and moderate macrovesicular and microvesicular steatosis are present. (Hematoxylin and eosin stain; original magnification $\times 100$.) **(B)** Photomicrographic view of the failed allograft (posttransplant day 4). Mixed inflammatory cell infiltrate, centrilobular macrovesicular and microvesicular steatosis, and portal-to-portal bridging necrosis are observed. (Hematoxylin and eosin stain; magnification $\times 40$.)

Fig 2. (A) Photomicrographic view of a pretransplant biopsy specimen from case no. 4. Moderate inflammatory cell infiltrate of the sinusoids predominantly by neutrophils and lymphocytes is demonstrated. (Hematoxylin and eosin stain; original magnification $\times 100$.) **(B)** Photomicrographic view of a percutaneous liver biopsy specimen from case no. 4 (posttransplant day 21). Marked cholangiolar proliferation and fibrous expansion of the portal tracts are present. (Hematoxylin and eosin stain; original magnification $\times 100$.)

1984 after demonstration of effective cooling with an aortic infusion technique.¹⁰ With this technique, or with its modification,⁶ it was possible in Sweden to systematically obtain good livers from non-heart beating cadavers before the implementation of a brain death law.³ In the Swedish experience between November 1984 and December 1987, only 1 (6%) of 17 liver allografts procured with these "rapid" techniques developed primary nonfunction, and 13 (77%) were functional 1 month following transplantation. A peak SGPT value of these grafts was not any higher than would be expected from heart-beating donors.

In our recent experience, as reported here, all but 1 live allograft functioned well. The liver in Case 2 required

replacement, presumably because of a combination of ischemia to the graft plus arterial insufficiency due to a celiac axis stenosis.

Since liver allografts are safely preserved cold up to 24 hours in UW solution,¹¹ there is time to obtain a frozen section liver biopsy. This is particularly important for a hepatic allograft from a donor who may have been suspected of excessive alcohol use or other activities that could contribute to liver disease. Although pretransplant biopsy cannot predict the extent of preservation injury on the postoperative clinical outcome, it is at least possible with the biopsy to rule out preexisting disease and to determine an acceptable histologic starting point.

The histologic findings reported here demonstrated no

apparent hepatocellular damage in any of the cases. Recent evidence has demonstrated that the liver is far less sensitive to warm ischemia than had been believed.^{12,13} Fifteen to 30 minutes of cardiac arrest should be compatible with an effective procurement of a liver allograft in many cases, particularly if efforts at cardiac massage have been made. Such livers undoubtedly constitute a somewhat increased risk, but this may be less than previously believed.

REFERENCES

1. Ruers TJM, Vroemen JPAM, Kootstra G: *Transplant Proc* 18:408, 1986
2. Starzl TE, Groth CG, Brettschneider L, et al: *Ann Surg* 168:392, 1968
3. Ericzon BG, Lundgren G, Wilczek H, et al: *Transplant Proc* 19:3862, 1987
4. Starzl TE, Demetris AJ, Van Thiel D: *N Engl J Med* (in press)
5. Calne RY (ed): *Liver Transplantation: The Cambridge—King's College Hospital Experience* (ed 2). Philadelphia, W.B. Saunders, 1987, p 1
6. Starzl TE, Miller C, Broznick B, et al: *Surg Gynecol Obstet* 165:343, 1987
7. Starzl TE, Marchioro TL, Von Kaulla KN, et al: *Surg Gynecol Obstet* 117:659, 1963
8. Starzl TE: *In experience in Hepatic Transplantation*. Philadelphia, Saunders, 1969, pp 16, 41, 58, 65, 159
9. Calne RY, Williams R: *Br Med J* 4:535, 1968
10. Starzl TE, Iwatsuki S, Shaw BW Jr, et al: *Transplant Proc* 17:250, 1985
11. Todo S, Nery J, Yanaga K, et al: *JAMA* 261:711, 1989
12. Huguet C, Nordlinger B, Bloch P, et al: *Arch Surg* 113:1448, 1978
13. Delva E, Camus Y, Nordlinger B, et al: *Ann Surg* 209:211, 1989