

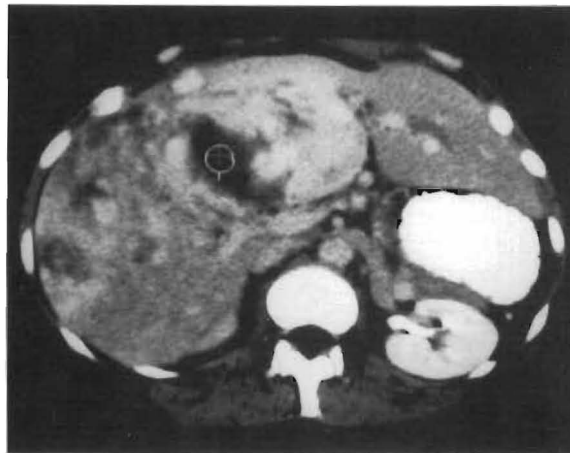
# Current Problems in Surgery®

## The Changing Face of Hepatic Resection

Shunzaburo Iwatsuki, M.D.

Daniel G. Sheahan, M.B., M.Sc.


Thomas E. Starzl, M.D., Ph.D.



Editor-in-Chief: **Samuel A. Wells, Jr.**

Editorial Board: **W. Gerald Austen, Eric W. Fonkalsrud,**

**Hiram C. Polk, Jr., H. William Scott, Jr., Fellicien M. Stelchen**

 Year Book  
Medical Publishers, Inc.

# Current Problems in Surgery®

**SAMUEL A. WELLS, Jr., M.D.**, Editor-in-Chief  
Professor and Chairman  
Department of Surgery  
Washington University  
School of Medicine  
St. Louis

## EDITORIAL BOARD

**W. GERALD AUSTEN, M.D.**  
Chief of the Surgical Services  
Massachusetts General Hospital  
Boston

**HIRAM C. POLK, Jr., M.D.**  
Professor and Chairman  
Department of Surgery  
University of Louisville  
Louisville

**ERIC W. FONKALSRUD, M.D.**  
Professor and Chief of Pediatric Surgery  
University of California  
School of Medicine  
Los Angeles

**H. WILLIAM SCOTT, Jr., M.D.**  
Professor of Surgery, Emeritus  
Vanderbilt University  
School of Medicine  
Nashville

**FELICIEN M. STEICHEN, M.D.**  
Professor of Surgery  
New York Medical College  
New York

---

## PUBLISHER'S STAFF

Editorial Director: Nancy E. Chorpensing  
Managing Editor: Craig A. Pugh  
Sponsoring Editors: Julie M. Jewell; James F. Shanahan  
Assistant Director, Manuscript Services: Frances M. Perveiler  
Associate Managing Editor: Denise Dungey  
Editorial Assistant, Serial Products: Lisa Claxton Moore  
Senior Project Manager: Nancy C. Baker  
Proofroom Manager: Shirley E. Taylor  
Assistant Product Manager: Susan Martinsen  
Special Sales Manager: Steve Wall  
Vice President, Operations: James D. Bondy

---

**Year Book Medical Publishers, Inc.**  
200 N. LaSalle St.  
Chicago, Illinois 60601

**CUSTOMER SERVICE: 1-800-621-9262**

# **THE CHANGING FACE OF HEPATIC RESECTION**

**Shunzaburo Iwatsuki,  
M.D.**

Department of Surgery  
University of Pittsburgh School of  
Medicine  
Pittsburgh, Pennsylvania

**Daniel G. Sheahan, M.B.,  
M.Sc.**

Department of Pathology  
University of Pittsburgh School of  
Medicine  
Pittsburgh, Pennsylvania

**Thomas E. Starzl, M.D.,  
Ph.D.**

Department of Surgery  
University of Pittsburgh School of  
Medicine  
Pittsburgh, Pennsylvania

Current Problems in Surgery (ISSN 0011-3840) is published monthly by Year Book Medical Publishers, Inc., 200 N. LaSalle St., Chicago, IL 60601. Prices for 12 issues are: U.S. individuals \$57.95, institutions \$78.50, medical student or resident physicians \$34.95. (Prices quoted are in U.S. dollars. Canadian orders will be billed in Canadian funds at the approximate current exchange rate. A small additional charge will be made for postage and handling.) FOREIGN: please refer below for the distributor in your area. Single issue price is \$13.95. Second-class postage paid at Chicago, IL and additional mailing offices. POSTMASTER: Send address changes to Current Problems in Surgery, Year Book Medical Publishers, Inc., 200 N. LaSalle St., Chicago, IL 60601.

---

COPYRIGHT © 1989 BY YEAR BOOK MEDICAL PUBLISHERS, INC.

All rights reserved. No part of this publication may be reproduced, stored in a retrieval system, or transmitted, in any form or by any means—electronic, mechanical, photocopying, recording, or otherwise—without prior written permission from the publisher except in cases described below.

The code at the bottom of the first page in this issue indicates the publisher's consent that copies of the article may be made for personal or internal use. This consent is given on the condition that the copier pay the stated per-copy fee through the Copyright Clearance Center, Inc. (Operations Office, 27 Congress Street, Salem, MA 01970) for copying beyond that permitted by Sections 107 or 108 of the United States Copyright Law. This consent does not extend to other kinds of copying, such as copying for general distribution, for advertising or promotional purposes, for creating new collected works, or for resale.

For your convenience, all inquiries regarding journal subscription, including claims and payments, should be addressed to:

In the U.S.A. and Canada:

YEAR BOOK MEDICAL PUBLISHERS  
200 N. LaSalle St.  
Chicago, Illinois 60601  
1-800-621-9262

In Japan:

NANKODO COMPANY, LTD.  
42-6 Hongo, 3-chome  
Bunkyo-ku  
Tokyo 113  
Japan

Worldwide excluding U.S.A., Canada, Japan, India,  
and Australia:

SWETS PUBLISHING SERVICE  
Heereweg 347b  
2161 CA Lisse  
The Netherlands

In India:

UNIVERSAL SUBSCRIPTION AGENCY  
101-102, Community Center, Saket  
New Delhi - 11017  
India

In Australia:

BLACKWELL SCIENTIFIC PUBLICATIONS  
107 Barry Street  
Carlton, VIC 3053  
Australia

**Current Problems in Surgery** is listed in *Index Medicus*, *Current Contents (CC)*, *ISI/BioMed*, and the *SCI*.



## **FOREWORD**

The surgical therapy of primary and secondary hepatic neoplasms has changed markedly over the last 30 years, from a time when partial hepatectomy was a relatively rare operation to the modern era when total hepatectomy and liver transplantation are being practiced in many medical centers. The members of the Starzl group, first in Denver and subsequently in Pittsburgh, have played a dominant role in developing the surgical techniques that have made this possible. In this issue of *Current Problems in Surgery*, Drs. Iwatsuki, Sheahan, and Starzl describe their experience to date with almost 500 patients whose liver tumors have been treated by aggressive hepatectomy. Their careful review of the surgical anatomy of the liver, their clear, detailed descriptions of the various hepatic resections, and the résumé of their clinical experience and excellent results represent an excellent overview of the field by the clinical investigators who have been primarily responsible for its establishment.

Samuel A. Wells, Jr., M.D.  
Editor-in-Chief




## CONTENTS

Foreword	283	
Surgical Anatomy	289	
Hepatic Artery	292	
Portal Vein	294	
Bile Duct	295	
Hepatic Vein	296	
Caudate Lobe	296	
Lobar and Segmental Hepatic Resection	297	
Subsegmental and Local Excisional Resections	299	
Milestones of Hepatic Resection	299	
Our Techniques of Hepatic Resection	300	
Incision and Exposure	300	
Right-Sided Hepatic Resections	301	
Left-Sided Hepatic Resection	312	
Before Closure	316	
Surgical Pathology	319	
Diagnostic Considerations	319	
Needle Biopsy and Fine Needle Aspiration Biopsy	319	
Frozen Section Diagnosis	320	
Benign Lesions	320	
Malignant Lesions	330	
Sarcomas	343	
Our Experience With Hepatic Resection	349	
Case Material	349	
Postoperative Mortality	350	
Postoperative Complications	354	
Hepatic Resection for Benign Lesions	355	
Giant Cavernous Hemangioma	356	
Liver Cell Adenoma (Adenoma)	360	
Focal Nodular Hyperplasia	362	
Congenital Cysts	362	
Hydatid Cysts	364	
Other Benign Hepatic Lesions	365	


<b>Hepatic Resection for Primary Hepatic Malignancy</b>	<b>365</b>
Survivals	366
Five-Year Survivors	367
<b>Hepatic Resection for Secondary Hepatic Malignancy</b>	<b>368</b>
Survivals	369
Five-Year Survivors	369
<b>The Changing Face of Hepatic Resection</b>	<b>370</b>
<b>References</b>	<b>372</b>



*Shunzaburo Iwatsuki, M.D., is Professor of Surgery at the University of Pittsburgh, School of Medicine. His clinical practice is at the Presbyterian-University Hospital and at the Children's Hospital of Pittsburgh. He took a fellowship under Dr. Thomas E. Starzl in Denver, and accompanied Dr. Starzl when he moved to Pittsburgh in 1981. Their collaboration has been for nearly 20 years. His interest has been in liver disease, including portal hypertension, hepatic resection, and liver transplantation. He was also trained as a hepatologist at the University of Southern California for 2 years under Drs. T.B. Reynolds and A.G. Redeker.*



*Daniel G. Sheahan, M.B., M.Sc., received his M.B., B.Ch., and B.A.O. from University College Dublin Medical School in 1959 and interned at St. Vincent's Hospital, Dublin. He joined the Department of Pathology of University College Dublin and obtained a postgraduate Masters (M.Sc.) degree in Pathology. He received residency training at the Mallory Institute of Pathology, Boston (1965-1968) and became Division Director of Department of Experimental Pathology at Walter Reed Army Institute of Research (1968-1971). He joined the Faculty of Pathology at Yale University School of Medicine from 1971-1978 as Assistant/Associate Professor, then at Trinity College Dublin, and is currently Professor of Pathology at the University of Pittsburgh and Associate Director of Laboratories/Chief of Surgical Pathology at Presbyterian University Hospital of Pittsburgh. Scientific interests have centered on the pathological histochemical and immunohistochemical aspects of gastrointestinal disease with emphasis on premalignant and malignant lesions of the digestive organs.*

Handwritten signature of Thomas E. Starzl in cursive script.

*Thomas E. Starzl, M.D., Ph.D., is a Distinguished Service Professor of Surgery at the University of Pittsburgh School of Medicine. Although he has made numerous contributions to our understanding of gastrointestinal physiology and pathophysiology, he is best known for his dominant role in developing the broad field of organ transplantation. His seminal work in liver surgery, especially his pioneering role in establishing liver transplantation as a standard clinical procedure, is of great importance. Surgeons from all over the world have come to train in his clinic and, through their own accomplishments, have broadened his substantial influence.*

# THE CHANGING FACE OF HEPATIC RESECTION

Although the first surgical removal of a portion of the human liver was recorded more than two centuries ago, the liver was regarded as a *noli me tangere* ("do not touch me") organ until the beginning of this century. This fear still exists in some degree even today. Until 10 to 15 years ago, the operative mortality with major hepatic resections was too great to justify their use if a less dangerous, even though unsatisfactory, alternative was available. This is no longer a supportable point of view in the 1980s. Major hepatic resections can now be performed quite safely, and indications for the operation have become far less restrictive for both malignant and benign hepatic lesions.

Increased numbers of hepatic mass-lesions are found today by advanced imaging technology, and physicians and surgeons are asked frequently for their best management. Our main concerns in this monograph are to summarize the essential surgical anatomy of the liver, the basic surgical pathology, and the techniques of hepatic resection. We also report our experience with excisional therapy for benign and malignant hepatic lesions over the last 25 years.

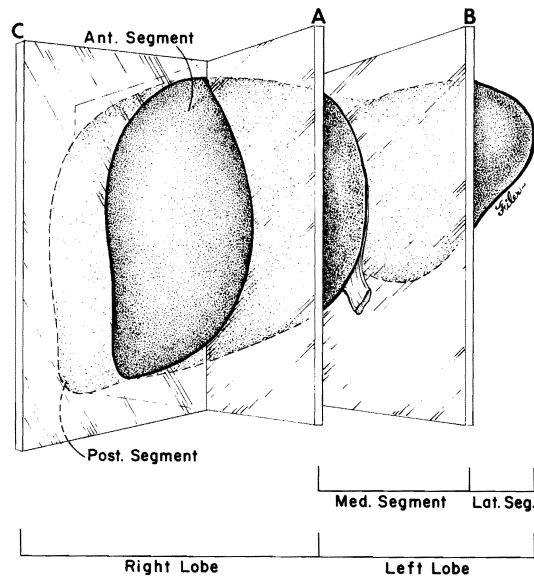
## SURGICAL ANATOMY

It is quite confusing when there are many different names for lobes and segments of the liver. For example, what is called "lobectomy" in Europe is often different in meaning from the same term in the United States of America. "Lobectomy" in the United States is equivalent to "hepatectomy" in Europe while "right lobectomy" in Europe is called "right trisegmentectomy" or "extended right lobectomy" in the United States, and "left lobectomy" in Europe is called "left lateral segmentectomy" in the United States. In Europe the liver is usually described as having eight segments, while it is most often divided into four segments in the United States. In Japan and other countries, European segments are called "subsegments" to avoid the confusion. So-called (used to be so-called) anatomical right and left

lobe are not "true" right and left lobes founded upon an embryologic or truly morphological basis.

A large portion of the liver that lies to the right side of the falciform ligament was mistaken as a right lobe for a long time. However, in 1898, Cantlie<sup>1</sup> and, in 1927, McIndoe and Counseller<sup>2</sup> reported that the division between the true right and left lobes of the liver was not at the falciform ligament as had previously been believed, but rather at a line passing through the bed of the gallbladder and projecting posteriorly toward the vena cava (known as Cantlie's line).

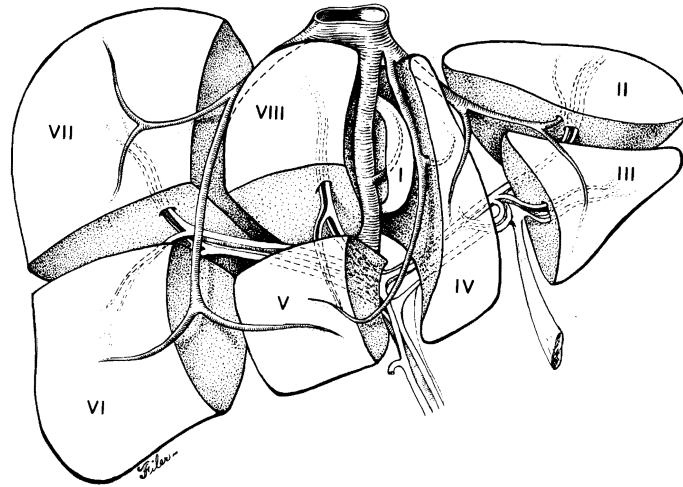
In the early 1950s Hjortsjo,<sup>3</sup> Elias and Petty,<sup>4</sup> and Healey and Schroy<sup>5,6</sup> demonstrated by casting studies of the liver that each true lobe was further divided into two segments: an anterior and a posterior segment of the right lobe, and a medial and lateral segment of the left lobe, and that the hepatic arterial, portal venous and biliary duct branches conformed to the four segments (Fig 1). These observations were confirmed and extended by Couinaud<sup>7</sup> and by Goldsmith and Woodburne.<sup>8</sup> Couinaud divided each of the four segments into two, resulting in a total of eight segments (subsegments)



**FIG 1.**

The liver is divided into the right and left lobes by a sagittal plane (A). The left lobe is further divided into the lateral and medial segments by another sagittal plane (B). The right lobe is divided into the anterior and posterior segments by a coronal plane (C).





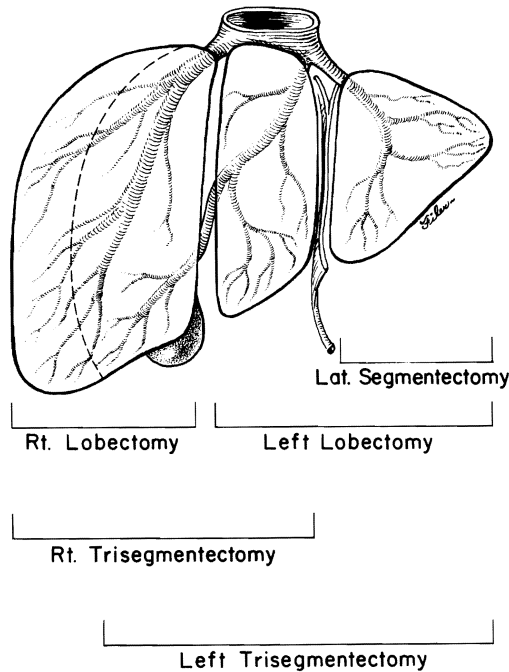
**FIG 2.**

Couinaud's eight hepatic segments (subsegments). The four segments shown in Figure 1 are each further divided into two subsegments, and each segment is numbered from I to VIII.

(Fig 2). The large hepatic venous branches are distributed differently since a number of their branches are between, rather than within, segments and lobes.

For practical purposes, there are only four surgical units that lend themselves to controlled excision: the anterior and posterior segments of the right lobe, and the medial and lateral segments of the left lobe (Fig 3). Each of the eight segments proposed by Couinaud (see Fig 2) is not considered as a surgical unit individually because divisions of most of his segments are ill defined, and resections of most of the anterior, posterior, and medial segments alone are not ordinarily necessary.

It is true, however, that the interest in subsegmental resection of small (less than 3 cm in diameter) hepatomas in cirrhotic livers has been growing in Asia and Europe, where these small tumors are frequently found in patients with cirrhosis during their regular screening with ultrasonography and serial determinations of serum  $\alpha$ -feto-protein. The segments of Couinaud can be marked by injection of contrast media or isotope into the subsegmental branches of the portal vein under ultrasonographic guidance.<sup>9-11</sup> The tumor-bearing subsegment is resected by an ultrasonic knife. Early occlusion of the portal venous branch is said to be important in preventing transportal dissemination of malignant cells.



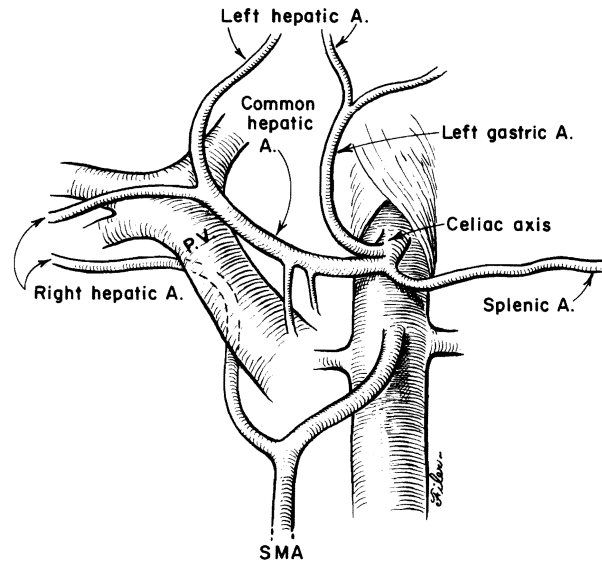
**FIG 3.**

For practical purposes, there are only four surgical units (segments), and five kinds of anatomical resections are commonly used.

#### *HEPATIC ARTERY*

Most commonly, the entire arterial supply to the liver is derived from the celiac axis. The celiac axis divides into the common hepatic, left gastric and splenic artery. The common hepatic artery, after giving off the gastroduodenal artery and the right gastric artery at the upper border of the first part of the duodenum, continues as the proper hepatic artery. The proper hepatic artery ascends within the hepatoduodenal ligament medial to the common bile duct and along the left anterior wall of the portal vein, and bifurcates into the right and left hepatic arteries. This bifurcation occurs at variable levels between the origin of the artery and the porta hepatis (Fig 4). In about 4% of cases, the common hepatic artery originates from the superior mesenteric artery.<sup>12, 13</sup>

The right hepatic artery usually runs behind the common hepatic duct and divides into the anterior and posterior segmental branches either before or after entering the hepatic parenchyma with the corresponding segmental bile ducts. Occasionally, the right hepatic ar-



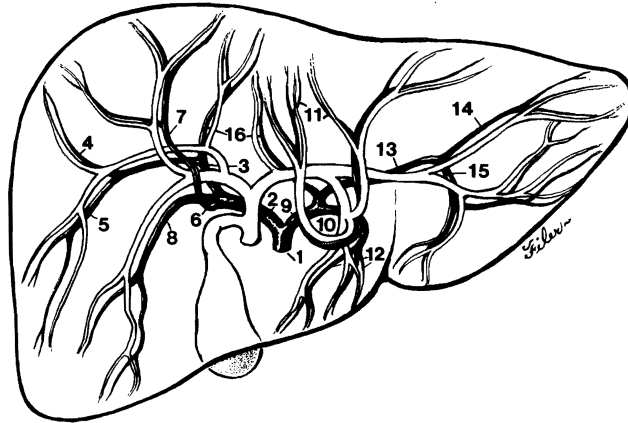
**FIG 4.**

Schematic drawing of common variations of hepatic arterial blood supply. A = artery, PV = portal vein, SMA = superior mesenteric artery.

tery passes in front of the bile duct. Often, the right hepatic artery or the posterior segmental branch of the artery arises from the superior mesenteric artery and courses posteriorly and to the right of the portal vein in the hepatoduodenal ligament (see Fig 4).

The cystic artery usually originates from the right hepatic artery and runs either in front of or behind the biliary duct system. Frequently the cystic artery arises from the anterior branch of the right hepatic artery. Double cystic arteries are found occasionally.

The left hepatic artery most commonly originates from the proper hepatic artery and branches off into the medial and lateral segments at the hepatic hilum. The lateral segmental artery divides into the superior and inferior branches at the base of the umbilical fissure (fissure between the medial and lateral segments of the left lobe). The medial segmental artery often arises from the inferior branch of the lateral segmental artery, and occasionally even from the anterior segmental branch of the right hepatic artery. The left gastric artery often gives off a branch to all or part of the left liver lobe. In this variation, the artery runs in the middle of the gastrohepatic ligament toward the umbilical fissure and is separate from the porta hepatis (Fig 5).



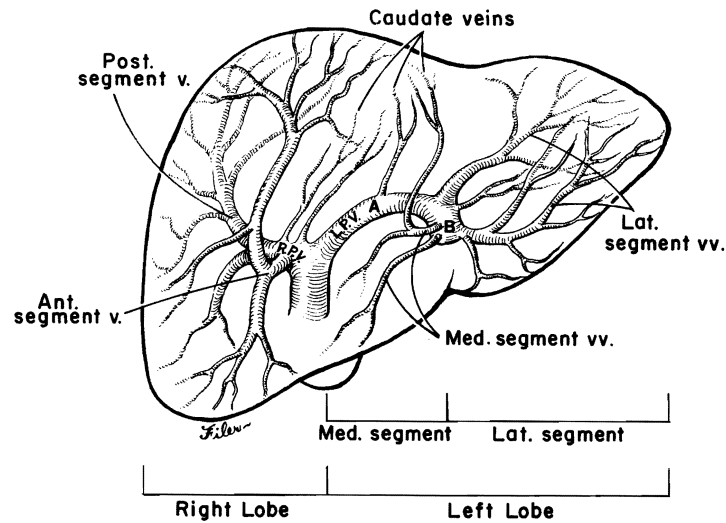
**FIG 5.**

Intrahepatic distribution of the hepatic arteries and bile ducts. (1) Common hepatic artery, (2) right hepatic artery, (3) posterior segmental artery, (4) superior posterior area artery, (5) inferior posterior area artery, (6) anterior segmental artery, (7) superior anterior area artery, (8) inferior anterior area artery, (9) left hepatic artery, (10) medial segmental artery, (11) superior medial area artery, (12) inferior medial area artery, (13) lateral segmental artery, (14) superior lateral area artery, (15) inferior lateral area artery, (16) arteries to the caudate lobe.

#### *PORTAL VEIN*

The portal vein is formed by a confluence of the splenic vein and superior mesenteric vein behind the pancreas. It passes from its origin behind the first part of the duodenum and then courses toward the porta hepatis in the hepatoduodenal ligament, in front of the foramen of Winslow. The course of the portal vein is quite uniform, although rarely it may run in front of the duodenum, especially when there is a complex of other anomalies including gut malrotation, absent retrohepatic inferior vena cava, and anomalous hepatic artery origin.<sup>14, 15</sup>

In the porta hepatis, the portal vein divides into the right branch, which is short and wide, and the left branch, which is longer and narrower. The branches of the hepatic artery and the bile duct maintain their anterior relationship to those of the portal vein. The right portal vein takes a very short course before it divides into the anterior and the posterior segmental vein, which further divides into the superior and the inferior branches (Fig 6). The left portal vein consists of two portions: the transverse portion (*pars transversus*), which runs at the base of the medial segment (*quadrate lobe*); and the umbilical portion (*pars umbilicus*), which curves forward as the continuation of the transverse part, lying in the umbilical fissure and



**FIG 6.**  
 Intrahepatic distribution of the portal vein: *RPV* = right portal vein, *LPV* = left portal vein, *A* = pars transversus, *B* = pars umbilicus.

ending anteriorly in an attachment to the round ligament (ligamentum teres hepatis). The superior and inferior branches of the lateral segment vein arise from the left side of the umbilical portion of the left portal vein, and the veins to the medial segment arise from the right side of this same vessel. Thus, the distribution of the left portal vein differs from that of the left hepatic artery and the bile duct (see Figs 5 and 6).

#### *BILE DUCT*

The common bile duct runs along the right margin of the hepatoduodenal ligament, anterior to the portal vein and, most often, to the right of the hepatic artery. The common hepatic duct which continues to run along the right anterolateral wall of the portal vein is the portion of the bile duct between the entry of the cystic duct and the bifurcation of the right and left bile ducts.

The cystic duct enters the bile duct at various levels, and it often joins the right hepatic duct. The right hepatic artery passes more often behind rather than in front of the common hepatic duct (see Fig 5).

The common hepatic duct may bifurcate at any level in the hepatoduodenal ligament, but its bifurcation is usually higher than that of the hepatic artery and of the portal vein, and often within the sub-

stance of the liver. The right hepatic duct is short, as is the right portal vein, and branches off into the anterior and posterior segmental ducts, maintaining the anterior position to the corresponding portal branches (see Fig 5). Occasionally, there is no union of the anterior and posterior segmental ducts, and therefore, no true right hepatic duct.

The left hepatic duct is longer than the right duct, and runs along the base of the medial segment into the umbilical fissure to become the lateral segmental duct (see Fig 5). The medial segmental duct most commonly enters the left hepatic duct at the right side of the umbilical fissure, but occasionally it drains into the inferior branch of the left lateral segmental duct. Nonunion of the medial and lateral segmental ducts is extremely rare.

#### *HEPATIC VEIN*

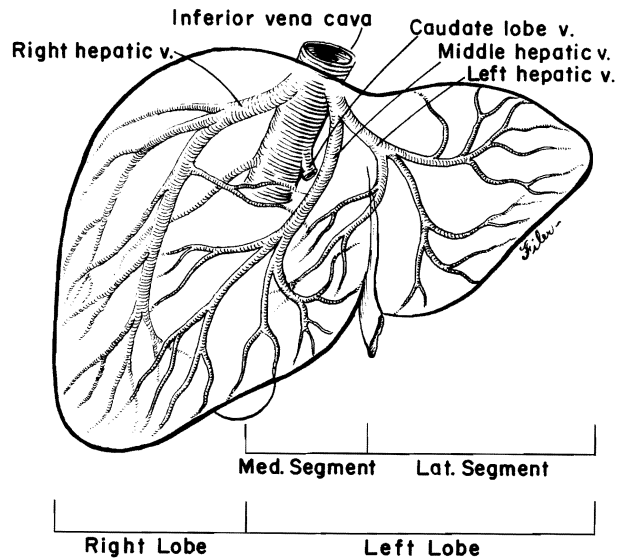
There are three major hepatic veins, which run predominantly in the intersegmental plane. The right hepatic vein passes between the anterior and posterior segments of the right lobe and drains into the right anterolateral ostium of the vena cava. The middle hepatic vein is the principal drainage for the medial segment of the left lobe, and its main branches are in the planes between the right and left lobes and between the medial and lateral segments of the left lobe. The terminal course of the middle hepatic vein usually is in the intersegmental plane between the medial and lateral segments of the left lobe where it may join the left hepatic vein (from the lateral segment) near the vena cava, or less commonly drain separately into the anterior ostium of the vena cava. The left hepatic vein drains into the left anterolateral ostium of the vena cava.

Besides these three major hepatic veins, there are several short hepatic veins draining directly from the posterior segment of the right lobe and from the caudate lobe into the vena cava (Fig 7) and irregularly from other parts of the posterior hepatic parenchyma.

#### *CAUDATE LOBE*

The medial segment of the left lobe is divided by the porta hepatis into the superior area (quadrate lobe) and inferior area (caudate lobe). The vascular and biliary branches of the caudate lobe are best described separately because this small area can be spared or removed in the lobectomy or trisegmentectomy, depending on the location of the hepatic lesion.

One of the most confusing anatomical designations is the so-called portion of the caudate lobe. The caudate lobe proper lies along the left side of the vena cava and extends to the fissure of the obliterated ductus venosus. A portion of the liver that lies in front of



**FIG 7.**  
Prevailing pattern of hepatic venous drainage.

the vena cava is the caudate process, and the right portion of the caudate lobe fuses with the posterior segment of the right lobe in the right side of the vena cava. The branches of the portal vein to the caudate lobe are usually two in number, one each arising from the right and left portal vein branch in the porta hepatis. Thus, the caudate lobe is actually part of both the true right and left lobes. Accordingly, arterial and biliary duct branches, usually two or three in number, originate from both right and left branches. There are usually a few short hepatic venous branches draining directly into the anterior and left walls of the vena cava.

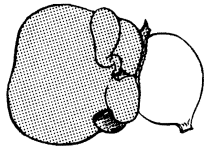
#### **LOBAR AND SEGMENTAL HEPATIC RESECTION**

Five lobar and/or segmental anatomical resections of the liver can be applied safely to various locations of hepatic lesions. They are right and left trisegmentectomy, right and left lobectomy, and left lateral segmentectomy (Fig 8). In Europe, the term "right hepatectomy" or "left hepatectomy" is used for the right lobectomy or left lobectomy of the liver. It is incorrect to call the right trisegmentectomy a right lobectomy, or to call a left lateral segmentectomy a left lobectomy.

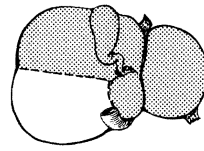
With right trisegmentectomy, the right lobe of the liver and the

---

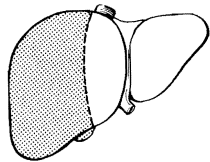
RT. TRISEGMENTECTOMY



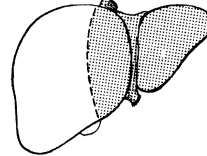
LT. TRISEGMENTECTOMY



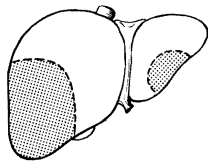
RIGHT LOBECTOMY



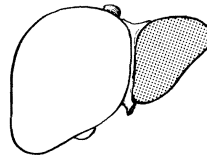
LEFT LOBECTOMY



NON-ANATOMICAL RESECTION



LT. LATERAL SEGMENTECTOMY



---

**FIG 8.**

Schematic drawings of five truly anatomical resections and a nonanatomical resection.

medial segment of the left lobe are removed, except that the left posterior portion of the caudate lobe (caudate lobe proper) may be removed or retained depending upon the location of the tumor. With left trisegmentectomy, the left lobe of the liver and the anterior segment of the right lobe are removed, but the caudate lobe proper may be resected or retained, as with right trisegmentectomy, depending upon the location of the tumor.

The term "extended right lobectomy" usually refers to a right trisegmentectomy. However, it may also refer to a slight modification of right lobectomy in which the hepatic parenchyma is transected well to the right of the falciform ligament rather than at this ligament,



thus sparing most of the medial segment. Extended right lobectomy with the latter meaning is a nonanatomical resection, which does not differ from the right lobectomy in preparation for actual hepatic parenchymal transection, as is described in a later section. The same is true for the so-called extended left lobectomy, which should not be confused with the left trisegmentectomy since it does not result in removal of the full anterior segment of the right lobe. Therefore, extended right and left lobectomy are classified as right and left lobectomy in the analysis for this text of our cases. The categories of hepatic resections in this text are shown in Figure 8 and consist of the five formal resections just delineated plus "nonanatomical" or local excisions.

### **SUBSEGMENTAL AND LOCAL EXCISIONAL RESECTIONS**

In Japan, Italy, and France, there has been a wave of enthusiasm for smaller resections in patients whose livers are cirrhotic.<sup>9-11, 16-20</sup> Any of the four principal segments can be removed, and for that matter so can the subsegments (the segments of Couinaud). Accurate delineation of the region to be excised has been facilitated by intraoperative ultrasonography,<sup>9-11</sup> and by the injection of dyes into the portal or arterial blood supply. Many of the excisions classified by us as "local" were resections of this kind. However, we have not used these resections in cirrhotic patients sufficiently to warrant personal opinions about their value. The reader is referred to more authoritative sources.<sup>9-11, 16-20</sup>

The term "local" can be misleading. Some of the largest masses removed by us were either along nonanatomical lines, or could be removed with segments or subsegments only.

### **MILESTONES OF HEPATIC RESECTION**

Although many hepatic resections had been carried out successfully before the turn of this century, these should rather be considered as uncontrolled amputations of hepatic lesions<sup>21, 22</sup> inasmuch as the precise anatomy of the liver was not well known until the middle of the 20th century. Wendel<sup>23</sup> has been credited with the first successful right lobectomy in 1911. He was convinced that his success was due to early ligation of the right hepatic artery and the biliary duct and covering of the cut hepatic surface with the gallbladder. He preserved the cystic artery and duct. Although Keen<sup>22</sup> or Abel<sup>24</sup> had been said to be the first surgeons to carry out left lobectomy, their operations were not true left lobectomies, but rather left lateral segmentectomies (removal of the liver left of the falciform ligament). We are not certain who performed the first true left lobectomy.

On the other hand, the record is clear that Lortat-Jacob and Robert first described right trisegmentectomy (removal of the liver to the right of the falciform ligament) in any detail.<sup>25</sup> Wangenstein<sup>26</sup> may have actually done this operation earlier, and Quattlebaum<sup>27</sup> was the first to describe the operation in the English literature. The operation became known as extended right lobectomy, and included partial removal of the quadrate and caudate lobes. Enthusiasm for this operation apparently was dampened by a high mortality reported by Bruhschwig<sup>28</sup> and others.<sup>29</sup> The procedure was virtually abandoned until subsequent refinements of the operative techniques and documentation of the safety of the operation.<sup>30, 31</sup>

The most recently described anatomic hepatic resection is left trisegmentectomy or a complete removal of the anterior segment of the right lobe along with the true left lobe. This operation was performed for the first time in 1980 and reported with three additional cases in 1982.<sup>32</sup>

At least two other great milestones of hepatic resection cannot be neglected. One is that of Raven,<sup>33</sup> and another is that of Pringle.<sup>34</sup> Although Wendel<sup>23</sup> had recommended the early ligation of the right hepatic artery and bile duct in 1911, Raven<sup>33</sup> was the first to describe the systematic ligation of the hepatic hilar structures in his 1949 report.

The Pringle maneuver for controlling hemorrhage from the liver during surgery is well known and widely practiced. Huguet and associates<sup>35</sup> documented that the human liver can tolerate total occlusion of hepatic blood inflow for over an hour. Todo and associates<sup>36</sup> showed with an ingenious experimental model that dogs can tolerate total warm ischemia of the liver for up to 3 hours.

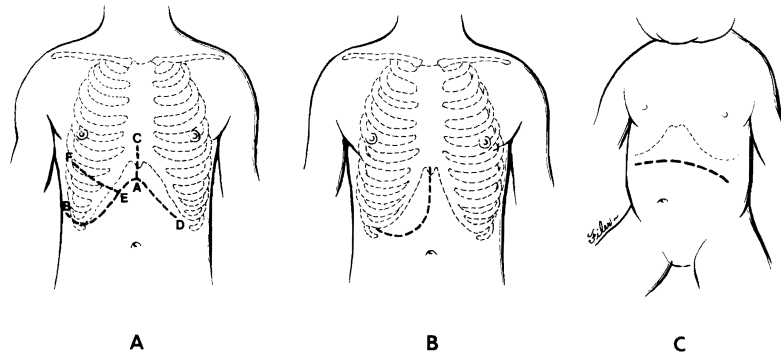
Recent advances in medicine such as the development of modern anesthesia, safe blood transfusion, countless effective antibiotics, and sophisticated technology in diagnosis and monitoring have contributed to the rapid progress in hepatic surgery of today.

Finally, total hepatectomy with replacement (orthotopic liver transplantation) has evolved from experimental to practical therapy in recent years.<sup>37-39</sup>

## **OUR TECHNIQUES OF HEPATIC RESECTION**

### *INCISION AND EXPOSURE*

All-purpose incisions for hepatic surgery are shown in Figure 9. The basic incision is a bilateral subcostal incision to which an upper midline extension usually is added (see Fig 9). The right side of the subcostal incision (points A-B) usually is longer than the left side (points A-D). If the upper midline extension (A-C) includes complete removal of the xiphoid process, exposure of the suprahepatic



**FIG 9.**  
Commonly used incisions for hepatic resection.

abdominal vena cava and the main hepatic veins is improved. A thoracic extension (E–F) into the eighth intercostal space is rarely necessary even for very large tumors. In many cases a right subcostal incision with an upper midline extension (A–B plus A–C) gives adequate exposure.

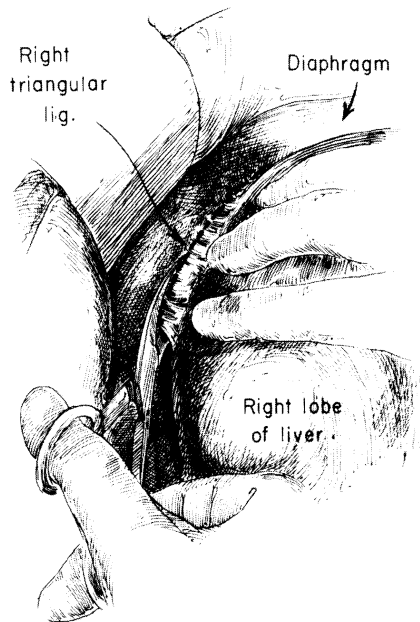
When the costal angle is narrow, a J-shaped incision as shown in Figure 9, B can be used. In children a rather flat bilateral subcostal incision as shown in Figure 9, C can be used, without the midline extension. We apply self-holding retractors (Rochard retractor) to the right and left costal margins in order to obtain steady satisfactory exposure.

#### *RIGHT-SIDED HEPATIC RESECTIONS*

The procedures of right trisegmentectomy and right lobectomy are described together in this section.

##### *Exploration and Early Mobilization of the Right Lobe*

After having obtained a satisfactory exposure and ruling out the possibility of extrahepatic metastases, a decision is made about the extent of hepatic resection, and a plan is developed for the steps of dissection. The sequence of the operation may vary from case to case depending upon the location and size of the lesions. Usually the attachment of the right colon (hepatocolic ligament) and the prerenal peritoneum (renohepatic ligament) are separated from the inferior surface of the liver. The right triangular and coronary ligaments may be incised at this time. If this is done, the right bare area can be broadly entered (Fig 10). By so doing, it becomes possible to



**FIG 10.**

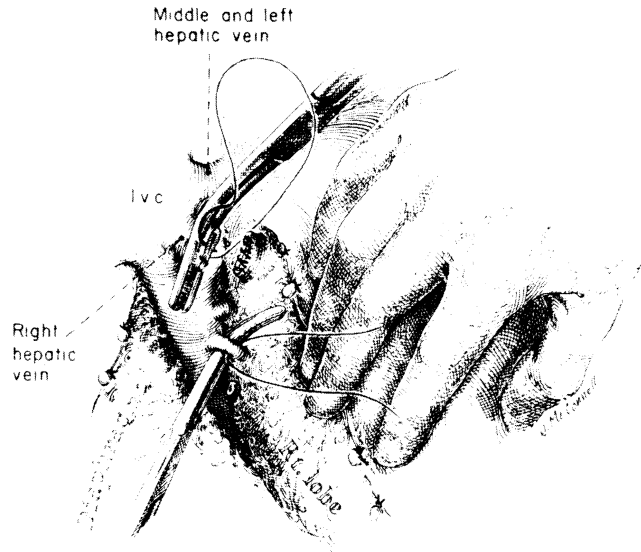
Preliminary mobilization of the right hepatic lobe. (From Starzl TE: *Experience in Hepatic Transplantation*. Philadelphia, WB Saunders Co, 1969, p 51. Used by permission.)

elevate the right lobe into the wound and to retract it toward the left freely when this maneuver becomes necessary later (Fig 11).

Early mobilization of the right lobe is an optional luxury, the feasibility of which depends on the location of the lesion. If mobilization is difficult, or if the right hepatic vein cannot be seen or encircled easily, it can be approached from within the liver during the parenchymal transection (see later). The intraparenchymal approach to the right hepatic vein is especially useful when the tumor is fixed to the diaphragm or to the adrenal gland or right kidney.<sup>31</sup> In such cases, the diaphragm, adrenal gland, or kidney can be included with the liver specimen as the last step in the extirpation. Having settled on the final incision and having decided for or against preliminary right lobar mobilization, attention is then turned to the hepatic hilus.

#### ***Hilar Dissection***

There are numerous variations of hepatic hilar structures, particularly of the hepatic artery as described in the previous section. In the past we thought that the dissection of the hilar structures would be

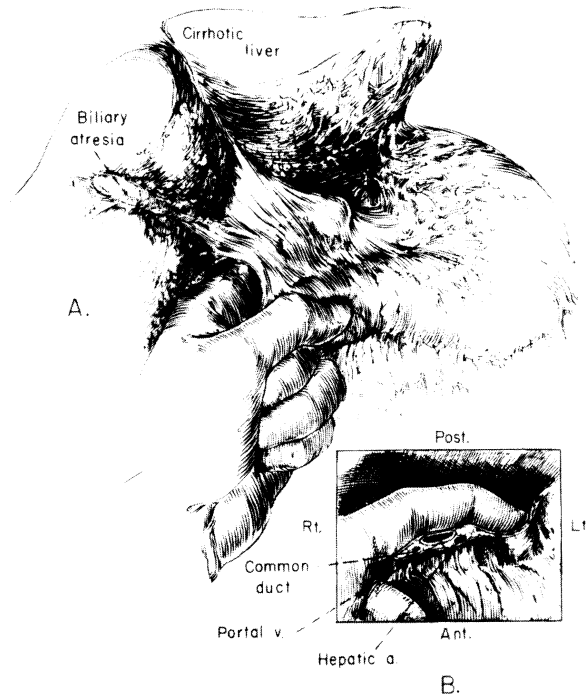


**FIG 11.**

Several small short hepatic veins are ligated and divided as they enter the vena cava. The right hepatic vein is divided between vascular clamps and oversewn with vascular sutures. *I.v.c.* = inferior vena cava. (From Starzl TE et al: *Surg Gynecol Obstet* 1975; 141:435. Used by permission.)

so greatly facilitated by prior knowledge of the arterial blood supply of the liver that elective hepatic resection should never be performed without preoperative angiography.<sup>30</sup>

For the last 10 years, however, we have not used preoperative angiography for this purpose because the intraoperative examination of the hilar structures by inspection and palpation is quite sufficient to determine all variants of the hepatic arterial blood supply. The first step is to look for an artery in the gastrohepatic ligament to the left of the portal triad. A vessel here is usually a left segmental or lobar branch and when present it usually comes from the left gastric artery. The branch enters the liver at the base of the umbilical fissure (between the medial and lateral segment) (see Fig 4). Then, a left index finger is inserted into the foramen of Winslow and pulses are palpated (Fig 12). If a pulse is found to the left of the common duct, anterior to the portal vein, it is almost certainly from the celiac axis (Fig 13). A pulse posterior to the portal vein is a sure sign of an artery that has originated from the superior mesenteric artery. This anomalous vessel usually supplies part or all of the right lobe of the liver, but it also may supply part of the left lobe as well or even the entire liver.

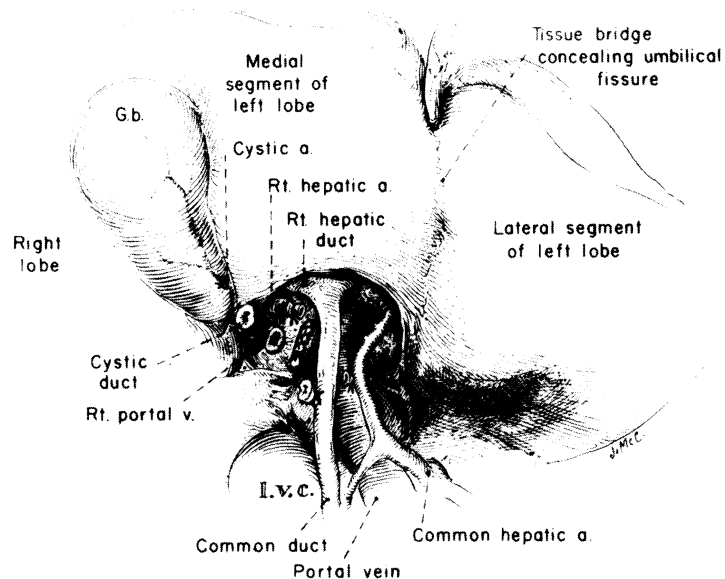


**FIG 12.**

Intraoperative examination of hepatic arterial blood supply. (From Starzl TE: *Experience in Hepatic Transplantation*. Philadelphia, WB Saunders Co, 1969, p 52. Used by permission.)

The first step in dissecting the hilum is to free, ligate and divide the cystic duct and artery (see Fig 13). The cystic artery usually arises from the right hepatic artery. By dividing the cystic artery and duct, the bifurcation and especially the right branches of the hilar structures can now be identified more easily and safely. The right hepatic artery is sacrificed first (see Fig 13). The hepatic arterial variations are so numerous that the ligation should never be performed without preliminary test occlusion and without being sure that during this test occlusion there are arterial pulsations going to the fragment to be retained whether this be the full left lobe or the left lateral segment.

After dividing the right hepatic artery and clearing the peritoneum, lymphatics, and nerve tissue, the right branch of the portal vein is encircled, ligated, and divided if it is long enough. If it is short, it is divided between vascular clamps, and the proximal ends closed with continuous 6-0 proline suture (see Fig 13). If any difficulty with exposure is encountered because of overhanging tumor,



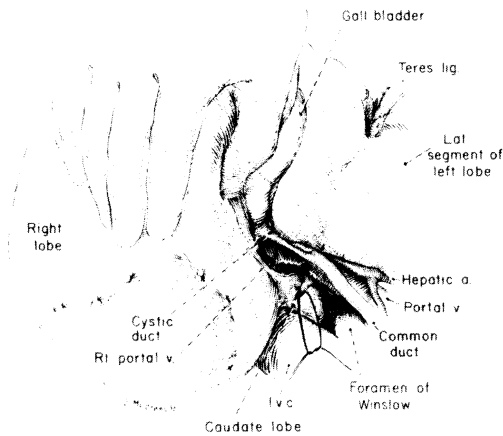
**FIG 13.**

Devascularization of the right lobe is completed. The bifurcation of the bile duct is almost always the most superior structure and is often inside the liver. *I.v.c.* = inferior vena cava; *G.b.* = gallbladder. (From Starzl TE et al: *Surg Gynecol Obstet* 1975; 141:431. Used by permission.)

the portal vein can be easily approached laterally or posteriorly, when the liver is retracted anteriorly to the right (Fig 14). This posterior approach is especially helpful if vein branches emanate from the back of the portal bifurcation, as is often seen.

After dividing the right hepatic artery and the right branch of the portal vein, a line of demarcation becomes evident between the true right and left lobe through the bed of the gallbladder and directed toward the vena cava. If the line of demarcation is not evident or is far to the right of the expected line, further search for missed hepatic arterial or portal branches is necessary.

Of the three triad structures, the common hepatic duct almost always has the most superior bifurcation, so high in fact that the division may be within the substance of the liver (see Fig 13). The right branch of the duct is near the base of the gallbladder bed, where it can come off like a crossbar from a T. In anomalous cases, the cystic duct can join the right hepatic duct, but this will have been discovered usually with the cystic duct dissection and ligation. The right duct is ligated and divided, but only after a definite duct has been demonstrated to pass to the retained left fragment of liver. (Injury to



**FIG 14.**

Posterior approach in dissecting the bifurcation of the portal vein. *I.v.c.* = inferior vena cava. (From Starzl TE et al: *Surg Gynecol Obstet* 1975; 141:432. Used by permission.)

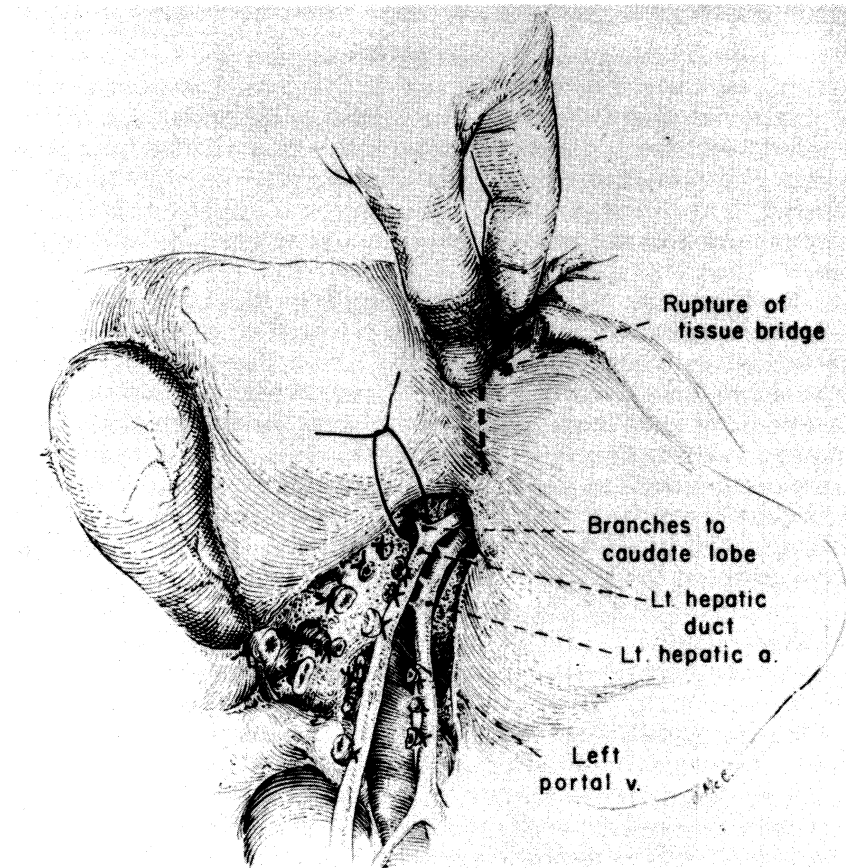
the duct system is probably the most common technical error committed today in performing hepatectomies.) At this point the hilar dissection of the right hepatic lobectomy has been completed. When it has been possible to divide the right hepatic vein, the stage is set for removal of the specimen. Additional dissection of the left branches are necessary if right hepatic trisegmentectomy is to be performed.

#### ***Additional Hilar Dissection for Right Trisegmentectomy***

Before proceeding further, the exact location of the umbilical fissure (left lateral segmental fissure) must be determined. In many human livers, the umbilical fissure is concealed by a fusion of the lips of the medial and lateral segments of the left lobe (Fig 15). Even if the fusion is complete and involves a large surface, no large structures pass through it and it can be readily opened with finger fracture (see Fig 15). In the base of the opened field lies the true umbilical fissure.

The groove running from the bifurcation of the portal structures to the left contains the left lobar branches. It is called *pars transversus* (transverse portion) and is several centimeters in length. It runs along the base of the quadrate lobe, dividing the medial segment of the liver into the quadrate and caudate components. As the left triad structures are mobilized from the transverse groove, the first branches pass posteriorly to the left portion of the caudate lobe. If a decision is made to sacrifice these branches (see Fig 15), the caudate lobe will be devitalized, and, ideally, it should be removed entirely





**FIG 15.** Nearly completed division of fine branches from the transverse part of portal triad structures. The branches to the caudate lobe should be preserved unless all of the caudate lobe is to be removed. The tissue bridge is being broken down to permit access to the umbilical fissure. (From Starzl TE et al: *Surg Gynecol Obstet* 1975; 141:433. Used by permission.)

from the wall of the inferior vena cava and from its junction with the lateral segment. If these posterior branches can be retained, the intrinsic risk of right trisegmentectomy is undoubtedly reduced by preserving a larger hepatic fragment. However, total extirpation of the caudate lobe is unavoidable if a good margin is to be obtained.

Except for early branches to the caudate lobe, usually there are few, and sometimes no, branches from the triad structures in the course of the pars transversus. However, these must be looked for, meticulously dissected, and doubly ligated and divided (see Fig 15). If there is a variant artery arising from the left gastric artery or from

the celiac axis (see Fig 4) to the entire left lobe or to the left lateral segment, it almost always enters the base of the umbilical fissure considerably to the left of the field of dissection of the pars transversus. This anomaly, if recognized early, is a technical advantage since its presence virtually eliminates the danger of dearterializing the remaining left lateral segment during dissection in the transverse groove. The dissection of the pars transversus from right to left is stopped short of the umbilical fissure (see Fig 15) if the structures become buried in the hepatic parenchyma, which frequently is the case.

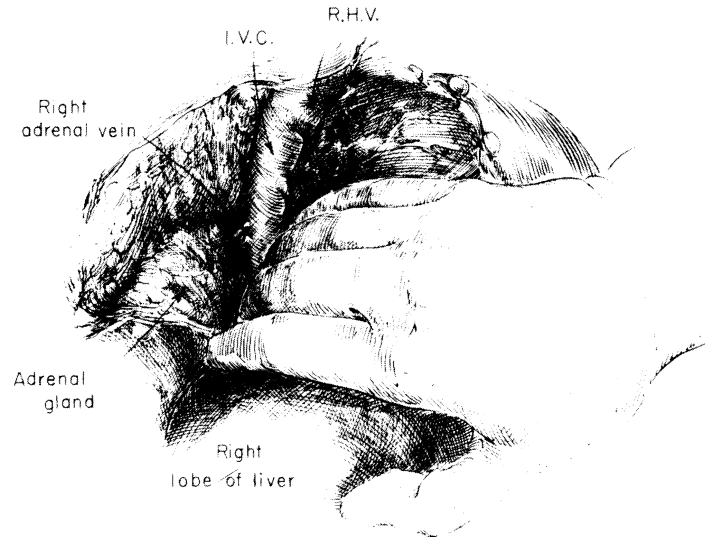
In some patients, the further division of the triad structures into medial and lateral segmental branches can be seen easily. If this natural advantage is present, cautious dissection, ligation, and division of those branches feeding back to the medial segment can be done now, working from the base of the umbilical fissure anteriorly. Any difficulty in dissection or ambiguity about what is being freed must prompt immediate discontinuance of such efforts, which could lead to damage of the structures going to the lateral segment. The safest technique will be to deal with the "feedback" structures to the medial segment at the time of parenchymal transection.

### *The Hepatic Veins*

If the right hepatic vein has not been dealt with at an earlier time, it is approached by cautious dissection as the right lobe is retracted, and it is encircled. This can be dangerous because the right hepatic vein is short outside the liver and a tear during its dissection may create a large defect at its junction with the suprahepatic inferior vena cava that can be difficult to control or repair. The encircled right hepatic vein is doubly clamped with angled pediatric vascular clamps, and divided and sewn shut on both sides with continuous vascular sutures (see Fig 11).

The right hepatic vein and a somewhat smaller posterior hepatic vein which is one of the most inferior veins are sacrificed with either right lobectomy or right trisegmentectomy. Judgment must be exercised about the intervening hepatic veins, the more conservative approach in sparing vessels being with the true right lobectomy. With either lobectomy or trisegmentectomy, the entire length of the retrohepatic vena cava is exposed by careful sharp dissection (Fig 16). The right adrenal gland is pushed back into the retroperitoneum and the adrenal vein should not be injured. The smaller hepatic veins which seem to enter from the specimen being developed into the anterior surface of the retrohepatic vena cava are doubly ligated and divided.

When right trisegmentectomy is performed, all of the caudate lobe may be removed or its left portion may be spared by leaving intact the first branches of the left triad structures (see earlier). If the deci-



**FIG 16.**

After preliminary mobilization the right lobe is gently retracted anteriorly and to the left. The entire length of the retrohepatic vena cava is exposed by careful dissection. *I.V.C.* = inferior vena cava; *R.H.V.* = right hepatic vein. (From Starzl TE: *Experience in Hepatic Transplantation*. Philadelphia, WB Saunders Co, 1969, p 116. Used by permission.)

sion is for complete caudate removal, four to eight small hepatic veins from this piece of liver are ligated and divided on the anterior left wall of the vena cava. With this radical step, the left hepatic vein is the sole source of venous drainage of the lateral segment.

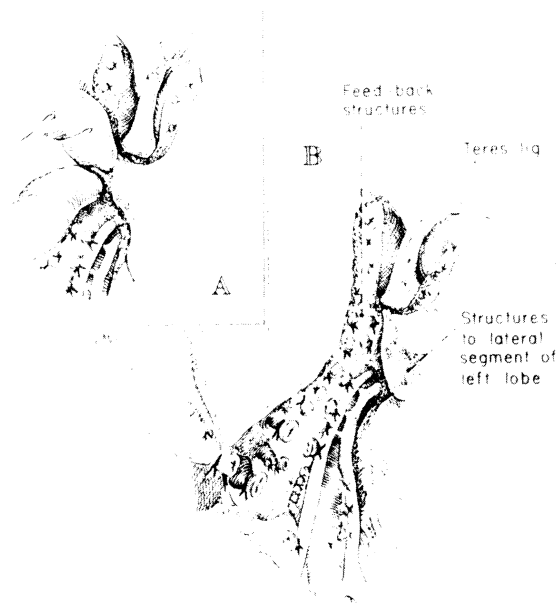
#### ***The Parenchymal Transections With Right Lobectomy and Right Trisegmentectomy***

**Right Lobectomy.**—The devascularized right lobe can be seen by the color demarcation in the anteroposterior plane that runs from the gallbladder bed toward the inferior vena cava. The cyanotic liver includes the right portion of the caudate lobe. The transection is in this plane, beginning from the edge of the liver with a combination of ligatures, clamps, knife handles, or fingers according to the surgeon's preference. As the transection moves toward the inferior vena cava, the fusions of the left part of the caudate lobe with the right caudate portion and with the posterior segment of the right lobe are opened up on the anterior aspect of the vena cava.

Development of the interlobar plane is made easier if an interlobar vein can be located as a "pathfinder." Such a vein, is usually a main branch of the middle hepatic vein, and normally branches of the

vein are the only big structures that cross the interlobar fissure. In unusual cases, triad structures originating from the left branches may cross the fissure to supply a portion of the right lobe, but these structures are automatically encountered and ligated as the plane is developed.

**Right Trisegmentectomy.**—The additional steps preparatory to right trisegmentectomy have already been mentioned. However, the crucial distinction between right trisegmentectomy and right lobectomy is the identification and ligation during trisegmentectomy of the complex of arterial, portal, and ductal structures that originate in the umbilical fissure and feedback from the main left trunks to the medial segment of the left lobe. These have been called “feedback structures,” and ordinarily they are buried in the hepatic parenchyma. Only after the occlusion of the feedback vessels does the medial segment become cyanotic. Although the feedback structures originate in the umbilical fissure, they are not dissected there unless



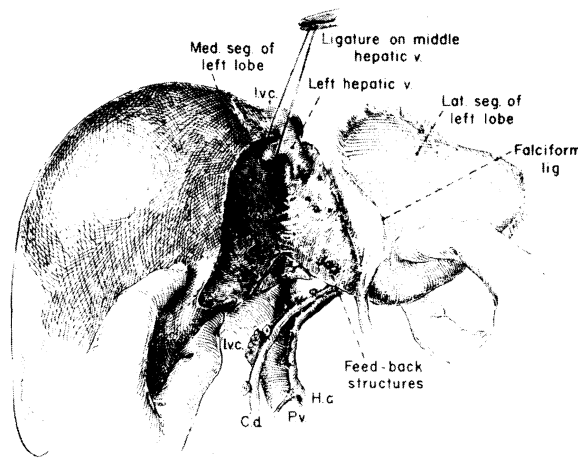
**FIG 17.**

Structures feeding back from the umbilical fissure to the medial segment of the left lobe. **A**, these structures are found in the liver substance just to the right of the falciform ligament and umbilical fissure. Note that hepatic tissue bridge has been broken down. **B**, the three segments of the specimen are now devascularized. (From Starzl TE, et al: *Surg Gynecol Obstet* 1975; 141:434. Used by permission.)

they can be clearly seen. Instead, the feedback structures usually are approached within the substance of the liver, just to the right of the falciform and round ligaments. The parenchyma of the liver can be crushed down to them, either with clamps and ligature or with fingers (Fig 17).

With all three segments devascularized, the liver is transected from below toward the diaphragmatic surface at the exact line of color demarcation (see Fig 17) in the same way as with lobectomy, fingers using intersegmental veins for guidance. These veins are kept intact with the lateral segment when possible. The transection of the liver is facilitated by pushing down the right side of the liver with the left hand of the operator to open the cleavage plane. The middle hepatic vein which drains the medial segment is ligated near the diaphragm. It either enters separately into the inferior vena cava or, more commonly, it joins the left hepatic vein to form a short common trunk (Fig 18).

Injury or stricture of the left hepatic vein must be prevented by cautious identification of the middle and the left hepatic vein. A stricture of the left hepatic vein will lead to acute Budd-Chiari syndrome and uncontrollable hemorrhage from the cut surface of the liver. If the lateral segment is left with its normal drainage, the frag-



**FIG 18.**

Nearly completed liver transection for right trisegmentectomy along exact line of color demarcation. The last major structure to be encountered is the middle hepatic vein. Injury to the left hepatic vein must be avoided. *I.v.c.* = inferior vena cava, *C.d.* = common bile duct, *H.a.* = hepatic artery, *P.v.* = portal vein. (From Starzl TE et al: *Surg Gynecol Obstet* 1975; 141:436. Used by permission.)

ment can accommodate the portal venous flow immediately without any portal hypertension.<sup>30, 31</sup>

Division of the right hepatic vein from within the liver and the use of this technique to help remove adjacent diaphragm or organs were mentioned earlier (Fig 19).

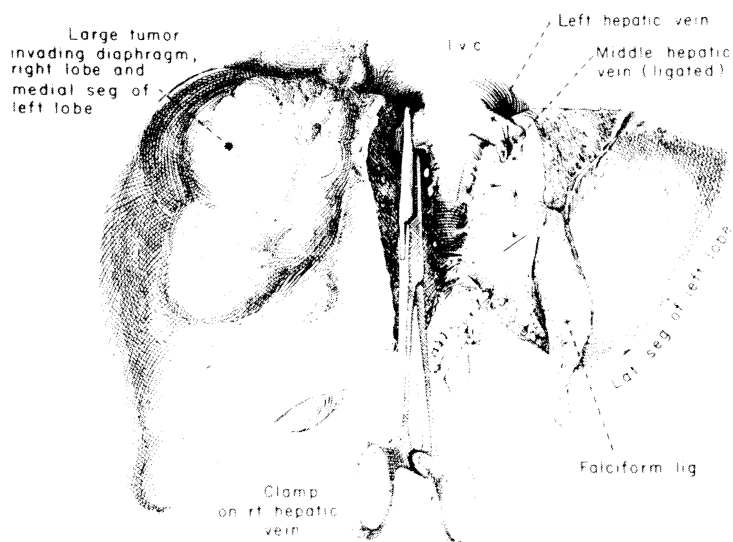
#### LEFT-SIDED HEPATIC RESECTION

The operative procedures of left lateral segmentectomy, true left lobectomy and left trisegmentectomy are described together.

##### *Exploration and Mobilization of the Left Lobe*

As with the right-sided resections, the initial step of left-sided hepatic resection is the identification of the hepatic arterial supply. The left hepatic artery originates either from the common hepatic artery or the left gastric artery. If there is an anomolous artery of left gastric origin it may supply the whole left lobe or only the lateral segment (see Fig 4).

If a left lobectomy or left trisegmentectomy is planned, or usually even for left lateral segmentectomy mobilization is begun by division



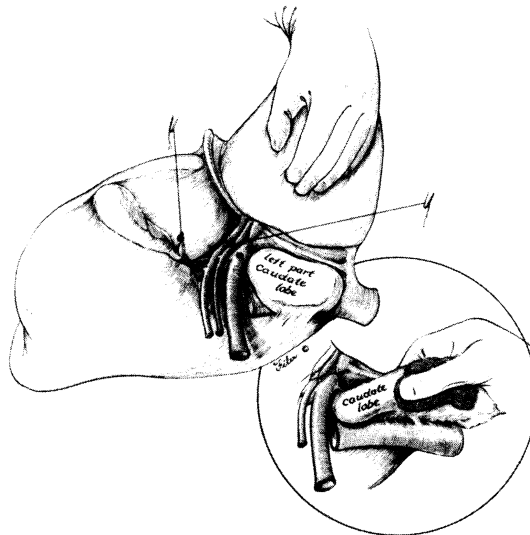
**FIG 19.**

Control of right hepatic vein from within the liver nearly at the end of liver transection. I.v.c. = inferior vena cava. (From Starzl TE et al: *Surg Gynecol Obstet* 1980; 150:2. Reproduced with permission.)

of the round ligament (ligamentum teres hepatis) and incision of the falciform ligament toward the suprahepatic part of the inferior vena cava. The left lobe can be lifted anteriorly and retracted to the right after division of the left triangular ligament and incision of the left coronary ligament. The small left bare area is developed so that the suprahepatic vena cava is exposed and the entrance of the left phrenic vein into the left hepatic vein is visualized.

#### **Hilar Dissection**

With the mobilized left lobe retracted into the wound, the principal left lobar branches of the portal triad can be approached safely from their posterolateral aspect (Fig 20). With this maneuver, the posteriorly located left portal vein is turned so as to become the most exposed of the triad structures. The left portal vein is dissected, encircled, and divided first. The hepatic artery and then the left branch of the duct are ligated and divided (see Fig 20). The exact location of the ligations determines whether the caudate process is to be removed since the first branches of the left triad structures go posteriorly to the left portion of the caudate lobe. If the caudate pro-



**FIG 20.**

Exposure of the left hilar structures is accomplished by retracting the lateral segment of the left lobe anteriorly and to the right. If the left portion of the caudate lobe is removed, it must be dissected from the vena cava, and a few small hepatic veins must be ligated. (From Starzl TE et al: *Surg Gynecol Obstet* 1982; 155:4. Used by permission.)

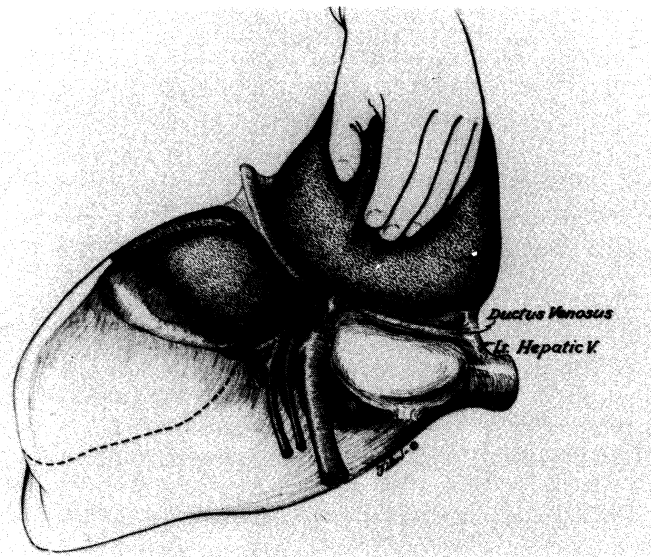
cess is to be retained the ligatures must be beyond these branches.

For the left lateral segmentectomy, dissection is more distal, within and to the left of the umbilical tissue. Ligatures are placed far enough distally to preserve the feedback vessels.

When these steps are completed, the devascularized portion of the liver becomes cyanotic. When the main left triad structures are ligated, the color demarcation is in the middle of the gallbladder bed (Fig 21). If true left lobectomy is planned, the gallbladder is removed to allow accurate development of the lobar plane.

### **Hepatic Vein**

The left hepatic vein is shorter than the right one, whether it empties separately into the suprahepatic vena cava or into the middle hepatic vein to form a common trunk. In performing lateral segmentectomy, the hepatic vein usually should be dealt with towards the end of the liver transection since it is too dangerous to attempt to encircle it. However, with full lobectomy or left trisegmentectomy, the exposure is more complete, and it is often possible to dissect free, clamp, and close with suture the left and middle veins, or a common trunk when this is present. If the caudate process is to be removed, several branches entering the left or anterior wall of the retrohepatic vena cava must be dissected, doubly ligated, or sutured and divided.



**FIG 21.**

Completion of the left hilar dissections and divisions. The caudate lobe is spared. Note the color demarcation and the posterior incision along the obliterated ductus venosus. (From Starzl TE et al: *Surg Gynecol Obstet* 1982; 155:4. Used by permission.)



## *The Parenchymal Transections*

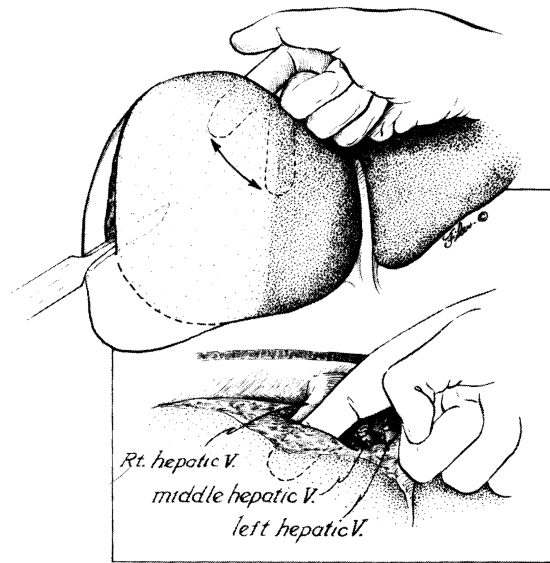
*Lateral Segmentectomy.*—The transection line is along the left side of the falciform ligament anteriorly and along the fissure of obliterated ductus venosus (fissure between the caudate process and the lateral segment) posteriorly. The feedback vessels to the medial segment of the left lobe must be preserved, as well as the hepatic duct. Near the end of liver transection the left hepatic vein and often the middle hepatic vein are encountered. The middle hepatic vein must not be harmed. The left hepatic vein is skeletonized as the last connection to the specimen, clamped, and sutured with a continuous vascular technique.

*Left Lobectomy.*—The color demarcation runs from the gallbladder bed toward the inferior vena cava, ending at the fissure of obliterated ductus venosus posteriorly if the caudate lobe proper is to be spared (see Fig 21). If the caudate lobe proper is removed, the anterior wall of the retrohepatic vena cava is completely exposed (see Fig 20). The cleavage plane can be developed from the hilum from the ligament of the obliterated ductus venosus, or by a retrograde technique from above downward. The left and middle hepatic veins or the common trunk can be skeletonized and sewed shut near the end of the transection, as described under lateral segmentectomy if this was not feasible earlier.

*Left Trisegmentectomy.*—As with left lobectomy, the liver transection can start posteriorly along the fissure of the obliterated ductus venosus or behind the left portion of the caudate lobe just in front of the vena cava (see Figs 20 and 21). With this approach, the left and middle hepatic veins already should have been crossclamped and sutured. The left side of the liver is then lifted anteriorly and retracted to the right. An intersegmental plane must be found between the anterior and posterior segments of the right lobe, both of which still have an intact blood supply (Fig 22). It is wise to clamp the portal triad structures at the hilus temporarily (Pringle maneuver) during this part of the operation. The Pringle maneuver not only reduces the blood loss but also facilitates the identification of arterial, portal venous, and biliary branches which are to be preserved.

The cleavage plane usually is begun at the diaphragm, keeping anterior to the right hepatic vein (see Fig 22). A resistance-free plane is sought with the dissection finger (see Fig 22), and all strands encountered are clamped or ligated. Downward traction is continued, and inferiorly the dissecting finger should emerge near the base of, and at right angles to, the gallbladder bed (Fig 23). Near the porta hepatis, still inside the substance of the liver, anterior branches of the right triad structures are encountered and individually ligated.

In some livers there is a natural transverse groove near the base of the gallbladder that delineates the plane between the anterior and



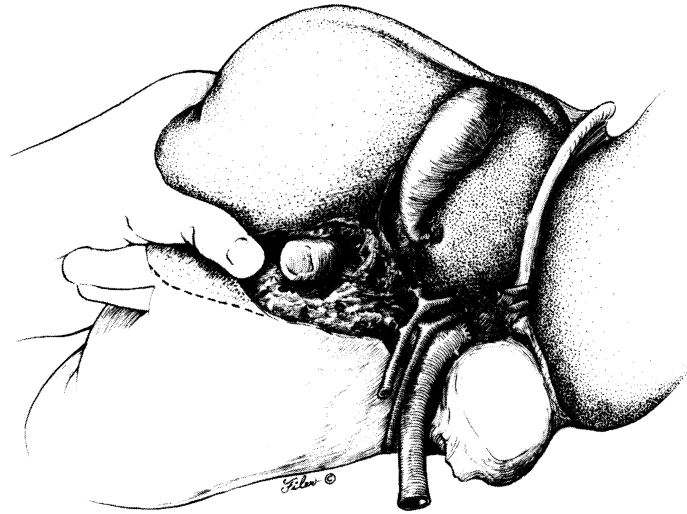
**FIG 22.**

Superior to inferior scalping of the anterior segment of the right lobe. Note that the dissecting finger is kept anterior to the right hepatic vein, the left and middle hepatic veins having been ligated or sutured. (From Starzl TE et al: *Surg Gynecol Obstet* 1982; 155:5. Used by permission.)

posterior segment at the hilum, and which allows the anterior segmental branches to be dissected, ligated, and divided in a conventional way. Under these circumstances, the transection for the left trisegmentectomy can be conducted from the hilum toward the diaphragm. Test clamping of the anterior branches marks the anterior segment by cyanotic discoloration. When the transection is begun from the hilum to the diaphragm, the specimen is lifted forward and retracted upward, while protecting the vital posterior structures from injury. Anterior branches are expeditiously and cautiously ligated and divided (Fig 24).

#### **BEFORE CLOSURE**

Complete hemostasis is the key in preventing postoperative mortality and morbidity after any resection. If the correct plane has been developed, the cut surface of the liver is pink and well vascularized. Since residual bleeders are not covered by devitalized tissue, they can be easily identified and suture ligated. The cut surface of the liver after left lateral segmentectomy or after right trisegmentectomy

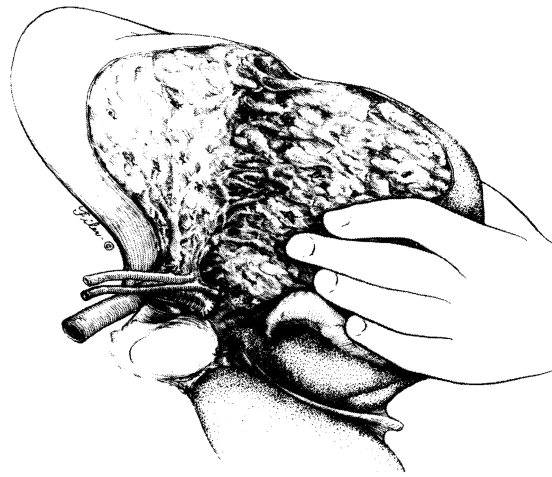


---

**FIG 23.**

Further development of plane between the anterior and posterior segment of the right lobe of the liver. (From Starzl TE et al: *Surg Gynecol Obstet* 1982; 155:5. Used by permission.)

---



---

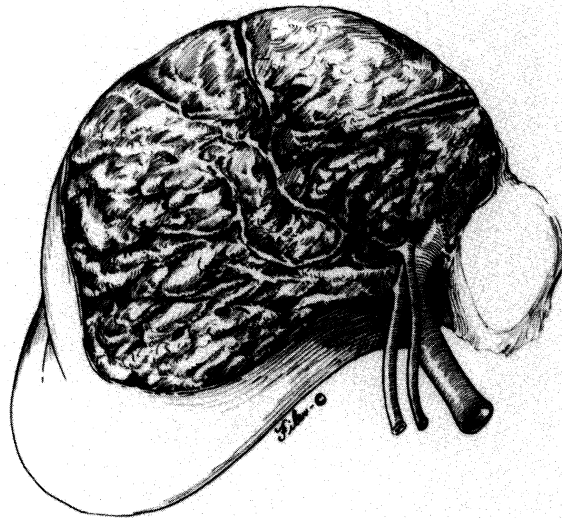
**FIG 24.**

Alternative approach with which the anterior segment is scalped from the hilus of the liver to the diaphragm. (From Starzl TE et al: *Surg Gynecol Obstet* 1982; 155:6. Used by permission.)

---

is small, and it is remarkably dry, when the appropriate cleavage plane is followed. On the other hand, the cut surface of the liver after left trisegmentectomy is broad and presents an unfamiliar sight for most surgeons (Fig 25). However, even with this operation, precise visualization of the residual bleeding points is possible after discontinuance of the Pringle maneuver. No effort is made to cover the cut surface with living tissue or prosthetic materials. Large suture ligatures to close the cut surface are avoided because they may obstruct the remaining major anatomic structures.

With left trisegmentectomy, the extent to which the remaining ducts are exposed is so much greater than with other kinds of anatomic resections that the risks of bile fistula and duct injury or positional distortion are increased. Attention is paid to meticulous closure with fine sutures of minute bile leaks from the exposed ducts. Even if the residual posterior duct is not distorted, kinked, or injured it is advisable to stent the duct and to drain it with a T-tube. An intraoperative cholangiogram should be obtained. This precautionary step not only confirms the integrity of the duct system, but also identifies sites of biliary leakage. The small leaking points are easily identified and closed with fine suture while a small amount of saline or diluted methylene blue is injected into the duct.



**FIG 25.**

Operative field after completion of left trisegmentectomy. (From Starzl TE et al: *Surg Gynecol Obstet* 1982; 155:6. Used by permission.)

The same precaution of cholangiography is worthwhile for other kinds of resections although we usually do not use T-tube biliary drainage except for left trisegmentectomy. One or two Jackson-Pratt closed suction catheters are placed near the cut surface in the subphrenic space before closure.

## **SURGICAL PATHOLOGY**

### *DIAGNOSTIC CONSIDERATIONS*

Hepatic tumors from the point of view of hepatic resection may be grouped into five categories:

1. Benign lesions with expectancy of cure.
2. Metastatic lesions limited to an anatomical region of the liver that permits their resection with expectation of increased longevity.
3. Primary malignant tumors limited to anatomical regions of the liver that permit their resection with expectation of cure or increased longevity.
4. Primary malignant tumors and rare benign lesions occurring diffusely throughout the liver treated by total hepatectomy with liver or organ cluster transplantation.
5. Unresectable tumors.

This discussion will focus largely on lesions in categories 1, 2, and 3, with occasional reference to those in the other two categories.

### *NEEDLE BIOPSY AND FINE NEEDLE ASPIRATION BIOPSY*

It is critical, especially with needle biopsy and fine needle aspirate, to be certain that tissue has been obtained from the lesion within the liver. Furthermore, we do not believe that most discrete lesions should require preoperative needle biopsies when they are to be removed surgically.

Needle biopsy and fine needle aspiration provide diagnostic information in approximately 40% to 75% of cases when performed in a "blind" fashion. When more extensive disease is present there is a greater yield.<sup>40, 41</sup> If biopsies guided by computed tomography (CT) and ultrasonography are used the diagnostic yield approaches 95%.<sup>42-44</sup> Despite the advantages of entering surgery with an established diagnosis, we usually do not perform these procedures as part of our workup. They have a small but significant complication rate. When an operation is planned in any case, we do not believe that the risk is justifiable.

## *FROZEN SECTION DIAGNOSIS*

Reciprocally, the pathologist who is fully informed about the lesion has the optimal opportunity to establish the most accurate diagnosis. The pathologist should ideally attend the operating room and personally visualize the gross location and extent of the tumor. Establishing the true nature of most hepatic tumors is not too difficult, but there are certain situations where it may be impossible to establish with certainty, on the basis of frozen section, the precise tumor type or whether it is benign or malignant.

The determination as to whether a lesion is a hepatic adenoma or a well-differentiated hepatocellular carcinoma may not be feasible on frozen section and, on occasion, may best be deferred. This does not significantly alter the surgical approach to the resectable lesion or the patient's immediate postoperative management. Similarly, the true characterization of the neuroendocrine nature of the lesion may have to await immunohistological or electron microscopic confirmation. Histologic subtleties, including a suggestion of nuclear palisading or a more uniform cell population, may serve to alert the pathologist initially to the possible neuroendocrine origin of the tumor.

Angiography, ultrasonography, CT, and radionuclide scanning do not always provide a clear diagnostic picture, and the pathologist should be aware of such facts in correlating data from these studies with the morphological appearances.

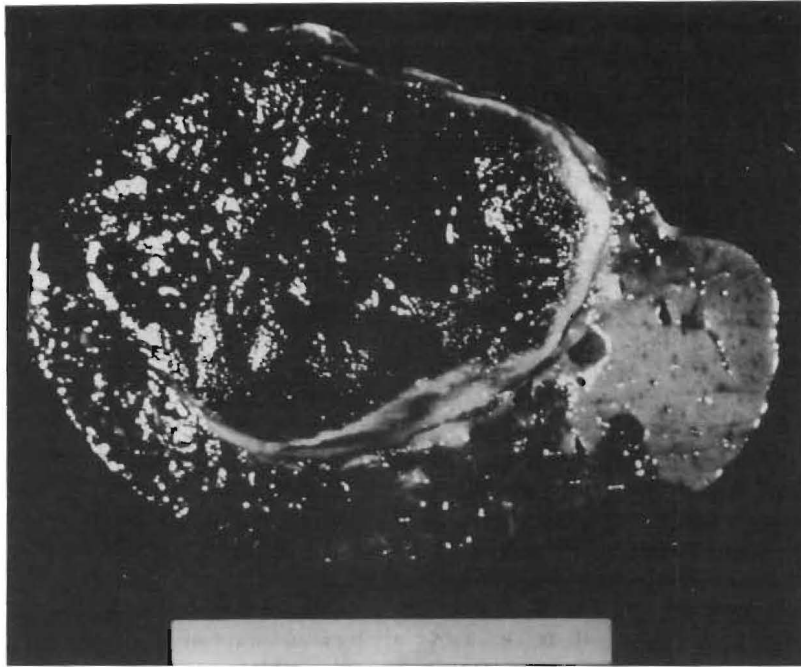
In unselected series of liver tumors metastatic carcinoma is the most common neoplasm. However, in series of patients undergoing hepatic resection for hepatic malignancy, such as the one that is the basis of this report, primary tumors are as frequent as metastatic tumors. Also in our series of patients there was an equal incidence of primary and metastatic sarcomatous lesions of the liver.

Only 50% of angiosarcomas of the liver are correctly diagnosed preoperatively,<sup>45</sup> and their differential diagnosis includes leukemic infiltrates involving the sinusoids, other sarcomata and, on occasion, poorly differentiated primary or metastatic spindle cell carcinoma in the liver. The differentiation of cholangiocarcinoma from metastatic adenocarcinoma may be impossible in specific instances and in others is resolved only following lengthy histologic and histochemical evaluation.

## *BENIGN LESIONS*

### *Hemangioma*

This is the most common of all hepatic tumors.<sup>46, 47</sup> It occurs at all ages, with roughly equal sex distribution. The tumor is usually solitary but multiple lesions do occur. They frequently extend to the



**FIG 26.**  
Giant cavernous hemangioma.

liver capsular surface, are red-blue-purple and usually well circumscribed. The lesion in vivo is compressible and will reexpand to its former size when the compressive force is removed. Cut surface of the tumor shows a spongelike or honeycombed appearance from which blood is freely expressible. Varying degrees of scar tissue resultant from organization of thrombosed and infarcted areas may provide a firm white appearance to focal areas of the tumor (Fig 26).

Histologically a typical cavernous hemangioma is composed of anastomosing vascular channels of varying caliber lined by flattened endothelial cells with hyalinized and focally calcified fibrous stroma. Occasional phleboliths occur.

#### *Infantile Hemangioendothelioma*

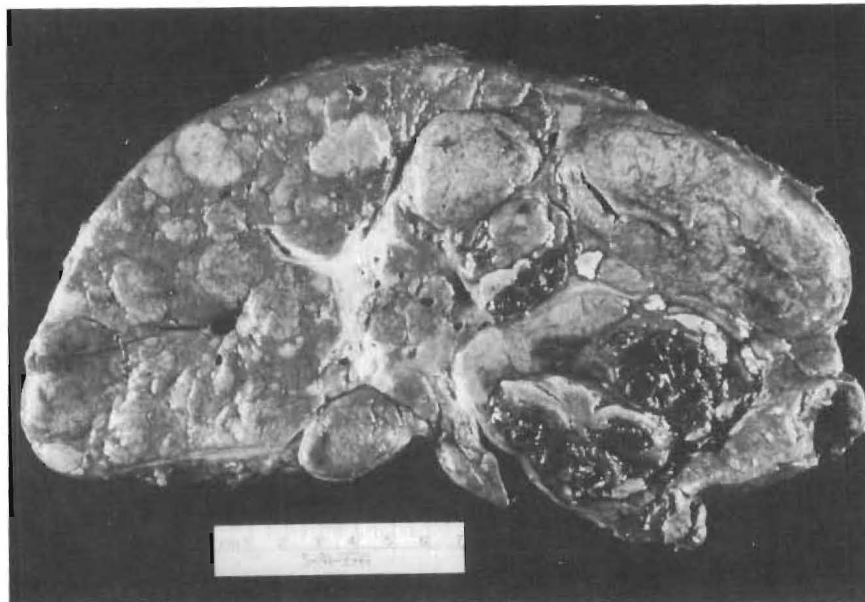
This is the most common vascular tumor in children.<sup>48</sup> It is frequently multiple and may be associated with similar lesions in other organs. Patients with these lesions may have an abdominal mass, high output cardiac failure, or jaundice. Grossly the liver contains multiple circumscribed masses measuring up to 3 cm in diameter, with gray-white borders and dark blue centers. Capsular rupture may occur. Microscopically this lesion shows two histologic patterns.<sup>49</sup> The most common (type I) shows vascular channels of vary-

ing size lined by plump endothelial cells showing rare mitoses. These lesions may be associated infrequently with the subsequent occurrence of angiosarcoma. In comparison, the other type (type II) is a more densely cellular lesion and shows a greater degree of pleomorphism. This variant may show areas of cavernous hemangioma, areas similar to type I lesion or areas of angiosarcoma as indicated by regions of intravascular endothelial proliferations, infarction and hemorrhage.

These observations make it difficult to predict the biological behavior of this tumor variant from its histologic appearance.<sup>49</sup> There is a similar lack of uniformity in its ultrastructural appearance which presumably reflects its multiple histologic patterns.

#### ***Liver Cell Adenoma***

This lesion is rarely seen in childhood and most cases have been reported in women of childbearing age. Prior to the use of synthetic gonadal steroids in 1960, this entity was rarely recognized.<sup>50</sup> Since that time reports of liver cell adenoma have become more frequent, especially in the United States, where such steroid usage was first introduced and the initial steroid concentrations were higher than in the more recent preparations. It has also been reported in as



**FIG 27.**

Multiple hepatic adenomas. Numerous lesions of irregular dimensions with focal hemorrhagic necrosis (*lower right*).



many as half the patients with type I glycogen storage disease,<sup>51</sup> in familial diabetes,<sup>52</sup> and in secondary hemochromatosis.

It usually occurs as a single lesion in an otherwise normal liver, but cases of multiple adenomas (Fig 27) have been described.<sup>53</sup> The lesions may vary in size, most being between 5 and 15 cm in major dimension, and they are soft, well circumscribed, extremely vascular, and tan, red, or yellow in color. Areas of hemorrhage, necrosis, and scar tissue are frequent, and the overall gross appearance may closely resemble a solitary mass of hepatocellular carcinoma. Histologically the lesion consists of hepatocytes arranged in two to three cell plates separated by slit-like sinusoidal spaces without evidence of portal structures (Fig 28). Importantly, the reticulin framework is retained and closely resembles that of normal lobules, which aids in its distinction from hepatocellular carcinoma, which rarely if ever produces a normal reticulin pattern. The individual hepatocytes are larger than normal, with uniform nuclei and pink granular or clear cytoplasm. Large thin-walled vessels are frequent, and when thrombosed they may be associated with areas of infarction or hemorrhage.

$\alpha$ -Fetoprotein is not demonstrable in tumor tissue nor in the serum of patients with these lesions.<sup>54</sup>  $\alpha$ -1-Antitrypsin globules may be



**FIG 28.**

Hepatic adenoma. Narrow trabecular pattern of hepatocytes with vascular channels loosely separated from normal liver tissue (*lower left*) shows dark portal triads. Hematoxylin-eosin;  $\times 20$ .

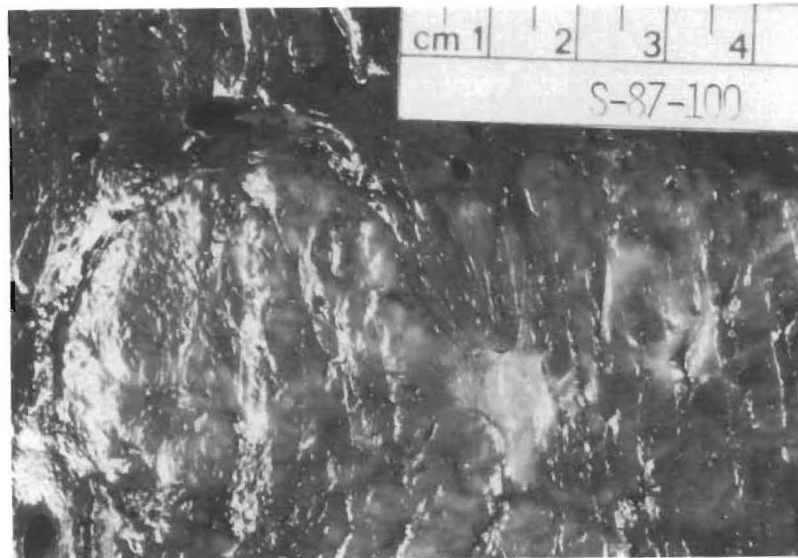
present—a nonspecific finding noted also in malignant hepatocellular neoplasms. No evidence of vascular invasion is seen. On rare occasion liver cell dysplasia is present, and its significance remains unknown.

### ***Focal Nodular Hyperplasia***

Focal nodular hyperplasia (FNH) occurs at any age but is most frequent between the years of 20 and 45. It is more common in women than in men. There is increasing evidence that FNH is probably unrelated etiologically to synthetic sex steroid usage; however, it has been suggested that these drugs may facilitate the tumors' growth.

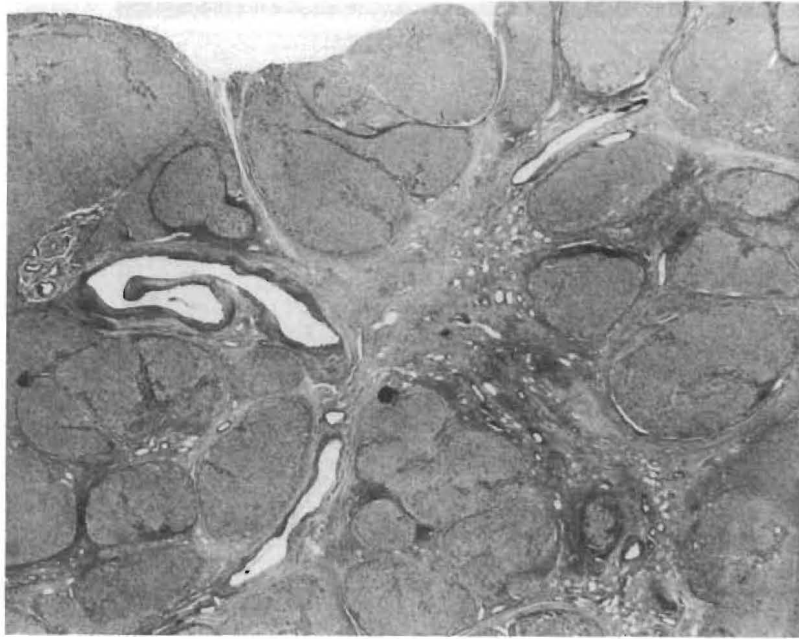
The lesion is usually round, solitary, and less than 5 cm in maximum dimension, occurring in an otherwise normal liver. Larger (15-cm or greater) lesions are rare and may be pedunculated. Histologically the lesion consists of normal appearing hepatocytes arranged irregularly into nodules, which are devoid of an acinar arrangement. There is a central or eccentric stellate scar with radiating fibrous septae containing proliferating bile ducts, inflammatory cell infiltrates, and large, irregularly thick-walled venous and arterial channels (Figs 29 and 30).

This lesion has been described in association with and has even been proposed as the benign counterpart of the fibrolamellar variant of hepatocellular carcinoma.<sup>55</sup> To date only 5 (4%) of 128 such cases



**FIG 29.**

Focal nodular hyperplasia. Segment of lesion with central white scar. The contiguous liver is normal.



**FIG 30.** Focal nodular hyperplasia. Irregular nodules of mature hepatocytes separated by irregular bands of fibrosis containing irregularly sized vascular channels and chronic inflammatory cells. Hematoxylin-eosin;  $\times 20$ .

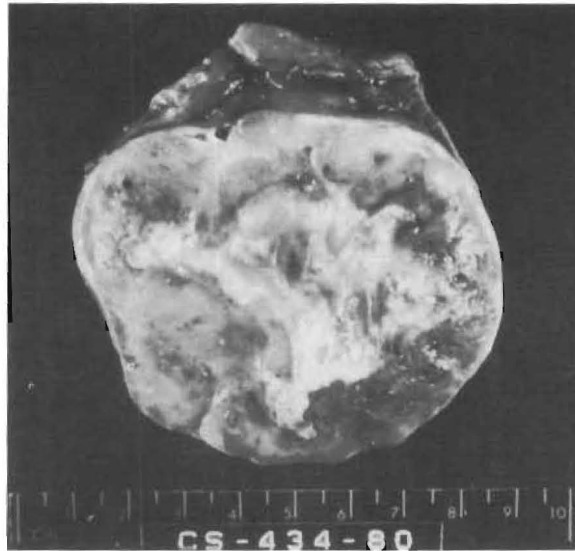have shown the presence of focal nodular hyperplasia in the same liver as the malignant tumor.<sup>54</sup>

#### ***Mesenchymal Hamartoma***

This lesion is second in incidence only to infantile hemangioendothelioma as a benign liver tumor in pediatric patients.<sup>56</sup> In a recent study of 48 cases of benign tumors from the Children's Hospital of Los Angeles<sup>57</sup> 14 (29%) were mesenchymal hamartomas while 29 (60%) were vascular in nature. It is almost exclusively a tumor of infants and very young children, most occurring before the age of 12 months. It is twice as common in males as females. We are aware of only 3 cases occurring in adults.<sup>58-60</sup>

Grossly, they are well-circumscribed, soft lesions that are fluctuant and cystic since they contain fluid or gelatinous material (Fig 31). In some cases the large number of cysts suggest a multilocular cyst.

Histologically these lesions are composed of edematous primitive connective tissue with multiple cysts, irregularly dilated tortuous bile ducts, and numerous blood and dilated lymphatic channels.<sup>61</sup> The connective tissues contain elongated spindle and stellate cells



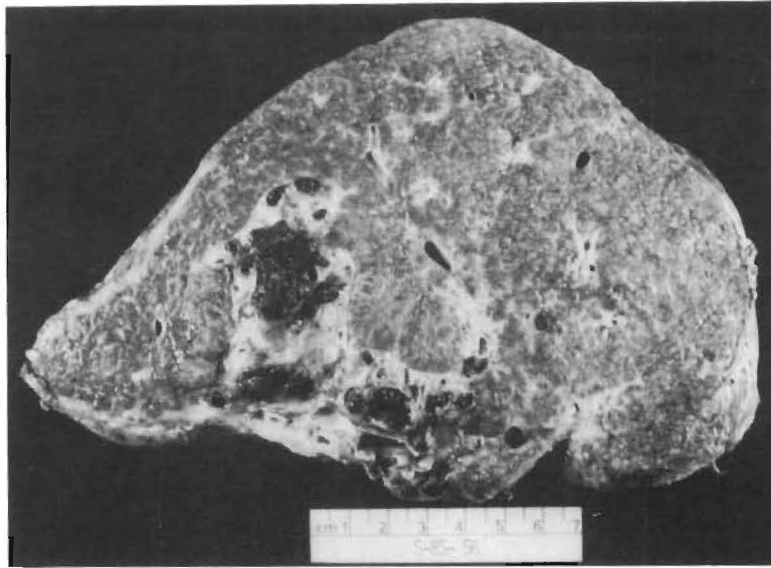
**FIG 31.** Mesenchymal hamartoma. Well-circumscribed mucoid-appearing lesion with central white scar tissue.

in a rich vascular background with large amounts of acid mucopolysaccharide, and varying degrees of chronic inflammatory cells. Vascular thrombosis with areas of infarction and hemorrhage may occur. Occasional islands of hepatocytes and extramedullary hematopoiesis are present. Mitoses are not seen, and neither recurrence following surgical resection nor malignant change has been reported.

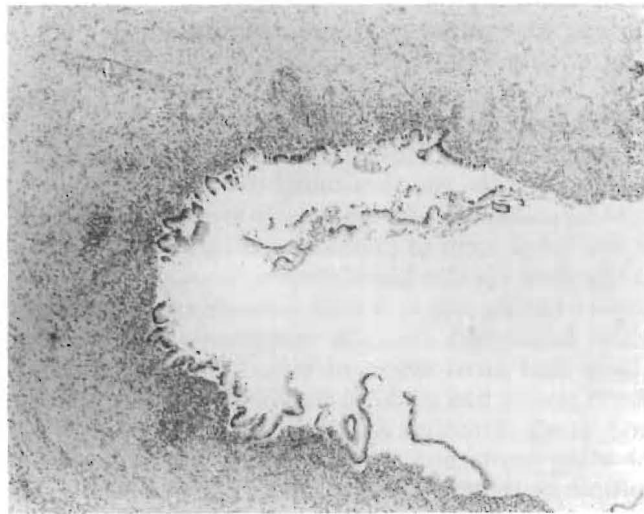
### *Congenital Cyst*

These may arise anywhere throughout the biliary tract, be single or multiple, and have congenital, traumatic, inflammatory parasitic, or neoplastic origins. The congenital or developmental cysts may be unilocular (solitary) or multiple (polycystic)—when they are usually associated with adult polycystic disease elsewhere (e.g., kidney). These cysts are usually lined by a flattened cuboidal epithelium. Other variants of congenital multiple cysts range from the common von Meyenberg complexes (small bile duct dilations), which may resemble multiple small metastatic deposits on the capsular surface of the liver, to the rare entities, Caroli's disease (Fig 32) and congenital hepatic fibrosis, which are characterized by a spectrum of dilated large bile ducts with associated bile inspissation, intraductal lithiasis, or surrounding fibrosis (Fig 33).

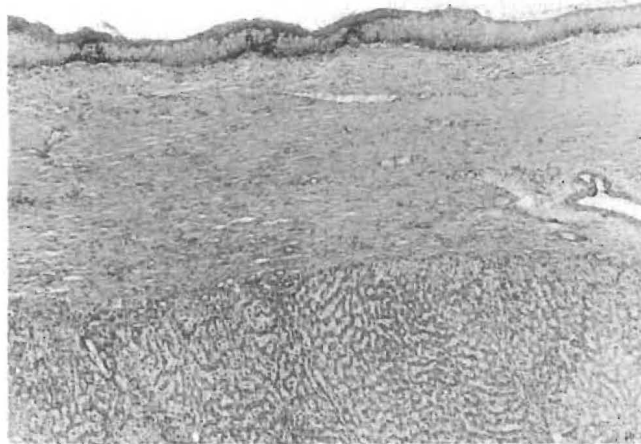
Cysts have also been noted to arise in the hepatic hilum and appear to represent dilations of the periductal glands possibly due to



**FIG 32.**  
Caroli's disease. Marked fibrosis of focally dilated intrahepatic biliary tree with numerous pigment stones and prominent biliary cirrhosis.



**FIG 33.**  
Caroli's disease. Dilated bile duct with partially denuded epithelial lining surrounded by secondary organized fibrosis and chronic inflammation. Hematoxylin-eosin;  $\times 50$ .



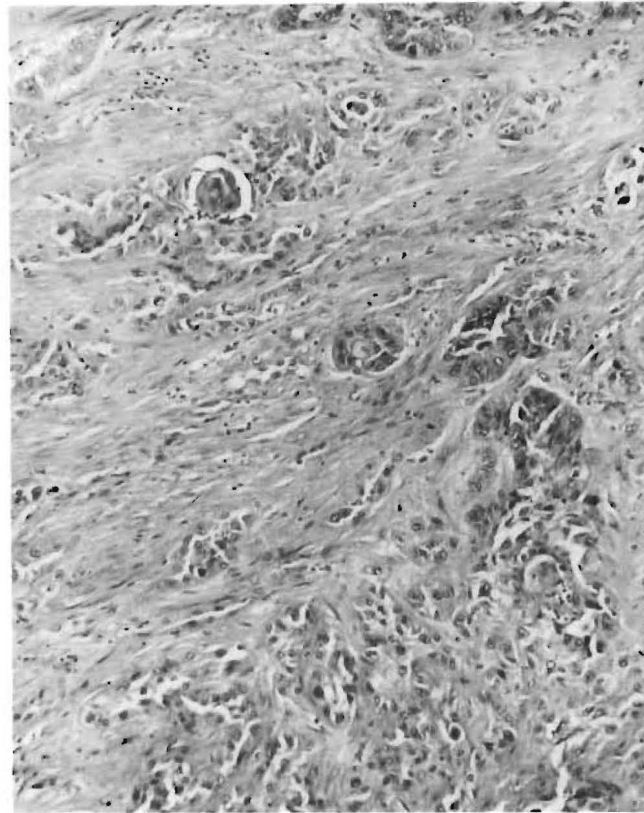
**FIG 34.** Squamous cyst of liver. Cyst is lined by mature squamous epithelium with subjacent fibrous wall separating it from liver parenchyma. Hematoxylin-eosin;  $\times 50$ .

inflammation. In these situations the cysts may be lined by nonciliated cuboidal to columnar epithelium. Metaplastic (Fig 34) and neoplastic transformation of these cystic lesions occurs and both cystadenocarcinoma as well as squamous carcinoma (Fig 35) have been described as arising from these congenital cysts.<sup>62-65</sup>

#### *Hydatid (Echinococcal) Cyst*

Echinococcosis is of worldwide distribution and may affect most organs within the body, the liver being the most frequently involved. Hydatid cyst formation in the liver is attributable to migration of the embryo of the larval form of *Echinococcus granulosus* from the duodenum to the liver via the bloodstream. Enclosed within the host's dense fibrous capsule, the cyst wall consists of an outer 1-mm thick, deathly white, laminated, anuclear membrane surrounding an inner germinal layer that gives origin to brood capsules that form protoscolices. Each scolex has suckers and hooklets, the latter being birefringent and easily demonstrable with acid-fast stains. The cyst enlarges, providing numerous evaginations of the wall with the formation of multiple generations of daughter cysts. As the brood capsules are shed into the cyst lumen they form a fine granular sediment known as hydatid sand.

The cysts are usually single but may be multiple. They usually occur in the right lobe, a feature that lends to their resectability. They may be large and even pedunculated from the liver substance, features that may increase the possibility of cyst rupture with conse-



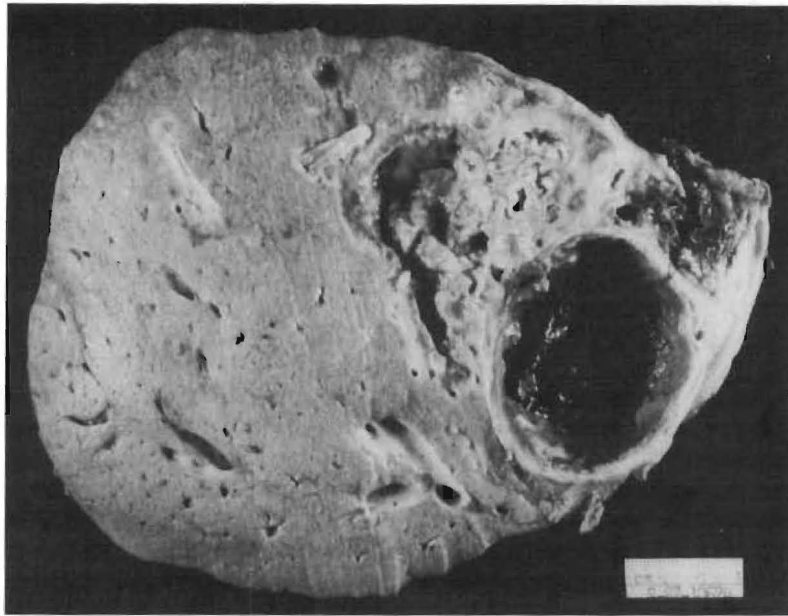
**FIG 35.**

Squamous cell carcinoma of liver. Irregular sheets of squamous epithelium with focal keratin pearl formation. Hematoxylin-eosin;  $\times 125$ .

quent severe, occasionally fatal, allergic reaction. Secondary infection may also cause rupture of the cyst into the biliary tree with cholangitis (Fig 36) or into the peritoneal cavity with extensive seeding and diffuse intraperitoneal cyst formation. The cyst wall may calcify, a feature of importance in the radiologic diagnosis of these lesions.

The preoperative diagnosis of hydatid cyst has been greatly facilitated by computerized tomography and ultrasonography. Specifically, liver biopsy is contraindicated in any patient in whom the diagnosis of hydatid disease is being considered because of the possibility of cyst content leakage with resultant anaphylactic reaction. Sclerosing cholangitis developing after surgical therapy for hydatid cyst has been reported.

*Echinococcus multilocularis*, which rarely infects humans, evokes no outer cyst wall, and as a result numerous small cysts form



**FIG 36.** Echinococcal cyst. Large cyst at right with contiguous smaller cysts embedded in fibrous tissue reflecting prior rupture of cyst.

throughout the entire liver. Many of these cysts, when they lose viability, evoke a foreign body giant cell reaction.

#### *MALIGNANT LESIONS*

##### *Metastatic Tumors*

Metastatic neoplasms are by far the most common hepatic malignancy, representing more than 95% of such neoplasms in autopsy series.<sup>66</sup> The most common primary sites are the pancreaticobiliary tree, breast, colon, skin, stomach, and lung. However, in the Western world metastatic carcinomas are most likely to have had their origin in lung, colon, breast, and pancreas because of the greater prevalence of these lesions in this geographic location.

The select subgroup of patients who are offered hepatic resection for metastatic disease have no metastases in other organs. The number and location of premetastatic lesions within the liver as well as the inherent biological behavior of the specific histologic tumor type determine resection. Pickren and associates<sup>66</sup> reported that malignancies arising in organs drained by the portal vein are more likely to show hepatic metastases and also are more likely to have metastases confined to the liver. These facts are among those contrib-



uting to the current emphasis on resecting colonic carcinoma metastases to the liver.

In our institution the isolated colonic metastasis in one or other lobe of the liver has been the most frequently resected metastatic lesion with neuroendocrine tumors a very distant second. Of the 153 metastatic carcinomas in our series 118 (77%) had primary origin in the colon, which contrasts with a relative frequency of 56% in autopsy series.<sup>66,67</sup>

The reasons for this difference are many. In patients with malignant disease who are evaluated at autopsy, as compared to those having liver resection, there is (1) a longer time for the development of liver metastases, (2) an increased likelihood of multiple liver metastases, (3) an increased period of time during which various types of carcinoma, including those with inherently poor prognoses could spread to the liver, and (4) the possibility of vital structure involvement that precludes any form of partial resection. For such reasons the resectability rates in patients with hepatic metastases are no greater than 25% to 30%.<sup>68,69</sup> There are valid reasons why select patients with metastatic neuroendocrine carcinoma/malignant carcinoid tumors may live for many years. Patients with colon carcinoma metastatic to a specific segment of the liver (Fig 37) have a long-term survival following resection.<sup>70-72</sup>

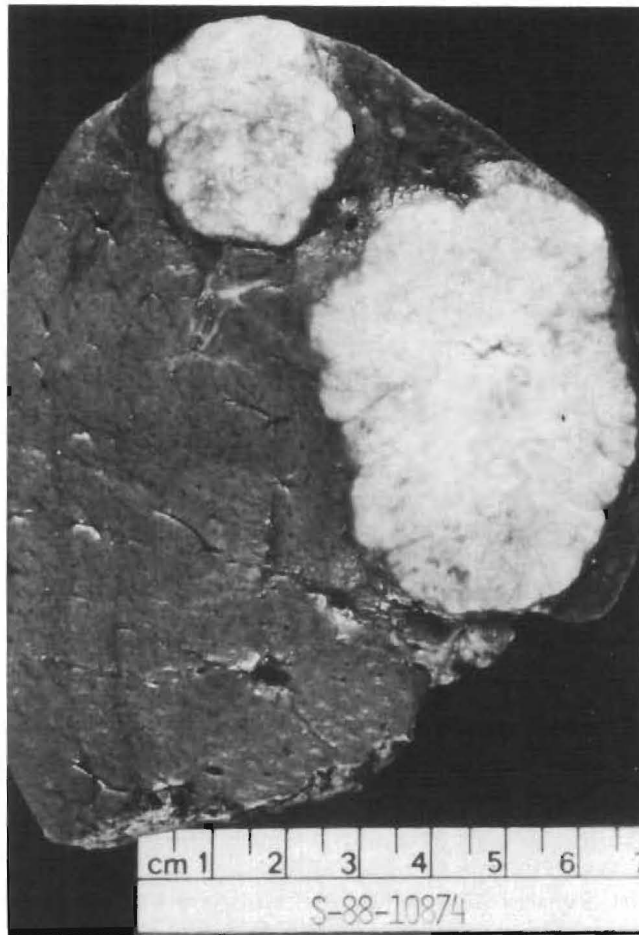
### *Hepatocellular Carcinoma*

This is the most common primary epithelial hepatic malignancy and represents up to 85% of such lesions.<sup>67</sup> There is a striking geographic variation in its distribution. It is relatively uncommon in the Western world but very frequent in South Africa, China, Japan, and Southeast Asia. The age of onset appears to be earlier (third to fifth decades) in areas of high incidence, compared with geographic areas of low incidence. There is a striking male predominance, especially in high-incidence areas.

The tumor may come to recognition because of the identification of a known etiologic factor. The theme common to most of these neoplasms is cirrhosis, attributable to a variety of chronic hepatic injuries, including viral hepatitis,<sup>73</sup> alcohol ingestion, and metabolic derangements.<sup>74</sup> Also, the consumption of aflatoxin, anabolic-androgenic steroids and possibly oral contraceptive steroids<sup>75</sup> has been suggested as being causative.

Tumor markers are used to diagnose hepatocellular carcinoma,<sup>76</sup> and improvements in the radioimmunoassay methods allow the detection of increased serum  $\alpha$ -fetoprotein levels in 80% of patients with hepatocellular carcinoma.<sup>77</sup>

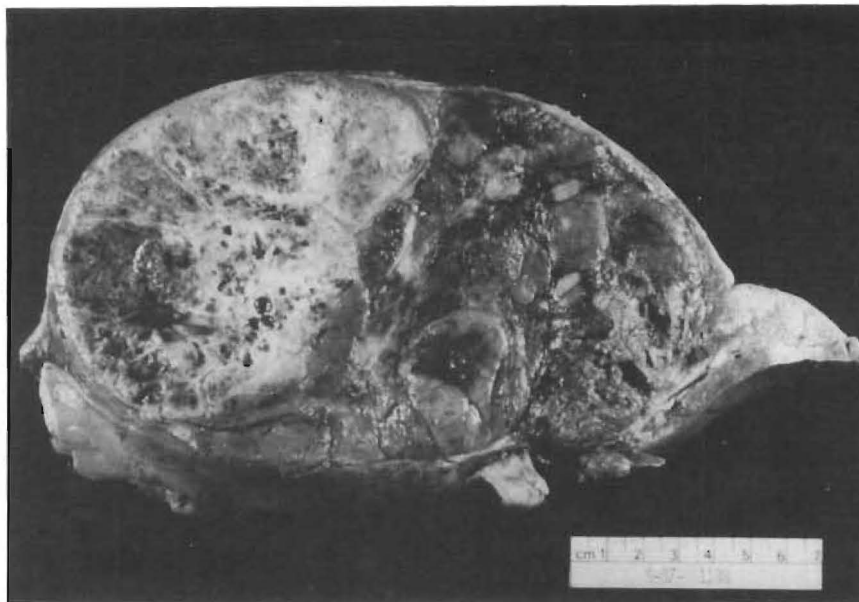Other diseases such as viral hepatitis, yolk sac tumors, gastric carcinoma, and pancreatic carcinoma,<sup>76,78,79</sup> as well as testicular teratomas, may be associated with increased levels of serum  $\alpha$ -fetopro-



**FIG 37.** Metastatic colon carcinoma. Two separate lesions, both abutting capsule. The resecting margin (*below*) is uninvolved by tumor.

tein. The value of other serum tumor markers in the diagnosis of hepatocellular carcinoma is being evaluated.<sup>80</sup>

Grossly the liver is enlarged and may be cirrhotic. The tumor is soft, necrotic, hemorrhagic, and focally bile stained. It occurs as a localized nodular mass, or it may be massive and involve an entire lobe (Fig 38). Rarely it occurs as a diffuse constellation of small nodules throughout the entire liver.<sup>81</sup> Another classification has been proposed by Okuda and associates<sup>82</sup> in a study of cases from Japan, South Africa, and the United States. They grouped cases into expanding, spreading, multifocal, and indeterminate categories and noted that the "encapsulated" variety was common in Japan but rare



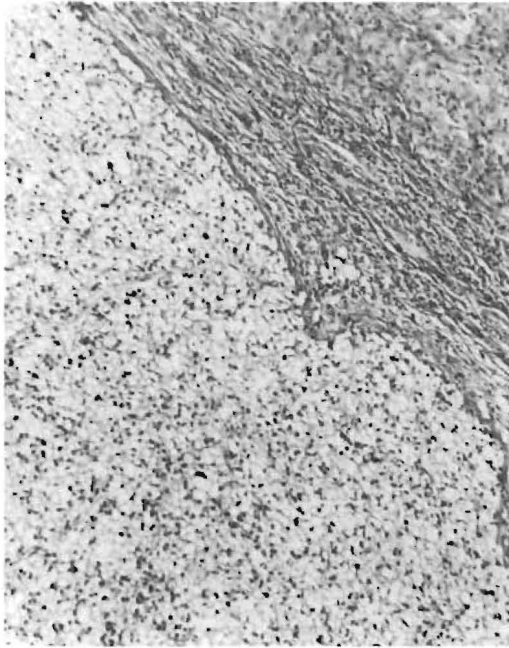
**FIG 38.**

Hepatocellular carcinoma. Large irregularly nodular tumor with multiple areas of hemorrhage, necrosis, cystic degeneration, and fibrosis.

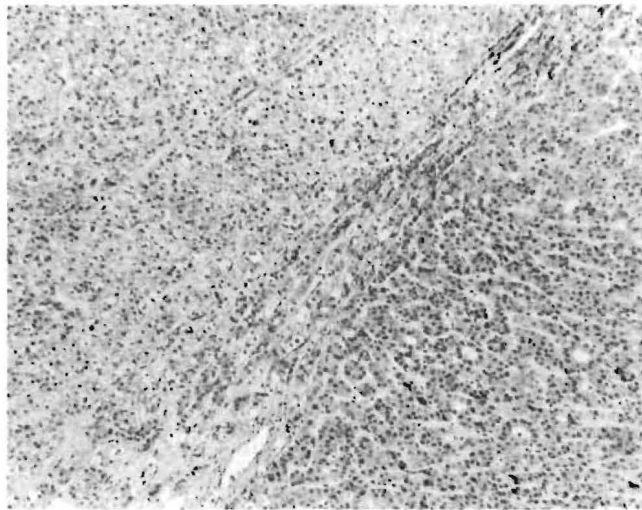
in the United States and South Africa. Invasion of the portal vein, hepatic vein, and bile duct may be noted, with occasional extension into the inferior vena cava and the right atrium.<sup>83</sup>

Microscopically this tumor may show a variety of histologic patterns occurring in the same tumor. The most frequent is that of trabecular growth, in which irregularly sized sheets of malignant hepatocytes are separated from one another by sinusoidal type spaces lined by endothelial cells. The stromal component, other than that attributable to scar, is minimal, hence their soft gross appearance. Bile canaliculi may be seen on routine stains and confirmed immunohistochemically.<sup>84</sup> The presence of bile within tumor cells is pathognomonic of this tumor. Vascular invasion is extremely frequent. The diminished to absent reticulin framework seen in this tumor is not evident in normal liver or benign hepatocellular lesions and is very valuable in the differential diagnosis of these hepatic lesions.<sup>85</sup>

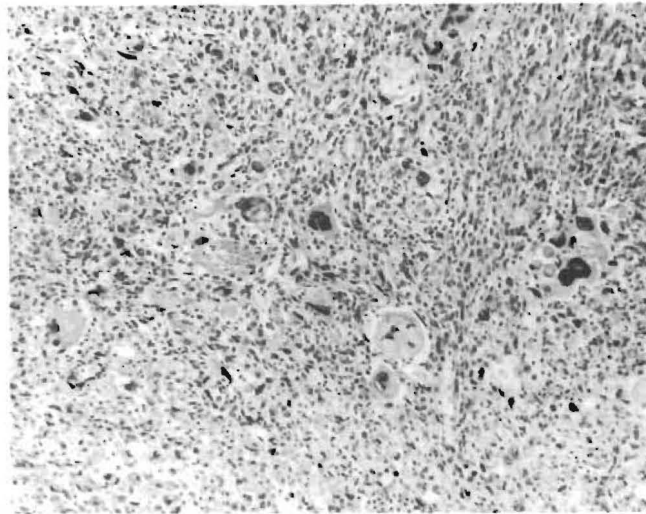
The malignant hepatocytes have defined cell borders, granular pink cytoplasm, and round to oval nuclei with prominent nucleoli. Clear cells (attributable to their fat or glycogen content) and pseudoglandular or adenoid areas are frequent (Figs 39 and 40). The degree of pleomorphism may be minimal or marked, with bizarre atypical giant cells and spindle cells (Fig 41). These various histo-



**FIG 39.** Hepatocellular carcinoma, clear cell type. This lesion must be differentiated from other clear cell carcinomas, especially renal and adrenal. Hematoxylin-eosin;  $\times 125$ .



**FIG 40.** Hepatocellular carcinoma. Two types of differentiation are present. The lower right shows trabecular and pseudoglandular (adenoid); the upper left shows clear cell differentiation. Hematoxylin-eosin;  $\times 125$ .



**FIG 41.**  
Hepatocellular carcinoma, giant cell type. Hematoxylin-eosin;  $\times 125$ .

logic patterns of hepatocellular carcinoma expand its differential diagnosis to include spindle cell neoplasms of soft tissue, whether primary or metastatic in the liver, as well as renal and adrenal carcinomas.

The identification of typical areas of hepatocellular carcinoma, the presence of immunohistochemically detectable  $\alpha$ -fetoprotein within tumor cells, and the elevated levels of this protein in the serum remain the best means of establishing the diagnosis of hepatocellular carcinoma. Immunohistochemical studies have shown the nonspecific presence of a variety of other antigenic components within malignant hepatocytes. Most of these antigens except for those of hepatitis B virus are equally commonly expressed in the ordinary and fibrolamellar variants of hepatocellular carcinoma.<sup>54</sup> Hepatitis B viral surface and core antigens are specifically but not commonly encountered in the ordinary variant and do not appear to be significantly expressed in the fibrolamellar variant of hepatocellular carcinoma.<sup>54</sup>

Other histologic features of hepatocellular carcinoma are the presence of intracellular Mallory's hyaline, hyaline globules, fat, glycogen, and a ground glass cellular appearance. With the exception of Mallory's hyaline, these features are nonspecific and can be seen in a variety of other tumors.

There are other histologic variants of hepatocellular carcinoma. They include the fibrolamellar and sclerosing variants, both of which have been recognized most frequently in the United States, and the so-called mixed hepatocellular cholangiocarcinoma, which is best

considered as a hepatocellular carcinoma with focal areas of mucin producing adenocarcinoma and behaves as the former (Fig 42). In much the same manner some hepatocellular carcinomas may show focal neuroendocrine differentiation, but too few of these lesions have been described to allow assessment of their behavior.

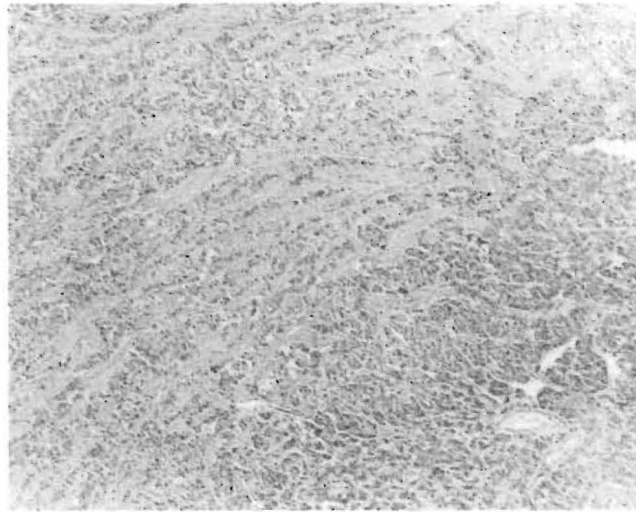
Areas of either large cell or small cell dysplasia appear to be associated with an increased risk of developing hepatocellular carcinoma, but the relationship is not considered established.

Hepatocellular carcinoma commonly metastasizes to lung, regional lymph nodes, and contiguous organs but rarely to other organs.

#### ***Fibrolamellar Hepatocellular Carcinoma***

This recently popularized variant of hepatocellular carcinoma<sup>86, 87</sup> was first recognized by Edmondson in 1956. Since then more than 150 cases have been reported.<sup>86</sup> This variant has been noted in the United States and Europe but seems to be rare elsewhere.

Fibrolamellar hepatocellular carcinoma has many eponyms, such as eosinophilic hepatocellular carcinoma with lamellar fibrosis, polygonal cell type with fibrous stroma, and fibrolamellar oncocytic hepatoma. The tumor is distinguished from the ordinary variant of hepatocellular carcinoma by its frequent occurrence in young patients, the lack of male predominance, characteristic morphological find-



**FIG 42.**

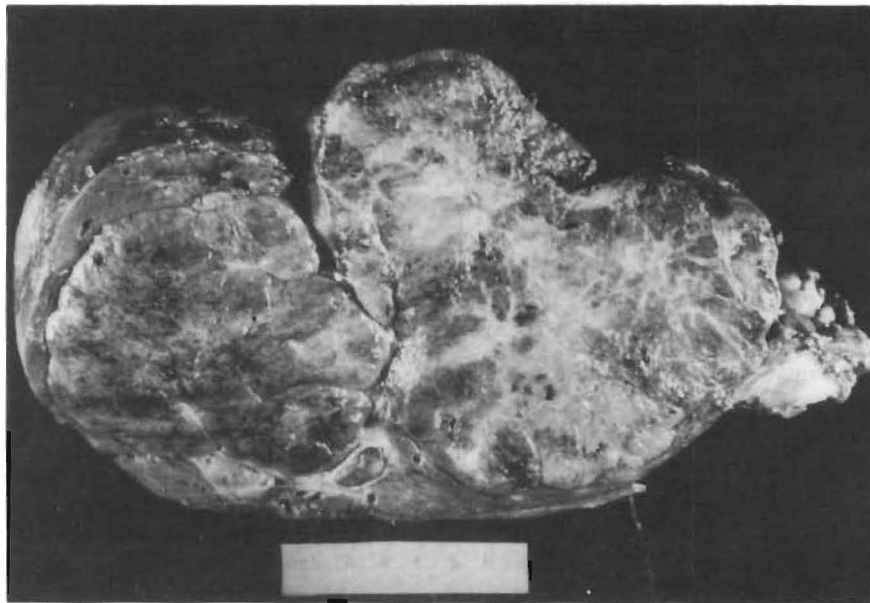
Hepatocellular carcinoma. Two types of differentiation are present: the lower right shows trabecular tumor; the upper left shows focal glandular differentiation. Hematoxylin-eosin;  $\times 50$ .

ings in which large eosinophilic (oncocytic) hepatocytes lie in a lamellated fibrous stroma, the lack of a significant association with cirrhosis, and its favorable prognosis.

The relationship between this tumor and oral contraceptive use remains controversial. In a recent study from this institution elevated serum  $\alpha$ -fetoprotein levels and demonstrable immunohistochemical localization of  $\alpha$ -fetoprotein in tumor cells was noted in 4 (21%) of 19 cases, a lower incidence than noted with the more common variant of hepatocellular carcinoma. Elevated vitamin B<sub>12</sub> binding capacity levels have been claimed to be specific for this tumor.<sup>88</sup>

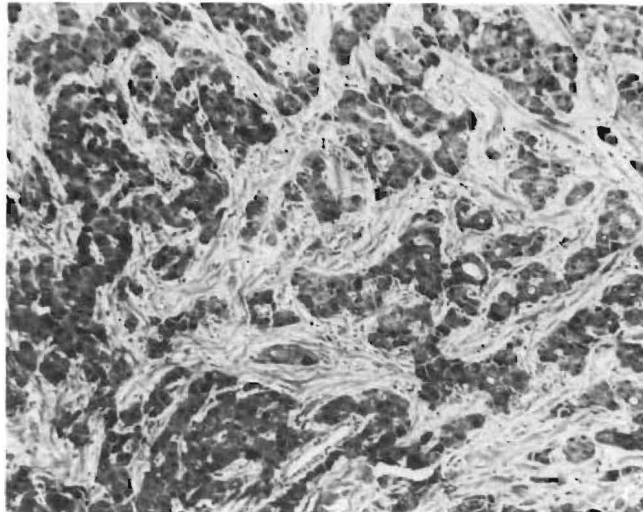
Grossly the tumor is a solitary, well-circumscribed, firm mass of variable size, with a nodular gray, green, white color on cut surface and a central stellate scar reminiscent of focal nodular hyperplasia (Fig 43).

Microscopically the tumor is composed of parvicellular hyalinized laminated collagen bundles which separate irregularly sized groups of eosinophilic, granular hepatocytes (Fig 44) (which show abundant mitochondria ultrastructurally). The cytoplasm also shows abundant hyaline globules, bile, copper and copper-associated protein, fibrinogen, C-reactive protein, ferritin and  $\alpha_1$ -antitrypsin.<sup>54,89</sup> The nuclei



**FIG 43.**

Fibrolamellar hepatocellular carcinoma: Large (20-cm) tumor arising in normal liver (*top left*) with extensive radiating scar formation (*center right*).



**FIG 44.** Fibrolamellar hepatocellular carcinoma. Large oncocytic hepatocytes in irregular cords separated by acellular lamellated collagen. Trichrome;  $\times 125$ .

are round, oval and vesicular with prominent nucleoli. Occasionally marked nuclear hyperchromatism and pleomorphism are seen.

This tumor may have foci of ordinary variant hepatocellular carcinoma but must also be distinguished grossly and microscopically from other tumors such as focal nodular hyperplasia, sclerosing hepatocellular carcinoma, and metastatic neuroendocrine carcinoma.<sup>90</sup>

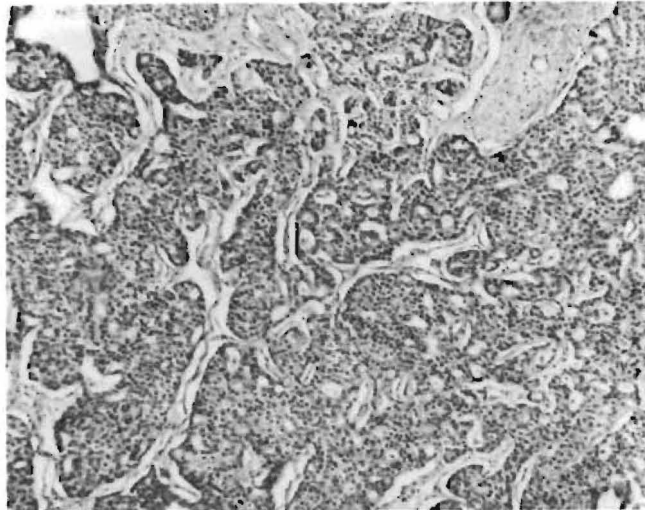
Fibrolamellar hepatocellular carcinoma is more amenable to resection than the ordinary variant, and the results of such therapy are much more favorable even when known metastases are present at the time of surgery.<sup>91</sup>

#### *Neuroendocrine Carcinoma*

These tumors have been reported both in children and adults.<sup>92, 93</sup> Some show apparent divergent differentiation patterns manifesting hepatocellular or cholangiocarcinomatous patterns, or both, together with a neuroendocrine pattern of malignancy.<sup>94</sup> It is difficult to prove the primary hepatic origin of such tumors, and good practice dictates that such an origin be ascribed only after exhaustive search has excluded an extrahepatic source for the tumor.

This is an important entity to differentiate from hepatocellular carcinoma in particular. They frequently are firm white to yellow on gross appearance and they show cellular monotony with a frequent palisading pattern at the periphery of tumor cell trabeculae histologically (Fig 45). Their true nature is readily confirmed by positive





**FIG 45.** Neuroendocrine carcinoma. Note palisading fibrovascular stroma and uniform appearance of epithelial cells. Hematoxylin-eosin;  $\times 125$ .

grimelius and chromogranin staining as well as by the characteristic appearances of neurosecretory granules on ultrastructural examination.

#### ***Cholangiocarcinoma***

This tumor is extremely rare in childhood. It occurs most frequently in patients who are older than 50 years, and it has equal sex distribution. The tumor may occur anywhere in the biliary tree, and its presentation reflects the specific site and extent of tumor occurrence. *Intrahepatic* tumors are usually peripheral and represent less than 25% of all primary malignant liver tumors.<sup>95</sup> Classically these tumors are rock hard and gray-white with irregular infiltrating edges and multiple satellite nodules. Vascular invasion is present in less than 20% of cases, but 70% to 75% of patients have metastases to regional nodes, lung, or bone. The major difficulty with this tumor is its pathologic distinction from metastatic adenocarcinoma arising in the pancreas, biliary tract, and other organs.

The diagnosis of primary cholangiocarcinoma can only be established after other primary sources have been excluded. A sometimes helpful feature is the presence of intraductal in situ carcinoma. However, we have seen partial replacement of a bile duct by metastatic colon adenocarcinoma which closely resembled the pattern of in situ cholangiocarcinoma. Inflammatory reactive epithelial changes, including those seen with sclerosing cholangitis may be confused with cholangiocarcinoma.

Cholangiocarcinoma has been associated with a variety of etiologic factors such as thorotrast,<sup>96</sup> sclerosing cholangitis associated with inflammatory bowel disease,<sup>97,98</sup> choledochal cysts, and, in appropriate geographic regions, Clonorchis infestation. Patients with chronic ulcerative colitis have a significantly greater risk of developing cholangiocarcinoma, usually at a younger age than these tumors most often occur.

*Extrahepatic* tumors are more frequent than intrahepatic lesions, but nevertheless account for less than 2% of surgical operations on the bile duct. We include the hilar (Klatskin) tumor with extrahepatic tumors, even though many of these tumors are "hidden" within the liver substance, because its presentation is similar to that occurring with the more distal biliary tract tumors.<sup>99</sup>

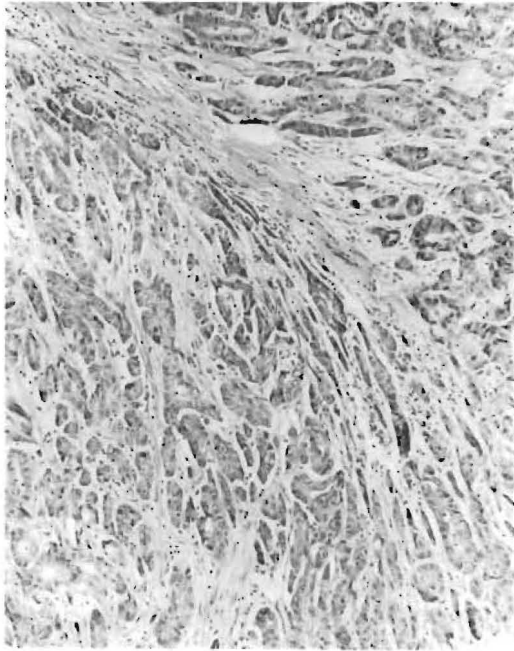
The recognized etiologic factors are similar to those seen with intrahepatic cholangiocarcinoma. If cirrhosis is present it is usually a biliary cirrhosis secondary to obstruction. Grossly the tumor may appear as a gray-pink, friable, intraductal papillary lesion or more frequently as a sclerosing white, nodular lesion extending along varying lengths of the thickened duct wall with consequent narrowing of the duct lumen. The tumor frequently extends into adjacent soft tissue and may surround or invade the portal vein or hepatic artery.

Some of the major problems with the tumor relate to (1) the difficulty in determining its extent both grossly and microscopically, (2) recognition that the disease may be multicentric throughout the biliary tree, and (3) the difficulty in distinguishing between inflammatory regenerative epithelial changes and true neoplasia on frozen section examination. The latter is probably one of the most difficult areas of surgical pathology and requires maximal cooperation and understanding between pathologist and surgeon.

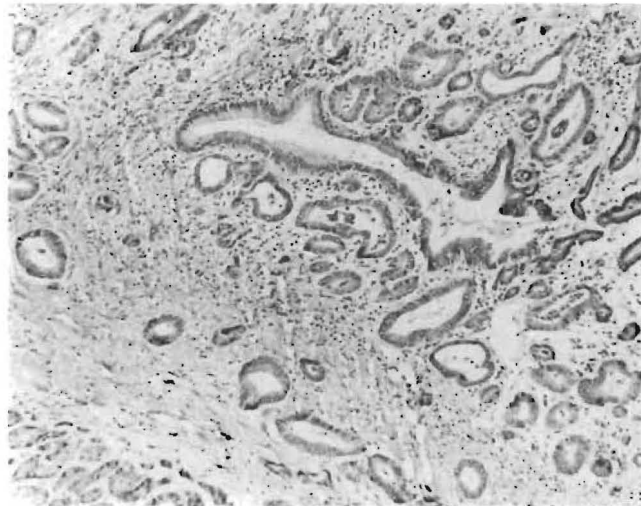
Microscopically the lesion is a mucin-producing, well-differentiated adenocarcinoma.<sup>100</sup> Rarely, squamous cell differentiation is encountered. The superficial regions of the tumor may show papillary features and the deeper regions may manifest poorly differentiated tumor. Cytologic examination of aspirates or duct scrapings has been of significant diagnostic value.<sup>101</sup> In association with its extensive desmoplastic reaction (Fig 46) the tumor shows the helpful diagnostic features of neural, venous, and lymphatic invasion as well as areas of necrosis. Areas of in situ carcinoma (Fig 47), dysplasia and metaplasia, intestinal as well as antral types, are frequently noted in areas contiguous to the carcinoma. Metastases are noted in approximately 50% of cases and are usually limited to regional lymph nodes and the liver. Involvement of more distant organs is rare.

### *Hepatoblastoma*

This malignant tumor occurs in the first few years of life and is slightly more frequent in males.<sup>102</sup> It usually presents as an upper



**FIG 46.**  
Infiltrating cholangiocarcinoma. Note marked desmoplasia and irregular gland formation. Hematoxylin-eosin;  $\times 125$ .

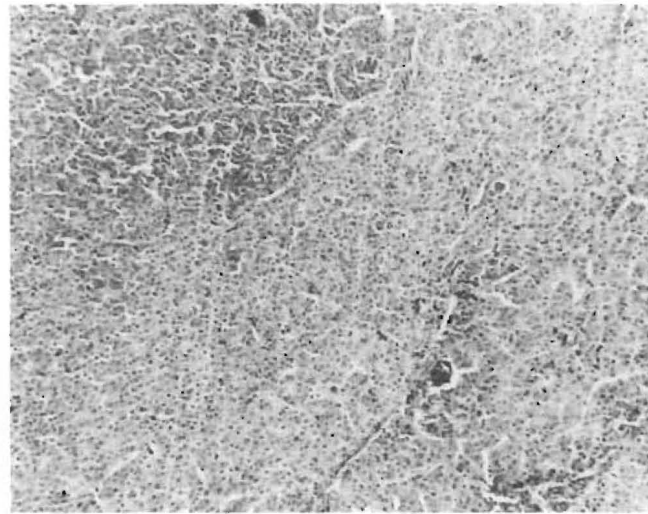


**FIG 47.**  
Cholangiocarcinoma, in situ and infiltrating. Note the normal appearance of left side of largest duct with abrupt change to neoplastic epithelium on the right. The infiltrating glandular component with prominent desmoplasia is evident. Hematoxylin-eosin;  $\times 125$ .

abdominal mass. Grossly the tumor appears as a well-circumscribed, lobulated, solitary, tan mass frequently in the right lobe of an otherwise normal liver.<sup>102, 103</sup> These features contribute to the relative ease of hepatic resection of this tumor; however, the surgeon should take a wide margin because microscopic intravascular spread beyond the grossly discernible tumor mass is not infrequent.

Microscopically this tumor has been recognized as a pure epithelial or as a mixed mesenchymal and epithelial type of malignancy.<sup>102</sup> The epithelial elements are fetal or embryonal cells, or both (Fig 48). The fetal cells are smaller than normal hepatocytes with minimal pleomorphism, rare mitoses, and clear or amphophilic cytoplasm. The cells are arranged in narrow cords or broad sheets. The embryonal cells occur in sheets and trabeculae and show larger, more pleomorphic nuclei, more frequent mitoses, and less cytoplasm, which gives the impression of a darker staining, more densely packed cell population. Occasional ductular differentiation is noted,<sup>104, 105</sup> and extramedullary hematopoiesis is almost always present.

The mesenchymal elements occur in up to 50% of hepatoblastomas<sup>102, 103</sup> and are small immature spindle cells, occurring in immediate relationship to the epithelial elements. Osteoid formation may be seen within the immature stromal or epithelial tissues; more rarely, cartilaginous or rhabdomyoblastic stromal differentiation occur.<sup>103, 105</sup>



**FIG 48.**

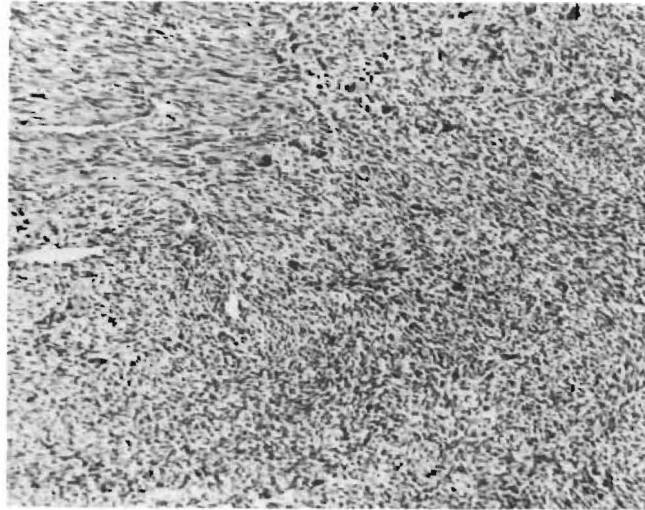
Hepatoblastoma. The darker embryonal cells are present at top left; the paler fetal cells are present throughout the remainder of the picture. Hematoxylin-eosin;  $\times 125$ .

The importance of resection is reflected in the fact that cure may be achieved in 30% to 50% of patients if the tumor is totally resected.<sup>106, 107</sup> In addition, cases in which the tumor was initially considered unresectable have been rendered resectable by preoperative chemotherapy.<sup>108, 109</sup> Unfavorable features associated with poor prognosis are the presence of multiple tumors or nodal metastases.<sup>110</sup> Provided it is completely resectable, the size of the primary tumor is not of prognostic significance. A favorable prognostic feature is fetal differentiation in contrast to the poor prognosis associated with embryonal or undifferentiated histologic types.<sup>103</sup>

Most hepatoblastomas, especially those showing histologic differentiation, will manifest increased serum levels of  $\alpha$ -fetoprotein. Other than hepatocellular carcinoma the only other primary hepatic tumors to be associated with markedly increased levels of  $\alpha$ -fetoprotein are the mesenchymal hamartoma<sup>111</sup> and rarely, yolk sac carcinoma.<sup>112</sup>

### SARCOMAS

These are much less common than carcinoma, whether they occur as primary or metastatic lesions.<sup>113</sup> The primary source of metastatic sarcoma in the liver is usually obvious. Of the primary tumors, angiosarcoma is the most common. Specific sarcomata such as leiomyosarcoma<sup>114</sup> appear to lend themselves more readily than others to hepatic resection (Fig 49). In our series almost half of both the pri-



**FIG 49.**

Leiomyosarcoma of liver. The top left corner shows well-differentiated tumor; the remainder is undifferentiated. Hematoxylin-eosin;  $\times 125$ .

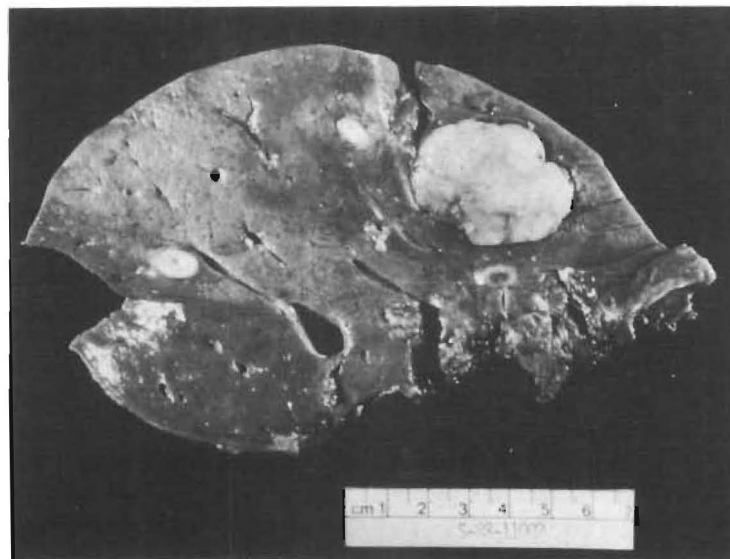
mary and the metastatic sarcomas were of smooth muscle origin. Although sarcomas of the liver are exceedingly rare, Chen<sup>114</sup> described 15 cases of primary leiomyosarcoma of the liver. Other reports of fibrosarcoma<sup>115</sup> and malignant fibrous histiocytoma<sup>116</sup> of the liver have also appeared.

Metastatic leiomyosarcoma to the liver (Fig 50) is most frequently of uterine, gastric, or intestinal origin. Sarcomas arising elsewhere usually spread first to lung and subsequently to liver.<sup>117</sup>

#### *Angiosarcoma*

This tumor is the most common mesenchymal neoplasm of the liver and occurs at all ages, with a mean age in the sixth decade.<sup>118</sup> It is more common in men and has a dismal prognosis—affected patients rarely survive beyond 2 years. The incidence of this tumor appears to have increased in recent decades, reflecting its recognized association with known etiologic agents such as thorotrast, vinyl chloride, arsenic, and anabolic steroids.<sup>118, 119</sup> Patients with such exposure have latent periods in excess of 20 years before the tumor is apparent. They also have associated hepatic fibrosis.

Grossly the tumor is most frequently multicentric and involves both lobes. The tumor nodules are of varying size, are irregular in outline and appear spongy. The contiguous liver may be fibrotic and thorotrast deposits may be noted in the subcapsular region and in regional lymph nodes.



**FIG 50.** Metastatic leiomyosarcoma of colon. Multiple irregular tumor nodules without specific distinguishing features. The resection margin (*lower right*) is not involved by tumor.

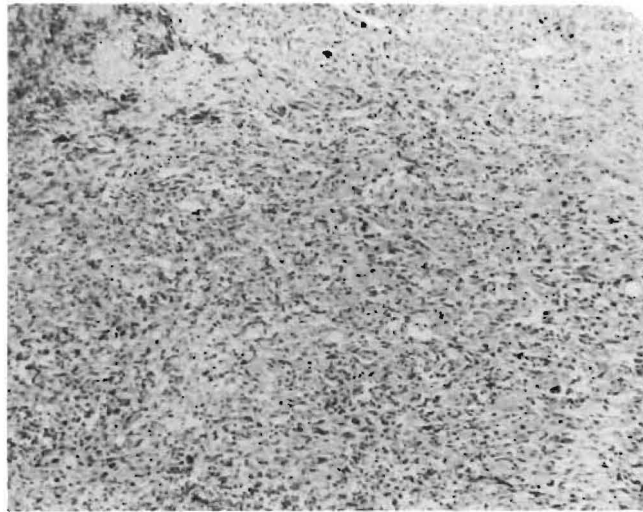
Microscopically the liver is composed of pleomorphic bizarre endothelial cells (Fig 51) which stain positively for factor VIII-related antigen (Table 1). There are varying numbers of mitoses. Sinusoidal dilatation with atrophy of hepatocytes associated with nodules of spindle and/or epithelioid cells separated by a delicate reticulin framework may be seen. There is little collagenous stroma, areas of hemorrhage and necrosis are common, and vascular invasion (portal and hepatic vein) is frequent.

Metastases occur to the lungs, bones, lymph nodes, spleen, and adrenal gland, but most deaths are attributable to liver failure or hemorrhagic complications. The median survival is less than 6 months.<sup>118</sup> To date surgery and chemotherapy have had little to offer.

#### *Epithelioid Hemangioendothelioma*

This malignant vascular tumor has been recently described in soft tissue,<sup>120</sup> lung,<sup>121</sup> and liver.<sup>122, 123</sup>

Grossly the lesion consisted of multifocal round to oval, white, firm nodules with hyperemic borders, which range in size up to 5.0 cm and are irregularly distributed throughout the entire liver (Fig 52). The nodules often extend to the capsule. The liver parenchyma is normal unless obstruction with secondary biliary cirrhosis occurs. Similar lesions may be seen in regional lymph nodes and in distant



**FIG 51.**

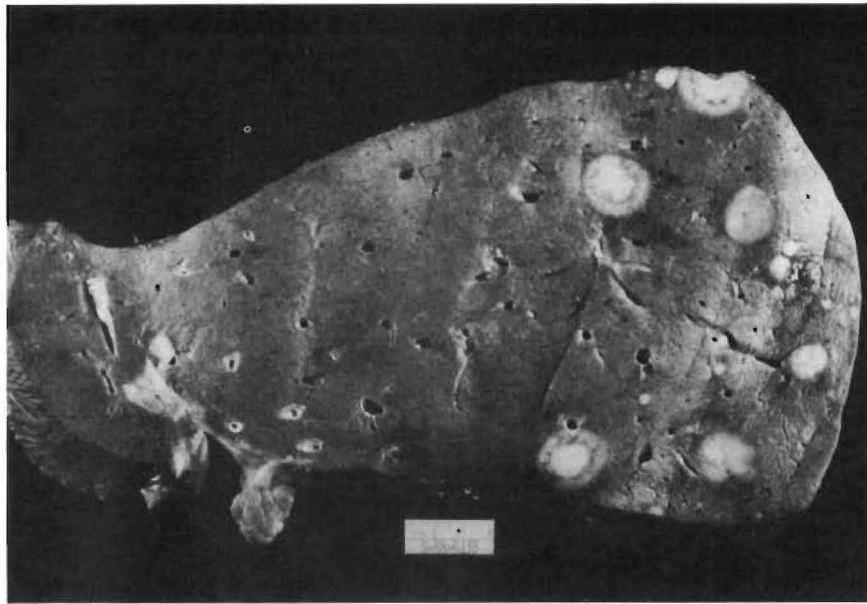
Angiosarcoma of liver. Irregular anastomosing channels lined by pleomorphic endothelial cells that also infiltrate into sinusoids between liver plates. Darker material at top left is thorotrast. Hematoxylin-eosin;  $\times 125$ .

**TABLE 1.**  
Immunohistochemical Findings in Liver Sarcomas

Type of Sarcoma	Myoglobin	Actin Myosin	Desmin	Vimentin	Factor VIII	$\alpha$ -antitrypsin
Embryonal rhabdomyosarcoma	+	+	+	+	-	+
Embryonal sarcoma	-	?	-	+	?	+
Leiomyosarcoma	-	+	+	+	-	-
Epithelioid hemangioendothelioma	?	?	?	?	+	-
Angiosarcoma	-	-	-	+	+	-

(Globules)





**FIG 52.**

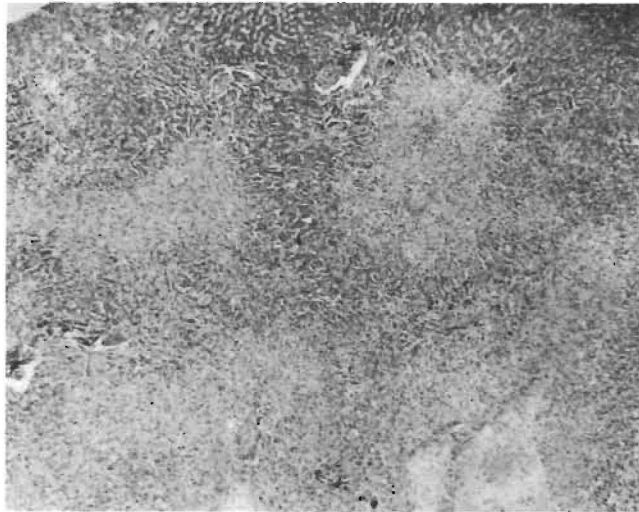
Epithelioid hemangioendothelioma. Multiple discrete nodules of varying size with surface umbilication occurring in otherwise normal liver.

organs. Microscopically the nodules show a parvicellular myxoid fibrous center with a relatively hypercellular periphery (Fig 53). The cells are of two types; dendritic and epithelial, the latter growing preferentially in vascular spaces.

Many cells showed vacuoles that are vascular spaces. The growth pattern appears centrifugal, with tumor cell extension along the portal vein and sinusoids, and hepatic venules in particular. Because of these histologic features this tumor has been misinterpreted in the liver as cholangiocarcinoma, sclerosing hepatocellular carcinoma, sclerosing angiosarcoma, or metastatic adenocarcinoma.

Immunohistochemically the tumor cells manifest factor VIII related antigen consistent with its vascular nature (see Table 1). Studies from this laboratory<sup>124</sup> have demonstrated the presence of von Willebrand factor antigen in tumors that have not manifested late recurrence, but not in those that have recurred extrahepatically.

The prognosis of patients with this tumor is unpredictable. It is not amenable to partial hepatic resection, but has been successfully treated with total hepatectomy and liver transplantation despite the presence of recognized extrahepatic tumor nodules.<sup>125</sup>



**FIG 53.** Epithelioid hemangioendothelioma. Irregular centriacinar extension of tumor around periportal zones (*top central*) with less cellular tumor in deeper regions (*bottom right*). Hematoxylin-eosin;  $\times 50$ .

### ***Embryonal Rhabdomyosarcoma***

This tumor develops in the extrahepatic biliary tree and is the most common bile duct tumor in children. It rarely occurs in adults.<sup>126, 127</sup> No sex predilection has been noted.

Grossly the tumor shows a white cut surface, thickening of the bile duct wall with narrowing of the lumen and projection of gelatinous grapelike (botryoid) masses into the duct lumen. These changes cause dilatation of the proximal biliary tree and green discoloration of the liver due to cholestasis.

Histologically, the tumor is covered by flattened biliary epithelium that may be ulcerated. The superficial subepithelial region of the tumor is densely cellular and is called the "cambium layer." The deeper areas of the tumor are less cellular and show a prominent myxoid stroma.

The tumor cells are primitive and round, spindle or racquet shaped with dense cytoplasmic eosinophilia indicative of rhabdomyoblasts. Cross striations are difficult to visualize and mitoses are of varying frequency.

Immunohistochemically the tumor cells may manifest myoglobin, myosin, desmin, or vimentin (see Table 1). The former is the most valuable marker, having been seen in the majority of tumors.<sup>128, 129</sup> The ultrastructural finding within some tumor cells of alternating actin and myosin filaments, occasionally showing a banding pattern, is also of diagnostic value.<sup>127, 130</sup>

### ***Embryonal Sarcoma***

This tumor is most frequently seen in children between 6 and 10 years of age.<sup>131</sup> It rarely occurs in adults.<sup>132, 133</sup>

The tumor is usually single, circumscribed, large, globular, fluctuant and may contain gelatinous, cystic, necrotic or hemorrhagic areas. Histologically it is composed of spindle and stellate cells, which are occasionally markedly atypical and multinucleate, and rest in a myxoid stroma. The tumor cells frequently show D-PAS-positive globules that stain for  $\alpha_1$ -antitrypsin (see Table 1). It is possible that they may also stain for other cell products such as fibrinogen if they resemble the globules seen in other liver tumors.<sup>54</sup>  $\alpha$ -Fetoprotein has not been demonstrated in these globules to date.<sup>134</sup> No divergent mesenchymal differentiation has been noted. Irregularly dilated bile duct elements may be seen at the tumor periphery and probably represent entrapped tissue, but no true malignant epithelial elements are present.<sup>131</sup> Patients with these tumors may survive following complete resection of the tumor; otherwise survival beyond 1 year is not commonly seen. It is of interest that in a recent series of patients with embryonal sarcoma and embryonal rhabdomyosarcoma the shortest survivals were in those who did not undergo tumor resection.<sup>135</sup>

### **OUR EXPERIENCE WITH HEPATIC RESECTION**

Our interest in hepatic resection started with the referral for liver transplantation of patients whose hepatic lesions were thought to be too extensive for subtotal hepatectomy (hepatic resection) and who would require total hepatectomy with liver replacement (orthotopic liver transplantation). Many of these tumors could be removed only by most extensive resections, such as right and left trisegmentectomy. This is the reason why more than one third of our patients were treated with trisegmentectomies, and our experience may not reflect the overall picture of surgery for hepatic tumors. Nevertheless, our aggressive approach to various hepatic lesions is worthwhile reporting because of the low operative mortality and morbidity, and the satisfactory results. Portions of our experience have been reported earlier.<sup>30-32, 135-141</sup>

### **CASE MATERIAL**

During a 25-year period, from October 1964 to September 1988, 473 patients underwent hepatic resection at the University of Colorado Health Sciences Center (1964 to 1980) and the University Health Center of Pittsburgh (1981 to 1988). The number of hepatic resections has increased sharply through the years (Table 2), and 500 patients will be included in our series by the end of 1988.

**TABLE 2.**

Hepatic Resection by 5-Year Period and Indication

Years	No. of Patients	Benign Lesion	Primary Malignancy	Secondary Malignancy
(1964)*-1970	6	4	2	0
1971-1975	25	10	10	5
1976-1980	77	32	17	28
1980-1985	181	87	43	51
1986-(1987)†	184	64	51	69
<b>Total</b>	<b>473</b>	<b>197</b>	<b>123</b>	<b>153</b>

( )\* = Starts in October.  
( )† = Ends in September.

Ages of the patients ranged from 11 months to 81 years. Twenty-seven of the 473 patients were younger than 18 years, and 24 of these 27 were younger than 12 years.

Indications for hepatic resection on 473 patients are listed in Table 2. There were 197 patients with benign hepatic lesions who underwent hepatic resection for therapeutic purposes or because malignancy could not be ruled out preoperatively. The remaining 276 patients had hepatic resection for malignant diseases, of which 123 tumors were primary to the liver and 153 were metastases to the liver from various origins (see Table 2).

The kinds and numbers of hepatic resections for benign lesions, primary hepatic malignancy and metastatic tumors are summarized in Table 3, including the operative mortality of each group. As mentioned previously, extended right and left lobectomy were classified as right and left lobectomy in this report.

#### POSTOPERATIVE MORTALITY

Any death within a month after hepatic resection was counted as an operative death. Sixteen of 473 patients died within a month after various kinds of hepatic resection, for an overall operative mortality of 3.4%. Details of the operative mortality after various kinds of hepatic resection for different indications are summarized in Tables 3 and 4. The operative mortality was 5.5% (9 of 163) after trisegmentectomies, 3.3% (6 of 183) after lobectomies and 0.8% (1 of 127) after left lateral segmentectomies and non-anatomical local resections. The operative mortality after hepatic resection for primary hepatic malignancy was considerably higher, 9.8% (12 of 123), than that after resection of metastatic tumors, 0% (0 of 153), and than that after resection of benign hepatic lesions, 2.0% (4 of 197).

Nineteen of the 473 patients had severe cirrhosis. The operative mortality in these 19 patients was 37% (7 of 19). In contrast the mor-

**TABLE 3.**

Indications, Extent of Resection, and Operative Mortality in 473 Patients\*

	Right Trisegmentectomy		Left Trisegmentectomy		Right Lobectomy		Left Lobectomy		Left Lateral Segmentectomy		Local Excision		Total
	No. of Patients	No. of Patients	No. of Patients	No. of Patients	No. of Patients	No. of Patients	No. of Patients	No. of Patients	No. of Patients	No. of Patients	No. of Patients	No. of Patients	
Primary malignancy	55 (5)	11 (2)			22 (4)		20 (0)		4 (0)		11 (1)		123 (12)
Hepatocellular carcinoma	32 (2)	6 (1)			18 (1)		12 (0)		3 (0)		5 (1)		76 (5)
Cholangiocarcinoma	6 (1)	3 (1)			2 (0)		3 (0)		0 (0)		1 (0)		15 (2)
Others	17 (2)	2 (0)			2 (0)		5 (0)		1 (0)		5 (0)		32 (2)
Secondary	50 (0)	6 (0)			53 (0)		19 (0)		14 (0)		11 (0)		153 (0)
Colorectal	37 (0)	6 (0)			40 (0)		17 (0)		11 (0)		7 (0)		118 (0)
Others	13 (0)	0 (0)			13 (0)		2 (0)		3 (0)		4 (0)		35 (0)
Benign lesion	39 (2)	2 (0)			55 (2)		14 (0)		11 (0)		76 (0)		197 (4)
Hemangioma	13 (0)	1 (0)			29 (0)		5 (0)		8 (0)		53 (0)		109 (0)
Adenoma	8 (0)	1 (0)			9 (0)		3 (0)		0 (0)		2 (0)		23 (0)
Focal nodular hyperplasia	3 (0)	0 (0)			3 (0)		1 (0)		1 (0)		11 (0)		19 (0)
Congenital cyst	7 (0)	0 (0)			3 (0)		2 (0)		0 (0)		4 (0)		17 (0)
Trauma	4 (2)	0 (0)			5 (0)		1 (0)		1 (0)		0 (0)		11 (2)
Others	4 (0)	0 (0)			6 (2)		2 (0)		1 (0)		5 (0)		18 (2)
Total	144 (7)	19 (2)			130 (6)		53 (0)		29 (0)		98 (1)		473 (16)

\*Operative mortality is shown in parentheses.

**TABLE 4.**

Time and Cause of Operative Mortality (Death in 1 Month)\*

Age/Sex	Diagnosis	Procedure	Time of Death (Days)	Cause of Death
64/F	Cholangiocarcinoma	RTS	20	Hepatic failure Celiac axis thrombosis
22/F	Regenerative nodule misdiagnosed as HCC	RL	4	Postoperative bleeding Hepatic failure
50/M	HCC in cirrhosis	RL	0	Perforation of CVP catheter into pericardium, cardiac tamponade
63/M	HCC in hemochromatosis	LTS	7	Hepatic failure
28/M	Abscess after trauma	RTS	0	Hemorrhage
77/M	HCC in cirrhosis	Local	0	Myocardial infarction
55/F	Cholangiocarcinoma	LTS	0	Hemorrhage
45/M	HCC	RTS	6	Hepatic failure Transplant on 6th day
31/M	Trauma	RTS	1	Arrhythmia due to fat emboli?
52/F	Neuroendocrine tumor (?)	RTS	0	Hemorrhage
51/M	Abscess after cholecystectomy	RL	19	Sepsis, multiple organ failure
36/F	HCC in cirrhosis	RTS	0	Hemorrhage
62/M	Bile duct cancer	RTS	29	Liver failure
71/M	HCC in cirrhosis	RL	28	Liver failure Myocardial infarction
59/M	HCC	RL	0	Hemorrhage
41/F	HCC in cirrhosis	RL	20	Liver failure Pneumonia

\*RTS = right trisegmentectomy; RL = right lobectomy; LTS = left trisegmentectomy; Local = nonanatomical local excision; HCC = hepatocellular carcinoma.

tality among the 454 patients without significant cirrhosis was 2% (9 of 454). Six of the 12 operative deaths among the patients with primary hepatic malignancy were encountered in the cirrhotic patients.

A high operative mortality was experienced after trisegmentectomy for primary malignancy (11%), after hepatic resection for trauma (18%) and for hepatic abscess (40%). On the other hand, there was no operative death after 153 hepatic resections for metastatic tumors. There was also no operative mortality among 109 pa-

tients with giant cavernous hemangioma, among 23 patients with liver cell adenoma, among 19 patients with focal nodular hyperplasia, and among 17 patients with congenital hepatic cysts. Four deaths among 197 patients with benign hepatic lesions occurred only with trauma, abscess and pseudohepatoma (a regenerative nodule misdiagnosed as a hepatoma) in a cirrhotic liver.

The circumstances of the 16 operative deaths are summarized in Table 4. There were 7 intraoperative deaths. Five of the 7 deaths were due to hemorrhage (4 in trisegmentectomy and 1 in right lobectomy). One patient died of myocardial infarction during a local excision of hepatocellular carcinoma in the cirrhotic liver. The blood loss was minimal during the procedure. In another patient a central venous catheter perforated the right atrium, which was not recognized until cardiac resuscitation. This patient died of cardiac tamponade and hypovolemia.

Four more patients died or underwent an attempt at liver transplantation in the first week after resection (see Table 4). The first patient had recovered completely from anesthesia after right trisegmentectomy for blunt trauma and was sitting and talking to the family, when he suddenly developed arrhythmia and died. The postmortem examination only revealed cardiomegaly and microscopic fat emboli of the heart and the lungs. The second patient died of postoperative bleeding and subsequent liver failure after right lobectomy. In this case a large regenerative nodule in the cirrhotic liver was misdiagnosed as an hepatocellular carcinoma.

The third patient with hemochromatosis died from hepatic failure after left trisegmentectomy for hepatocellular carcinoma. The search for a suitable donor was unsuccessful. The fourth patient underwent liver transplantation 6 days after an unwise attempt at right trisegmentectomy for hepatocellular carcinoma which had compromised the inferior vena cava just at the diaphragm. This patient died from multiple organ failure. The last two patients should have been treated by total hepatectomy and hepatic replacement as primary therapy.

Five other patients died from hepatic failure within a month after hepatic resection. The first patient died from acute onset of hepatic failure due to celiac axis thrombosis 20 days after right trisegmentectomy. The postmortem examination revealed a significant injury at the orifice of the celiac axis, probably caused by preoperative angiography. The second patient had developed a large abscess in the necrotic right lobe after cholecystectomy. Despite percutaneous catheter drainage, the patient had been septic and had required hemodialysis for renal failure. This patient died 19 days after resection from multiple organ failure.

The third patient died of hepatic failure 29 days after right trisegmentectomy and duct reconstruction of the left lateral segment to

the Roux-en-Y jejunum for bile duct cancer at the hepatic hilum. The fourth patient with hepatoma in a cirrhotic liver died of myocardial infarction and liver failure 28 days after right lobectomy. The last patient died of hepatic failure and pneumonia 20 days after right lobectomy for a large hepatocellular carcinoma in a cirrhotic liver. This patient was a chronic hepatitis B surface antigen carrier, whose tumor had grown and ruptured behind the right colon.

Another perspective is provided by correlating the data in Table 3 and Table 4. The only patients with benign disease who died were 2 with traumatic injury severe enough to require trisegmentectomy, 1 with an iatrogenic liver abscess, and 1 other with cirrhosis, whose regenerative nodule was misdiagnosed. Trisegmentectomy was associated with the highest mortality of any of the resections (5.5%), but 5 of the 9 deaths after trisegmentectomy resulted from treating very extensive primary hepatic malignancies, and 2 more occurred after the treatment of massive hepatic trauma. Exclusive of these high-risk cases, the operative mortality of trisegmentectomy would have been less than 2%.

Although further reduction must be achieved, our operative mortality has been acceptable when compared with those of others in recent years.<sup>70-72, 142, 143</sup>

#### POSTOPERATIVE COMPLICATIONS

There were 57 major complications, some patients having more than one, and they are stratified by the extent of resections and listed in Table 5. The most frequent complication was subphrenic abscess, which occurred in 27 patients, all but 1 after right-sided resection. The incidence was by far the highest after right trisegmentectomy (14%). Fluid collection or blood clots in the subphrenic space were treated as subphrenic abscess when occurring in patients with fever and/or leukocytosis. These were drained surgically by the posterior route through the 12th rib or on some occasions by transcutaneous tube drainage without delay. With this aggressive approach only 3 of the 27 patients with subphrenic abscess died after the drainage procedure, all from hepatic failure.

Minor bile leaks through the drain were seen occasionally, but these all closed spontaneously within a few days. Prolonged bile leaks occurred in 14 patients. All of these major bile leaks closed spontaneously without surgical correction within 2 months. In 2 patients prolonged bile leaks were followed by the later development of subphrenic abscess, which was surgically drained successfully. Prolonged bile leaks were most frequently seen after left trisegmentectomy (32%).

Seven (1.5%) of the 473 patients required re-exploration for postoperative bleeding. Hemorrhage was from the cut surface of the liver in



**TABLE 5.**

Postoperative Major Complications in Relation to Extent of Hepatic Resection\*

	RTS (n=144)	LTS (n=19)	RL (n=130)	LL (n=53)	LLS (n=29)	Local (n=98)	Total (n=473)
Subphrenic abscess	20	1	5	0	0	1	27
Prolonged bile leak	3	6	3	1	0	1	14
Postoperative bleeding	3	0	1	1	0	2	7
GI tract bleeding	3	0	0	0	0	0	3
Deep vein thrombosis	1	0	1	0	0	0	2
Myocardial infarction	0	0	1	0	0	0	1
Cerebrovascular accident	0	0	2	0	0	0	2
Small bowel obstruction	0	0	1	1	0	0	1
<b>Total</b>	<b>30</b>	<b>7</b>	<b>14</b>	<b>2</b>	<b>0</b>	<b>4</b>	<b>57</b>

\*RTS = right trisegmentectomy; LTS = left trisegmentectomy; RL = right lobectomy; LL = left lobectomy; LLS = left lateral segmentectomy; local = nonanatomical local excision; GI = gastrointestinal.

6 patients and from the cystic artery in 1 patient. All but 2 patients recovered without additional complication. One of the 2 patients who bled after right lobectomy for pseudohepatoma died of liver failure as described earlier, and another patient with hemangioma developed a subphrenic abscess that was drained successfully. Three patients had major bleeding from stress ulcer in the stomach and duodenum after trisegmentectomy. Two died of hepatic failure a few days after ulcer surgery. One patient survived stress ulcer and liver failure and is alive and well 6 months after hepatic resection.

Other complications such as deep vein thrombosis, myocardial infarction, cerebral vascular accident, and small bowel obstruction were managed successfully.

#### HEPATIC RESECTION FOR BENIGN LESIONS

With the recent advances in imaging techniques, space occupying lesions of the liver are now detected rather frequently. Although various imaging techniques are quite accurate in identifying cysts and hemangiomas, other lesions such as adenomas, focal nodular hyperplasia, and other benign solid tumors cannot be diagnosed with a high degree of confidence. Benign hepatic tumors sometimes cause life-threatening complications and more often trigger disabling and quite annoying symptoms in otherwise healthy persons.

**TABLE 6.**

Indications for 473 Hepatic Resections

Type of Lesion	No. of Patients
<b>Benign Hepatic Lesion</b>	
Cavernous hemangioma	109
Adenoma	23
Focal nodular hyperplasia	19
Congenital cyst	17
Polycystic disease	6
Nonpolycystic disease	11
Trauma	11
Hydatid cyst	5
Abscess	5
Caroli's disease	2
Fibroma	1
Leiomyoma	1
Mesenchymal hamartoma	1
Mesenchymoma	1
Regenerative nodule	1
Organized hematoma	1
<b>Total</b>	<b>197</b>
<b>Primary Hepatic Malignancy</b>	
Hepatocellular carcinoma (HCC)	76
Fibrolamellar HCC	12
Nonfibrolamellar	64
Cholangiocarcinoma (CHC)	15
Bile duct cancer	9
Carcinoma of hepatic cyst wall	4
Leiomyosarcoma	4
Adenocarcinoma of gallbladder	3
Rhabdomyosarcoma	2
Hepatoblastoma	2
Neuroendocrine tumor	2
Angiosarcoma	1
Sarcoma, undetermined cell type	1
Adenocarcinoma, unknown primary	1
Unclassified malignancy	3
<b>Total</b>	<b>123</b>

*(Continued.)***GIANT CAVERNOUS HEMANGIOMA**

There were 109 patients in our series whose giant cavernous hemangiomas were surgically excised (Table 6). Twenty-six were men and 83 were women. The patients' ages ranged from 22 to 77 years, with a mean age of 46 years. Twenty-two of the 109 patients had multiple hemangiomas. The masses ranged from 4 cm to 41 cm in largest diameter with a mean of 12 cm. Focal nodular hyperplasia coexisted in 3 female patients and hamartoma in 2 male patients.

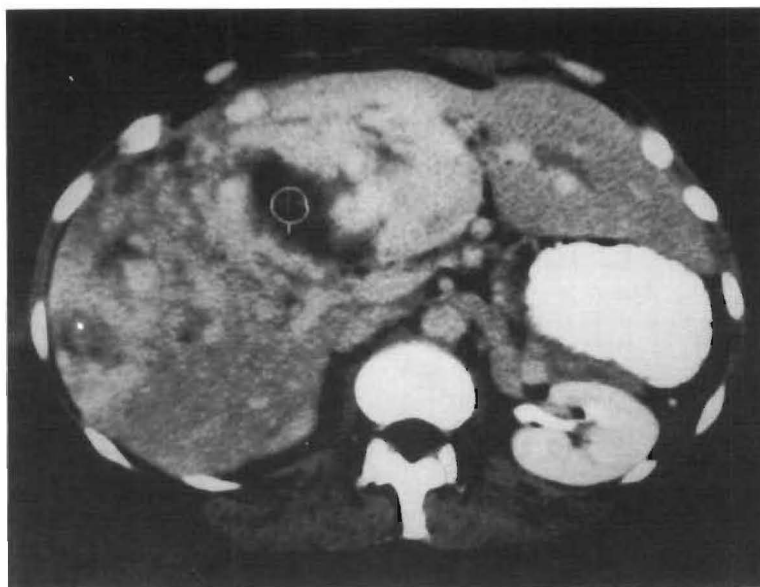
**TABLE 6 (cont.).**

Indications for 473 Hepatic Resections

Type of Lesion	No. of Patients
Secondary Hepatic Malignancy	153
Colorectal cancer	118
Intestinal cancer	6
Carcinoid	4
Spindle cell sarcoma	1
Leiomyosarcoma	1
Kidney cancer	5
Renal cell cancer	3
Wilms' tumor	2
Adrenal cancer	5
Adrenocortical carcinoma	4
Neuroblastoma	1
Breast cancer	4
Adenocarcinoma	2
Comedocarcinoma	1
Angiosarcoma	1
Gastric leiomyosarcoma	2
Ovarian adenocarcinoma	2
Uterus cancer	2
Squamous cell cancer	1
Endometrial sarcoma	1
Melanoma	2
Glucagonoma, pancreas	1
Leiomyosarcoma, rectum	1
Thyroid medullary carcinoma	1
Ewing's sarcoma	1
Mesothelioma	1
Rhabdomyosarcoma, colon	1
Adenocarcinoma, stomach	1
<b>Total</b>	<b>153</b>

Surgical removal of the hemangioma was decided in 30 patients because of severe pain associated with rupture or hemorrhage into the necrotic center of the tumor. The hemangioma ruptured spontaneously in 2 patients, resulting in hemoperitoneum or hemobilia. In 8 patients hemorrhage followed unwise percutaneous needle biopsy or open biopsy. In the remaining 20 patients hemorrhage occurred spontaneously into the necrotic center of the giant hemangioma and in these patients preoperative dynamic CT scan predicted the pathologic findings accurately (Fig 54). The patients with this complication noticed an enlarging palpable abdominal mass or hepatomegaly, accompanied by severe abdominal pain.

The indication of excision was moderate to severe pain in 49 patients. The pain was almost always located in the right upper quadrant or the epigastrium, and frequently radiated to the back and the



**FIG 54.**  
Giant cavernous hemangioma with central necrosis

shoulder. The diagnostic workup of gallbladder disease or peptic ulcer disease often led to the discovery of hepatic lesions. The gallbladder disease actually coexisted in 4 patients.

Vague but annoying symptoms of long duration, caused by a large abdominal mass, were the main indication for surgery in 17 patients. These symptoms consisted of all or any combinations of shortness of breath, abdominal fullness, pressure and dull ache, early satiety, nausea, vomiting, fatigue, night sweats, fever, and weight loss. In 13 patients the hemangiomas were relatively or completely asymptomatic, but in 10 of these patients the specific diagnosis could not be made with certainty in spite of an extensive workup. Eight of the 10 patients had a history of previous malignancy. In the remaining 2 patients CT scan revealed a large central necrosis in the relatively asymptomatic giant cavernous hemangioma.

Hematologic abnormalities were noted in 15 patients: 11 patients had anemia with a hemoglobin value of less than 10 gm/dl, 3 patients had a platelet count of less than 100,000/cu mm, and 1 patient carried a diagnosis of primary fibrinolysis for several years. These abnormalities were all corrected after the removal of the hemangioma. Infertility and miscarriage were noted in 4 young women.

Fourteen trisegmentectomies, 34 lobectomies, 8 left lateral segmentectomies, and 53 nonanatomical resections were used to remove the giant hemangiomas (see Table 3). The trisegmentectomies

and lobectomies were reserved for very large lesions (see Fig 54) or for hemangiomas located deep inside the liver, but some of the massive hemangiomas could be removed by local excision if they were pendulous or had narrow pedicles. Some of the medium-sized hemangiomas located on the edge of the liver could also be enucleated using the pseudocapsule of the hemangioma as a dissection plane.

All 109 patients survived the operation and were followed up for at least several months, after which further visits were not encouraged. However, 79 patients were traced for this report after 1 to 15 years (mean, 5 years). Four patients had died of malignancies that had been diagnosed before hepatic resection (chronic lymphocytic leukemia, testicular carcinoma, lung carcinoma and hypernephroma). A fifth patient died of colon carcinoma diagnosed 6 years after hepatic resection. Of the surviving patients none developed late complications except 1 who had an incisional hernia. Two of the patients developed acute hepatitis with recovery long after operation.

Sixty-one of 79 patients had had significant symptoms before hepatic resection. One or more years after resection 55 of the 61 were symptom free, but 6 still had vague abdominal complaints which were different from previous ones. Among the 18 patients who had been relatively asymptomatic preoperatively, 14 had no major symptoms and the other 4 had died from previously known malignancies before the follow-up contact. Although in 3 patients small hemangiomas (less than 2 cm in diameter) were known to be left unexcised, no recurrence of a symptomatic hemangioma is known to us at this time.

In general, it is safe to observe asymptomatic hemangiomas of moderate size closely. Danger of hemorrhage is low and there is no reason for therapy in the majority of patients with these lesions.<sup>136, 139, 141, 144</sup> However, the magnitude of symptoms should not be the only determinant for excisional therapy. Relatively asymptomatic hemangiomas 10 cm or more in diameter with documented central necrosis must be managed differently. Two of the 25 patients with such lesions in our series had emergency surgery for rupture, and 16 other patients required urgent operations for the sudden onset of severe pain and an acutely enlarging mass.

At surgery each patient was found to have hemorrhage inside the necrotic center of a giant hemangioma. Therefore we believe that this type of hemangioma should be excised, while they are still relatively asymptomatic. Hepatic artery ligation or embolization, and irradiation of the symptomatic giant cavernous hemangiomas had been recommended in the past because the mortality from any of the major hepatic resections was too high and extensive resection was thought unjustified for benign hepatic lesions. These modalities of treatment are no longer employed because they are ineffective; moreover, hepatic resection can now be carried out quite safely.

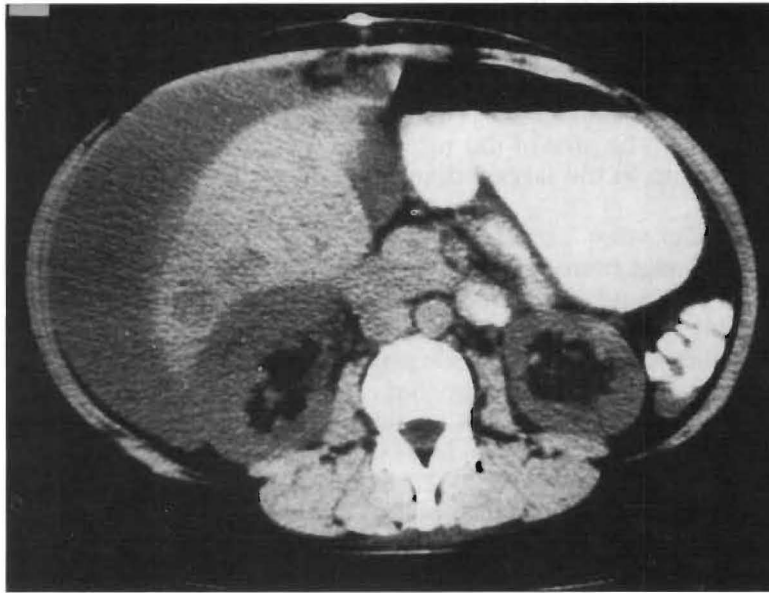
It is worth noting here that we have experienced at least 5 patients who had been thought to have typical imaging characteristics of hemangioma preoperatively but actually had malignant tumors: 3 patients had hepatocellular carcinoma, 1 patient had metastatic adrenal carcinoma, and another had multiple epithelioid hemangioendothelioma.

#### *LIVER CELL ADENOMA (ADENOMA)*

There were 23 patients whose adenomas were surgically removed (see Table 6). Five were male and 18 were female. Ages ranged from 16 to 60 years, with a mean of 31 years. Ten of the women had a history of using birth control pills or estrogen therapy. Five of the 23 patients, 2 men and 3 women, had multiple adenomas. Tumor size ranged from 5 to 27 cm in the greatest diameter, with a mean of 12 cm. One male patient had a parathyroid adenoma and 1 female patient had focal nodular hyperplasia. Sixteen of the 23 patients had moderate to severe abdominal pain and 4 more had vague abdominal complaints, similar to those described previously in patients with hemangioma. Six patients presented to us with hemoperitoneum from a ruptured adenoma (Fig 55). Four other patients with spontaneous hemorrhage into the necrotic center of the adenoma developed excruciating pain. Only 3 patients were asymptomatic, their solid tumors being found incidentally during physical examination for an unrelated illness or during abdominal exploration for another lesion. These asymptomatic adenomas were excised because of their large size, or because a definitive diagnosis could not be established preoperatively.

Lobectomies or trisegmentectomies were necessary in 21 of the 23 patients (see Table 3). Each of the 23 patients survived and all patients were available for postoperative evaluation between 3 months and 18 years (mean, 6 years) after surgery. In 3 patients with multiple adenomas that involved all four segments of the liver, some of the lesions were left behind after right trisegmentectomy. In each case the remaining adenomas enlarged or new lesions developed. One of these patients died of liver failure 6 years after resection. Another patient died 5 years after resection from cryptococcosis, a complication of her acquired immunodeficiency syndrome. The remaining patient required liver transplantation for massive adenoma regrowth 1 year after right trisegmentectomy and is alive and well 6 years after liver transplantation.<sup>141</sup> No other recurrence of adenoma is known to us at this time. Nineteen patients are free of symptoms after resection, and 2 others still have vague abdominal complaints that are different from previous symptoms.

The well-known propensity of hepatic adenomas to rupture, with



**FIG 55.**  
Spontaneous rupture of multiple liver cell adenoma. Note massive hemoperitoneum.

life-threatening hemorrhage, was seen in almost half of our patients. It is sometimes difficult histologically to differentiate liver cell adenoma from well-differentiated hepatocellular carcinoma even after the removal of the tumor, as illustrated in two of our patients. In one patient a large tumor was removed by right lobectomy with wide tumor-free margins. The tumor was histologically diagnosed as an adenoma. Two years later, the patient developed a pathologic fracture of the right femur. After examination of the bone lesion, the previous diagnosis of adenoma was corrected to well-differentiated hepatocellular carcinoma.

In another patient a large tumor was removed by nonanatomic hepatic resection. The diagnosis of adenoma established preoperatively by needle biopsy at another institution was confirmed after removal of the tumor. Several years later the tumor recurred in the same area, and it was resected by right lobectomy with wide margins. After the lobectomy the diagnosis was corrected to well-differentiated hepatocellular carcinoma. For these reasons, the argument for conservatism in treating adenomas is hard to sustain.<sup>145</sup> It is best to treat the adenoma as a potential malignancy and resect it with wide margins. Twenty-one of our 23 patients with adenoma were treated with anatomical resection, and only 2 patients with a small adenoma along the edge of the liver were treated by nonanatomical resections with wide margins.

### *FOCAL NODULAR HYPERPLASIA*

Nineteen patients, all female, had excisional therapy for focal nodular hyperplasia (see Table 6). Their ages ranged from 20 years to 52 years, with a mean of 35 years. Fourteen patients had used birth control pills. The size of the tumors ranged from 4 to 14 cm, with a mean of 8 cm in the largest diameter. Two patients had multiple lesions.

Symptoms were usually milder in these patients than in those with cavernous hemangiomas or adenomas, and in 4 patients the lesions were found incidentally. One patient had had ovarian carcinoma and another had a malignant histiocytoma of the skin. The definitive diagnosis was not made preoperatively in any case, although the diagnosis was often suspected.

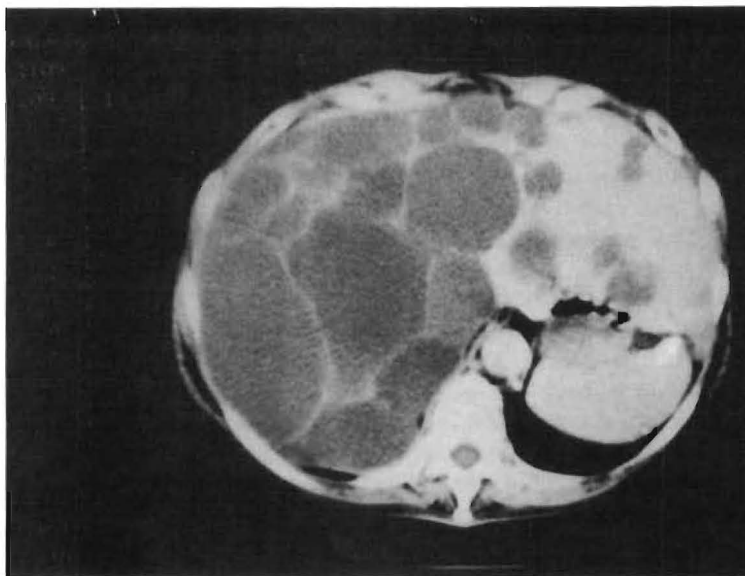Three trisegmentectomies, 4 lobectomies, 1 lateral segmentectomy, and 11 nonanatomical local excisions were performed with no operative death (see Table 3). Fifteen of the 19 patients were evaluated in 1988 after a follow-up of 6 months to 11 years, mean 3 years. All of the 12 patients who had had significant symptoms were now symptom-free, but 3 patients had some vague abdominal complaints. No recurrence of this lesion is known to us during the follow-up.

Patients with focal nodular hyperplasia, which at one time was confused with adenoma,<sup>146</sup> can be observed closely if the diagnosis is absolutely certain since these lesions rarely cause life-threatening complications such as rupture or internal hemorrhage.<sup>46, 147</sup> The diagnosis of focal nodular hyperplasia by imaging techniques is not as dependable as is the diagnosis of hemangioma or hepatic cyst. Histologic diagnosis is relatively easy for FNH, but we have experienced several cases in which the differential diagnosis with adenoma was confusing, and on one occasion the diagnosis by a frozen section biopsy was later changed to fibrolamellar hepatocellular carcinoma after removal of the tumor. As mentioned in the section on adenoma, some of our patients had both a hepatic adenoma and focal nodular hyperplasia occurring simultaneously.

### *CONGENITAL CYSTS*

Seventeen patients in our series with congenital cysts were treated by excisional therapy. Two patients had widespread polycystic disease and 4 others had multiple cysts that were limited to the resected specimen. The remaining 11 patients had single congenital cysts (see Table 6). All of these patients with large cysts had significant symptoms and had had repeated aspiration of cyst fluid. Two of the 6 patients with polycystic disease (Fig 56) had required intravenous alimentation for nutrition and the continuous administra-





**FIG 56.**  
Polycystic disease of the liver.

tion of narcotics for severe pain. Ten of the 17 patients had fever and chills, and 4 of them had jaundice. Seven trisegmentectomies, five lobectomies, and five nonanatomical local excisions were performed with no mortality.

The 2 patients with severe polycystic disease (see Fig 56) had right trisegmentectomy or right lobectomy, leaving a lateral segment or the left lobe that had fewer and smaller cysts than the rest of the liver. There was marked symptomatic relief for several years, but eventually there was cystic enlargement of the cysts in the remaining portion of the liver almost to the original size. One of these patients required orthotopic liver transplantation 8 years after right lobectomy. In contrast to the recurrence after partial resection of widespread polycystic disease, none of the patients whose cyst or cysts could be completely resected has had subsequent difficulties during a follow-up of 1 to 15 years.

Aspiration,<sup>148</sup> internal drainage,<sup>149</sup> marsupialization,<sup>150</sup> fenestration,<sup>151</sup> and sclerotherapy<sup>152</sup> have all been recommended for congenital hepatic cysts. These therapies can no longer be justifiable treatment for single or localized multiple cysts because resection can be performed so safely.

The problem of missed diagnosis was also experienced in 4 of our patients with single hepatic cysts. Three of the 4 patients had been diagnosed as having benign congenital cysts, and the cysts had been drained through jejunal Roux limbs at other institutions prior to our

seeing them. Pain, fever and intermittent jaundice developed or re-developed after internal drainage of the cysts. By the time we performed resection, squamous cell carcinoma of the cyst wall had spread regionally in these 3 patients. They died of widespread cancer within 6 to 16 months. The only survivor had primary nonanatomical resection of the cyst after repeated aspirations. The examination of the cyst wall after resection revealed a small adenocarcinoma. The patient is well and tumor-free 16 months postoperatively.

We have successfully treated 2 other patients with severe polycystic disease involving both the liver and the kidneys by combined liver and kidney transplantation. The quality of life of the 2 transplant patients is much better than that of patients after partial hepatic resection. If confronted with extreme complications of polycystic disease today, we would recommend organ replacement as the first, not the last, step of therapy.<sup>141</sup>

#### *HYDATID CYST*

Five patients with hydatid cyst were treated by trisegmentectomy (1), lobectomy (3), and local excision (1) (see Tables 3 and 6). One patient with a small hydatid cyst died from pancreas cancer 10 months after local excision of the cyst. The remaining 4 patients are alive, free of hydatid disease from 1 to 12 years after anatomical resection of the liver.

The most widely used treatment of hydatid cyst has been the removal of the lining membrane and all cyst contents after sterilizing the paracysts with formalin, alcohol or hypertonic saline solution.<sup>153</sup> Besides the toxicity of the sterilizing solution and the occasional damage to the biliary duct, the cyst frequently recurs when the paracysts escape alive. Although small, satellite cysts adjacent to a dominant one are frequently not recognized, and these tend to grow progressively after the larger cysts are treated. Although our experience is limited to only 5 cases, 2 of these patients had had multiple operations over a period of years at outstanding clinics in the United States and Europe. Increasingly complex problems had developed, such as communication between the cyst and the biliary duct and growth of satellite cysts. Despite this, all of the lesions could be removed by a difficult trisegmentectomy and lobectomy.

We believe that a large cyst or multiple cysts should be excised by anatomical resection whenever feasible, and that the cystectomy be only reserved for cases in which the cysts cannot be removed by partial hepatic resection. We have treated a young woman by liver transplantation who had developed sclerosing cholangitis and cir-

rhosis after sterilization by formalin and cystectomy. Another young patient died during an attempt at liver transplantation after several operations in Europe had cured the hydatid cysts, but she had resultant sclerosing cholangitis.

#### *OTHER BENIGN HEPATIC LESIONS*

Eleven patients were treated with trisegmentectomy (4), lobectomy (6), and lateral segmentectomy (1) of the traumatized liver (see Tables 3 and 6). Six resections were for acute hemorrhage, 4 were for post-traumatic abscess and 1 for bile peritonitis after repair of laceration. Two of the 11 patients died postoperatively of various causes as described in the earlier section.

Five patients with hepatic abscess were treated with four anatomic resections and one nonanatomical resection. Two patients with iatrogenic abscess following cholecystectomy had been unsuccessfully managed by percutaneous drainage. One patient with fungal abscess of unknown origin was thought to have necrotic malignant tumor preoperatively. Two of the 5 patients died postoperatively of infectious complications and hepatic failure, as shown in Table 4.

Eight other patients with various benign hepatic lesions had hepatic resection. Miscellaneous diagnosis and the procedures used are summarized in Table 3 and 6. Two patients had right lobectomy for localized Caroli's disease. The death of a patient with pseudohepatoma was described in the earlier section. In none of the other 5 patients could a correct diagnosis be made preoperatively.

#### **HEPATIC RESECTION FOR PRIMARY HEPATIC MALIGNANCY**

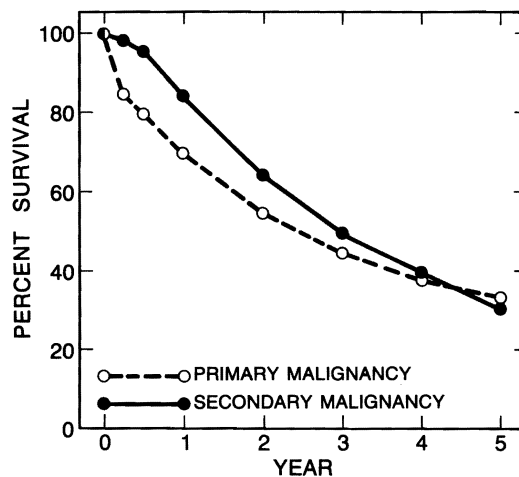
Histologic diagnoses of the 123 patients with primary hepatic malignancy are shown in Table 6. There were 76 patients with hepatocellular carcinoma (HCC), of whom 12 had fibrolamellar hepatocellular carcinoma (FL-HCC). Fifteen patients had peripheral cholangiocarcinoma (CHC) and 9 had bile duct cancer at the bifurcation (Klatskin tumor). The remaining 23 patients had various rare types of primary malignancy, in some of whom a definitive histologic diagnosis could not be made.

More than a half of the patients (66 of 123) were treated with trisegmentectomies, and most of the patients (108 of 123) with lobectomies or greater resections, reflecting the extremely high incidence of advanced stages of malignant tumors among our patients (see Table 3). Eight of the 12 operative deaths would have been avoided if orthotopic liver transplantation had been chosen for these patients (see Table 5).

## SURVIVALS

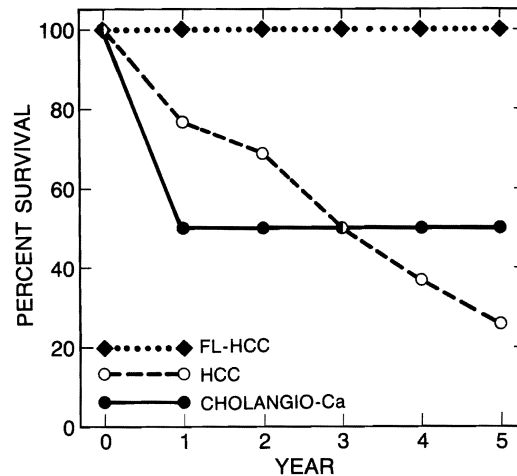
The actuarial survivals of patients with primary hepatic malignancy are shown graphically in Figures 57 and 58. Overall survival rates of 123 patients with primary hepatic malignancy, including operative deaths, were 85% at 3 months, 80% at 6 months, 69% at 1 year, 55% at 2 years, 46% at 3 years, 38% at 4 years, and 33% at 5 years after hepatic resection. Similar results have been reported by others.<sup>72, 142, 143</sup>

All but 1 of the 12 patients with fibrolamellar hepatocellular carcinoma are alive (see Fig 58): 9 patients are free of disease from 2 to 16 years after resection, and 2 are with disease from 2 to 4 years after resection. One patient died 8 years after hepatic resection during an attempt at en bloc liver and pancreas transplantation for recurrent tumor that obstructed the portal vein. One- to 5-year survival rates of 64 patients with nonfibrolamellar hepatocellular carcinoma were 77%, 69%, 50%, 37% and 26%, respectively, and those of 15 patients with cholangiocarcinoma were 50%, 40%, 40%, 40%, and 40%, respectively (see Fig 58). The survival of patients with fibrolamellar hepatocellular carcinoma was significantly better than the survival of patients with nonfibrolamellar hepatocellular carcinoma and patients with cholangiocarcinoma ( $P < .01$ ). There was no difference in survival between patients with nonfibrolamellar hepatocellular carcinoma and patients with cholangiocarcinoma ( $P < .05$ ).



**FIG 57.**

After hepatic resection there was no difference in actuarial survival rates between 123 patients with primary hepatic malignancy and 153 patients with secondary hepatic malignancy.



**FIG 58.**

After hepatic resection the survival rate of patients with fibrolamellar hepatocellular carcinoma was higher ( $P < .01$ ) than that of patients with nonfibrolamellar hepatocellular carcinoma and higher than with cholangiocarcinoma.

Nine patients with carcinoma of the bile duct bifurcation (Klatskin tumor) were treated with right trisegmentectomy (6), or left trisegmentectomy (1), left lobectomy (1), and left lateral segmentectomy (1). In these patients the tumor bearing extrahepatic bile ducts were excised and the remaining bile duct was anastomosed to the Roux-en-Y jejunum. Three of the 9 patients died: 1 from liver failure within a month and 2 others from recurrent tumor, 8 months and 4 years after operation. The remaining 6 patients are alive between 6 months and 18 months after resection, but 2 have recurrent tumor.

The 4 patients with single hepatic cysts that had malignant degeneration in the cyst wall were treated by trisegmentectomy (3) and local nonanatomical resection (1). The 3 patients treated with trisegmentectomy died from recurrence of squamous cell cancer 6, 10, and 16 months after resection. The fourth patient whose solitary cyst contained a small adenocarcinoma is alive and free of tumor 18 months after local excision.

#### *FIVE-YEAR SURVIVORS*

There were 18 patients who survived more than 5 years after hepatic resection for primary hepatic malignancy (Table 7). Five of them had had fibrolamellar hepatocellular carcinoma, all of which were resected by trisegmentectomy. One patient died 8 years after

**TABLE 7.**

Follow-up of 18 Patients With Primary Hepatic Malignancies Who Lived for 5 Years\*

Histology	Fibrolamellar	HCC	CHC	Other	Total
Number	5	6	4	3	18
Trisegmentectomy	5	4	2	3	14
Lobectomy	0	2	1	0	3
Died > 5 yr	1	2	1	1	4
Time of death (yr)	8	8,8	6	13	—
Living > 5 yr	4	4	3	3	14
Survival (yr)	6,8,9,15	5,7,7,13	6†,7†,8	13,14	—

\*Fibrolamellar = fibrolamellar variant of hepatocellular carcinoma; HCC = nonfibrolamellar hepatocellular carcinoma; CHC = cholangiocarcinoma; other = hepatoblastoma, leiomyosarcoma, rhabdomyosarcoma.  
†Living with recurrence

hepatic resection during an attempt at en bloc liver-pancreas transplantation as described earlier. The remaining 4 patients are alive and free of tumor from 6 to 15 years after resection. Six patients with nonfibrolamellar hepatocellular carcinoma also survived more than 5 years. Four of the 6 patients were treated by trisegmentectomy and 2 by lobectomy. Two of the 6 patients died 8 years after resection from recurrent tumor. The remaining 4 patients are alive and free of tumor between 5 and 13 years after resection.

Four patients with peripheral cholangiocarcinoma survived more than 5 years. However, 1 patient died from recurrent tumor 6 years after resection, and 2 patients are alive with recurrent tumor in the sixth and seventh year after resection. Only 1 patient is alive and free of tumor 8 years after resection. Three other patients survived more than 3 years after trisegmentectomy for hepatoblastoma, leiomyosarcoma, and rhabdomyosarcoma. One patient with hepatoblastoma died of acute leukemia 13 years after hepatic resection. The remaining 2 patients are alive and free of tumor 13 and 14 years after resection. It is worth noting that 14 of the 18 5-year survivors had been treated by trisegmentectomy for removal of their large tumors.

#### HEPATIC RESECTION FOR SECONDARY HEPATIC MALIGNANCY

Primary sites of malignancy and histologic diagnoses of 153 patients with hepatic metastases are shown in Table 6. There were 118 patients with hepatic metastases from colorectal carcinoma, and 35 patients with metastases from various other primary sites. The fact that more than one third of the patients were treated with trisegmentectomy and the vast majority (128 of 153) of patients required

lobectomy or larger resections indicates the high incidence of advanced metastatic disease among our patients (see Table 3).

There was no operative death among 153 patients with hepatic metastases as described earlier.

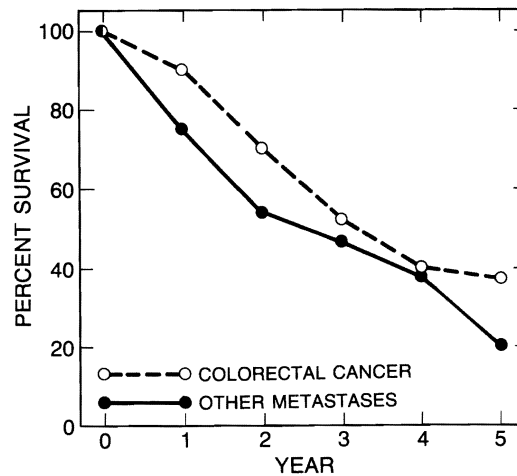
### SURVIVALS

The overall actuarial survival rates of 153 patients with hepatic metastases are shown graphically in Figure 57: 99% at 3 months, 96% at 6 months, 84% at 1 year, 65% at 2 years, 51% at 3 years, 40% at 4 years and 31% at 5 years after resection.

The 1- to 5-year survivals of 118 patients with metastases from colorectal carcinoma were 90%, 69%, 52%, 40% and 37%, respectively (Fig 59). The similar survivals of the 35 patients with metastases from primaries other than colorectal carcinoma were 75%, 54%, 47%, 38% and 20%, respectively (see Fig 59). The difference in survival was not statistically significant. Similar results have been noted by others.<sup>70, 81, 154</sup>

### FIVE-YEAR SURVIVORS

There were 16 patients who survived more than 5 years after hepatic resection for metastases (Table 8). Eleven of them had had metastases from colorectal carcinoma, 2 had had carcinoid tumor of



**FIG 59.**

After hepatic resection there was no difference in actuarial survival rates between 118 patients with colorectal metastasis and 35 patients with other metastases.

**TABLE 8.**

Follow-up of 16 Patients With Hepatic Metastases Who Survived for More Than 5 Years After Hepatic Resection

Histology	Colorectal	Carcinoid	Others*	Total
Number	11	2	3	16
Trisegmentectomy	2	0	3	5
Lobectomy	5	1	0	6
Lateral Segmentectomy	4	1	0	5
Died > 5 yr	3	1	0	4
Time of death (yr)	6†,7†,8‡	8†	—	—
Living > 5 yr	6	1	3	9
Survival (yr)	5†,5†,6† 7,8,14	9	5,15,15	—
Lost to follow-up (yr)	6*,8	—	—	2

\*One each of leiomyosarcoma of stomach, adrenal neuroendocrine tumor, and endometrial sarcoma of uterus.  
 †Had recurrence when last seen.  
 ‡Died of myocardial infarction, tumor free.

the intestine, and 3 others had had leiomyosarcoma of the stomach, an adrenal neuroendocrine tumor and endometrial sarcoma of the uterus. Five of the 16 patients were treated with trisegmentectomy, 6 with lobectomy and the other 5 with less than lobectomy.

Three of the 11 5-year survivors with metastases from colorectal carcinoma died: 2 from tumor recurrence and 1 from myocardial infarction without evidence of tumor recurrence. Six of the 11 patients are alive from 5 to 14 years after hepatic resection: 3 with and 3 without tumor recurrence. The remaining 2 of the 11 patients were lost from follow-up after 5 years: 1 in the sixth year with known tumor recurrence and another in the 8th year with no evidence of recurrent tumor.

One of the 2 patients with metastatic carcinoid tumor died with recurrent tumor 8 years after resection and another patient is alive and free of tumor 9 years after resection. Three other patients are alive and free of tumor: 5 years after hepatic resection for endometrial sarcoma, 15 years after hepatic resection for leiomyosarcoma of the stomach and 15 years after hepatic resection for adrenal neuroendocrine tumor.

### THE CHANGING FACE OF HEPATIC RESECTION

Hepatic resection has evolved from the speedy amputation of hepatic lesions decades ago to well-controlled removal of anatomically defined portions of the liver in the middle of this century, when precise anatomy of the liver was finally understood. In the 1960s and



1970s malignant tumors were treated aggressively by major anatomical hepatic resections, but the operative mortality was so high that this most effective surgery was not employed for patients with benign lesions.<sup>155, 156</sup> During this period less effective but safer procedures for benign hepatic lesions were introduced, and the conservatism in treating these lesions spread widely. In the 1980s the safety of major anatomical hepatic resection has been well established, and the indications for hepatic resection must be broadened. Rigid conservatism in treating benign hepatic lesions can no longer be justified.<sup>141</sup>

Also in the 1980s hepatic transplantation<sup>38, 39</sup> has become a practical therapeutic modality not only for acute and chronic hepatic failure, but also for benign and malignant hepatic lesions. Massive benign hepatic lesions such as multiple adenomas, polycystic disease and lymphoangiomas have been treated successfully by total hepatectomy and transplantation.<sup>38, 39</sup> The results after hepatic transplantation for malignant tumors have been rather discouraging.<sup>39, 157-159</sup> Although the survival for the first year has been very high, late tumor recurrence has plagued these efforts. In the past, adjuvant chemotherapy, radiotherapy, and biologic therapy for malignancy have not been systematically tried after transplantation.

Liver transplantation, however, can result in the cure of hepatic malignancy on more than the isolated occasion. The most favorable lesions for hepatectomy and transplantation, just as for resection, are small lesions, fibrolamellar hepatomas and epithelioid heman-gioendothelial sarcomas.<sup>157</sup> Even in highly selected cases of metastatic hepatic tumors significant palliation or even long survival has been accomplished.<sup>39, 160</sup>

The most recent development is the en bloc removal and replacement of upper abdominal organs (organ-cluster transplantation) for regionally spread hepatic, biliary, pancreatic, and duodenal malignancy. The liver, pancreas, duodenum, and even a part of the small intestine have been grafted in continuity in 7 patients. Five of the 7 patients are yet alive, free of tumor, within several months.

Lest these remarks be misunderstood, it should be pointed out that in addition to demonstrating how safe hepatic resection and transplantation can be, our observations have also shown that the real key to the cure of malignant tumors is nonsurgical. While the yield from complete surgical removal of hepatic malignancy was substantial in our patients, tumor recurrence was the rule, not the exception.<sup>157-160</sup> The recurrence must be prevented by nonsurgical therapy. With the development of safer and more effective chemotherapy, radiotherapy, and immunotherapy, hepatic resection and transplantation will become reliable adjuvant therapies for malignant disease in the future.

## REFERENCES

1. Cantlie J: On a new arrangement of the right and left lobes of the liver. *Proc Anat Soc Gr Britain Ireland* 1898; 32:4–9.
2. McIndoe AH, Counseller VG: The bilaterality of the liver. *Arch Surg* 1927; 15:589–612.
3. Hjortsjo CH: The topography of the intrahepatic duct systems. *Acta Anatomica* 1950/1951; 11:599–615.
4. Elias H, Petty D: Gross anatomy of the blood vessels and ducts within the human liver. *Am J Anat* 1952; 90:59–111.
5. Healey JE Jr, Schroy PC: The intrahepatic distribution of the hepatic artery in man. *J Int Coll Surgeons* 1953; 20:133–148.
6. Healey JE Jr: Clinical anatomic aspects of radical hepatic surgery. *J Int Coll Surgeons* 1954; 22:542–549.
7. Couinaud C: *Le foie: études anatomiques et chirurgicales*. Paris, Masson & Cie, 1957, pp 3–9.
8. Goldsmith NA, Woodburne RT: The surgical anatomy pertaining to liver resection. *Surg Gynecol Obstet* 1957; 105:310–318.
9. Makuuchi M, Hasegawa H, Yamazaki S: Intraoperative ultrasonic examination for hepatectomy. *Jpn J Clin Oncol* 1981; 11:367–374.
10. Nagasue N, Suehiro S, Yuikaya H: Intraoperative ultrasonography in the surgical treatment of hepatic tumors. *Acta Chir Scand* 1984; 150:311–316.
11. Shinagawa T, Ohta M, Okuda K, et al: Diagnosis and clinical features of small hepatocellular carcinoma with emphasis on the utility of real time ultrasonography. *Gastroenterology* 1984; 86:495–502.
12. Michels NA: Newer anatomy of the liver and its variant blood supply and collateral circulation. *Am J Surg* 1966; 112:337–347.
13. Suzuki T, Nakayasu A, Kawabe K, et al: Surgical significance of anatomic variation of the hepatic artery. *Am J Surg* 1971; 122:505–512.
14. Lilly JR, Starzl TE: Liver transplantation in children with biliary atresia and vascular anomalies. *J Pediatr Surg* 1974; 9:707–714.
15. Lilly JR, Starzl TE: Operative implications of preduodenal portal vein. *Surgery* 1979; 85:717–718.
16. Okamoto E, Tanaka N, Yamanaka N, et al: Results of surgical treatment of primary hepatocellular carcinoma: Some aspects to improve long term survival. *World J Surg* 1984; 8:360–366.
17. Kinami Y, Takashima S, Miyazaki I: Hepatic resection for hepatocellular carcinoma associated with cirrhosis. *World J Surg* 1986; 10:294–301.
18. Nagasue N, Yukaya H, Ogawa Y, et al: Segmental and subsegmental resection of the cirrhotic liver under hepatic inflow and outflow occlusion. *Br J Surg* 1985; 72:565–570.
19. Gozzetti G, Mazziotti A, Cavallari A, et al: Clinical experience with hepatic resections for hepatocellular carcinoma in patients with cirrhosis. *Surg Gynecol Obstet* 1988; 166:503–510.
20. Castaing D, Emond J, Kunstlinger F, et al: Utility of operative ultrasound in the surgical management of liver tumors. *Ann Surg* 1986; 204:600–605.
21. Keen WW: On resection of the liver especially for hepatic tumors, with the report of an adenoma of the bile-ducts, and a table of twenty recorded cases of hepatic operations. *Boston Med Surg J* 1892; 126:405–416.
22. Keen WW: Report of a case of resection of the liver for the removal of a neoplasm, with a table of seventy-six cases of resection of the liver for hepatic tumors. *Ann Surg* 1899; 30:267–283.

23. Wendel W: Beitrage zur chirurgie der leber. *Arch fur Kin Chirurg* 1911; 95:887–894.
24. Abel L: Primary carcinoma of the liver: with report of case successfully treated by partial hepatectomy. *Brit J Surg* 1934; 21:684–700.
25. Lortat-Jacob JL and Robert HG: Hepatectomie droite réglée. *Presse Med* 1952; 60:549–551.
26. Wangensteen OH: Cancer of the esophagus and stomach: Proc 3rd Natl Cancer Conf. Philadelphia, JB Lippincott Co, 1951, pp 94–97.
27. Quattlebaum JK: Massive resection of the liver. *Ann Surg* 1953; 137:787–796.
28. Brunschwig A: The surgery of hepatic neoplasms with special reference to right and left lobectomies: XVI Congrès de la Société Internationale de Chirurgie, Copenhagen. Brussels, Imprimerie Médicale et Scientifique, 1955, pp 1122–1132.
29. Miller TR: Neoplasms of the liver, in Maingot R (ed): *Abdominal Operations*. New York, Appleton-Century-Crofts, 1974, vol 2, pp 1226–1246.
30. Starzl TE, Bell RH, Beart RW, et al: Hepatic trisegmentectomy and other liver resections. *Surg Gynecol Obstet* 1975; 141:429–437.
31. Starzl TE, Koep LJ, Weil R III, et al: Right trisegmentectomy for hepatic neoplasms. *Surg Gynecol Obstet* 1980; 150:1–7.
32. Starzl TE, Iwatsuki S, Shaw BW Jr, et al: Left hepatic trisegmentectomy. *Surg Gynecol Obstet* 1982; 155:21–27.
33. Raven RW: Partial hepatectomy. *Br J Surg* 1949; 36:397–401.
34. Pringle JH: Notes on the arrest of hepatic hemorrhage due to trauma. *Ann Surg* 1908; 45:541–549.
35. Huguet C, Nordlinger B, Galopin JJ, et al: Normothermic hepatic vascular exclusion for extensive hepatectomy. *Surg Gynecol Obstet* 1978; 147: 689–693.
36. Todo S, Yokoi H, Podesta L, et al: Amelioration of normothermic canine liver ischemia. *Transplant Proc* 1988; 20:965–968.
37. Starzl TE, Marchioro TL, Von Kaulla KN, et al: Homotransplantation of the liver in humans. *Surg Gynecol Obstet* 1963; 117:659–676.
38. Starzl TE, Iwatsuki S, Van Thiel DH, et al: Evolution of liver transplantation. *Hepatology* 1982; 2:614–639.
39. Iwatsuki S, Starzl TE, Todo S, et al: Experience in 1,000 liver transplants under cyclosporine-steroid therapy: A survival report. *Transplant Proc* 1988; 20:498–504.
40. Conn HO, Yesner R: A re-evaluation of needle biopsy in the diagnosis of metastatic cancer of the liver. *Ann Intern Med* 1963; 59:53–61.
41. Whitlatch S, Nunez C, Pitlik DA: Fine needle aspiration biopsy of the liver: A study of 102 consecutive cases. *Acta Cytol* 1984; 28:719–725.
42. Haaga JR, Vanek J: Computed tomography guided liver biopsy using the Menghini needle. *Radiology* 1979; 133:405–408.
43. Tatsuta M, Yamamoto R, Kasugai H, et al: Cytohistologic diagnosis of neoplasms of the liver by ultrasonically guided fine needle aspiration biopsy. *Cancer* 1984; 54:1682–1686.
44. Jacobsen GK, Gammelgaard J, Fuglo M: Coarse needle biopsy versus fine needle aspiration biopsy in the diagnosis of focal lesions of the liver. *Acta Cytol* 1983; 27:152–156.
45. Falk H, Herbert J, Crowley S: Epidemiology of hepatic angiosarcoma in the United States: 1964–1974. *Environ Health Perspectives* 1981; 41:107–113.
46. Ishak KG, Rabin L: Benign tumors of the liver. *Med Clin North Am* 1975; 49:995–1013.

47. Edmondson HA, Peters RL: Neoplasms of the liver, in Schiff L, Schiff ER (eds): *Diseases of the Liver*. Philadelphia, JB Lippincott Co, 1982, pp 303–331.
48. Weinberg AG, Finegold MJ: Primary hepatic tumors of childhood. *Hum Pathol* 1983; 14:512–537.
49. Dehner LP, Ishak KG: Vascular tumors of the liver in infants and children: A study of 30 cases and review of the literature. *Arch Pathol* 1971; 92:101–111.
50. Fechner RE: Benign hepatic lesions and orally administered contraceptives: A report of seven cases and a critical analysis of the literature. *Hum Pathol* 1977; 8:255–268.
51. Goire CL, Qizilbash AH, Castelli MF: Hepatic adenomata in type 1A glycogen storage disease. *Arch Pathol Lab Med* 1987; 11:166–169.
52. Foster JH, Donohue TA, Berman MM: Familial liver cell adenomas and diabetes mellitus. *N Engl J Med* 1978; 299:239–341.
53. Flejou JF, Barge J, Menu Y, et al: Liver adenomatosis: An entity distinct from liver adenoma? *Gastroenterology* 1985; 89:1132–1138.
54. Berman M, Burnham J, Sheahan DG: Fibrolamellar carcinoma of the liver: An immunohistochemical study of nineteen cases and a review of the literature. *Hum Pathol* 1988; 19:784–794.
55. Vecchio FM, Fabiano A, Ghirlanda G, et al: Fibrolamellar carcinoma of the liver: The malignant counterpart of focal nodular hyperplasia with oncocytic change. *Am J Clin Pathol* 1984; 81:521.
56. Dehner LP: Hepatic tumors in the pediatric age group: A distinctive clinicopathologic spectrum, in Rosenberg HS, Bolande RP (eds): *Perspectives in Pediatric Pathology*. vol 4. Chicago, Year Book Medical Publishers, 1979, pp 217–268.
57. Ehren H, Mahour GH, Isaacs H: Benign liver tumors in infancy and childhood: Report of 48 cases. *Am J Surg* 1983; 145:325–329.
58. Dooley JS, Li AKC, Scheuer PJ, et al: A giant cystic mesenchymal hamartoma of the liver: Diagnosis, management, and study of cyst fluid. *Gastroenterology* 1983; 85:958–961.
59. Gramlich TL, Killough BW, Garvin AJ: Mesenchymal hamartoma of the liver: Report of a case in a 28-year-old. *Hum Pathol* 1988; 19:991–992.
60. Grasses PJ, Matos-Villalobos M, Arcia-Romero F, et al: Mesenchymal hamartoma of the liver. *Gastroenterology* 1979; 76:1466–1469.
61. Stocker JT, Ishak KG: Mesenchymal hamartoma of the liver: Report of 30 cases and review of the literature. *Pediatric Pathol* 1983; 1:245–267.
62. Homer LW, White HJ, Read RC: Neoplastic transformation of v. Myenberg complexes of the liver. *J Path Bact* 1968; 96:499–502.
63. Bloustein PA: Association of carcinoma with congenital cystic conditions of the liver and bile ducts. *Am J Gastroenterol* 1977; 67:40–46.
64. Cruickshank AH, Sparshott SM: Malignancy in natural and experimental hepatic cysts: Experiments in aflatoxin in rats and the malignant transformation of cysts in human livers. *J Pathol* 1971; 104:185–190.
65. Gresham GA, Rue LW: Squamous cell carcinoma of the liver. *Hum Pathol* 1985; 16:413–416.
66. Pickren JW, Tsukada Y, Lane WW: Liver metastasis: Analysis of autopsy data, in Weiss L, Gilbert HA (eds): *Liver Metastasis*. Boston, G.K. Hall Medical Publishers, 1982, pp 2–18.
67. Edmondson HA, Peters RL: Neoplasms of the liver, in Schiff L, Schiff ER (eds): *Diseases of the Liver*, ed 5. Philadelphia, JB Lippincott Co, 1982, pp 1101–1158.

68. August DA, Sugarbaker PH, Schneider PD: Lymphatic dissemination of hepatic metastases: Implications for the follow-up and treatment of patients with colorectal cancer. *Cancer* 1985; 55:1490–1494.
69. Foster JH, Berman MM: Solid liver tumors, in *Major Problems in Clinical Surgery*. vol 22. Philadelphia, WB Saunders Co, 1977, p 82.
70. Adson MA, Van Heerden JA, Adson MH, et al: Resection of hepatic metastases from colorectal cancer. *Arch Surg* 1984; 119:647–651.
71. Fortner JG, Silva JS, Golbey RB, et al: Multivariate analysis of a personal series of 247 consecutive patients with liver metastases from colorectal cancer. *Ann Surg* 1984; 199:306–316.
72. Fortner JG, MacLean BJ, Kim DK, et al: The seventies' evolution in liver surgery for cancer. *Cancer* 1981; 47:2162–2166.
73. Gerber MA, Thung SN, Popper H: Viral hepatitis and hepatocellular carcinoma, in Deinhardt F, Deinhardt JB (eds): *Laboratory and Clinical Science of Viral Hepatitis*. New York, Marcel Dekker, Inc, 1983, pp 239–253.
74. Bomford A, Williams R: Long-term result of venesection therapy in idiopathic hemochromatosis. *Q J Med* 1976; 45:611–623.
75. Ishak KG: Hepatic neoplasms associated with contraceptive and anabolic steroids, in Lingeman CH (ed): *Recent Results in Cancer Research: Carcinogenic Hormones*. New York, Springer Verlag, 1979, vol 66, pp 73–128.
76. Alpert E: Human alpha-fetoprotein, in Okuda K, Peters RL (eds): *Hepatocellular Carcinoma*. New York, John Wiley & Sons, 1976, pp 353–367.
77. Chen DS, Sung JL, Sheu JC, et al: Serum fetoprotein in the early stage of human hepatocellular carcinoma. *Gastroenterology* 1984; 86:1404–1409.
78. Bloomer J: Serum alpha-fetoprotein in nonneoplastic liver diseases. *Dig Dis Sci* 1980; 25:241–242.
79. Ishikura H, Fukasawa Y, Ogasawara K, et al: An AFP-producing gastric carcinoma with features of hepatic differentiation. A case report. *Cancer* 1985; 56:840–848.
80. Deugnier Y, David V, Brissot P, et al: Serum fucosidase: A new marker for the diagnosis of primary hepatic carcinoma? *Hepatology* 1984; 4:889–892.
81. Becker FF: Hepatoma—nature's model tumor: A review. *Am J Pathol* 1974; 74:1797–2000.
82. Okuda K, Peters RL, Simson IW: Gross anatomic features of hepatocellular carcinoma from three disparate geographic areas. *Cancer* 1984; 54:2165–2173.
83. Kojiro M, Nakahara H, Sugihara S, et al: Hepatocellular carcinoma with intra-atrial tumor growth: A clinicopathologic study of 18 autopsy cases. *Arch Pathol Lab Med* 1984; 108:989–992.
84. Roncalli M, Borzio M, Debiagi G, et al: Liver cell dysplasia and hepatocellular carcinoma: A histological and immunohistochemical study. *Histopathology* 1984; 9:209–221.
85. Peters RL: Pathology of hepatocellular carcinoma, in Okuda K, Peters RL: *Hepatocellular Carcinoma*. New York, John Wiley & Sons, 1976, pp 107–168.
86. Berman MM, Libbey NP, Foster JH: Hepatocellular carcinoma with carcinoid features. *Hum Pathol* 1984; 15:892–894.
87. Craig JR, Peters RL, Edmondson HA, et al: Fibrolamellar carcinoma of the liver: A tumor of adolescents and young adults with distinctive clinicopathologic features. *Cancer* 1980; 46:372–379.
88. Paradinas FJ, Melia WM, Wilkinson ML, et al: High serum vitamin B<sub>12</sub> binding capacity as a marker of the fibrolamellar variant of hepatocellular carcinoma. *Br Med J* 1982; 285:840–842.

89. Lefkowitz JH, Muschel R, Price JB, et al: Copper and copper binding protein in fibrolamellar liver cell carcinoma. *Cancer* 1983; 51:97-100.
90. Omata M, Peters RL: Sclerosing hepatic carcinoma: Relationship to hypercalcemia. *Liver* 1981; 1:33-49.
91. Terpstra OT, tenKate FJW, et al: Long-term survival after resection of a hepatocellular carcinoma with lymph node metastasis and discontinuation of oral contraceptives. *Am J Gastroenterol* 1984; 79:474-478.
92. Smith AL, Auldist AW: Successful surgical resection of an hepatic gastrinoma in a child. *J Pediatr Gastroenterol Nutr* 1984; 3:801-804.
93. Ali M, Fayemi AO, Braun EV: Malignant apudoma of the liver with symptomatic intractable hypoglycemia. *Cancer* 1978; 42:686-692.
94. Barsky SH, Linnoila I, Triche TJ, et al: Hepatocellular carcinoma with carcinoid features. *Hum Pathol* 1984; 15:892-894.
95. Mori W, Nagasako K: Cholangiocarcinoma and related lesions, in Okuda K, Peters RL (eds): *Hepatocellular Carcinoma*. New York, John Wiley & Sons, 1976, pp 227-246.
96. Rubel LR, Ishak KG: Thorotrast-associated cholangiocarcinoma: An epidemiologic and clinicopathologic study. *Cancer* 1982; 50:1408-1412.
97. Wee A, Ludwig J, Coffey RJ, et al: Hepatobiliary carcinoma associated with primary sclerosing cholangitis and chronic ulcerative colitis. *Hum Pathol* 1985; 16:719-726.
98. Christophi C, Hughes ER: Hepatobiliary disorders in inflammatory bowel disease. *Surg Gynecol Obstet* 1985; 160:187-193.
99. Klatskin G: Adenocarcinoma of the hepatic duct at its bifurcation within the porta hepatis: An unusual tumor with distinctive clinical and pathological features. *Am J Med* 1965; 38:241-256.
100. Weimbren K, Mutum SS: Pathological aspects of cholangio-carcinoma. *J Pathol* 1983; 139:217-238.
101. Yamada T, Marohisa B, Mato Y, et al: Cytologic detection of small pancreatico duodenal and biliary cancers in the early developmental stage. *Acta Cytol* 1984; 28:435-442.
102. Ishak KG, Glunz PR: Hepatoblastoma and hepatocarcinoma in infancy and childhood: Report of 47 cases. *Cancer* 1967; 20:396-422.
103. Weinberg AG, Finegold MJ: Primary hepatic tumors of childhood. *Hum Pathol* 1983; 14:512-537.
104. Keeling JW: Liver tumours in infancy and childhood. *J Pathol* 1970; 103:69-85.
105. Misugi K, Okajima H, Misugi N, et al: Classification of primary malignant tumors of the liver in infancy and childhood. *Cancer* 1967; 20:1760-1771.
106. Price JB Jr, Schullinger JN, Santulli TV: Major hepatic resections for neoplasia in children. *Arch Surg* 1982; 117:1139-1141.
107. Randolph J, Chandra R, Leiken S: Malignant liver tumors in infants and children. *World J Surg* 1980; 4:71-81.
108. Weinblatt ME, Siegel SE, Siegel MM, et al: Preoperative chemotherapy for unresectable primary hepatic malignancies in children. *Cancer* 1982; 50:1061-1064.
109. Andrassy RJ, Brennan LP, Siegal MM, et al: Preoperative chemotherapy for hepatoblastoma in children: Report of six cases. *J Pediatr Surg* 1980; 15:517-522.
110. Morita K, Okabe I, Ochino J, et al: The proposed Japanese TNM classification of primary liver carcinoma in infants and children. *Jpn J Clin Oncol* 1983; 13:361-369.

111. Ito H, Toda T, Kishikawa T, et al: A case of mesenchymal hamartoma of the liver with a review of the reported cases in Japan. *J Jpn Soc Pediatr Surg* 1979; 15:997.
112. Hart WR: Primary endodermal sinus (yolk sac) tumor of the liver. *Cancer* 1975; 35:1453–1458.
113. Ishak KG: Mesenchymal tumors of the liver, in Okuda K, Peters RL (eds): *Hepatocellular Carcinoma*. New York, John Wiley & Sons, 1976, pp 247–307.
114. Chen KTK: Hepatic leiomyosarcoma. *J Surg Oncol* 1983; 24:325–328.
115. Bodker A, Boiesen PT: A primary fibrosarcoma of the liver. *Hepato-gastroenterology* 1981; 28:218–220.
116. Alberti-Flor JJ, O'Hara MF, Weaver F, et al: Malignant fibrous histiocytoma of the liver. *Gastroenterology* 1985; 89:890–893.
117. Edmondson HA: *Tumors of the liver and intrahepatic bile ducts*. Atlas of Tumor Pathology Fascicle 25, Washington DC, Armed Forces Institute of Pathology, 1985, p 181.
118. Locker GY, Doroshow JH, Zwelling LA, et al: The clinical features of hepatic angiosarcoma: A report of four cases and a review of the English literature. *Medicine* 1979; 58:48–64.
119. Popper H, Thomas LB, Telles NC, et al: Development of hepatic angiosarcoma in man induced by vinyl chloride, thorotrast and arsenic. *Am J Pathol* 1978; 92:349–369.
120. Weiss SW, Enzinger FM: Epithelioid hemangioendothelioma: A vascular tumor often mistaken for a carcinoma. *Cancer* 1982; 50:970–981.
121. Dail DH, Liebow AA, Gmelich JT, et al: Intravascular, bronchiolar, and alveolar tumor of the lung (IVBAT): An analysis of twenty cases of a peculiar sclerosing endothelial tumor. *Cancer* 1983; 51:452–464.
122. Ishak KG, Sesterhenn IA, Goodman ZD, et al: Epithelioid hemangioendothelioma of the liver: A clinicopathologic and followup study of 32 cases. *Hum Pathol* 1984; 15:839–852.
123. Dean PJ, Haggitt RC, O'Hara CJ: Malignant epithelioid hemangioendothelioma of the liver in young women: Relationship to oral contraceptive use. *Am J Surg Pathol* 1985; 9:695–704.
124. Sheahan DG: Personal communication Dec 15, 1988.
125. Koneru B, Casavilla A, Bowman J, et al: Liver transplantation for malignant tumors, in Van Thiel DH, Makowka L (eds): *Gastroenterol Clin North Am* 1988; 17:177–193.
126. Ruyman FB, Raney B, Crist WM, et al: Rhabdomyosarcoma of the biliary tree in childhood: A report from the intergroup rhabdomyosarcoma study. *Cancer* 1985; 56:575–581.
127. Lack EE, Perez-Atayde AR, Schuster SR: Botryoid rhabdomyosarcoma of the biliary tract. *Am J Surg Pathol* 1981; 5:643–652.
128. Brooks JJ: Immunohistochemistry of soft tissue tumors myoglobin as a tumor marker for rhabdomyosarcoma. *Cancer* 1982; 50:1757–1763.
129. Molenarr WM, Osterhuis JW, Osterhuis AM, et al: Mesenchymal and muscle-specific intermediate filaments (vimentin and desmin) in relation to differentiation in childhood rhabdomyosarcomas. *Hum Pathol* 1985; 16: 838–843.
130. Kahn HJ, Yeger H, Kassim O, et al: Immunohistochemical and electron microscopic assessment of childhood rhabdomyosarcoma: Increased frequency of diagnosis over routine histologic methods. *Cancer* 1983; 51:1897–1903.
131. Stocker JT, Ishak KG: Undifferentiated (embryonal) sarcoma of the liver: Report of 31 cases. *Cancer* 1978; 42:336–348.

132. Ellis IO, Cotton RE: Primary malignant mesenchymal tumour of the liver in an elderly female. *Histopathology* 1983; 7:113–121.
133. Chang WWL, Agha FP, Morgan WS: Primary sarcoma of the liver in the adult. *Cancer* 1983; 52:1510–1517.
134. Harris MB, Shen S, Weiner MA, et al: Treatment of primary undifferentiated sarcoma of the liver with surgery and chemotherapy. *Cancer* 1984; 54:2859–2862.
135. Horowitz ME, Etcubanas E, Webber BL, et al: Hepatic undifferentiated (embryonal) sarcoma and rhabdomyosarcoma in children. *Cancer* 1987; 59:396–402.
136. Starzl TE, Koep LJ, Weil R III, et al: Excisional treatment of cavernous hemangiomas of the liver. *Ann Surg* 1980; 192:25–27.
137. Starzl TE, Iwatsuki S, Shaw BW Jr, et al: Treatment of fibrolamellar hepatoma with partial or total hepatectomy and transplantation of the liver. *Surg Gynecol Obstet* 1986; 162:145–148.
138. Weil R III, Koep LJ, Starzl TE: Liver resection for hepatic adenoma. *Arch Surg* 1979; 114:178–180.
139. Iwatsuki S, Shaw BW Jr, Starzl TE: Experience with 150 liver resections. *Ann Surg* 1983; 197:247–253.
140. Iwatsuki S, Esquivel CO, Gordon RG, et al: Liver resection for metastatic colorectal cancer. *Surgery* 1986; 100:804–810.
141. Iwatsuki S, Starzl TE: Personal experience with 411 hepatic resections. *Ann Surg* 1988; 208:421–434.
142. Adson MA, Weiland LH: Resection of primary solid hepatic tumors. *Am J Surg* 1981; 141:18–21.
143. Lin Y, Chen KM, Chen CC, et al: Role of surgery in the treatment of primary carcinoma of the liver: A 21-year experience. *Br J Surg* 1987; 74:839–842.
144. Trasetek VF, VanHeerden JA, Sheedy PF II, et al: Cavernous hemangiomas of the liver: Resect or observe? *Am J Surg* 1983; 145:49–53.
145. Terblanche J: Liver tumors associated with the use of contraceptive pills. *S Afr Med J* 1978; 53:439–442.
146. Mays ET, Christopherson WM, Barrows GH: Focal nodular hyperplasia: Possible relationship to oral contraceptives. *Am J Clin Pathol* 1974; 61:735–746.
147. Klatskin G: Hepatic tumors: Possible relationship to use of oral contraceptives. *Gastroenterology* 1977; 73:386–394.
148. Henson SW Jr, Gray HK, Dockerty MB: Benign tumors of the liver: IV. Polycystic disease of surgical significance. *Surg Gynecol Obstet* 1957; 104:63–67.
149. Manheimer LH: Solitary non-parasitic cyst of the liver. *Ann Surg* 1953; 137:410–415.
150. Hashemian H, James TGI: Non-parasitic cysts of the liver. *Br J Surg* 1955; 42:405–407.
151. Lin TY, Chen CC, Wang SM: Treatment of nonparasitic cystic disease of the liver: A new approach to therapy with polycystic disease. *Ann Surg* 1968; 168:921–927.
152. Bean WJ, Rodan BA: Hepatic cysts: Treatment with alcohol. *Am J Radiology* 1985; 144:237–241.
153. Vilardeell F: Cysts of the liver: Part II. Echinococcus (Hydatid) cysts of the liver, in Bockus HL (ed): *Gastroenterology*. Philadelphia, WB Saunders Co, 1976, vol 3, pp 570–575.
154. Registry of Hepatic Metastases: Resection of the liver for colorectal carcinoma metastases: A multi-institutional study of indications for resection. *Dis Colon Rectum* 1988; 31:278–288.



155. Foster JH: Survival after liver resection for cancer. *Cancer* 1970; 26:493–502.
156. Foster JH: Survival after liver resection for secondary tumors. *Am J Surg* 1978; 135:389–394.
157. Iwatsuki S, Gordon RD, Shaw BW Jr, et al: Role of liver transplantation in cancer therapy. *Ann Surg* 1985; 202:401–407.
158. Pichlmayr R: Is there a place for liver grafting for malignancy? *Transplant Proc* 1988; 20:478–482.
159. O'Grady JA, Polson RJ, Rolles K, et al: Liver transplantation for malignant disease: Results in 93 consecutive patients. *Ann Surg* 1988; 207:373–379.
160. Huber C, Niederwieser D, Schonitzer D, et al: Liver transplantation followed by high-dose cyclophosphamide, total body irradiation, and autologous bone marrow transplantation for treatment of metastatic breast cancer. *Transplantation* 1984; 37:311–312.

*A new text...*

# **PROGRESS IN GASTROINTESTINAL SURGERY**

By:

**John S. Najarian**

*Regents' Professor and Chairman*

*Department of Surgery*

*University of Minnesota Medical School*

**John P. Delaney**

*Professor*

*Department of Surgery*

*University of Minnesota School*

Based upon the 52nd Annual Continuation Course in Surgery presented at the University of Minnesota, this volume offers a state-of-the-art review of gastrointestinal surgery. The leading authorities in the field contribute to this work which covers both recent advances and controversial topics in this emerging surgical specialty.

Contributions are also featured by the distinguished University of Minnesota faculty.

Doctor Najarian is a world-renowned surgeon acclaimed for his work in the area of transplantation.

1989 apx. 360 pp./illustrations \$29.50

Prices quoted are in U.S. dollars. Canadian orders will be billed in Canadian funds at the current approximate exchange rate. Prepaid orders shipped postage free. All orders charged an 8% handling fee. IL, TN, and MA residents will be billed appropriate sales tax. All prices quoted are subject to change.

Order this text **FREE ON  
30-DAY APPROVAL!**

**To order, fill in this form and mail or call toll-free 1-800-622-5410 Monday through Friday (Continental U.S., Virgin Islands, and Puerto Rico only). In Illinois, call collect 312-726-9746.**

NAME \_\_\_\_\_

ADDRESS \_\_\_\_\_

CITY /  
STATE \_\_\_\_\_

ZIP /  
PHONE \_\_\_\_\_

\_\_\_\_\_*Najarian: Progress in  
Gastrointestinal Surgery (NVY-  
1)...\$29.50*

Mail to:

**YEAR BOOK**

**MEDICAL**

**PUBLISHERS**

200 North LaSalle Street,  
Chicago, Illinois, 60601

BGP1

## ***Now you can organize your Current Problems in Surgery® journals for quick, convenient access!***

To fully benefit from the resourceful information your *Current Problems in Surgery*® journals provide, you need to be able to quickly access and organize them for fast, convenient reference. To answer this need, Year Book presents *Current Problems*® custom binders! These new binders are an inexpensive way to enhance the value of your journal subscription.

### **Accessible**

*Current Problems*® binders store 12 issues (2 full years worth) of journals in one convenient place. No longer will you be searching for that particular issue - it will be on your bookshelf for efficient reference!

### **Long-Lasting**

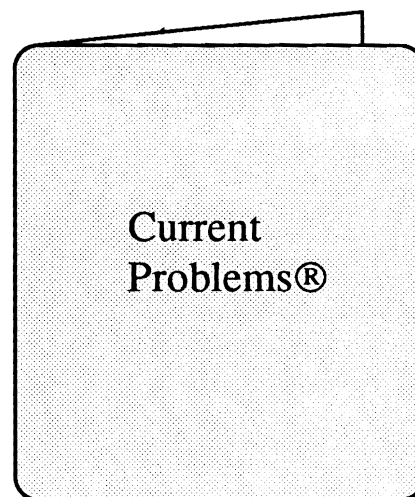
Not only are *Current Problems*® binders designed to hold 12 issues of *Current Problems in Surgery*® journals, they are also constructed of sturdy vinyl that will last for years to come.

### **Inexpensive**

You can protect and organize your *Current Problems*® journals for only \$14.95 - a small price to pay in order to store 2 years worth of critical information!

**FREE  
ON 30-DAY  
APPROVAL!**

**Introducing  
*Current Problems*®  
custom binders!**



*One 6x9 inch binder  
holds 2 years worth of issues!*

### **ORDERING INFORMATION:**

To order, simply fill out the business reply card found in this journal. To order by phone, call toll-free 1-800-622-5410 Monday through Friday (Continental U.S., Virgin Islands and Puerto Rico only). In Illinois, call collect 312-726-9746.

BGP1

# Current Problems in Surgery<sup>®</sup>

**Year Book**  
**Medical Publishers, Inc.**  
200 N. LaSalle St.  
Chicago, Illinois 60601

**CPS**

0011-3840  
0-8151-9903-1