

922-~~922~~

19

---

## Auxiliary Vascular Allografts in Renal Transplantation

---

Lewis W. Teperman, Robert D. Gordon, J. Wallis Marsh,  
Andreas G. Tzakis, Leonard Makowka, Andrei Stieber,  
Shunzabura Iwatsuki, and Thomas E. Starzl

Vascular allografts were first used in humans to replace the diseased aorta [1]. Although short term results were good, most of these grafts eventually deteriorated as a consequence of immunologic injury.

Vascular allografts, however, have continued to be used in organ transplantation. Kidneys with injured or multiple renal arteries can often be reconstructed and successfully implanted with the use of an auxiliary arterial allograft. Furthermore, the right renal vein is often too short to allow implantation of a kidney without excessive tension. In this instance, vein grafts can be used to lengthen the renal vein.

We herein report our experience with 149 consecutive renal transplants. The incidence and indications for the use of auxiliary arterial or venous grafts and a comparison of outcome with transplants not requiring the use of such grafts is reviewed.

### MATERIALS AND METHODS

We reviewed 149 consecutive non-matched cadaveric renal transplants in 142 patients performed on the general surgical service at the University Health Center of Pittsburgh from June 1984 to July 1986. There were 142 primary grafts, 6 secondary grafts, and 1 tertiary graft. Follow-up extended through December 1986. There were 92 (64.8%) male and 50 (35.2%) female recipients with ages ranging from 2 to 66 years (mean  $39.2 \pm 14.5$ , S.D.). All patients were treated with combination immunosuppression with cyclosporine-prednisone as previously described [2]. Since November 1984, we have used OKT3 monoclonal antibody (Orthoclone OKT3, Ortho Pharmaceuticals, Raritan, NJ) for the treatment of steroid-

### Harvesting of Iliac Grafts

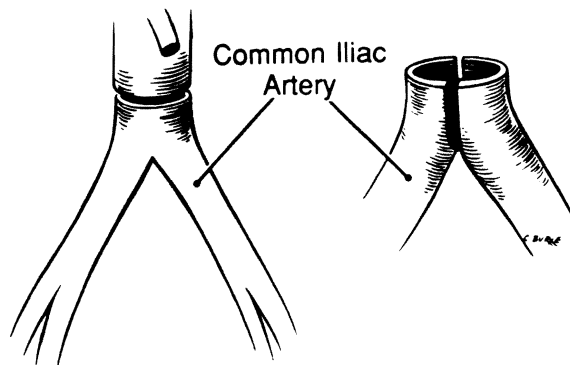


Figure 19.1. Harvest and division of donor iliac arteries.

resistant acute cellular rejection. A small number of patients with severe rejection or cyclosporine intolerance were also treated with low dose azathioprine.

Vascular grafts including the aortoiliac vessels and the iliocaval veins were procured immediately after completing the cadaver donor nephrectomy and were stored in Terasaki medium at 4°C (Figure 19.1). Grafts were discarded if not used within 1 week of harvest. Whenever possible, grafts from the same donor as the renal allograft were used, but if these were not available, ABO blood group matched grafts were used.

Short renal veins were reconstructed with direct extensions of allograft vena cava or interposition iliac vein grafts (Figures 19.2 and 19.3). Repair of an arterial injury is shown in Figure 19.4. Arterial grafts were also occasionally required because of atherosclerosis. En-bloc pediatric renal grafts were implanted on a stalk of aorta and vena cava as previously described [3].

Statistical analysis (chi-square, t-test, and life table survival analysis) was performed on an IBM/PC-AT microcomputer using SPSS PC+ (SPSS, Inc., Chicago, IL) and BMDP (BMDP Statistical Software, Los Angeles, CA).

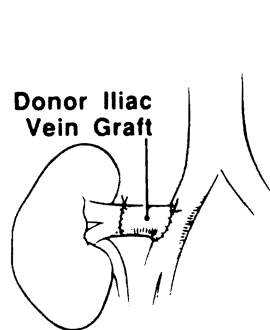


Figure 19.2. Lengthening of a short right renal vein by direct extension of the vena cava.

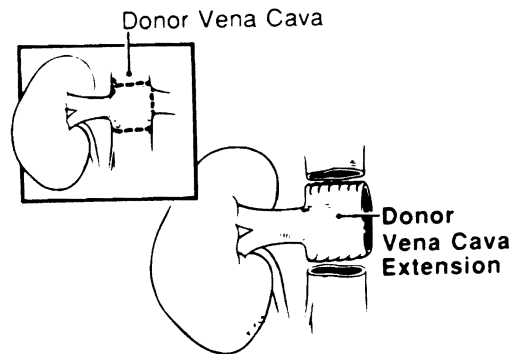
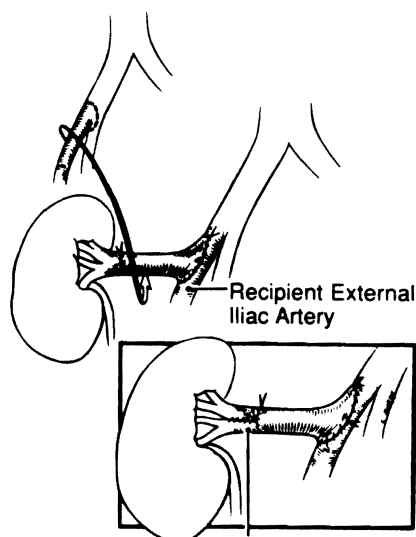


Figure 19.3. Lengthening of a short right renal vein by use of an auxiliary interposition iliac vein graft.



*Patient*  
dead. The  
vascular  
years). A  
auxiliary  
graft is 9.  
*Renal*  
function  
(76.2%)  
107 renal  
42 renal  
19.5B).  
function:  
ing trans;  
*Venou*  
iliac vein  
still func  
been lost  
*Arteri*  
harvestin  
*En-bl*  
allograft-



Repair of Donor Renal Artery Harvesting Injury

Figure 19.4. Repair of harvesting injury to the renal artery using an auxiliary interposition arterial graft.

## RESULTS

**Patient survival.** If the 142 patients, 131 (92.3%) are living and 11 (7.7%) are dead. There is no difference in the mean age of patients who required an auxiliary vascular graft ( $38.7 \pm 13.9$ , S.D. years) and those who did not ( $40.2 \pm 16.0$ , S.D. years). Actuarial survival at one year for the 101 patients who did not require an auxiliary vascular graft is 92.7% and for the 41 patients requiring a venous or arterial graft is 94.3% ( $p=NS$ , Figure 19.5A).

**Renal function and graft survival.** Of the renal transplants, 104 (69.8%) are still functioning, including 72 (67.3%) done without an auxiliary vascular graft and 32 (76.2%) done with such a graft (Table 19.1). Actuarial survival at one year for the 107 renal transplants not requiring an auxiliary vascular graft is 69.2% and for the 42 renal transplants requiring a venous or arterial graft is 75.4% ( $p=NS$ , Figure 19.5B). There is no significant difference between mean serum creatinine for functioning transplants without a vascular graft ( $2.5 \pm 1.5$ , S.D. mg/dl) and functioning transplants with a vascular graft ( $2.2 \pm 0.1$ , S.D. mg/dl).

**Venous reconstructions.** Venous grafts, including 19 vena caval extensions and 11 iliac vein interposition grafts, were used in 30 (20.2%) cases. Of these grafts, 27 are still functioning, 2 were lost to rejection, and 1 to death of the patient. None have been lost to thrombosis.

**Arterial reconstructions.** Arterial allografts were used in 5 (3.4%) cases to salvage harvesting injuries. All of these grafts are still functioning.

**En-bloc pediatric grafts in adults.** Seven en-bloc transplants of pediatric renal allografts into adult patients were performed. One graft was lost to venous throm-

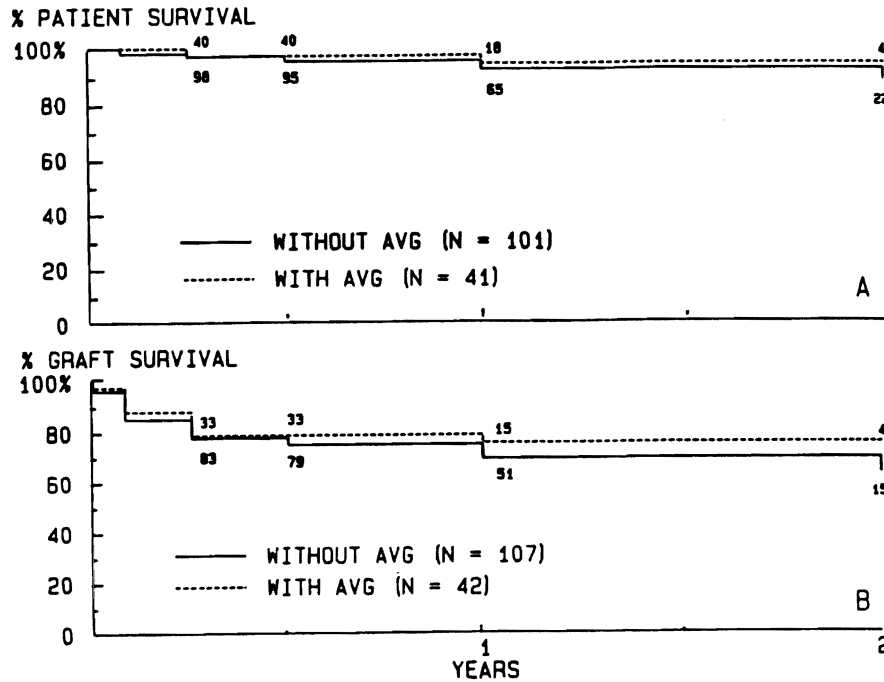


Figure 19.5. Actuarial patient survival (A) and actuarial graft survival (B) for renal transplants which required or did not require use of an auxiliary vascular graft (AVG). Use of an AVG had no significant effect on either patient or graft survival.

Table 19.1. Kidney Status

Status	No Vascular Graft	Vascular Graft
Functioning	72 (67.3%)	32 (76.2%)
Rejection, not retransplanted	13 (12.1%)	6 (14.3%)
Retransplanted for rejection	6 (5.6%)	0 (0%)
Died, graft functioning	6 (5.6%)	1 (2.4%)
Primary failure	2 (1.9%)	1 (2.4%)
Arterial thrombosis	3 (2.8%)	1 (2.4%)
Venous thrombosis	3 (2.8%)	1 (2.4%)
Artery and venous thrombosis	2 (1.9%)	0 (0%)
Creatinine	2.47 ± 1.55	2.15 ± 0.09

basis, probably as a result of being died with a functioning

Vascular homograft banking techniques were major complications as dissection of small vessels

A classical study by [7] that patency was directly until 1975 that William immunological rejection therapy, graft durability endothelium [7].

It is now believed that component that activated theory suggests that in The T-helper cells rejection [9].

Cyclosporine, which suppresses T-helper cell effects [10-12]. In this of auxiliary vascular cyclosporine and predicted use of such grafts affected demand for cadaveric to salvage all available important method for contribute to unnecessary.

Excessive tension or vein thrombosis after preserved in continuity vena cava is a simple necessary. We have with renal veins extended

Pediatric kidneys are and because many trans adults. The use of an vena cava is one method for kidneys. This method of ing of the complex grafts has been favorable

The follow-up for thrombosis or infections have yet been

basis, probably as a result of improper positioning of the graft at surgery. One patient died with a functioning graft.

### DISCUSSION

Vascular homografts were first performed in animals in 1896 [4]. Homograft banking techniques were developed in the 1940s and have improved since. The major complications associated with use of vascular homografts are thrombosis and dissection of small vessels and calcification and rupture of larger vessels [5].

A classical study by Szilagyi in 1957 on the outcome of 150 homografts found that patency was directly proportional to the diameter of the graft [6]. But it was not until 1975 that Williams showed that early graft occlusion was, in fact, due to immunological rejection. Williams demonstrated that under immunosuppressive therapy, graft durability was enhanced and graft endothelium was replaced by host endothelium [7].

It is now believed that vascular endothelium may be the antigen-contributing component that activates the T-cell in an Ia-restricted manner [8]. An alternative theory suggests that immunization is initiated by Ia positive passenger leukocytes. The T-helper cells recognize HLA-DR antigen and the graft undergoes acute rejection [9].

Cyclosporine, which has been in use by some transplant centers since 1978, suppresses T-helper cell function and also has a variety of other immunosuppressive effects [10-12]. In this report, we have presented a favorable experience with the use of auxiliary vascular grafts in a series of renal transplants performed with cyclosporine and prednisone immunosuppression. We found no evidence that the use of such grafts affects transplant function or graft outcome. The continuing excess demand for cadaveric organs for transplantation mandates that every effort be made to salvage all available organs. The use of auxiliary vascular allografts is an important method for salvage of vascular injuries and other complications that contribute to unnecessary organ wastage.

Excessive tension on the short right renal vein is the most frequent cause of renal vein thrombosis after transplantation in our experience. If the vena cava has been preserved in continuity with the right renal vein at harvest, a direct extension of the vena cava is a simple way to lengthen it; otherwise, an interposition vein graft is necessary. We have not experienced any cases of renal vein thrombosis in grafts with renal veins extended by either of these methods.

Pediatric kidneys are frequently wasted for lack of a suitable pediatric recipient and because many transplant surgeons are reluctant to put very small kidneys into adults. The use of an en-bloc pair of pediatric kidneys on a stalk of aorta and vena cava is one method for implanting a larger renal mass into adults using pediatric kidneys. This method, however, requires two ureteral implants and careful positioning of the complex graft to avoid vascular thrombosis. Our experience with these grafts has been favorable, and we continue to use them when possible.

The follow-up for this series has been 6 months to 2 years. No graft aneurysms or infections have yet been encountered. Additional follow-up will be necessary to

determine the long-term fate of many of these grafts. Doppler ultrasound is currently in use to monitor flow in the grafts and to screen for other complications.

### SUMMARY

A series of 149 consecutive, non-matched cadaveric renal transplants in 142 patients was reviewed. Auxiliary arterial or venous grafts were used in 42 cases. There was no difference in patient or graft survival or in the quality of graft function between transplants with and without auxiliary grafts. No arterial auxiliary grafts or renal vein extensions were lost to thrombosis. One en-bloc pair of pediatric kidneys was lost to venous thrombosis, probably because of malposition at implantation. There were no graft aneurysms or infections. The use of auxiliary vascular allografts is a safe and effective method for salvaging renal grafts that might otherwise be wasted.

### ACKNOWLEDGEMENTS

This study was supported by Research Project Grant No. AM-29961 from the National Institutes of Health, Bethesda, Maryland. Leonard Makowka is the recipient of a Centennial Fellowship from the Medical Research Council of Canada.

### REFERENCES

1. DeBakey ME, Cooley DA. 1953. Surgical treatment of aneurysm of the abdominal aorta by resection and restoration of continuity with homograft. *Surg Gyn Obstet* 97:257.
2. Starzl TE, Klintmalm GBC, Weil R III, Porter KA, Iwatsuki S, Schroeter GP, Fernandez-Buene C, MacHugh N. 1091. CyclosporinA and steroid therapy in 66 cadaver kidney recipients. *Surg Gyn Obstet* 153:486.
3. Wengerter K, Matas AJ, Tellis VA, Quinn T, Soberman R, Veith FJ. 1986. Transplantation of pediatric donor kidneys to adult recipients: Is there a critical donor age? *Ann Surg* 204(2):172-175.
4. Brian, Jaboulay M. 1896. Recherches experimental sur la sutre et la greffe arterielles. *Lyon Medical* 97.
5. Deterling RA, Clauss RH. 1970. Long-term fate of aortic and arterial homografts. *J Cardiovasc Surg* 11:35.
6. Szilagyi DE, McDonald RT, Smith BF, Whitcomb JG. 1957. Biological fate of human arterial homografts. *Arch Surg* 75:506.
7. Williams GM, ter Haar A, Krajewski G, Parks LC, Roth J. 1975. Rejection and repair of endothelium in major vessel transplants. *Surgery* 78:694.
8. Pober JS, Gimbrone MA, Cotran RS, et al. 1983. Ia expression by vascular endothelium is inducible by activated T- cells and by human gamma interferon. *J Exp Med* 157:1339.
9. Hirschberh H, Braathen LR, Thorsby E. 1982. Antigen presentation by vascular endothelial cells and epidermal Langerhans cells: The role of HLA-DR. *Immunol Rev* 62:57.
10. Mason DW, Morris PJ. 1984. Inhibition of accumulation, in rat kidney allografts, of specific but not nonspecific cytotoxic T-cells by cyclosporine. *Transplantation* 87:16.
11. Beem GH, Cook LA, Palladino MA. 1983. Cyclosporine inhibits interleukin-2 and interferon gamma by human thymocytes. *Transplant Proc* 15:2387.
12. Kalman VK, Klimpel GR. 1983. Effects of cyclosporine on the production of various interferons. *Transplant Proc* 15:2383.

Vascular injuries continue to be a major concern for surgeons world wide [1]. The complexity of the many complications and ultimate vascular trauma is an area that a periodic exchange of meetings.

It would appear that the world when there is a war, areas around the world, weaponry used in urban areas for arterial and venous and therapeutic techniques for arteries and veins that re-

Extremity vascular trauma, arteries and veins treated, logistical problems and a majority of patients survive. Whether in civilian or military, approximately 90% treated. difference, however, do not. extremity vascular injuries "traps," used frequently directed more toward the

Hippocrates supposed an army. Subsequently, history. In the 20th cent