

#476 908

## Treatment of Hepatic Epithelioid Hemangioendothelioma With Liver Transplantation

IGNAZIO R. MARINO, MD, SATORU TODO, MD, ANDREAS G. TZAKIS, MD, GORAN KLINTMALM, MD, PHD,\*  
MICHAEL KELLEHER, MD, SHUNZABURO IWATSUKI, MD, THOMAS E. STARZL, MD, PHD,  
AND CARLOS O. ESQUIVEL, MD, PHD

Ten patients received liver transplants for unresectable epithelioid hemangioendothelioma (EHE). At the time of transplantation, four patients had microscopic metastases to the hilar lymph nodes, and one of the four also had metastases to a rib. The fifth patient had metastases to the lung, pleura, and diaphragm. The remaining five patients were believed to be free of metastatic disease. Two of these five patients died of metastatic disease at 3 and 16 months, respectively, after transplantation. Interestingly, all five patients with metastatic involvement are currently alive  $40.6 \pm 22$  months (mean  $\pm$  standard error of mean [SEM]) after transplantation, although one of these patients currently has metastatic disease to the lungs and mediastinum. Thus, the projected 5-year actuarial survival rate is 76%, with two patients at risk after the third year. In conclusion, liver transplantation is a reasonable procedure for bulky, otherwise unresectable, EHE even in the presence of metastatic disease.

*Cancer* 62:2079-2084, 1988.

**E**PITHELIOID HEMANGIOENDOTHELIOMA (EHE) is a soft tissue malignant tumor that is characterized by its epithelioid appearance and vascular endothelial histogenesis. It was specifically identified histologically by Weiss and Enzinger<sup>1</sup> in 1982. In 1975, a similar if not identical tumor occurring in the lung was described by Dail and Liebow who proposed the term "intravascular bronchioalveolar tumor."<sup>2</sup> In 1984, Ishak *et al.* reported for the first time 32 patients with primary EHE of the liver.<sup>3</sup>

The current definition of EHE as a unique form of vascular lesion consisting of endothelial cells is based on the presence of immunohistochemical staining for Factor VIII-related antigen in the tumor.<sup>1-5</sup> Using this specific definition, only a few cases of EHE have been described in the literature, particularly as primary hepatic malignancies, although EHE may occur more often than it is reported.<sup>1,6-8</sup>

The therapeutic approaches used in the clinical management of this tumor have been variable because of the

limited clinical experience with this malignancy. There have been two separate single case reports of patients with EHE who have been treated with orthotopic liver transplantation (OLT).<sup>9,10</sup>

Herein we report the results with hepatic transplantation in ten patients with EHE. In each of these patients, the tumor was unresectable using any of several different conventional subtotal hepatectomy procedures.

### Patients and Methods

#### Patient Profile

Between March 1963 and October 1987, 1281 patients had transplants performed at either the University of Colorado or University of Pittsburgh Health Centers or the Baylor University Medical Center. In 91 of these patients (7.1%), the indication for OLT was a primary hepatic malignancy that could not otherwise be resected. The histologic diagnosis in ten of these 91 patients was EHE. Only one of these ten patients has been reported currently.<sup>3</sup> Their ages ranged from 24 to 52.5 years (median age, 29.5 years). Six of ten patients were female.

After OLT, the immunosuppression consisted of azathioprine and prednisone for the first two patients and cyclosporine and prednisone for the subsequent eight patients.

All ten patients were evaluated initially in different institutions. They were referred to one of our hospitals for liver transplantation because the malignant lesions were deemed unresectable except as a total hepatectomy. Before

From the Department of Surgery, Pathology, and Medicine, University Health Center of Pittsburgh, and the Veterans Administration Medical Center, Pittsburgh, Pennsylvania; and the \*Department of Surgery, Baylor University Medical Center, Dallas, Texas.

Supported by Research Grants from the Veterans Administration and Project Grant No. AM 29961 from the National Institutes of Health, Bethesda, Maryland.

Address for reprints: Carlos O. Esquivel, MD, PhD, Pacific Presbyterian Medical Center, Division of Transplantation, Box 7999, San Francisco, CA 94120.

Accepted for publication April 14, 1988.

TABLE 1. Clinical Features

Patient no.	First symptoms	Preoperative				
		Total bilirubin (mg/dl)	SGOT (IU/l)	SGPT (IU/l)	AP (IU/l)	GGT (IU/l)
1	Abdominal pain, vomiting, jaundice	17.9	80	30	425	—
2	Chest and abdominal pain, palpable mass	0.3	20	25	221	150
3	Pyrosis, transient jaundice	0.7	97	54	810	459
4	15-lb weight loss, pruritus, spider angiomas, ascites	0.5	18	10	273	176
5	Incidental investigation for trauma causing back pain, otherwise asymptomatic	0.6	21	16	80	25
6	Right subcostal pain	0.4	25	19	100	46
7	Abdominal pain, 10-lb weight loss, anorexia	0.7	57	93	388	201
8	Abdominal pain	0.9	48	35	352	101
9	Abdominal pain	0.6	16	16	119	42

SGOT: serum glutamic oxaloacetic transaminase; SGPT: serum glu-

tamic pyruvic transaminase; AP: alkaline phosphatase; GGT: gamma-glutamyl transpeptidase.

transplantation, the patients were subjected to a thorough evaluation to rule out the presence of any metastatic disease. This included an ultrasonographic examination of the abdomen (with particular attention to the presence of any vascular lesions), computerized axial tomography of the chest, abdomen, and head, a bone scan for the detection of metastases, complete upper and lower gastrointestinal endoscopy, and chest roentgenograms. Occasionally, an arteriogram or laparoscopy also was performed.

The correct diagnosis of EHE was known preoperatively in six patients. In two other patients, the diagnosis was not made until the excised liver was examined histologically and Factor VIII-related antigen was detected immunocytochemically as being present within the tumor cells. The initial histopathologic diagnosis was erroneous in two patients (the first two). A recent review of their histologic material showed the correct diagnosis.

#### *Clinical Features, Operation, and Findings*

Complete clinical data were available in nine of ten patients. In one patient, only the operative records and histopathology were available.

As shown in Table 1, pain was the most common initial symptom of the disease, with a nonspecific intestinal disturbance being the second most common complaint. Two patients had jaundice, one with ascites and one with a palpable hepatic mass. Another patient experienced obstruction of large intrahepatic biliary ducts with cholestasis and symptoms of veno-occlusive disease. Liver injury variables often showed nonspecific abnormalities, and all but one patient had an increased alkaline phosphatase and gamma-glutamyl transpeptidase (GGT) level.

Although a standard protocol for chemotherapy has not been instituted yet, four patients did receive postoperative adjuvant chemotherapy after transplantation con-

sisting of Adriamycin (Adria Laboratories, Columbus, OH) (Table 2). The one patient who originally was thought to have a fibrolamellar hepatocellular carcinoma received intraarterial hepatic chemotherapy and 2400 cGy of external hepatic radiation before OLT. The patient with metastasis to the left second rib underwent rib resection after radiation therapy to the area.

The technique for liver replacement was similar to that reported elsewhere, except that the recipient hepatectomy included the gastrohepatic ligament, the hepatoduodenal ligament, and skeletonization of all vascular structures in the hepatic hilum.<sup>11</sup> The common bile duct was transected distally as it passed behind the duodenum and the biliary reconstruction was performed using an end-to-side donor choledochus to a recipient Roux-en-Y jejunal limb. In one patient, a portion of the diaphragm was excised because of local tumor invasion. The diaphragmatic defect in this case was repaired with Marlex mesh.

One patient was known to have metastatic disease involving the left second rib before OLT. In addition, four other patients were found to have metastases at the time of the transplant surgery. One of these had involvement of the lung, pleura, and diaphragm. The other three had microscopic involvement of their hilar lymph nodes (Table 2).

#### *Pathologic Studies*

Six of 10 patients had a preoperative biopsy diagnosis of EHE. In each of those patients, the original surgical pathology was reviewed before OLT. All hepatectomy specimens underwent a complete pathologic examination according to a standard liver transplant protocol used at our institutions. In each case, the tumor was weighed and fixed in 10% formalin. The extent of tumor within the liver, the surgical margins, and the number of lymph nodes

TABLE 2. Gross Pathologic Findings and Clinical Results

Patient no.	Liver weight	Hepatic tumor location	Pre-OLT metastases	Chemotherapy	Recurrence	Metastases location	Survival status
1	4800	Multifocal	Abdomen, lungs, pleura and diaphragm invasion	No	No	—	11 yr, alive
2	1720	Multifocal	No	No	No	—	4 yr, alive
3	1610	Multifocal	No	Yes	12 mo after OLT	Liver, lungs	16 mo, dead
4	6670	Multifocal	Hilar lymph nodes, common bile duct	Yes	18 mo after OLT	Mediastinum, right lung	2 yr, alive
5	1450	Multifocal	Extrahepatic lymph nodes, left lung	No	No	—	16 mo, alive
6	1600	Multifocal	Hilar lymph nodes	Yes	No	—	16 mo, alive
7	1400	Multifocal	Extrahepatic lymph nodes	Yes	No	—	15 mo, alive
8	2240	Multifocal	No	No	No	—	9 mo, alive
9	1800	Multifocal	No	No	No	—	1 mo, alive
10	2510	Multifocal	No	No	2 mo	Lungs, liver, spleen, pancreas, kidney, pericardium, brain	3 mo, dead

OLT: orthotopic liver transplantation.

included were documented and appropriate sections were removed and studied. Besides routine hematoxylin and eosin (H & E) stains, eight of ten cases were studied immunocytochemically for Factor VIII-related antigen to confirm the diagnosis. In each of these cases, cytokeratin and alpha-fetoprotein immunocytochemistry was negative. Those patients in whom recurrent disease developed had all of their pathologic material reviewed to ensure that the recurrences were identical to the original tumor.

#### Statistical Analysis

The collected data were incorporated into the existing liver transplant database of the Department of Surgery at the University of Pittsburgh. Data analysis was performed using the Life Table and Survival Function Programs of the BMDP statistical software package (Statistical Software, Inc., Los Angeles, CA).<sup>12</sup>

### Results

#### Survival and Tumor Recurrence

The projected 5-year actuarial survival rate of the ten patients is 76%, with eight patients at risk after the first year, three after the second year, and two after the third year (Fig. 1).

Table 2 reports the clinical outcome. None of the ten patients died of a complication related to the transplant procedure. Two died of recurrence of EHE at 3 and 16 months, respectively, after transplantation. Recurrence in the first of these two patients was noticed 2 months after OLT, with tumor being found in the liver allograft and lungs. The postmortem examination in this case also showed tumor involving the brain, spleen, pancreas, kidneys, and pericardium. The second patient had a recurrence in the hepatic allograft 12 months after surgery. An autopsy also documented recurrent tumor in the lungs.

Six patients are alive at 1 month (Patient 9), 9 months (Patient 8), 16 months (Patients 5 and 6), 4 years (Patient 2), and 11 years (Patient 1), respectively, after transplantation without any evidence of recurrence. Our first case might represent a case of tumor regression after surgery because this patient had intra-abdominal, pleural, and pulmonary metastases at the time of OLT (Table 2). This patient, who did not receive adjuvant therapy, is alive and free of malignant disease 11 years after OLT.

Two patients are alive despite the presence of recurrent or residual tumor. The first patient (Patient 4) underwent transplantation 2 years ago and recurrence was first detected in the mediastinum 18 months after transplantation. In June 1987, he underwent surgery for resection of this metastatic mass, during which several additional metastases in the right lung were detected. The second patient (Patient 7), who was transplanted 15 months ago, had a rib metastasis that was recognized before OLT (Table 2).

% PATIENT SURVIVAL

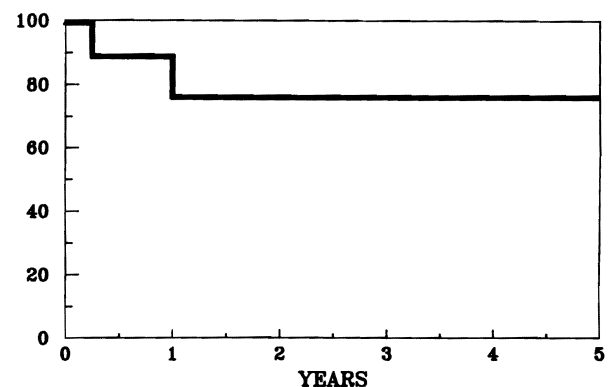


FIG. 1. Five-year actuarial survival rate of ten patients with hepatic EHE who had OLT.

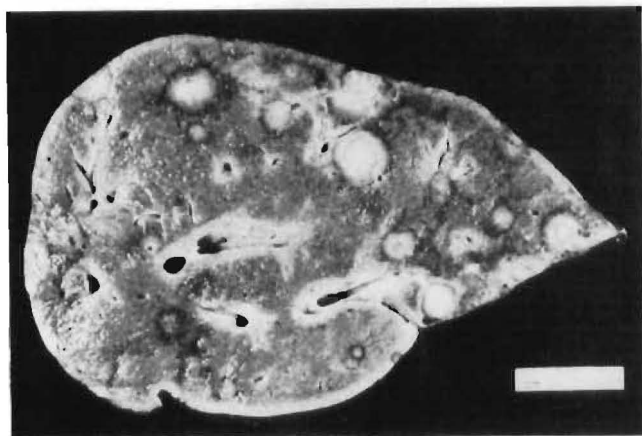


FIG. 2. Cross-section of liver showing multiple white nodules, some of which are seen in continuity with the capsule.

### Pathologic Findings

The liver resection specimens weighed between 1400 and 6670 g. The capsular surface in all hepatectomy specimens was smooth except for the presence of some white tumor depressions ranging from 0.5 to 2.5 cm in diameter. Cross-sections of the resected liver showed multiple non-encapsulated white nodules throughout both lobes ranging from 1 to 5 cm in greatest diameter. Some of these nodules were seen in continuity with the hepatic capsule. No preferential localization within the hepatic parenchyma was evident (Fig. 2). The intervening nonmalignant hepatic parenchyma was normal except for cholestasis.

On low-power examination, the tumor nodules appeared to have a variable cellularity with ill-defined mar-

gins. At the gross anatomic periphery of the tumor, infiltration of adjacent hepatic sinusoids (Fig. 3) was evident, whereas the central areas showed both necrosis and sclerosis. Tumor invasion into the central and portal veins was observed with varying degrees of occlusion of their lumens being a common finding (Fig. 3 *Inset*).

The tumor cells were surrounded by cleft-like spaces (Fig. 4) and formed cellular tufts (Fig. 4 *Inset*) reminiscent of "glomeruloid bodies," some of which contained percolating erythrocytes. In the more cellular areas, tumor cells were arranged in solid cords and nests and had an abundant eosinophilic cytoplasm mimicking "epithelioid cells." In other less cellular areas having a sclerotic matrix, single neoplastic cells had irregular cytoplasmic processes. Some of these cells had intracytoplasmic vacuoles that were mucicarmine negative (Fig. 5 and Fig. 5 *Inset*) and appeared to contain erythrocytes. Eight of ten patients in this series were immunocytochemically positive for Factor VIII-related antigen.<sup>5</sup> In each of these cases, only some cells were positive for Factor VIII-related antigen.

### Discussion

Hepatic malignancy is perhaps the only diagnostic indication for OLT still surrounded by controversy. The controversy exists because hepatocellular carcinomas and bile ductular cancers are associated with a high recurrence rate after OLT.<sup>13</sup> Little information is available about the prognosis for other tumors, and essentially nothing relative to EHE treated with hepatic transplantation exists in the literature.<sup>3,10</sup>

The initial clinical presentation of EHE is rather nonspecific. The true incidence of this tumor is not yet known,

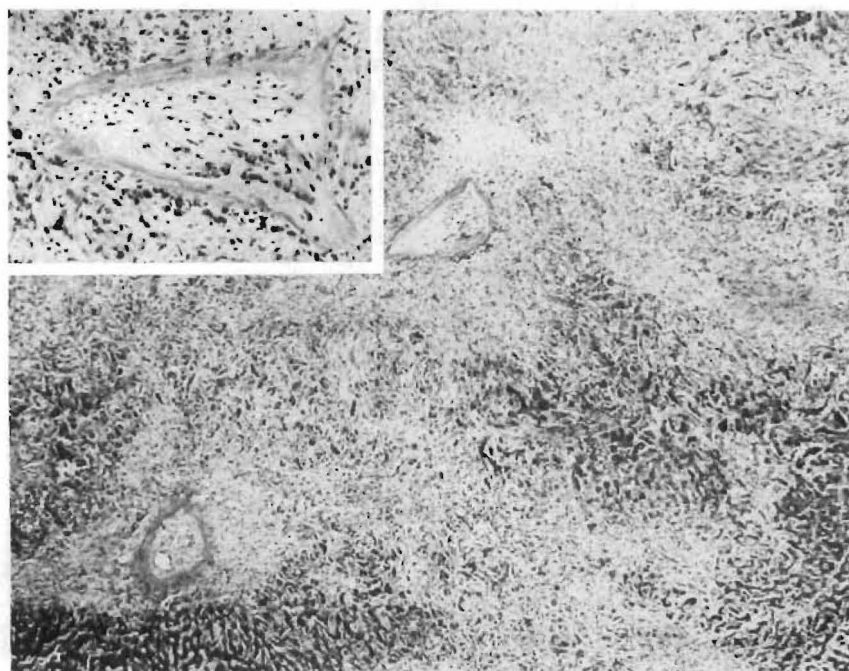
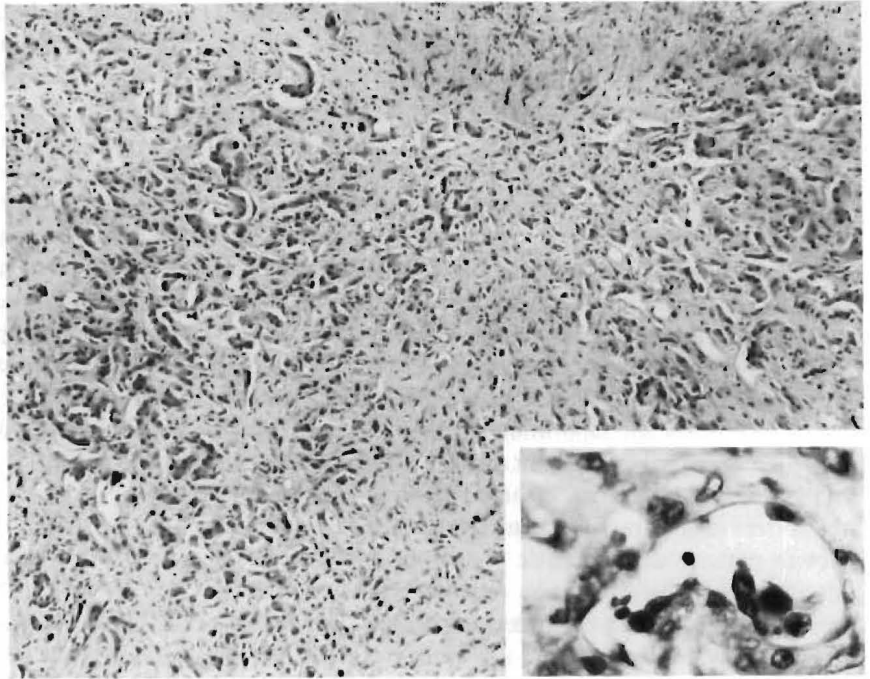


FIG. 3. Low-power appearance of a tumor nodule showing extension of the tumor (pale areas) into the liver parenchyma (dark area). The tumor is more cellular at the periphery (H & E,  $\times 35$ ). *Inset*: Typically, the central veins are densely sclerotic. However, on closer inspection, atypical tumor cells can be seen in the lumen and along the wall of the vein (H & E,  $\times 125$ ).

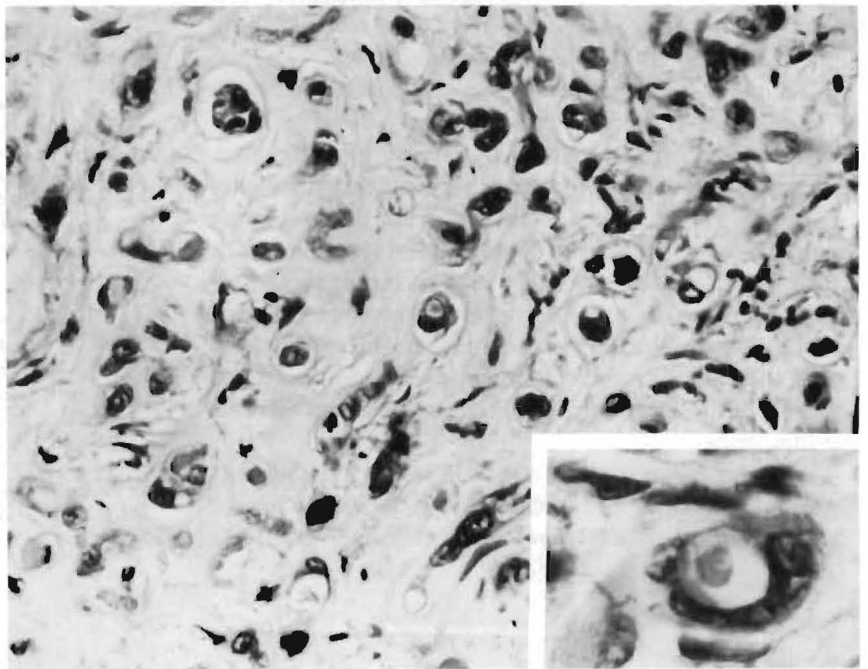
FIG. 4. Clusters of tumor cells projecting into cleft-like spaces within fibrocellular background stroma (H & E,  $\times 125$ ). *Inset*: "Glomeruloid bodies" formed by cytologically atypical epithelioid tumor cells (H & E,  $\times 500$ ).



and it is highly probably that many of these tumors have been mistakenly diagnosed, especially before 1984.<sup>3</sup> The pathologic diagnosis of this neoplasm often requires a wedge biopsy of the tumor as the architectural features of the tumor seen in larger biopsies, such as an intravascular or intrasinusoidal growth pattern, should alert the pathologist to the diagnosis. Given the variable cellularity within any given tumor nodule, a single area of sampling as obtained by "tru cut" liver biopsy may not be

diagnostic<sup>10</sup> as only a more fibrous area may be examined and incorrectly diagnosed as being a benign condition such as perivenular fibrosis rather than a malignant vascular tumor. Furthermore, experience with fine-needle aspiration for cytologic examination of this tumor is limited. Relying on only the cytologic appearance of this tumor may result in overgrading the lesion as being a highly malignant angiosarcoma rather than a slow growing more benign, albeit malignant, lesion.

FIG. 5. Single tumor cells with intracytoplasmic vacuoles, signet ring type, in a dense hyalinized stroma (H & E,  $\times 500$ ). *Inset*: High-power appearance of a tumor cell containing an intracytoplasmic lumen within which an erythrocyte is seen (H & E,  $\times 1250$ ).



Three patients in the current series had an incorrect diagnosis before examination of the entire liver. The diagnoses in these cases included cholangiocarcinoma, sclerosing hepatoma, and a high-grade angiocarcinoma. Immunohistochemistry used to detect Factor VIII-related antigen is a prerequisite for the confirmation of EHE and was diagnostic in each case so studied in this series.<sup>1-5</sup> Specifically, this technique allows us to reject incorrect initial diagnoses of sclerosing hepatic carcinoma and cholangiocarcinoma. The latter is typically carcinoma embryonic antigen, epithelial membrane antigen, and cytokeratin positive, whereas hepatocellular carcinomas are frequently alpha-fetoprotein positive immunocytochemically. The histologic separation of EHE from high-grade angiosarcoma may be difficult as was the situation in one of the current cases. Criteria that are useful in establishing the correct diagnosis of angiosarcoma include the variable growth pattern along hepatic plates, the presence of an interanastomizing pattern on reticular stains, anaplastic cytologic features, and the presence of mitotic figures. This separation is important given the more aggressive course of angiosarcoma. It is apparent from the current series that EHE has a spectrum of biologic behaviors but, in general, has a more benign biologic behavior than angiosarcoma does. The conventional histopathologic variables useful for grading malignancy, such as necrosis, cytologic pleomorphism, and mitotic figures, are not evident in EHE.

A direct comparison between the report of Ishak *et al.* of 32 patients with EHE and the current series is not possible. However, it is interesting to notice that only nine of 32 (28%) of the Ishak *et al.* patients survived more than 5 years. The actuarial survival rate of the EHE patients treated with OLT in the current series is satisfactory and compares favorably with that seen for OLT recipients who received transplants for nonmalignant disease.<sup>14</sup>

It remains difficult to propose a single standard therapeutic approach for these tumors because they occur unusually and their natural history is very unpredictable. Long-term survival without any specific therapy has been reported.<sup>3</sup> The histologic features of EHE do not appear to predict tumor behavior.<sup>1</sup> Thus, it is not possible to use the histologic characteristics of a given tumor as a guide for therapeutic decisions. As a result, there are different opinions regarding the therapeutic recommendations for EHE that vary from only observation in asymptomatic cases,<sup>15</sup> to the excision of localized lesions<sup>1</sup> and OLT as in this series.

We believe that surgical resection is the best course of action. If due to its multifocal location the tumor cannot be removed by a subtotal resection, it seems reasonable

to consider liver transplantation based on the experience reported herein. This therapeutic approach can be used even in the presence of a localized number of small metastases because the natural course of the disease is so favorable. This was demonstrated by one of the patients in this series who, despite metastatic disease at the time of OLT, is currently alive 11 years later and has an apparent spontaneous resolution of the metastases.

We do not have sufficient data to define a role for chemotherapy, radiotherapy, or both in the treatment of this tumor. Thus, prospective studies should be performed.

In conclusion, OLT appears to be a reasonable therapeutic approach for hepatic EHE when the tumor is not resectable except as a total hepatectomy.

#### REFERENCES

1. Weiss SW, Enzinger FM. Epithelioid hemangioendothelioma: A vascular tumor often mistaken for a carcinoma. *Cancer* 1982; 50:970-981.
2. Dail DH, Liebow AA. Intravascular bronchioalveolar tumor (Abstr). *Am J Pathol* 1975; 78:6.
3. Ishak KG, Sesterhenn IA, Goodman MZD, Rabin L, Stromeyer FW. Epithelioid hemangioendothelioma of the liver: A clinicopathologic and follow-up study of 32 cases. *Hum Pathol* 1984; 15:839-852.
4. Fukayama M, Nihei Z, Takizawa T, Kawaguchi K, Harada H, Koike M. Malignant epithelioid hemangioendothelioma of the liver, spreading through the hepatic veins. *Virchows Arch [A]* 1984; 404:275-287.
5. Sternberger LA, Hardy PH, Cuculis JJ, Meyer HG. The unlabelled antibody enzyme method of immunohistochemistry: Preparation and properties of soluble antigen and antibody complex (horseradish peroxidase-anti-horseradish oxidase) and its use in identification of spirochaetes. *J Histochem Cytochem* 1970; 18:315-333.
6. Echeverria RA, Arean VM, Galindo L. Hepatic tumors of long duration with eventual metastases: Two cases of leiomyosarcomatosis possibly arising from hamartomas of liver. *Am J Clin Pathol* 1978; 69:624-631.
7. Ludwig J, Grier MW, Hoffman HN, McGill DB. Calcified mixed malignant tumor of the liver. *Arch Pathol* 1975; 99:162-166.
8. Persaud V, Bateson EM, Bankay CD. Pleural mesothelioma associated with massive hepatic calcification and unusual metastases. *Cancer* 1970; 26:920-928.
9. Dean PJ, Haggitt RC, O'Hara CG. Malignant epithelioid hemangioendothelioma of the liver in young women: Relationship to oral contraceptive use. *Am J Surg Pathol* 1985; 9:695-704.
10. Clements D, Hubscher S, West R, Elias E, McMaster P. Epithelioid hemangioendothelioma: A case report. *J Hepatol* 1986; 2:441-449.
11. Starzl TE, Iwatsuki S, Esquivel CO *et al.* Refinements in the surgical technique of liver transplantation. *Semin Liver Dis* 1985; 5:349-356.
12. Dixon WJ. BMDP Statistical Software Manual. Los Angeles: University of California Press, 1985.
13. Esquivel CO, Iwatsuki S, Marino IR, Markus BH, Van Thiel D, Starzl TE. Liver transplantation for hepatocellular carcinoma and other primary hepatic malignancies. In: Sugahara K, ed. *New Trends in Gastroenterology*. Kyoto, Japan: Shinkosha, 1987; 323-332.
14. Starzl TE, Iwatsuki S, Shaw BW Jr, Gordon RD, Esquivel CO. Immunosuppression and other nonsurgical factors in the improved results of liver transplantation. *Semin Liver Dis* 1985; 5:334-343.
15. Dail DH, Liebow AA, Gmelich JT *et al.* Intravascular, bronchiolar, and alveolar tumor of the lung (IVBAT). *Cancer* 1983; 51:452-464.