

Intrahepatic bile duct strictures after human orthotopic liver transplantation

Recurrence of primary sclerosing cholangitis or unusual presentation of allograft rejection?

J. Lerut^{1*}, A. J. Demetris², A. C. Stieber¹, J. W. Marsh¹, R. D. Gordon¹, C. O. Esquivel¹, S. Iwatsuki¹, and T. E. Starzl¹

¹ Department of Surgery and ² Department of Pathology, University Health Center of Pittsburgh, Pittsburgh, PA 15213, USA

Abstract. One of 55 patients transplanted for sclerosing cholangitis during the cyclosporin-steroid era (March 1980–June 1986) developed intrahepatic biliary strictures in the absence of allograft rejection within the 1st year posttransplantation. Although many causes underlie biliary pathology in the postoperative period (i.e., arterial injury, ischemia, chronic rejection, cholangitis), recurrent disease remains a possibility.

Key words: Human orthotopic liver transplantation – Complications – Biliary tract – Primary sclerosing cholangitis – Recurrent disease – Rejection.

Biliary tract complications after orthotopic liver transplantation (OLT) are frequent; they are mostly due to inappropriate reconstruction of the extrahepatic bile duct [1]. Recurrent disease in the allograft is common after OLT in malignant biliary tract disease but is very rare in benign biliary tract disease [2–6]. A patient presenting with a possible recurrent sclerosing cholangitis some months after liver transplantation is discussed.

Case report

On August 21, 1984, a 34 year-old male underwent OLT with a graft of identical blood group, type A, for end-stage primary sclerosing cholangitis (PSC) (Fig. 1). He had been under medical management for severe ulcerative colitis since the age of 21. His past medical history revealed an uncomplicated cholecystectomy at age 27 and an appendectomy for perforative appendicitis

* *Present address:* Universitätsklinik für Viszerale und Transplantationschirurgie, Inselspital, Freiburgstrasse, CH-3010 Bern, Switzerland

Offprint requests to: T. E. Starzl, Department of Surgery, Falk Clinic 4 West, 3601 Fifth Avenue, Pittsburgh, PA 15213, USA

2 years later. During the latter postoperative recovery he presented with jaundice, attributed to sclerosing cholangitis. Because of persistence of the jaundice, percutaneous biliary drainage was attempted in 1982 and 1983. Finally, a choledochojejunostomy was carried out using a transhepatic, trans-anastomotic U-tube, which was removed 4 months later. Repeated evaluations showed a progressive worsening of the liver disease, justifying a recommendation for treatment by OLT. The cholestasis worsened (total bilirubin, 23 mg%; alkaline phosphatases, 2020 IU). Osteoporosis was responsible for compression fractures of thoracic vertebrae 8–10 and an aseptic necrosis of the left femoral head. Gastrointestinal bleeding due to portal hypertension also occurred.

The liver grafting was uneventful: the allograft had a single arterial supply, the liver was reperfused after the completion of all four vascular anastomoses, and cold and warm ischemic times were within normal limits. The former Roux-en-Y-jejunal loop was reused for the end-to-side choledochojejunostomy. The anastomosis was carried out using a 12 French-feeding-tube stent and interrupted, absorbable 5–0 vicryl sutures. An intraoperative cholangiogram showed a normal intra- and extrahepatic biliary tree, an absence of leakage, and a patent anastomosis. The postoperative course was uneventful and the patient was discharged 20 days postsurgery with nearly normal liver function tests (LFT) [total/conjugated bilirubin (bil.t./conj), 1.7/0.9 mg%; alkaline phosphatase (alk.phos.) 228 IU; transaminases (SGPT/SGOT), 150/25 IU/l; Gamma-glutamyl-transpeptidase (GGTP), 64 IU; protime (PT), 11 s]. The rapid postoperative normalization of transaminases precluded major ischemic injury to the allograft during procurement and reimplantation.

On January 11, 1985, the patient was readmitted due to abnormal LFT (bil.t., 1.4 mg%; alk.phos., 725 IU; SGPT/SGOT, 400/268 IU/l; GGTP, 204 IU; PT, 12 s). The patient had no cholestatic symptoms. The biochemical abnormalities were attributed to an impaired cyclosporin absorption due to large amounts of diarrhea associated with a flu. Adjustment of the cyclosporin dose almost immediately normalized liver function (bil.t./conj, 0.5/0.1 mg%; alk.phos., 341 IU; GGTP, 257 IU; SGPT/SGOT, 51/28 IU/l). A liver biopsy showed early changes of bile duct obstruction, such as duct dilatation, portal edema, marginal duct proliferation, and ductal ectasia. There were no remarkable signs of rejection, viral infection, or drug toxicity.

On February 20, 1985, the patient was rehospitalized due to persistent liver function abnormalities in the absence of clinical symptoms (bil.t./conj., 1.8/0.2 mg%; alk.phos., 587 IU; SGPT/SGOT, 462/321 IU/l; GGTP, 365 IU; PT, 11.4 s). A liver

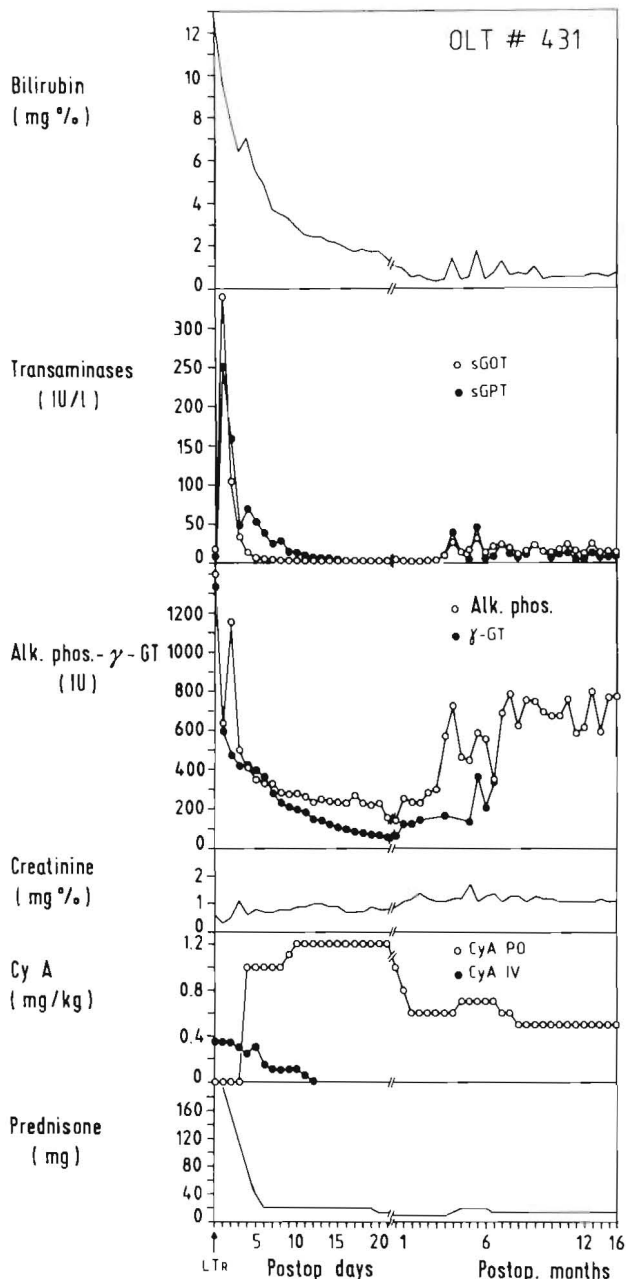


Fig. 1. Biochemical evolution and immunosuppressive regimen of the case report

biopsy confirmed changes consistent with biliary obstruction; portal fibrosis had worsened. There were almost no signs of graft rejection. Direct visualization of the biliary system by transhepatic cholangiography revealed poor filling of the peripheral ducts and alternation of biliary tract strictures and dilations. The extrahepatic biliary tract and choledochojejunostomy were normal. Brush cytology of the intra- and extrahepatic bile ducts was negative for tumor cells. Repeated Doppler ultrasonography showed normal arterial and venous allograft vascularization.

Beginning April 1985 the patient underwent a new transhepatic cholangiogram due to the development of cholangitis. The anastomosis was widely patent. On April 19, 1985, the stent was removed. A cholangiogram carried out at that time (Fig. 2) con-

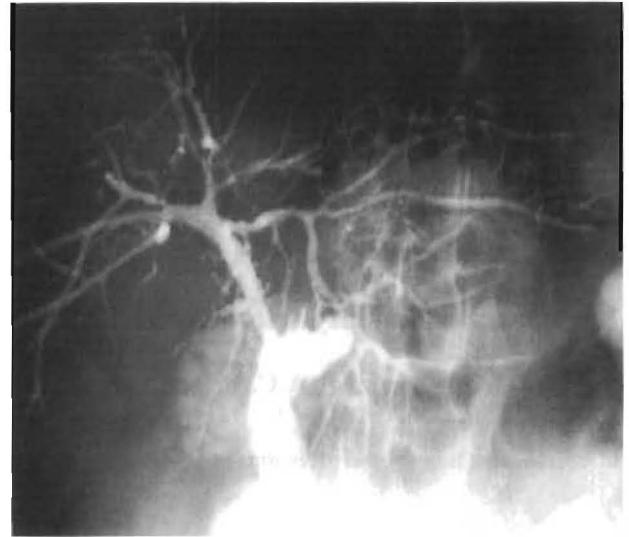

Fig. 2. Percutaneous cholangiogram carried out in March 1985, confirming the peripheral intrahepatic biliary strictures in the presence of a patent biliodigestive anastomosis. The internal stent migrated into the jejunal limb

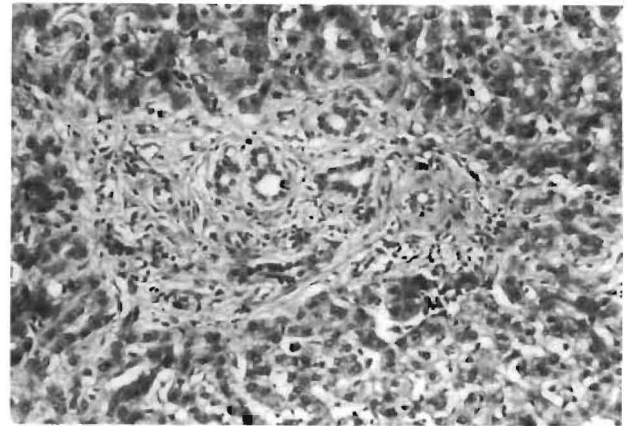


Fig. 3. Needle liver biopsy specimen, showing portal tract with fibrosis, ductular proliferation, and absence of infiltrate as well as of vascular changes (H & E, $\times 96$)

firmed peripheral intrahepatic biliary strictures in the presence of a patent choledochojejunostomy. The liver function abnormalities persisted on different occasions between May 1985 and June 1987 (bil.t., 0.5 mg%; alk.phos., 910 IU; SGPT/SGOT, 145/82 IU/l; PT, 11.7 s). Histological examinations showed progression of the biliary obstruction and advancing portal fibrosis without evidence of graft rejection (Fig. 3). On one occasion, a lymphogranulomatoid nodule was seen near an interlobular bile duct (Fig. 4). Portal inflammation was otherwise minimal. More than 3.5 years posttransplantation, the graft is still functioning well, which precludes a further histological examination of the organ as well as modification of the low-dose steroid-cyclosporin therapy.

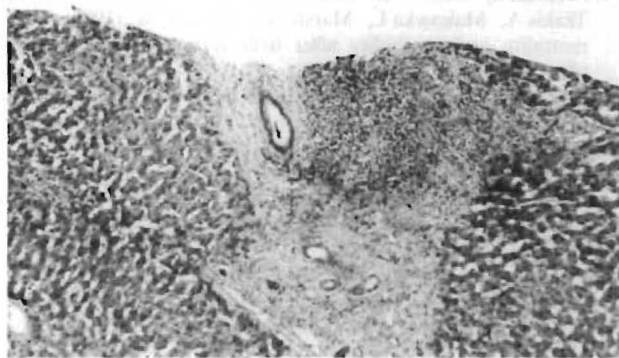


Fig. 4. Allograft liver biopsy taken 10 months postoperatively, showing portal fibrosis, mild duct proliferation and dilation. A single lymphogranulomatoid inflammatory aggregate is seen near, but not involving, a septal bile duct (H & E, $\times 48$)

All posttransplant biopsies were obtained according to a protocol defining the criteria of allograft rejection [6] and prepared with hematoxylin-eosin stain (H & E), trichrome orcein and rhodanine. All specimens were evaluated for cirrhosis, marginal ductular proliferation, granulomas, portal or septal lymphoid nodules, the presence and location of cholestasis, portal and/or central vein subendothelial infiltration, mononuclear inflammatory cell damage to bile ducts, ductular loss, and chronic arterial and/or venous lesions as seen in allograft rejection.

Discussion

Changes in the peripheral intrahepatic bile ducts of a liver allograft may be the expression of different phenomena: (a) inadequate liver procurement, (b) inappropriate biliary tract reconstruction or (c) arterialization of the allograft, (d) (chronic) allograft rejection, (e) recurrent primary biliary tract disease, and (f) primary or recurrent viral hepatitis [1, 2, 6, 7, 9].

Small intrahepatic ducts may be the primary target of damaging immune reactions [6, 8]. Rejection can cause rapid destruction of the interlobular bile ducts associated with severe centrilobular cholestasis, marginal ductular proliferation, and nongranulomatous cell inflammation in the portal tracts. This rapidly progressive destruction, consistent with a major clinical and chemical cholestatic picture, has been described as the "vanishing bile duct syndrome" [8]. These alterations occur in different forms related to different stages of development or to different immunosuppressive regimens. They may even present as nonsuppurative destructive cholangitis, resembling the changes seen in primary biliary cirrhosis (PBC) [6, 10]. Only 4 of 604 grafts (0.6%) carried out during the period between March

1980 and June 1986 had radiological abnormalities of the intrahepatic bile ducts similar to those described in this case report. These abnormalities occurred within the first 12 months after transplantations carried out for a disease not primarily affecting the biliary tract. All four patients had histologically proven graft rejection prior to the development of intrahepatic biliary strictures [2].

Recurrent biliary malignancy in the allograft is common after OLT; however, recurrent, primary, benign biliary tract disease in the allograft is exceptional [6, 7]. Three cases of possible, late recurrence of PBC after OLT have been reported, although the changes in the bile duct fell short of those characteristic of PBC [5]. The liver biopsy changes in these patients were similar to those seen in chronic rejection, viral hepatitis, and graft-versus-host disease. Thus, the recurrence of PBC in liver allografts has not formally been proven [5]. This was also confirmed in our recently reviewed series of 76 patients grafted during the period from March 1980 to September 1985 for advanced PBC. No instance of recurrent PBC was either clinically or histologically documented in the 52 surviving recipients with follow-ups of 1–6.5 years [3].

During the same period, 55 patients were grafted for primary sclerosing cholangitis (PSC) [4]. Only 1 of 37 surviving recipients with follow-ups of 1–5 years developed chemical and radiological abnormalities of the primary disease 6 months post-transplantation. The first posttransplant biopsy showed minimal or no rejection and early changes in biliary obstruction.

In the subsequent percutaneous biopsies, the changes in biliary obstruction and portal fibrosis progressed despite the absence of rejection. The paraductal lymphogranulomatoid nodule seen in this case was never observed in our previous transplant biopsies [6]. Evidence of rejection or hepatitis could not be demonstrated in any of the allograft biopsies. The normalization of liver function following cyclosporin dose adjustment could be explained by a mitigated rejection episode. However, the serial biopsy changes in the absence of allograft rejection are indicative of biliary tract pathology that would be consistent with but by no means diagnostic of recurrent sclerosing cholangitis. It is possible that the etiology of the intrahepatic bile duct strictures in this patient was due to recurrent PSC, as no other cause or process capable of causing strictures could be identified. However, since there are so many other causes of biliary strictures and because the diagnosis depends on a clinicopathological correlation, we cannot be certain. This observation suggests that the recurrence of PSC in

allografts, if possible, is rare. However, chronic allograft rejection must be ruled out by serial liver biopsies, as peripheral intrahepatic biliary strictures can be an unusual consequence (or some modified form) of graft rejection. In the present case report, the long-term stabilization of the patient's condition as well as of his liver function, despite identically low immunosuppression, argues against this hypothesis.

References

1. Demetris AJ, Jaffe R, Starzl TE (1987) A review of adult and pediatric post transplant liver pathology. In: Rosen PP, Fechner RE (eds) Pathology annual, vol 22. Appleton-Lange, Norwalk, pp 347-386
2. Esquivel CO, Van Thiel DH, Bernardos A, Demetris AJ, Iwatsuki S, Markus B, Gordon RD, Marsh JW, Makowka L, Tzakis A, Todo S, Gavaler J, Starzl TE (1988) Liver transplantation for primary biliary cirrhosis. *Hepatology*
3. Fennell RH, Shires RH, Vierling JH (1983) Relationship of pretransplant hepatobiliary disease to bile duct damage occurring in the liver allograft. *Hepatology* 3: 84-89
4. Iwatsuki S, Starzl TE, Gordon RD, Esquivel CO, Todo S, Tzakis A, Makowka L, Marsh JW, Miller CM (1987) Late mortality and morbidity after liver transplantation. *Transplant Proc* 19: 2373-2378
5. Lerut J, Gordon RD, Iwatsuki S, Shaw BW Jr, Esquivel CO, Tzakis A, Starzl TE (1987) Biliary tract complications in 393 human liver transplantations. *Transplantation* 43: 47-51
6. Marsh JW, Iwatsuki S, Makowka L, Esquivel CO, Gordon RD, Todo S, Tzakis A, Van Thiel D, Starzl TE (1988) Orthotopic liver transplantation for primary sclerosing cholangitis. *Ann Surg* 207: 21-25
7. Neuberger J, Portmann B, MacDougall B, Calne RY, Williams R (1982) Recurrence of primary biliary cirrhosis after liver transplantation. *N Engl J Med* 306: 1-4
8. Porter KA (1969) Pathology of the orthotopic homograft and heterograft. In: Starzl TE, Putnam CW (eds) Experience in liver transplantation. Saunders, Philadelphia, pp 422-471
9. Portmann B, Neuberger JM, Williams R (1983) Intrahepatic bile duct lesions. In: Calne RY (ed) Liver transplantation. Grune & Stratton, New York London, pp 279-287
10. Starzl TE, Iwatsuki S, Shaw BW Jr, Gordon RD, Esquivel CO, Todo S, Kam I, Lynch S (1985) Factors in the development of liver transplantation. *Transplant Proc* 17: 107-119