

863 # ~~0000~~

# WHICH LIVER-DISEASE PATIENTS NEED A TRANSPLANT?

Organ replacement has come into its own as a treatment for end-stage liver disease. A team of experts from two leading transplant centers reviews current indications, survival rates, and methods of evaluating candidates for operation.

By Leonard Makowka, MD, PhD, Linda Sher, MD, Delawir Kahn, MD, Thomas E. Starzl, MD, PhD, et al\*

**L**iver transplantation is now the treatment of choice for many patients with end-stage liver disease.<sup>1-3</sup> Since the introduction of the immunosuppressive agent cyclosporine in 1978,<sup>4</sup> organ replacement has gained acceptance as the only intervention that can cure this relentless, chronic process and offer the chance of complete rehabilitation.

One-year survival rates of 70% or better have been reported for many groups of patients.<sup>5,6</sup> The majority can look forward to long, productive lives. The operation now can be recommended to persons formerly thought to be at

prohibitively high risk because of their particular disease, prior abdominal surgery, extreme youth, or advanced age. The youngest and oldest recipients of successful transplants at our institutions were 3 $\frac{1}{2}$  weeks and 76 years old.

Refinements in surgical technique have contributed to these improved results, particularly the introduction of the venovenous bypass,<sup>7</sup> improvements in biliary tract reconstruction,<sup>8</sup> and the development of methods for multiple organ procurement.<sup>9,11</sup> For a description of how the operations on donor and recipient are done, see "Current surgical technique," page 78.

## PATIENT EVALUATION

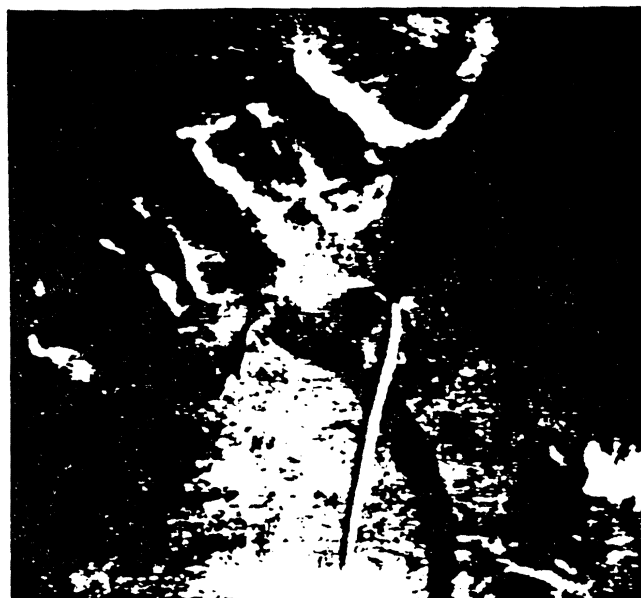Even though most patients are referred to a transplant center with an established diagnosis, each person is thoroughly evaluated to assess suitability and fitness for operation. We take a careful his-

tory, paying special attention to alcohol and drug abuse, blood-product transfusions, concomitant illnesses, previous operations, medications, and exposure to toxins. During the physical examination, we look for xanthomas and Kayser-Fleischer rings, which are associated with primary biliary cirrhosis and Wilson's disease, respectively.

Mental status is assessed. We grade encephalopathy, according to its severity (Table 1), and try to identify precipitating causes, such as dehydration, infection, or gastrointestinal (GI) bleeding. More severe cases are managed in the intensive care unit; endotracheal intubation is sometimes necessary to prevent aspiration. Patients with encephalopathy are given neomycin and lactulose.

Routine blood tests include CBC, full coagulation profile, liver-function tests, measures of serum electrolytes and glucose, and

\*A.G. Teakis, MD, S. Todd, MD, J.W. Marsh, MD, A. Sreber, MD, E. Koneru, MD, G.E.G. Kinnaman, MD, Ph.D., S.M. Staschak, RN, S. Iwaraki, MD, R.D. Gordon, MD, and D. Van Thiel, MD. The authors are from the department of surgery, University Health Center of Pittsburgh, University of Pittsburgh; the Veterans Administration Medical Center, Pittsburgh; and Baylor University Medical Center, Dallas.



**FIGURE 1.** When a transplant candidate's portal vein cannot be visualized on ultrasound or Doppler examination, angiography is performed. At left, the venous phase of a splenic arteriogram demonstrates confluence of the inferior mesenteric vein and the splenic vein with absence of the portal vein (arrow).

At right, the venous phase of a superior mesenteric arteriogram in the same patient demonstrates absence of the superior mesenteric vein (arrow). Such abnormalities can often be repaired by thrombectomy, anastomosis, or a graft at the time of operation.

renal-function tests. Abnormalities in the coagulation profile should be corrected before any invasive procedures are done. Renal-function abnormalities are investigated, in order to distinguish among the hepatorenal syndrome, simple dehydration (due to chronic diuretic therapy and ascites), and intrinsic renal disease. Morbidity and mortality are increased in patients who develop renal failure during the posttransplant period. Patients who have end-stage liver disease and irreversible renal failure can be managed successfully with combined liver-kidney transplantation.<sup>12</sup>

We have found the indocyanine clearance study useful in assessing residual liver function and in

determining the urgency of a patient's need for a transplant. After an initial loading dose of 0.5 mg/kg, indocyanine retention is measured at five-minute intervals. A retention of 5% or greater at 20 minutes constitutes evidence of liver disease; values greater than 30% or 50% indicate significant or very severe liver disease, respectively.

Upper-GI endoscopy is performed to detect esophageal varices. Persons who have a history of variceal bleeding or have severe varices at endoscopy are treated with injection sclerotherapy. Colonoscopy may be performed to detect other pathologic conditions, such as inflammatory bowel disease (IBD) or neoplasia in pa-

tients with primary sclerosing cholangitis.

Ultrasound and Doppler studies determine the patency of the portal vein, hepatic artery, hepatic veins, and vena cava. Angiography is reserved for patients whose portal veins cannot be visualized by noninvasive means and for those with previous portosystemic venous shunts; it is important to assess the status of both the shunt and the portal vein.

A thrombosed portal vein (Figure 1), once an absolute contraindication to liver transplantation, is now only a relative contraindication. It is often possible either to perform a thrombectomy on the recipient portal vein, to anastomose the donor portal vein, or to

interpose a graft of donor iliac vein at the confluence of the recipient mesenteric and splenic veins.<sup>13</sup>

The transplant center's social service department evaluates all candidates. Psychiatric assessment and treatment are sometimes sought for patients with psychosocial problems. The most frequent reasons for referral are substance abuse and compliance problems.

Once we have determined that a patient needs a liver transplant, we evaluate pulmonary, cardiac, and renal status in order to gauge surgical risk and to prepare for the operation. We also consider other risk factors—previous abdominal or portosystemic shunt surgery, active infection, and advanced age. Although risk does increase with age, transplantation can succeed with carefully selected patients aged 70 or more.<sup>14</sup> The oldest patient in our series, a 76-year-old woman with primary biliary cirrhosis, is doing extremely well more than 18 months after operation.

The absolute contraindications to liver transplantation are malignant disease outside the liver, a patient's inability to accept or understand the procedure, symptomatic acquired immunodeficiency syndrome, and other systemic diseases or debilitating complications that transplantation cannot reverse. Indications for early hepatic transplantation include major GI bleeding, repeated bouts of encephalopathy, progressive neuropathy, refractory ascites, a recent precipi-

tous deterioration in liver function, rapid progression of bone disease, and severe wasting.

The patient's weight, height, ABO blood group, and liver volume as assessed by ultrasound or computed tomography (CT) (Figure 2) aid in donor-recipient matching.<sup>15</sup> The ultrasound study and CT are also useful means of detecting hepatic tumors and excluding extrahepatic extension.

The results of the evaluation are discussed at a weekly conference attended by the transplant surgeons, hepatologists, nurse coordinators, social workers, anesthesiologists, radiologists, pathologists, critical-care physicians, psychiatrists, and sometimes other specialists. At this meeting, we assess the urgency of the patient's need for a transplant, on the basis of clinical findings and performance status, as described in Table 2.

While awaiting a donor, patients who can be managed at home return to the care of their private physicians, maintaining close communication with the clinic through an assigned nurse coordinator. Others find local accommodations and visit the clinic once or twice a week. Persons in urgent need of transplantation remain in the hospital until a donor becomes available, to ensure that they are in the best possible condition at the time of operation.

#### INDICATIONS FOR TRANSPLANTATION

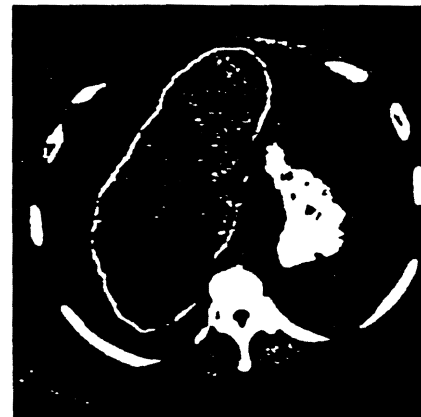
Between March 1980, when cyclosporine-corticosteroid therapy

#### KEYPOINTS

**Key:** A thrombosed portal vein is no longer an absolute contraindication to liver transplantation. Surgical repair at the time of transplantation is usually successful.

**Key:** Reformed alcoholics with Laënnec's cirrhosis can do as well after transplantation as other cirrhotic patients; don't exclude them from consideration.

was introduced, and July 1987, 666 adults and 334 children underwent liver transplantation at programs in Denver and Pittsburgh, and at Baylor University Medical Center in Dallas. In adults, the most common indications for transplantation were postnecrotic cirrhosis, primary biliary cirrhosis, and sclerosing cholangitis; in children, they were



**FIGURE 2.** Computed tomography determines liver volume in a transplant recipient, as part of the donor-recipient matching process.

biliary atresia, inborn errors of metabolism, and cirrhosis (Figure 3). The one- and five-year actuarial survival rates for these 1,000 patients were 71.2% and 62.6%, respectively.<sup>16</sup> Actuarial survival rates by reason for operation appear in Figure 4.

**Postnecrotic cirrhosis.** Most patients with cirrhosis, the most common indication for liver transplantation, have chronic active hepatitis. Some have cryptogenic cirrhosis, and an increasing number have Laennec's cirrhosis.

After transplantation, disease often recurs in persons whose earlier serologic tests were positive for hepatitis B surface antigen (HBsAg). Some patients have undergone retransplantation after recurrence, but the risk of a second recurrence is high. We are currently evaluating whether  $\alpha$ -interferon, administered during the perioperative period to HBsAg-positive patients and the donor livers, will reduce the recurrence rate.

Because of general ill-health, patients with Laennec's cirrhosis are a high-risk group, and alcoholic recidivism is a concern. However, transplantation should be offered to carefully selected patients who have this condition. Experience with our first 41 such individuals suggests that their chances of survival and rehabilitation are as good as those of patients who have nonalcoholic cirrhosis.<sup>10</sup>

**Primary biliary cirrhosis.** An uncommon disease that most often affects middle-aged women,

primary biliary cirrhosis is the second leading indication for transplantation in adults. It is characterized by jaundice, pruritus, hepatomegaly, easy fatigability, and bone disease of varying severity. Although its cause is unknown, it is believed to be an autoimmune disease; antimitochondrial antibodies are found in over 90% of patients. Thyroiditis, lupus erythematosus, scleroderma, renal tubular acidosis, and rheumatoid arthritis are likely concomitant illnesses.

Asymptomatic patients have an excellent life expectancy, and many never develop clinically significant organ damage.<sup>17</sup> For those who do, medical therapy—D-penicillamine, chlorambucil, colchicine, corticosteroids, azathioprine, or cyclosporine—has been advocated, but there is little evidence that these agents are effective.<sup>18</sup> Recent trials with D-penicillamine failed to demonstrate a significant benefit.<sup>19-21</sup> Once the disease has progressed to an advanced stage, with jaundice and ascites, liver transplantation is the treatment of choice. Since advanced age, a debilitated state, and disabling bone disease can complicate postoperative recovery, referral for transplantation should not be delayed.

**Sclerosing cholangitis.** Most common in young men, sclerosing cholangitis frequently occurs in association with other disorders, especially IBD. The incidence of coexisting cholangiocarcinoma has been reported to be about 10%.<sup>22</sup> Clinical findings suggest-

TABLE 1

## GRADING HEPATIC ENCEPHALOPATHY

### Stage I

Agitation  
Mild confusion  
Tremors

### Stage II

Disorientation  
Lethargy  
Asterixis

### Stage III

Delirium  
Somnolence  
Seizures  
Muscle twitching  
Hyperactive reflexes

### Stage IVA

Coma with response to noxious stimuli

### Stage IVB

Coma with no response to noxious stimuli

Source: Adapted from Schuff L, Schuff ER (eds). *Diseases of the Liver*, ed 5. Philadelphia: JB Lippincott Co, 1982, p 449.

ing such a carcinoma include an exceedingly high bilirubin, recent deterioration in liver function, a long history of sclerosing cholangitis, and an elevated level of carcinoembryonic antigen. However,

as these findings may be absent, everyone with sclerosing cholangitis should undergo cholangiography and brush biopsy of suspicious lesions.

The results of transplantation in patients with cholangiocarcinoma have been poor; these individuals should be referred for radiotherapy. We are presently considering preoperative radiotherapy for patients with small, early bile duct cancers, to determine whether such treatment reduces the incidence of tumor recurrence.

Sclerosing cholangitis is an incurable disease. Previous attempts at surgical biliary diversion and hilar reconstruction usually complicate transplantation. Such operations should be avoided except in highly selected patients with well-defined, localized extrahepatic lesions. Operation for associated IBD is best deferred until three to six months after liver transplantation.

**Liver tumors.** Transplantation should be considered for patients with advanced hepatic malignancy and those who have benign tumors that cannot be removed by conventional subtotal resections. Types of tumors for which patients have undergone liver transplantation include hepatocellular carcinoma, cholangiocarcinoma, hemangioendothelioma, neuroendocrine tumors, and multiple adenoma. One patient whose liver had been almost entirely replaced by lymphangioma received a transplant.<sup>23</sup>

Most patients with tumors are excellent candidates for opera-

tion, since portal hypertension and its complications are usually not present. Early survival after transplantation has been good, but long-term survival has been poor because tumors may recur fairly soon after transplantation.

Patients with a hepatic malignancy must be examined thoroughly to determine that the tumor does not extend beyond the confines of the liver. Often, the final decision must be made at surgery. If a suitable donor becomes

available, the surgeon does an exploratory operation, proceeding to transplantation only if there is no evidence of extrahepatic tumor spread.

In general, the survival rate after transplantation for hepatocellular carcinoma has been poor; however, there are exceptions. Patients who receive transplantation for end-stage liver disease and are found to have an incidental primary hepatic tumor have the same survival rate as do oth-

TABLE 2

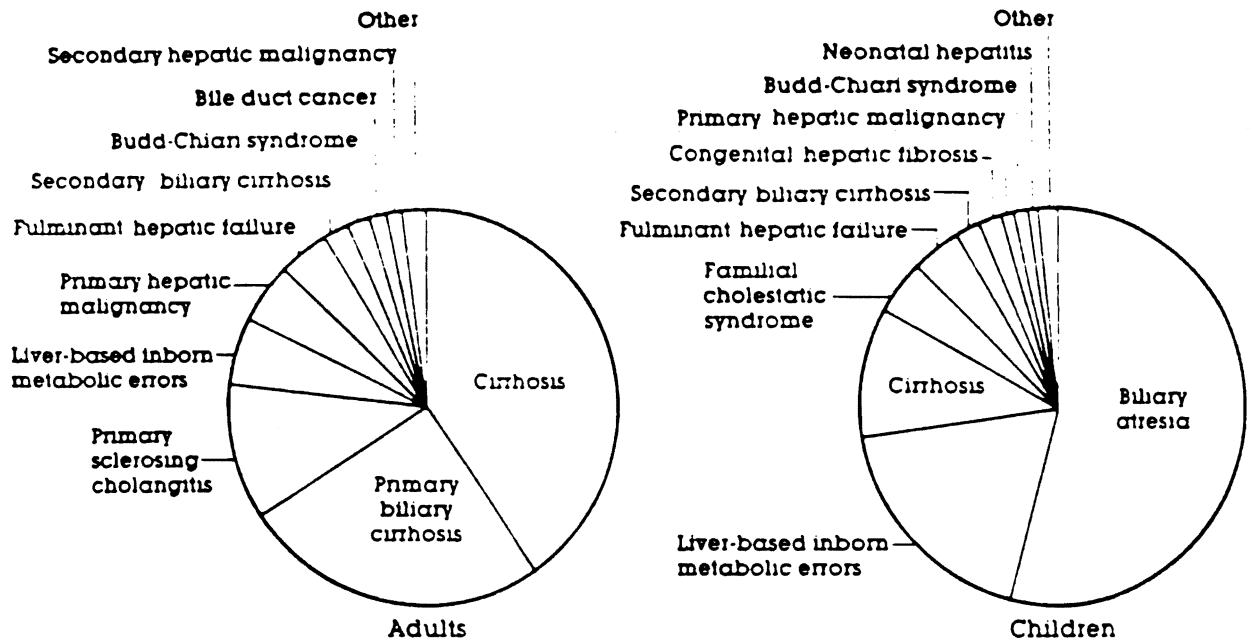
### CLASSIFYING PERFORMANCE IN PATIENTS WITH LIVER DISEASE

Performance level	Adult	Child
1	Working	Working or full-time student; normal growth
2	Partially disabled, capable of self-care	At home most of the time, mild to moderate growth retardation
3	Homebound with attendant, unable to work	Homebound, requires professional care, unable to attend school, moderate to severe growth retardation
4	Hospitalized	Hospitalized
5	Needs intensive care	Needs intensive care
6	On life support	On life support

Source: Adapted from Starzl TE, Gordon RD, Tezak AS, et al: Equitable allocation of extrahepatic organs. With special reference to the liver. *Transplant Proc* 1988; 20:131-138

FIGURE 3

INDICATIONS FOR TRANSPLANTATION



Between March 1980 and July 1987, 666 adults and 334 children underwent liver transplantation at programs in Denver, Pittsburgh and Dallas

Among adults (left), cirrhosis was the most common reason for transplantation, among children (right) biliary atresia

ers with the same original disease, and their tumors have not recurred.

The fibrolamellar variant of hepatocellular carcinoma tends to occur in younger patients and is less aggressive than other malignant lesions. Although tumor generally recurs, palliation for two or more years can be achieved in many patients. Even after recurrence, the quality of life may be good for a prolonged period, which is not the case when other malignancies recur. Liver trans-

plantation for hemangioendothelioma offers similarly favorable results.<sup>24</sup>

Conventional adjuvant chemotherapy and radiotherapy have been used in combination with liver transplantation in an effort to improve survival, but additional follow-up is needed to evaluate their success. Furthermore, immunosuppressive agents given during the posttransplant period may accelerate the growth of extrahepatic nests of malignant cells that were not detected at the

time of transplantation. Improved results may have to await the advent of more selective methods of immunosuppression.

**Biliary atresia.** Nearly all infants and children who receive transplantation for biliary atresia have had a previous operation, usually a portoenterostomy (Kasai procedure). Prior operation in the right upper quadrant, particularly in the hepatic hilum, makes transplantation much more difficult and increases postoperative morbidity. Although a well-timed

and properly performed portoenterostomy can be useful, we advise restraint rather than liberal use of this procedure, especially in patients with established cirrhosis. Replacement of the liver is the treatment of choice for biliary atresia, although the limited availability of very small pediatric donors continues to be a major problem.

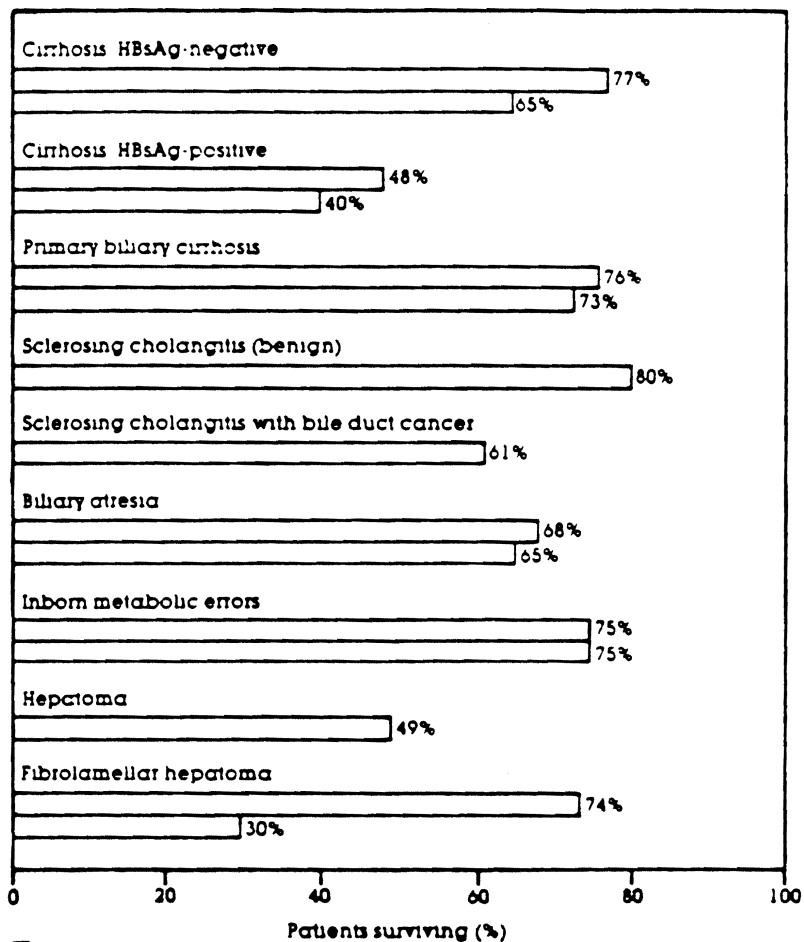
**Inborn errors of metabolism.** Most patients with inborn errors of metabolism are in good health otherwise, and few have had previous upper-abdominal surgery. Thus, they are good candidates for transplantation. The one-year survival rate is excellent, and no deaths have occurred beyond that point.

$\alpha$ -1-Antitrypsin deficiency and Wilson's disease are two metabolic diseases that transplantation can cure. The former causes a progressive macronodular cirrhosis and obstructive pulmonary disease; the latter is associated with reduced copper excretion, decreased serum ceruloplasmin, and excessive deposition of copper in the liver and brain. Hereditary tyrosinemia, which causes progressive cirrhosis and increases the risk of hepatocellular cancer, is another indication for operation. Transplantation has also been performed in patients with glycogen storage disease, hemochromatosis, and familial hypercholesterolemia.

**Budd-Chiari syndrome.** Some patients given transplants because of Budd-Chiari syndrome require extensive thrombectomy

FIGURE 4

**SURVIVAL RATES**



One year  
 Five years  
 Key HBsAg = hepatitis B surface antigen

Since 1980, one- and five-year survival rates after transplantation have risen to 71.2% and 62.6%, respectively. Patients with HBsAg-negative cirrhosis, primary biliary cirrhosis, biliary atresia, and inborn errors of metabolism have the best prognosis. Five-year rates for patients with sclerosing cholangitis are not yet available, as the longest-surviving patients received new livers four years ago. There have been no five-year survivors after transplantation for nonfibrolamellar hepatoma.

## CURRENT SURGICAL TECHNIQUE

Operation to remove the liver from a donor is performed through a complete midline incision from the suprasternal notch to the pubis. For the transplant recipient, a bilateral subcostal incision with a superior midline T extension is almost always used. It should not be necessary to enter the chest.

**Standard approach to donor.** The standard technique is first to divide the falciform, left triangular, and gastrohepatic ligaments<sup>5</sup> and then to ligate and divide the branches of the celiac trunk, including the right gastric, gastroduodenal, splenic, and left gastric arteries. The common bile duct is divided and the gallbladder flushed out. The portal vein is skeletonized and the splenic vein cannulated. The supraceliac aorta is encircled for later cross-clamping. Next, the distal aorta is ligated and cannulated. The superior mesenteric artery is ligated and divided, the aorta cross-clamped, and ice-cold Ringer's solution rapidly infused through the splenic (portal) vein and the aorta. Infusion of preservation solution follows.

Once the liver has become very cold, it is removed, along with a large cuff of diaphragm around the suprahepatic vena cava and over the bare area of the liver. The intrahepatic vena cava is divided just above the renal veins. The celiac trunk is removed, with a cuff of aorta. This technique is slightly modified when vascular anomalies are found.<sup>25,26</sup>

**New approach.** Recently, a method that entails virtually no preliminary dissection of the liver has been used.<sup>16,17</sup> The inferior mesenteric vein and distal aorta are ligated and cannulated. The supraceliac aorta is cross-clamped, and the ice-cold infusion through the inferior mesenteric vein and aorta begun. When the liver is thoroughly cooled, working in a bloodless field without risk of inadvertent compromise of blood flow, the surgeon ligates and divides the hilar structures and removes the organ as described above.

In both methods, the final dissection and preparation for anastomosis of the vena cava and the hilar structures is performed on the back table. These methods allow the safe removal of multiple organs (heart or heart-lung, kidney, liver, pancreas) in various combinations, while maintaining excellent function.

**Recipient operation.** Once the abdomen is entered, the structures of the hepatic hilum are skeletonized, and the hepatic artery and common bile duct are ligated and divided. A pump-driven venovenous bypass system without recipient heparinization is used almost routinely in adults and children over 30 pounds.<sup>7</sup> Cannulae for the bypass are placed into the portal, femoral, and axillary veins. With the patient on bypass, the coronary and triangular ligaments are taken down and the vena cava is dissected to complete the hepatectomy.

The venovenous bypass allows the surgeon sufficient time to close the raw surfaces created during the hepatectomy. It also converts a crisis environment during the anhepatic phase of the operation into one that is easily controlled, and it has reduced intraoperative bleeding, postrevascularization pulmonary edema and cardiac standstill, and postoperative renal and gastrointestinal dysfunction.

Vascular cuts are fashioned and the upper and lower caval anastomoses performed. After portal anastomosis, the liver is reperused. The bypass cannulae are removed and hemostasis secured. Revascularization of the liver is completed with the arterial anastomosis. If the recipient hepatic artery is inadequate, an iliac artery graft is interposed between the donor hepatic artery and the infrarenal aorta, through a tunnel created in an avascular plane behind the pancreas and duodenum. Finally, the biliary tract is restored, using either a duct-to-duct repair over a T-tube stent or a choledochojejunostomy to a jejunal Roux-en-Y limb.



of the portal vein and vena cava, and all of them must be maintained on permanent anticoagulation after operation. If anticoagulation is interrupted even briefly, thrombosis, possibly fatal, may recur.

#### A LOOK AT THE FUTURE

Future advances in immunology, organ procurement and preservation, and surgical technique can be expected to lead to additional improvements in survival and quality of life. Progress in organ preservation will make more livers available for transplantation by extending ischemia time and

thus allowing harvesting at greater distances from the transplant center. The recent development of a lactobionate-hydroxyethyl starch-based preservation solution, by Belzer and associates at the University of Wisconsin, has already made it possible to preserve organs for significantly increased lengths of time.<sup>27</sup> In over 100 transplantations of donor livers preserved in this solution, we have found it to be superior to conventional preservation methods.

Although cyclosporine-corticosteroid therapy deserves much of the credit for current high survival rates after transplantation, fur-

ther improvements in immunosuppressive therapy are anticipated; the ultimate goal is donor-specific immunotherapy. The monoclonal antibody OKT3, produced by Ortho Pharmaceuticals as Orthoclone OKT3, has proved highly effective in reversing steroid-resistant rejections, but like other relatively nonspecific immunosuppressives, it is associated with a significant incidence of opportunistic infections.<sup>28</sup> A recent symposium in Gothenburg, Sweden, introduced a new agent known as FK506, which has been tested extensively in animals with promising results.<sup>29</sup> ☐

#### REFERENCES

- Starzl TE, Iwatsuki S, Van Thiel DH, et al: Evolution of liver transplantation. *Hepatology* 1982;2:614-636.
- National Institutes of Health Consensus Development Conference Statement. Liver Transplantation—June 20-23, 1983. *Hepatology* 1984;4:107S-110S.
- Report of the task force on organ transplantation. Organ transplantation issues and recommendations. April 1986. U.S. Department of Health and Human Services. Health Resources and Services. HRP-090676.
- Calne RY, White DJ, Thiru S, et al: Cyclosporin A in patients receiving renal allografts from cadaver donors. *Lancet* 1978;2:1323-1327.
- Busuttill RW, Colonna JO 2d, Hiatt JR, et al: The first 100 liver transplants at UCLA. *Ann Surg* 1987;206:387-402.
- Gordon RD, Iwatsuki S, Esquivel CO, et al: Progress in liver transplantation. *Adv Surg* 1987;21:49-64.
- Shaw BW Jr, Martin DJ, Marquez JM, et al: Venous bypass in clinical liver transplantation. *Ann Surg* 1984;200:524-534.
- Lerut J, Gordon RD, Iwatsuki S, et al: Biliary tract complications in human orthotopic liver transplantation. *Transplantation* 1987;43:47-51.
- Starzl TE, Hakala TR, Shaw BW Jr, et al: A flexible procedure for multiple cadaveric organ procurement. *Surg Gynecol Obstet* 1984;158:223-230.
- Starzl TE, Miller C, Broznick B, et al: An improved technique for multiple organ harvesting. *Surg Gynecol Obstet* 1987;65:343-348.
- Miller C, Mazzaferro V, Makowka L, et al: Rapid flush technique for donor hepatectomy. Safety and efficacy of an improved method of liver recovery for transplantation. *Transplant Proc* 1988; 20 (suppl 1):948-950.
- Fung JJ, Makowka L, Griffin M, et al: Successful sequential liver-kidney transplantation in patients with preformed lymphocytotoxic antibodies. *Clinical Transplantation* 1987;1:187-194.
- Shaw BW Jr, Iwatsuki S, Bron K, et al: Portal vein grafts in hepatic transplantation. *Surg Gynecol Obstet* 1985;161:66-68.
- Starzl TE, Todo S, Gordon RD, et al: Liver transplantation in older patients (letter). *New Engl J Med* 1987;316:484-485.
- Van Thiel DH, Hagler NG, Schade RR, et al: In vivo hepatic volume determination using sonography and computed tomography. Validation and a comparison of the two techniques. *Gastroenterology* 1985;88:1812-1817.
- Iwatsuki S, Starzl TE, Todo S, et al: Experience in 1000 liver transplants under cyclosporine steroid therapy. A survival report. *Transplant Proc* 1988; 20 (suppl 1):498-504.
- James O, Macklon AF, Watson AJ: Primary biliary cirrhosis—a revised clinical spectrum. *Lancet* 1981;1:1278-1281.
- James SP, Hoofnagle JH, Strober W, et al: NIH conference. Primary biliary cirrhosis. A model autoimmune disease (clinical conference). *Ann Intern Med* 1983;99:500-512.
- Bodenheimer HC Jr, Schaffner F, Sternlieb I, et al: A prospective clinical trial of D-penicillamine in the treatment of primary biliary cirrhosis. *Hepatology* 1985;5:1139-1142.
- Dickson ER, Fleming TR, Wiesner RH, et al: Trial of penicillamine in advanced primary biliary cirrhosis. *N Engl J Med* 1985;312:1011-1015.
- Neuberger J, Christensen E, Portmann B, et al: Double blind controlled trial of D-penicillamine in patients with primary biliary cirrhosis. *Gut* 1985;26:114-119.
- Wiesner RH, LaRusso NF: Clinicopathologic features of the syndrome of primary sclerosing cholangitis. *Gastroenterology* 1980; 79:200-206.
- Miller C, Mazzaferro V, Makowka L, et al: Orthotopic liver transplantation for massive hepatic lymphangiomatosis. *Surgery* 1988; 103:490-495.
- Iwatsuki S, Gordon RD, Shaw BW Jr, et al: Role of liver transplantation in cancer therapy. *Ann Surg* 1985;202:401-407.
- Shaw BW Jr, Iwatsuki S, Starzl TE: Alternative methods of arterialization of the hepatic graft. *Surg Gynecol Obstet* 1984;159:490-493.
- Gordon RD, Shaw BW Jr, Iwatsuki S, et al: A simplified technique for revascularization of homografts of the liver with a variant transplantation of a hepatic artery from the superior mesenteric artery. *Surg Gynecol Obstet* 1985;160:474-476.
- Jamieson NV, Sundberg R, Liddell S, et al: Successful 24-30-hour preservation of the canine liver. A preliminary report. *Transplant Proc* 1988; 20 (suppl 1):945-947.
- Fung JJ, Demetris AJ, Porter KA, et al: Use of OKT3 with cyclosporin and steroids for reversal of acute kidney and liver allograft rejection. *Nephron* 1987;1(suppl):19-33.
- Starzl TE, Makowka L, Todo S, eds: Symposium: FK506—a potential breakthrough in immunosuppression. *Transplant Proc* 1987;19(suppl 6):3-104.