


676 

Chapter 6

Surgery for Metabolic Liver Disease

THOMAS E. STARZL

There is no aspect of intermediary metabolism in which the liver is not involved. Consequently, it is not surprising that inborn errors of metabolism can be influenced by operations on the liver. This chapter will describe how the course of liver-based inborn errors of metabolism can be changed by two kinds of hepatic operations, portacaval shunt and liver transplantation.

Portal Diversion

Mechanism of Effects

Venous blood from the splanchnic viscera has liver-supporting qualities not found to the same degree in other kinds of arterial or venous blood (1-6). The main splanchnic venous "hepatotrophic" factors are almost certainly endogenous hormones of which the single most important is insulin. Deprivation of the liver of the so-called "hepatotrophic effects" of portal blood has been noted under several experimental conditions (including portacaval shunt) to cause hepatocyte atrophy, deglycogenation, and fatty infiltration. With electron microscopic studies, relatively specific findings have been disruption and reduction of the rough endoplasmic reticulum (RER) and diminution of its lining polyribosomes (1,3-7). Since RER is the "factory" of the cell, a consequent reduction in many biosynthetic processes would be expected. Numerous studies have verified this hypothesis.

For example, the effect of portal diversion on hepatic lipid metabolism has been unusually well studied. Reductions of more than 80% in hepatic cholesterol and/or triglyceride or lipoprotein synthesis have been demonstrated in rats, dogs, swine, and baboons (1,3). Reductions in hepatic lipid synthesis also have been documented in

patients treated by us with portacaval shunt for familial hypercholesterolemia (FH) (8-10), and it has been shown that total body cholesterol is greatly reduced (10). Thus, lipid homeostasis is altered to an extraordinary degree by portacaval shunt, with the reduction in hepatic lipid synthesis being the greatest change.

Bile acid synthesis also is greatly reduced by portacaval shunt (1,8,10). Another synthetic pathway that has been well studied after portal diversion is the hepatic urea (Krebs-Henseleit) cycle, which has been shown by Reichle et al. to be depressed by Eck's fistula in rats (11) and dogs (12). They also demonstrated a reduction in several of the enzymes involved in this metabolic pathway.

Many studies during the 1970s and mid-1980s, summarized elsewhere (1), have shown that portacaval shunt lowers the activity of the hepatic microsomal mixed-function enzyme system. Aside from illustrating the principle of a wide-ranging decline in hepatic metabolic functions after portacaval shunt, these observations are of potential specific importance because the microsomal mixed-function enzyme system, for which multiple cytochrome P450 and P448 species serve as terminal oxidases, metabolizes a variety of drugs and foreign chemicals, as well as endogenous compounds such as steroids and fatty acids. The depression of this broad-ranging enzyme system would relate to many of the metabolic effects of portal diversion.

Clinical Applications of Portal Diversion

Portacaval shunt has been used to palliate hepatic-based inborn errors of carbohydrate, lipid, and protein metabolism. Although these were great advances at the time, such surgical therapy has

Table 6.1. Patients with GSD Treated by Portal Diversion^a

Patient No.	Age (yr)	GSD Type	Date of Operation	Preoperative Symptoms			Survival After Shunt
				Hypoglycemia	Acidosis	Growth Retardation	
1	8	III	October 15, 1963	Yes	Yes	Yes	Alive 22½ years
2	7	I	June 26, 1968	Yes	Yes	Yes	Died 2 days
3	7	I	May 2, 1972	Yes	Yes	Yes	Alive 14 years
4	11	I	May 17, 1972	Yes	Yes	Yes	Died 4¾ years
5	10	VI	August 2, 1972	—	—	Yes	Alive 13½ years
6	5	III	November 7, 1972	Yes	Yes	Yes	Alive 13½ years
7	3	III	November 8, 1972	Yes	Yes	Yes	Alive 13½ years
8	8	I	August 13, 1973	Yes	Yes	Yes	Alive 12¾ years
9	12	I	December 14, 1973	Yes	Yes	Yes	Alive 12½ years
10	1	I	October 2, 1976	Yes	Yes	Yes	Alive 9½ years

^a Patients 1 and 2 had portacaval transposition; all others had portacaval shunt.

^b Overnight feeding via nasogastric tube starting 2½–4 years after portacaval shunt.

^c Underwent orthotopic liver transplantation February 12, 1982, and is alive 4 years later (see text).

been rendered obsolete by the even more effective procedure of liver transplantation. Nevertheless, the information obtained has been important in understanding hepatic physiology in humans, and will be briefly described here.

GLYCOGEN STORAGE DISEASE

Portal diversion was first performed for glycogen storage disease more than 20 years ago (13) with a rationale that is naive in retrospect. It was hoped that by short-circuiting splanchnic venous blood around the liver, glucose would be made more readily available to peripheral tissues with relief of the hypoglycemia caused by glycogen storage disease (GSD), and that the liver would be coincidentally deglycogenated. The animal experiments cited in Mechanism of Effects, above, suggest that the consequences of portacaval shunt are far more subtle and wide-ranging than this simple view.

That first patient had type III GSD. She is still alive more than 20 years after portacaval transposition. The bypassed portal venous blood was replaced with blood returning from the inferior vena cava, an operation which was first described in animals by Child et al. (14). The transposition was used in order to avoid the potential hazards of Eck's fistula. It was appreciated then, and amply confirmed since (1,7), that most animals, including subhuman primates, develop wasting and encephalopathy after portal diversion, but it was not appreciated that humans would be an exception to this generalization.

Two more portacaval transpositions were per-

formed, one by Riddell et al. (15). In Riddell's patient, the cavoportal anastomosis clotted (16). The other attempt cost the life of our second patient; the liver was unable to transmit the re-routed vena caval flow, causing hepatic swelling and uncontrollable acidosis (17).

Subsequently, the simpler procedure of portacaval shunt has been used (16). To our knowledge, end-to-side portacaval shunt was used in all later patients. By the spring of 1973 (16), our own series of patients had reached seven, and six more had been formally reported in the literature from other centers. Subsequently, our patients increased in number to 10. Type I disease (glucose-6-phosphatase deficiency) was the indication for treatment in six patients, type III disease (amylo-1, 6-glucosidase deficiency) in three, and type 6 disease (phosphorylase deficiency) in one (Table 6.1).

Metabolic Effects

Most of the children who had pre-existing hypoglycemia did not obtain relief from this problem after portal diversion, or the relief was not complete. Thus, night feedings usually had to be continued. Studies of plasma insulin and glucagon in several of these patients showed marked elevations of the insulin response to a glucose meal, and smaller increases in the glucagon curve. However, the glucose tolerance curves were very little different before and after operation (1).

Liver glycogen concentrations in all those patients who were later biopsied were not changed. In spite of this, in several of our patients and in those reported by others, the liver underwent an

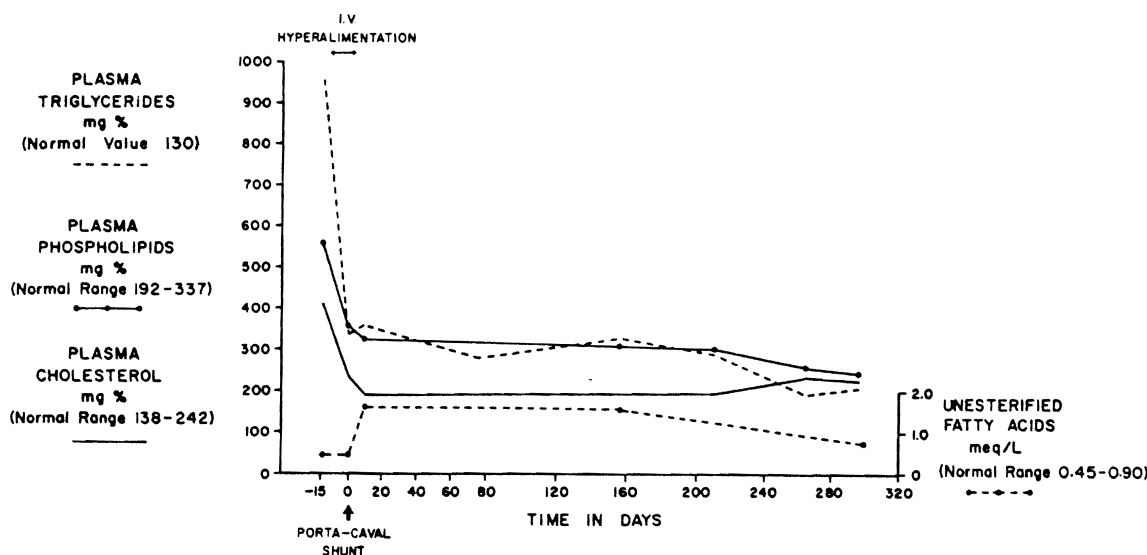


Figure 6.1. Effect of parenteral hyperalimentation and end-to-side portacaval shunt on the plasma lipids of a patient whose diagnosis was type I glycogen storage disease. Note the rapid and relatively complete reversal of all abnormalities. (Reproduced by permission from Starzl TE, Putnam CW, Porter Ka, et al. Portal diversion for the treatment of glycogen storage disease in humans. *Ann Surg* 1973; 178:525-539.)

obvious reduction in size as measured with liver scan planimetry. Even if obvious shrinkage did not occur, postoperative biopsies always showed a diminution in individual hepatocyte size similar to that produced in animals by portacaval shunt (16).

In contrast to the incomplete relief of hypoglycemia, there was profound and permanent relief of all components of the hyperlipidemia that is a characteristic of type I disease (Fig. 6.1). Correction of other metabolic defects was observed, including abnormal bleeding, uric acid elevation, and abnormal calcium metabolism (16). These observations have been confirmed by others (18-20).

Growth

All 10 of our patients had growth retardation before portacaval shunt. Increases in height, which in most cases had virtually ceased, occurred postoperatively at rates in the first year of approximately 0.5 centimeters per month. Quantitative measures of growth were obtained with radiographic techniques (16). An example of the results is shown in Figure 6.2. Comparison of the wrist and hands in this 7-year-old stunted child before and 11½ months after operation showed the phenomenal effects of bone-age doubling. In addition to the size change, mineralization occurred, as did the appearance of new wrist bones. Circulating

somatotrophin in these patients was normal. The growth spurts may have been at least partially attributable to the increased insulin distribution to the periphery mentioned earlier, since insulin has been recognized to be a major growth hormone, comparable in potency to somatotrophin. The simpler possibility that better nutrition was responsible must also be considered.

Encephalopathy and Other Risks

One patient exhibited hepatic encephalopathy 8 years after end-to-side portacaval shunt for type I glycogen storage disease, and also developed multiple filling defects in her enlarged liver. The diseased liver was replaced at transplantation. The metabolic abnormalities of type I GSD that had not been normalized by the portacaval shunt were completely relieved (21).

One other child developed a blood ammonia concentration of 85 micrograms per 100 milliliters (normal less than 60 $\mu\text{g}/100\text{ ml}$ for that laboratory), but there were no symptoms of encephalopathy. This patient died almost 5 years after portacaval shunt during an attempt at transcaval radiographic visualization of the portacaval anastomosis. Except for the slightly elevated blood ammonia concentration, her standard liver functions were normal. At autopsy, the liver had macroadenomatosis, very

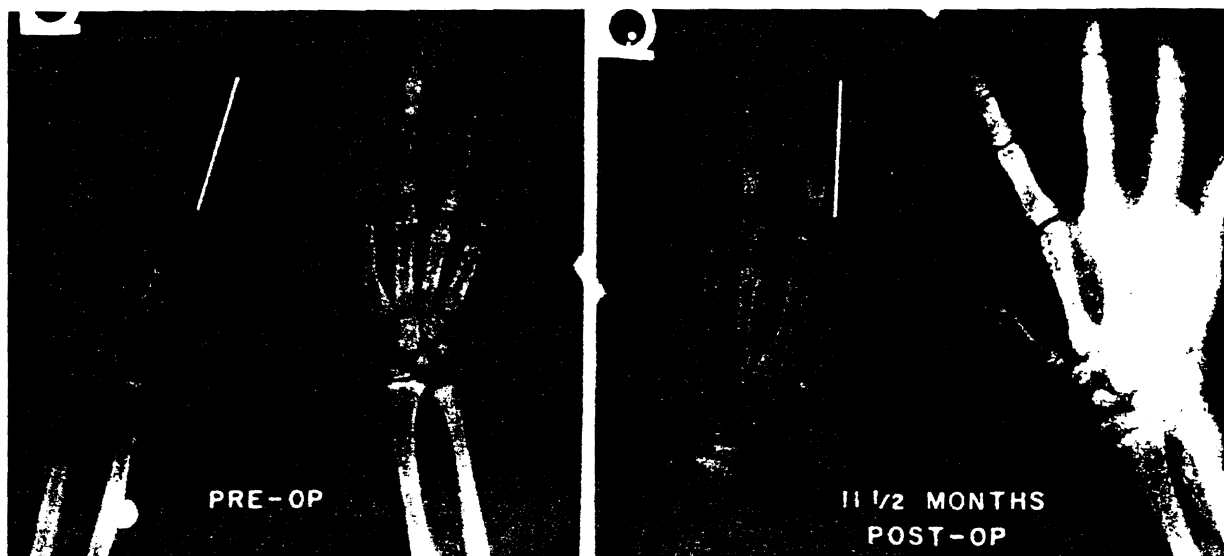


Figure 6.2. The dramatic wrist and hand bone growth and mineralization in a patient with type I GSD during the first 11½ postoperative months. The bracket on the left index finger is 5 cm in length. (Reproduced by permission from Starzl TE, Putnam CW, Porter KA, et al. Portal diversion for the treatment of glycogen storage disease in humans. *Am Surg* 1973; 178:525-539.)

similar to that in the child who underwent transplantation. An autopsy finding that had not been suspected in life was advanced right ventricular hypertrophy and dilatation. The smaller pulmonary arteries and arterioles had medial muscle hypertrophy, medial and intimal fibrosis, scattered fibrinoid necrosis, and numerous plexiform lesions. Such cardiopulmonary complications have been documented in other patients with type I GSD and other liver diseases (22).

The macroadenomatosis seen in both of the foregoing patients is common in patients with type I GSD, and was reported in seven of eight non-shunted patients aged 3 to 28 years (23).

Present Status of Portal Diversion

Portacaval shunt in the treatment of GSD has been supplanted by the continuous night feeding schedule advocated by Greene et al. (24) and Crigler and Folkman (25). Failures of this more conservative approach should be considered for liver transplantation (see Liver Transplantation, Mechanism of Effect, below).

FAMILIAL HYPERCHOLESTEROLEMIA

In March 1973, a 12-year-old girl with homozygous FH was treated with an end-to-side portacaval

shunt; her serum cholesterol concentration fell markedly (26) (Fig. 6.3). By March 1982, we had treated 12 patients with FH in this way (27), eight children and four adults.

In patients with this disease, there is an absence or deficiency of cell membrane lipoprotein receptors (28,29) and thus, a switch-off mechanism to control lipid (especially cholesterol) synthesis is not present. All but two patients were homozygous for the FH abnormality as judged by measure of low-density lipoprotein (LDL) receptors on cultured fibroblasts obtained from all patients (28,29). The other two patients had heterozygous disease.

Effect on Serum Lipids

Total serum cholesterol concentrations fell significantly in every patient after portacaval shunt (27). The total cholesterol declines ranged from 20% to 55.4% (average 33.8%) and were maintained throughout the period of study. With the fall in cholesterol concentration, tendinocutaneous xanthomas regressed or disappeared in every patient (Fig. 6.4). An anticholesterolemia response after portal diversion has been confirmed by numerous other authors [summarized in Starzl et al. (27)], at the time tendinocutaneous xanthomas have regressed. Hoeg et al. (30) have reported a postoperative increase in hepatic lipoprotein receptors in

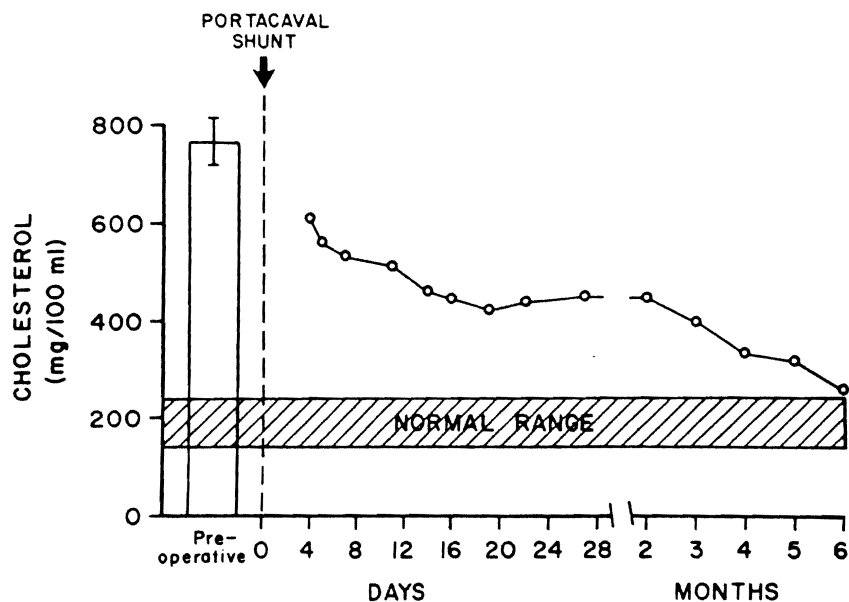


Figure 6.3. Serum cholesterol concentration after portacaval shunt in a patient of our FH series. (Reproduced by permission from Starzl TE, Chase HP, Putnam CW, Porter KA. Portacaval shunt in hyperlipoproteinemia. *Lancet* 1973; 2:940-944.)

one of our patients. Although an increase of receptors could have contributed to an antilipidemic effect of portal diversion, the principal effect probably was caused by reduced cholesterol and lipoprotein synthesis (1,3,8,10-12).

Morbidity

The invariable and long-lasting lipid lowering in our 12 patients was achieved without surgical morbidity. The physical development of those children who were normal before operation has pro-

ceeded, and the growth of those who were stunted before has moved toward normal. Emotional or intellectual deterioration secondary to the portal diversion has not occurred, although one child had an acute episode of encephalopathy, which was managed with diet (27).

Effect on Cardiovascular Disease

Reversal of aortic stenosis was seen in two of our patients, but regression of atheromas in the coronary arteries and aorta was not regularly accom-

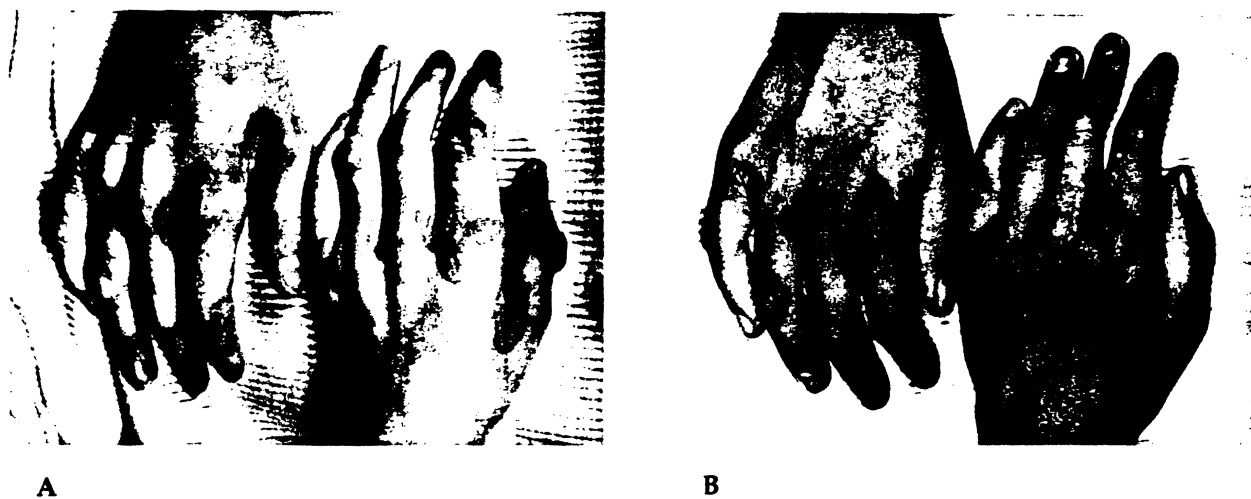


Figure 6.4. The hands of patient 1 of the hyperlipidemia series (A) 2 weeks before and (B) 16 months after portacaval shunt.

plished (27). Small and Shipley (31) have examined the factors that could preclude the reversal of atherosclerosis; some of these, including secondary fibrosis, would not be corrected completely by the resorption of intravascular xanthomas.

Present Status of Portal Diversion

The palliation is incomplete, since restoration of normal serum cholesterol values has not been achieved in any patient with homozygous disease. In contrast, the metabolic abnormalities of FH can be completely corrected by the ultimate step of liver transplantation, which will become the preferred method of treatment in the near future (see Clinical Applications of Liver Transplantation, below) in medically refractory cases.

ALPHA₁-ANTITRYPSIN DEFICIENCY

Patients with this disorder have a low level plasma alpha₁-antitrypsin (an alpha-globulin), a high incidence of pulmonary complications, and an increased incidence of liver disease. The basis for the liver injury may be the hepatic production of an abnormal alpha₁-antitrypsin, which cannot be effectively transported out of the liver cells and which consequently becomes sequestered within the hepatocytes near the RER (32). Irritation by the entrapped glycoprotein has been the postulated cause of the hepatic cirrhosis, portal hypertension, and hepatic failure that follow.

We have performed end-to-side portacaval shunt in three children with the cirrhotic liver disease of alpha₁-antitrypsin deficiency (33). Follow-up reports are available at 6½, 8, and nearly 10 years. Standard liver function tests have not changed greatly since the portacaval shunt, although the plasma ammonia levels have been elevated in all three patients. Patient 2 has had mental slowness, which may be a symptom of encephalopathy.

The most objective evidence that the natural history of the disease was favorably altered came from the histopathologic studies of operative and postoperative biopsies in patients 2 and 3 (33). In patient 2, a biopsy 9 months after the portal diversion showed that the number of hepatocytes that contained alpha₁-antitrypsin globules was diminished to 28.5%, compared with 38.2% at the time of the original operation. The hepatocytes were 22% smaller and the amount of RER in their cytoplasm was greatly reduced.

In patient 3, the percentage of hepatocytes containing alpha₁-antitrypsin globules was 44.5% at the time of operation, and 48.2 and 38.7% at 7 and 13 months, respectively, after portacaval shunt. The hepatocytes were 15% and 20% smaller at these postoperative periods. The percentage of hepatocytes containing alpha₁-antitrypsin globules was reduced to 20.4% in the biopsy taken at 2 years, 11 months. The hepatocytes remained 20% smaller than in the preoperative biopsy, and the amount of both RER and smooth endoplasmic reticulum in their cytoplasm was reduced. The severity of the macronodular cirrhosis was unaltered.

We believe that the portacaval shunt diminished the synthesis of the abnormal alpha₁-antitrypsin, presumably by altering the function of the RER and its ribosomes (see Portal Diversion, Mechanism of Effects, above) without commensurately reducing the transport of this glycoprotein. With a better equilibrium between the production and transport of the alpha₁-globulin, it is possible that its intracellular accumulation has been slowed or probably even reversed (33).

No further portacaval shunts have been carried out in patients with alpha₁-antitrypsin deficiency for more than 6 years. It has been established that liver transplantation provides a metabolic "cure" and that the protein phenotype of the recipient becomes that of the donor for the lifetime of the graft (see Liver Transplantation, Mechanism of Effect, below).

Liver Transplantation

Mechanism of Effect

The use of portal diversion to treat liver-based inborn errors of metabolism requires the creation of an abnormal physiologic state for the liver in order to achieve countervailing metabolic objectives. A more direct and satisfactory approach is to provide a phenotypically normal liver. Studies of haptoglobin (34-36), group-specific component (36,37), and numerous other products of hepatic synthesis (21,32,38-40) have shown that liver homografts permanently retain their original metabolic specificity after transplantation. Consequently, liver transplantation has been recognized for a number of years (37,41) as a potentially decisive way to treat those inborn errors of metab-

Table 6.2. Inborn Errors of Metabolism Corrected by Liver Transplantation—Cases from Personal Series

Disease	Cases	Enzyme Defect	Metabolic Cure	Longest Survival (yr)
Alpha ₁ -antitrypsin deficiency	38	Unknown	Yes	10
Wilson's disease	14	Unknown	Yes	15½
Tyrosinemia	6	Fumarylacetoacetate hydrolase	Yes	4½
Type IV GSD	4	Amylo-1,4 transglucosidase (branching enzyme)	Yes	1½
Hemophilia-A	3	Unknown	Yes	1
Crigler-Najjar syndrome	2	Glucuronyl-transferase	Yes	4 ^a
Familial hypercholesterolemia	2	None: deficient lipoprotein receptors	Yes	2
Type I GSD	1	Glucose-6-phosphatase	Yes	4
Niemann-Pick disease	1	Sphingomyelinase	Possibly	1½ ^b
Sea-blue histiocyte syndrome	1	Unknown	No	4
Cystic fibrosis	1	Unknown	Not studied	1½
Hemochromatosis	1	Unknown	Yes	2
Type I oxalosis	1	Thiamin-pyrophosphate-dependent carbolygase	Probably	Unknown ^c

^a Longest survivor reported by Professor H. Wolff, Berlin, East Germany.

^b Patient treated by Dr. Pierre Daloze, Notre Dame Hospital, Montreal; died of neurologic complications.

^c Patient of Professor Roy Calne, Cambridge, England.

olism that result partly or completely from defects in hepatic function.

In many of the diseases for which liver transplantation has been carried out, a specific enzyme is missing as exemplified by the GSDs. With other disorders (e.g., Wilson's disease), the pathogenesis is not well understood even today (Table 6.2). In some of these conditions, the exact role of liver was not known until a study of patients after transplantation proved that the defect was hepatic. In two of these diseases, familial hypercholesterolemia and hemophilia, the transplantation itself became the most powerful of research tools while at the same time benefiting the patient.

Clinical Applications of Liver Transplantation

The inborn errors of metabolism for which liver transplantation has been carried out are shown in Table 6.2. In the majority of such patients, the inborn error has itself been responsible for damage to the liver, in which case the conventional indication of liver failure prompted the liver replacement. However, a small but particularly interesting minority of transplantations have been carried out solely for the purpose of correcting the inborn error itself, and in these cases, a morphologically normal liver has been removed and replaced with a homograft. Examples include familial hypercholesterolemia, congenital oxalosis, and Crigler-Najjar syndrome. In the following descriptions,

emphasis is on those inborn errors that were once treated with portal diversion, but for which the most desirable treatment today probably is liver replacement.

GLYCOGEN STORAGE DISEASE

An 8-year-old girl with type I GSD underwent an end-to-side portacaval shunt in 1973. Although she had reasonable palliation from her multiple symptoms, she eventually developed hepatic encephalopathy, and in addition, her liver developed masses that were suspected of being hepatomas. In January 1982, her diseased liver was removed, the portacaval shunt was taken down, and a phenotypically normal liver was implanted. Her recovery was relatively uncomplicated, and all of the metabolic stigmata of type I GSD (mentioned in Glycogen Storage Disease, Metabolic Effects, above) were corrected (21). Prior to operation, she required frequent night feedings, and if she fasted for more than a few hours, her blood sugars dropped to below 10 mg%. Afterward, she could fast indefinitely. Some months postoperatively, her portal vein thrombosed, but she developed extensive collaterals to the hepatic graft and she has had no evidence of encephalopathy or liver failure during her 4 postoperative years.

Four patients with type IV GSD (see Table 6.2) have had their cirrhotic livers removed and replaced. Two of these children died perioperatively.

The other two have normal function 3 and 18 months postoperatively. A 1-year biopsy of the child with the longest survival has shown no evidence of recurrent disease.

FAMILIAL HYPERCHOLESTEROLEMIA

A 6-year-old girl with severe hypercholesterolemia and atherosclerosis had two defective genes at the LDL receptor locus, as determined by biochemical studies of cultured fibroblasts. One gene, inherited from the mother, produced no LDL receptors; the other gene, inherited from the father, produced a receptor precursor that was not transported to the cell surface and was unable to bind LDL. The patient degraded intravenously administered ^{125}I -LDL at an extremely low rate, indicating that her high plasma LDL-cholesterol level was caused by defective receptor-mediated removal of LDL from plasma. After transplantation of a liver and a heart from a normal donor, the patient's plasma LDL-cholesterol level declined by 81%, from 988 to 184 mg%. The fractional catabolic rate for intravenously administered ^{125}I -LDL, a measure of functional LDL receptors in vivo, increased by 2.5-fold. Thus, the transplanted liver, with its normal complement of LDL receptors, was able to remove LDL cholesterol from plasma at a nearly normal rate. We concluded from these observations that a genetically determined deficiency of LDL receptors could be largely reversed by liver transplantation. These data have underscored the importance of hepatic LDL receptors in controlling the plasma level of LDL cholesterol in human beings (42).

The foregoing hypothesis that the disease was caused by deficient LDL receptors has not excluded the further possibility that the hepatocytes of the metabolically abnormal liver overproduce cholesterol. A second patient, an 11-year-old boy, underwent liver transplantation on December 6, 1985. His serum cholesterol also fell to essentially normal levels. Presently, he is on a medical ward at the National Institutes of Health undergoing extensive postoperative metabolic studies. Although his heart had been gravely damaged by the high cholesterol of his disease, heart transplantation was not required. A residual high-grade stenosis of one of the coronary arteries has been treated by an internal mammary artery-coronary artery bypass.

It has become clear that liver transplantation

"cures" familial hypercholesterolemia. Furthermore, the performance of the liver replacement has permitted the most decisive studies on the pathogenesis of the disease that have ever been possible.

ALPHA₁-ANTITRYPSIN DEFICIENCY

Serum alpha₁-antitrypsin levels, which normally are 200 to 300 mg%, usually are about one-tenth of this value in patients who develop alpha₁-antitrypsin-associated liver disease. Patients at risk can be identified by Pi (protease inhibitor) phenotypes, the ZZ marker usually being associated with the liver disease. More than a decade ago, it was demonstrated that the serum alpha₁-antitrypsin levels were brought to normal, and that the new Pi type of liver recipient permanently became that of the donor (32,41). Alpha₁-antitrypsin deficiency has been the inborn error of metabolism most commonly treated by liver transplantation (see Table 6.2). Realization of the effectiveness of liver replacement has prompted us to discontinue efforts at portal diversion, particularly since portacaval shunts can jeopardize candidacy for the definitive procedure of transplantation.

OTHER INBORN ERRORS

Among the first 500 liver transplantations carried out by us under cyclosporine-steroid therapy, there were almost a dozen inborn errors (see Table 6.2). One of the most significant observations (in 1985) has been that classical hemophilia is completely corrected by liver replacement (43). The explanation of hemophilia has been unknown, but the predominance of opinion has been that the liver was not central to the pathogenesis. With the simple expedient of liver transplantation, this doctrine was overthrown, and subsequent gene probe studies have verified the hepatocyte as the location of factor VIII production.

Summary

Complete portal diversion can palliate at least three inborn errors of metabolism, GSD, FH, and alpha₁-antitrypsin deficiency. However, these three liver-based inborn errors of metabolism, as well as numerous other inborn errors, can be metabolically cured by the transplantation of phenotypically normal livers.

References

- Starzl TE, Porter KA, Francavilla A. The Eck fistula in animals and humans. *Curr Probl Surg* 1983; 20(11):688-752.
- Starzl TE, Francavilla A, Halgrimson CG, Francavilla FR, et al. The origin, hormonal nature, and action of hepatotrophic substances in portal venous blood. *Surg Gynecol Obstet* 1973; 137:179-199.
- Starzl TE, Lee I-Y, Porter KA, Putnam CW. The influence of portal blood upon lipid metabolism in normal and diabetic dogs and baboons. *Surg Gynecol Obstet* 1975; 140:381-396.
- Starzl TE, Porter KA, Kashiwagi N, Lee IY, et al. The effect of diabetes mellitus on portal blood hepatotrophic factors in dogs. *Surg Gynecol Obstet* 1975; 140:549-562.
- Starzl TE, Porter KA, Kashiwagi N, Putnam CW. Portal hepatotrophic factors, diabetes mellitus and acute liver atrophy, hypertrophy and regeneration. *Surg Gynecol Obstet* 1975; 141:843-858.
- Starzl TE, Porter KA, Watanabe K, Putnam CW. The effects of insulin, glucagon and insulin/glucagon infusions upon liver morphology and cell division after complete portacaval shunt in dogs. *Lancet* 1976; 1:821-825.
- Putnam CW, Porter KA, Starzl TE. Hepatic encephalopathy and light and electron micrographic changes of the baboon liver after portal diversion. *Ann Surg* 1976; 184:155-161.
- Bilheimer DW, Goldstein JL, Grundy SM, Brown MS. Reduction in cholesterol and low density lipoprotein synthesis after portacaval shunt surgery in a patient with homozygous familial hypercholesterolemia. *J Clin Invest* 1975; 56:1420-1430.
- Ginsberg H, Davidson N, Le N-A, Gibson J, et al. Marked overproduction of low density lipoprotein apoprotein-B in a subject with heterozygous familial hypercholesterolemia: Effect of portacaval shunting. *Biochim Biophys Acta* 1983; 712:250-259.
- McNamara DJ, Ahrens EH Jr, Kolb R, Parker TS, et al. Cholesterol homeostasis in two familial hypercholesterolemic patients with a portacaval anastomosis. *Circulation* 1982; 66(Suppl 11):159.
- Reichle FA, Bernstein MR, Hower RD, et al. Urea cycle enzyme activity in human hepatic cirrhosis and after experimental portacaval shunt. *Surg Forum* 1973; 24:246-248.
- Reichle FA, Rao NS, Reichle RM, Chang KHY. The mechanism of postshunt liver failure. *Surgery* 1977; 82:738-749.
- Starzl TE, Marchioro TL, Sexton AW, Illingworth B, et al. The effect of portacaval transposition upon carbohydrate metabolism: Experimental and clinical observations. *Surgery* 1965; 57:687-697.
- Child CG, Barr D, Holswade GR, Harrison CS. Liver regeneration following portacaval transposition in dogs. *Ann Surg* 1953; 138:600-608.
- Riddell AG, Davies RP, Clark AD. Portacaval transposition in the treatment of glycogen storage disease. *Lancet* 1966; 2:1146-1148.
- Starzl TE, Putnam CW, Porter KA, Halgrimson CG, et al. Portal diversion for the treatment of glycogen storage disease in humans. *Ann Surg* 1973; 178:525-539.
- Starzl TE, Brown BI, Blanchard H, Brettschneider L. Portal diversion in glycogen storage disease. *Surgery* 1969; 65:504-506.
- Corbeel L, Hue L, Lederer B, DeBarys T, et al. Clinical and biochemical findings before and after portacaval shunt in a girl with type Ib glycogen storage disease. *Pediatr Res* 1981; 15:58-61.
- Folkman J, Philippart A, Tze W-J, Crigler J Jr. Portacaval shunt for glycogen storage disease: Value of prolonged intravenous hyperalimentation before surgery. *Surgery* 1972; 72:306-314.
- Liebschutz D, Soper RT. Portacaval shunt in siblings for type I glycogenosis. *J Pediatr Surg* 1976; 11:557-561.
- Malatack JJ, Finegold DN, Iwatsuki S, Shaw BW, et al. Liver transplantation for Type I glycogen storage disease. *Lancet* 1983; 1:1073-1076.
- Levine OR, Harris RC, Blanc WA, Wellins RB. Progressive pulmonary hypertension in children with portal hypertension. *J Pediatr* 1973; 83:964-972.
- Howell RR, Stevenson RE, Ben-Menachem Y, Phyliky RL, et al. Hepatic adenomata with type I glycogen storage disease. *JAMA* 1976; 236:1481-1484.
- Greene HL, Slonim AE, O'Neill JA, Burr IM. Continuous nocturnal intragastric feedings for management of type I glycogen storage disease. *N Engl J Med* 1976; 294:1125-1129.
- Crigler JF Jr, Folkman J. Glycogen storage disease. New approaches to therapy. In: Porter R, Whelen J, eds. *Hepatotrophic Factors*. Ciba Foundation Symposium No. 55. Amsterdam: Elsevier/Excerpta Medica, 1978, pp. 331-356.
- Starzl TE, Chase HP, Putnam CW, Porter KA. Portacaval shunt in hyperlipoproteinemia. *Lancet* 1973; 2:940-944.
- Starzl TE, Chase HP, Ahrens EH Jr, McNamara DJ, et al. Portacaval shunt in patients with familial hypercholesterolemia. *Ann Surg* 1983; 198:273-283.
- Goldstein J, Brown MS. Binding and degradation of low density lipoproteins in cultured human fibroblasts: Comparison of cells from a normal subject and from a patient with homozygous familial hypercholesterolemia. *J Biol Chem* 1974; 249:5153-5162.
- Goldstein JL, Dana SE, Brunschede GY, Brown MS. Genetic heterogeneity in familial hypercholesterolemia: Evidence for two different mutations affecting functions of low density lipoprotein receptor. *Proc Natl Acad Sci USA* 1975; 72:1092-1096.
- Hoeg JM, Demosky SJ Jr, Schaefer EJ, Starzl TE, Brewer HB Jr. Characterization of hepatic low density lipoprotein binding and cholesterol metabolism in normal and homozygous familial hypercholesterolemic subjects. *J Clin Invest* 1984; 73:429-436.
- Small DM, Shipley GG. Physical chemical basis of lipid deposition in atherosclerosis: The physical state of the lipids helps to explain lipid deposition and lesion reversal in atherosclerosis. *Science* 1974; 185:222-229.
- Hood JM, Koep LJ, Peters RL, Schroter GPJ, et al. Liver transplantation for advanced liver disease with alpha₁-antitrypsin deficiency. *N Engl J Med* 1980; 302:272-275.
- Starzl TE, Porter KA, Francavilla A, Iwatsuki S. Reversal of hepatic alpha₁-antitrypsin deposition after portacaval shunt. *Lancet* 1983; 2:724-726.
- Starzl TE, Marchioro TL, Rowlands DT Jr, Kirkpatrick CH, et al. Immunosuppression after experimental and clinical homotransplantation of the liver. *Ann Surg* 1964; 160:411-439.
- Merrill DA, Kirkpatrick CH, Wilson WEC, Riley CM. Change in serum haptoglobin type following human liver transplantation. *Proc Soc Exp Biol Med* 1964; 116:748-751.
- Kashiwagi N, Groth CG, Starzl TE. Changes in serum haptoglobin and group specific component after orthotopic liver homotransplantation in humans. *Proc Soc Exp Biol Med* 1968; 128:247-250.
- Kashiwagi N. Special immunochemical studies. In: Starzl TE, ed. *Experience in Hepatic Transplantation*. Philadelphia: WB Saunders, 1969, pp. 394-407.

38. Alper CA, Johnson AM, Birtch AG, Moore FD. Human C³: Evidence for the liver as the primary site of synthesis. *Science* 1969; 163:286-288.
39. Alper CA, Raum D, Awdeh Z, Petersen BH, Taylor PD, Starzl TE. Studies of hepatic synthesis *in vivo* of plasma proteins, including orosomucoid, transferrin, alpha₁-antitrypsin, C8, and Factor B. *Clin Immunol Immunopathol* 1980; 16:84-89.
40. Raum D, Marcus D, Alper CA, Levey R, Taylor PD, Starzl TE. Synthesis of human plasminogen by the liver. *Science* 1980; 208:1036-1037.
41. Starzl TE, Iwatsuki S, Van Thiel DH, Gartner JL, et al. Evolution of liver transplantation. *Hepatology* 1982; 2:614-636.
42. Bilheimer DW, Goldstein JL, Grundy SC, Starzl TE, Brown MS. Liver transplantation provides low density lipoprotein receptors and lowers plasma cholesterol in a child with homozygous familial hypercholesterolemia. *N Engl J Med* 1984; 311:1658-1664.
43. Lewis JH, Bontempo FA, Spero JA, Ragni WV, Starzl TE. Liver transplantation in a hemophiliac. (Letter to the Editor) *N Engl J Med* 1985; 312:1189.

Editorial Comment

The chapters that are concerned with inborn errors of metabolism relating directly or indirectly to the liver, are a well-orchestrated combined effort of two leaders in that field, Marshall Kaplan in medicine and Thomas Starzl in surgery.

Dr. Kaplan has presented a wide-ranging dissertation on a number of different familial disorders, and has then deferred in terms of surgical treatment to the section specifically related to this therapeutic approach.

Dr. Starzl has covered the main inborn errors of metabolism (specifically relating to surgical procedures). These include glycogen storage disease, familial hypercholesterolemia, alpha₁-antitrypsin

deficiency, isolated examples of rare entities such as congenital oxalosis, and the Crigler-Najjar syndrome. The earlier imaginative approaches to some of these metabolic defects by portal diversion have contributed over the years, not only to a therapeutic program for these children, but also toward a better understanding of the abnormal metabolic defects.

Starzl's pioneer work in liver transplantation has made this somewhat formidable procedure a more acceptable and effective type of therapy. Orthotopic liver transplantation carried out for a number of inborn errors in metabolism, as Dr. Starzl points out, has replaced portal diversion as the surgical therapy in this area. In many of these instances, the metabolic defect results in the liver damage, which, in turn, proved to be the surgical indication for transplantation, but in a number of other instances the defect itself was the rationale for treatment by liver replacement. It is in this group in particular that liver transplantation has not only proved to be therapeutically effective, but also has contributed enormously to an increasing understanding of some of the puzzling enzymatic and other defects that are reflected in these inborn errors of metabolism. Observations are still emerging and may have widespread applications, for example, the suggested evidence that the hepatocyte is the site of the defect that results in classical hemophilia.

This review provides a succinct but hardly cursory review of a fascinating segment of human disease.