

## Resolution of the Clinical Features of Tyrosinemia Following Orthotopic Liver Transplantation for Hepatoma

David H. Van Thiel<sup>1</sup>, Lawrence M. Gartner<sup>2</sup>, Frank K. Thorp<sup>2</sup>, Stephen L. Newman<sup>3</sup>, Julie A. Lindahl<sup>3</sup>, Elizabeth Stoner<sup>4</sup>, Maria I. New<sup>4</sup> and Thomas E. Starzl<sup>1</sup>

<sup>1</sup>University of Pittsburgh, Pittsburgh, PA, <sup>2</sup>University of Chicago, Chicago, IL, <sup>3</sup>Wright State University, and <sup>4</sup>The New York Hospital-Cornell Medical Center, New York (U.S.A.)

(Received 9 October, 1985)

(Accepted 28 January, 1986)

---

### Summary

The clinical history before transplantation and subsequent clinical and biochemical course of 3 children and one adult with hereditary tyrosinemia treated by orthotopic hepatic transplantation is described. All four patients are now free of their previous dietary restrictions and appear to be cured of both their metabolic disease and their hepatic neoplasm.

---

### Introduction

Hereditary tyrosinemia is an inborn error of tyrosine metabolism which results from a deficiency of the enzyme, fumarylacetoacetate hydrolase [1-6]. A pathognomic feature of the disease is the presence of succinyl acetone (4,6-dioxoheptonic acid) in the serum and urine of affected persons. It is characterized by multiple proximal renal tubular defects, including a decreased capacity to reabsorb phosphate which leads to rickets, and progressive hepatic fibrosis leading to cirrhosis and hepatoma [1,5-10]. Intermit-

tant extreme elevations of alpha-fetoprotein occur in all patients with the disease. To date, with the exception of a single patient, the clinical management of children with this disorder has been limited to dietary manipulation [7,11-14]. We have performed orthotopic hepatic transplantation in 4 patients with tyrosinemia, 3 children and 1 adult, who had developed hepatic neoplasms. The present communication is a report of the biochemical findings and clinical course before and after transplantation in these four patients.

---

This work was supported in part by grants from the NIAAA, no. AA04425 and the Gastroenterology Medical Research Foundation of Southwestern Pennsylvania.

Address reprint requests to: D.H. Van Thiel, M.D., 1000J Scaife Hall, University of Pittsburgh, Pittsburgh, PA 15261, U.S.A.

*Case presentations**Patient 1*

LT is a 4½-year-old girl who was referred because of hepatic failure, ascites, Fanconi's syndrome, a biopsy-proven hepatoma with an alpha-fetoprotein level of 182 000 ng/ml and failure to thrive. Developmental milestones had occurred normally until 6 months of age, but she was not standing or making sounds at 13 months of age. At 9 months of age, her hemoglobin was 12.5 g/dl. At 1 year it was 10.5 at which time her spleen was noted to be enlarged. At 18 months she was at the 25th percentile in weight and 50th percentile for height and had a head circumference at the 15th percentile. In addition her liver was enlarged and the spleen was enlarged 2 cm below the left costal margin. Neurologic evaluation revealed poor levels of proximal muscle strength in the lower extremities. Plasma tyrosine (751 µM; nl = 21–87 µM), methionine (989 µM; nl = 6–39 µM), and ammonia (9.4 mM; nl < 40 mM) were all elevated. Similarly urinary threonine, serine, glycine, alanine, methionine, isoleucine and tyrosine were increased (data not shown). No response to glycogen was observed either fasting or post prandially and galactose-1-phosphate uridylyltransferase activity was within normal limits. The serum alpha-fetoprotein level was increased markedly at 182 000 ng/l. Recurrent episodes of hypoglycemia and acidosis were prominent clinical problems. Liver biopsy showed cirrhosis with nodular areas with variable amounts of steatosis. The hepatic enzymes of tyrosine metabolism measured in the liver included: tyrosine amino transferase (0.024 units/mg protein, nl = 0.027–0.091); 4 hydroxyphenylpyruvate di-oxygenase (<0.004 units/mg protein; nl = 0.085–0.144); and fumararyl acetoacetate hydrolase (0.15 units/mg protein; nl = 0.60–1.17). A diagnosis of hereditary tyrosinemia was made and she was placed on a severely restricted tyrosine-free diet.

She had been followed prospectively with serial abdominal ultrasound examinations at quarterly intervals and 4 months prior to transplantation several new hepatic defects consistent with hepatoma were detected. Pertinent laboratory data are shown in

Table 1. She underwent orthotopic hepatic transplantation on 11 November, 1981. The liver was found to contain numerous small hepatomas measuring 3–5 cm in diameter. Postoperatively she did well until early 1983 when her serum bilirubin level increased slightly and hepatic rejection was diagnosed. She failed to respond to increased immunosuppression and underwent a second liver transplant on 13 May, 1983. She has been well and eating an unrestricted diet for 31 months following her second transplant.

*Patient 2*

CB is a 22-year-old short prepubertal woman who was referred after she had undergone a complicated right hepatic lobe resection for hepatoma. At the age of 3 years she was noticed to have marked growth retardation, hypophosphatemic vitamin D-resistant rickets, hepatomegaly and proteinuria. A 24-h urine demonstrated a generalized amino aciduria with hypertyrosyluria and *p*-hydroxyphenylacetic aciduria. Serial serum amino acid levels demonstrated 3–4-fold increases in the levels of tyrosine and glutamic acid. She was treated with vitamin D, oral phosphate and a 6% sodium 4% potassium citrate solution and a tyrosine-deficient diet. At age 7 an angiogram demonstrated a homogenous large liver with vascular tortuosity consistent with cirrhosis but no tumor. At age 21 years she was noted to have an even larger liver and angiography demonstrated a large tumor involving the right hepatic lobe. She had a preoperative alpha-fetoprotein level of 2 740 ng/ml, Fanconi's syndrome, and hepatic failure manifested as ascites, jaundice and a coagulopathy. Pertinent additional laboratory data are presented in Table 1. She underwent orthotopic hepatic transplantation 20 January, 1983 and she has been well and eating an unrestricted diet since, now 35 months after the transplant.

*Patient 3*

VO is a 4¼-year-old girl with tyrosinemia who was referred to us at 31 months of age because of hepatic failure manifested as coagulopathy, ascites and jaundice. She had an abnormal alpha-fetoprotein of 4 600 ng/ml which declined to 1 100 ng/ml by 41 months of

TABLE I  
CLINICAL AND LABORATORY DATA OBTAINED PREOPERATIVELY OR FROM THE RECORD PRIOR TO REFERRAL

	Patient			
	LT	CB	VO	WT
Cirrhosis	+	+	+	+
Hepatoma	+	+	+	+
Rickets	+	+	+	+
Fanconi syndrome	-	+	+	+
Ascites	+	+	+	+
Protime pt/control (s)	15/12	17/11	17/12	15/11
Platelet count ( $\times 1000$ )	52	54	39	132
WBC count ( $\times 1000$ )	9.0	11.7	3.6	2.9
Bilirubin (mg/dl)	1.8	2.9	1.8	3.7
Albumin (g/dl)	3.8	2.8	3.6	2.9
Hepatic fumarylacetoacetate hydrolase activity	markedly decreased	absent	+ <sup>a</sup>	markedly decreased
Urinary succinylacetate	+			
Urinary succinylacetoacetate			absent	absent
Plasma tyrosine	normal <sup>b</sup>	normal <sup>b</sup>		

<sup>a</sup> Present but reduced.

<sup>b</sup> Normal on dietary control (tyrosine-free diet).

+ = increased.

age following intensive in hospital dietary management. Additional pertinent laboratory data are shown in Table 1. On 15 January, 1984 she underwent orthotopic hepatic transplantation at which time multiple hepatomas were found in the removed organ. The child is now well and eating an unrestricted diet 23 months post-transplantation.

#### Patient 4

WT is a 3¼-year-old female who was referred to us because of hepatic failure, Fanconi syndrome and the finding of an abnormal alpha-fetoprotein of 13 560 ng/ml. Preoperative laboratory data are shown in Table 1. Orthotopic hepatic transplantation was performed on 28 May, 1984. Eighteen months

postoperatively, she is well and eats an unrestricted diet.

#### Methods

All plasma and urine samples collected preoperatively were obtained while the patients were on a strict tyrosine-free diet. All samples collected following transplantation were obtained while the patients were ingesting a standard hospital diet. Plasma samples for amino acid analysis were deproteinized using sulfosalicylic acid. Urine samples were adjusted to pH 2.2 with concentrated hydrochloric acid. The deproteinized samples were assayed on a Beckman 119

CL automatic amino acid analyzer.

Urinary succinyl acetate and succinyl acetoacetate were assayed according to the method of Grenier et al. [6].

#### Other laboratory tests

All standard blood and urinary chemistry studies were performed by the Clinical Pathology Laboratory of the University of Pittsburgh School of Medicine, Department of Pathology either at Children's Hospital of Pittsburgh or at the Presbyterian-University Hospital.

#### Follow-up

Each patient described above and transplanted for tyrosinemia has been followed closely since transplantation and is currently doing well without evidence of tyrosinemia or hepatic neoplasia. The three children are all growing normally and are entirely free of their former dietary restriction. The one adult has not grown or progressed further through puberty since transplantation. She is now 35 months post-transplantation. She continues to demonstrate very mild delta aminolevulinic aciduria but not any of the

plasma findings of tyrosinemia (Table 2).

Laboratory data obtained on these patients during the postoperative period and/or at last follow-up examination are shown in Table 2 and Figs. 1-4.

#### Discussion

The four patients herein reported are of interest for several reasons: (1) they are the first 4 cases of tyrosinemia for which orthotopic hepatic transplantation has been applied and resulted in life outside hospital on no dietary restriction; (2) all 4 patients had preoperative identifiable hepatomas present in the removed liver; (3) each patient is currently free of all evidence of hepatic cancer and has an undetectable alpha-fetoprotein level; (4) all abnormal serum amino acid levels noted preoperatively have returned to normal following transplantation and have remained so since transplantation without dietary restriction; and (5) urinary amino acid excretion has been either normal or only minimally abnormal following successful liver transplantation in patients 1 and 2, the only two so studied. However, patient 2 continues to

TABLE 2  
LABORATORY DATA OBTAINED POSTOPERATIVELY OR IN FOLLOW-UP

	Patient			
	LT	CB	VO	WT
Alpha-fetoprotein	absent	absent	absent	absent
Protome pt/control (s)	11/11	11/11	11/11	11/11
Albumin (g/dl)	4.6	4.6	3.1	4.7
Calcium (mg/dl)	10.6	10.2	9.2	10.1
Phosphate (mg/dl)	3.9	4.1	3.1	4.2
Urinary delta aminolevulinic acid (mg/dl)	absent	absent	ND+	ND
Succinyl acetone (mg/g creatinine)	absent	18.00 <sup>a</sup>	ND	ND
<i>p</i> -Hydroxyphenyl acetic acid (mg/g creatinine)	absent	29.56 <sup>a</sup>	ND	ND
Lactic acid (mg/g creatinine)	absent	3.18 <sup>a</sup>	ND	ND

<sup>a</sup> Results from the McGill University Biomedical Mass Spectrometry Unit.  
ND = not done, + = increased.

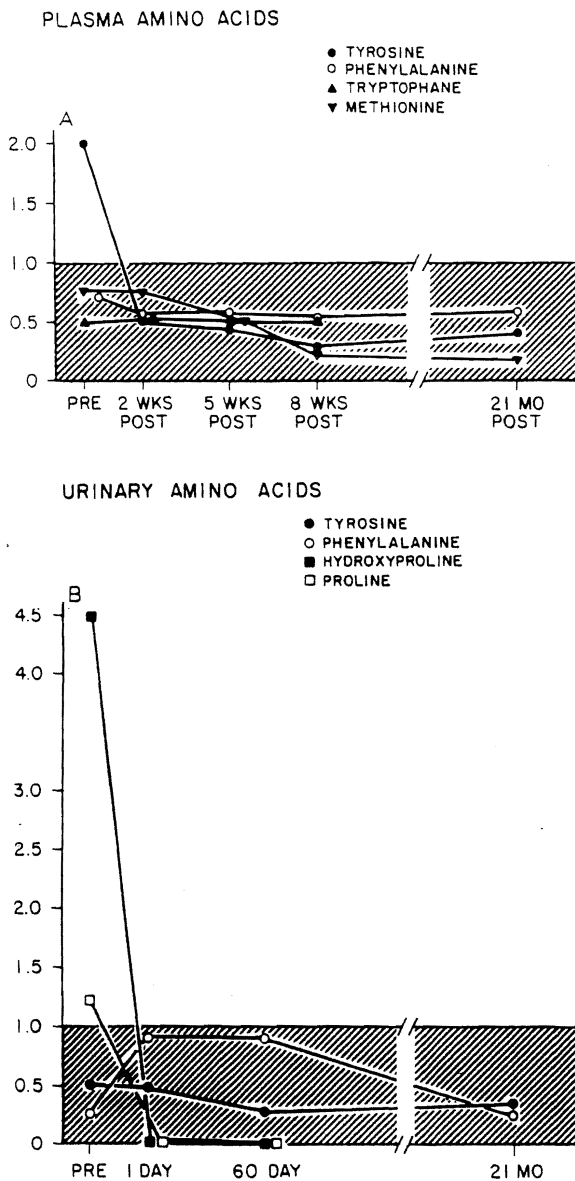


Fig. 1. Fasting plasma (A) and 24-h urinary (B) amino acids before and after liver transplantation of Case 1. The shaded area represents the range of normal. The units on the ordinate are expressed in terms of units times the upper limit of normal (variable range for each).

excrete succinyl acetone suggesting that this metabolite is still being produced at some nonhepatic site (Table 2).

In such cases referral for possible orthotonic liver transplantation was initiated because of hepatic fail-

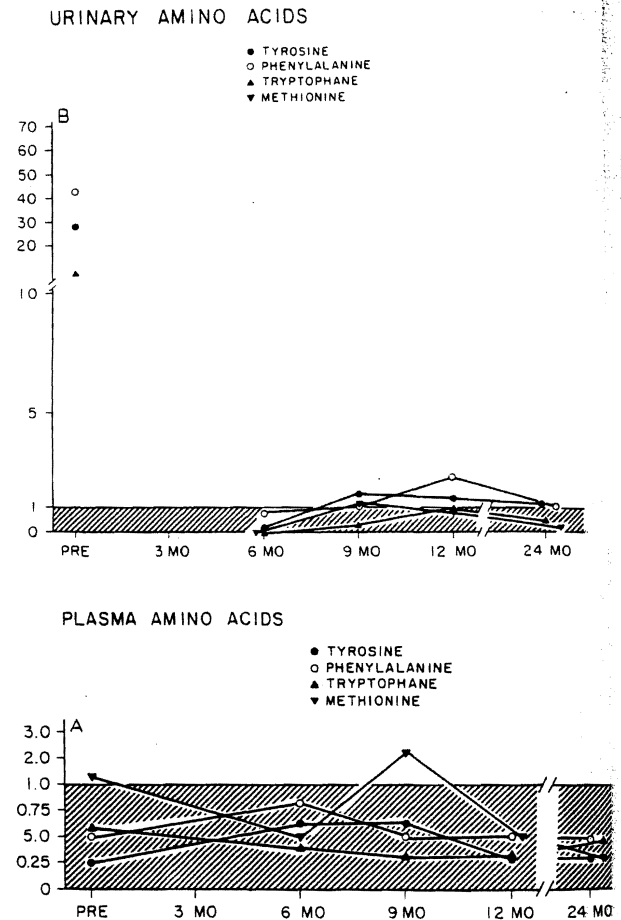


Fig. 2. Fasting plasma (A) and 24-h urinary (B) amino acids before and after liver transplantation of Case 2. The units as the ordinate are expressed in terms of units times the upper limit of normal.

ure either with or without a recognized hepatic cancer. These data demonstrate that the consequences of tyrosinemia such as abnormal plasma and urinary amino acid levels, growth failure, liver disease and hepatic neoplasms may be corrected as a result of successful orthotopic hepatic transplantation.

Interestingly however, is the observation that despite the fact of an apparent biochemical cure of tyrosinemia for 32 months following liver transplantation, the single adult studied has not grown as have the three children so treated and she has not progressed into puberty. This suggests that either her preexisting tyrosinemia has stunted her growth per-

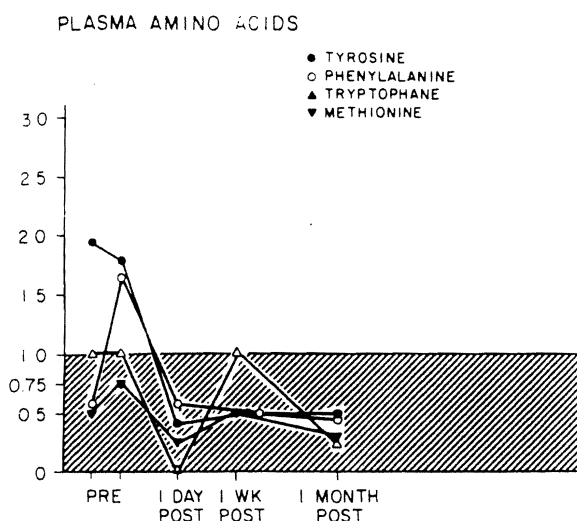


Fig. 3. Fasting plasma amino acids in Case 3 before and after liver transplantation.

manently and has prevented her progression through puberty, or that other nonhepatic sites of her fumaryl acetoacetate hydrolase deficiency either are responsible for, or regulate these processes. Her continued urinary excretion of small amounts of succinyl acetone (less than 1/3 that observed prior to liver transplantation) is consistent with this possibility. The specific location of these postulated nonhepatic sites are unknown at this time. In contrast to the findings in the one adult studied, the three children transplanted for tyrosinemia have all demonstrated normal linear growth postoperatively. The specific mechanisms responsible for this difference in response to successful liver transplantation for hereditary tyrosinemia between children and adults remains to be determined.

These patients are also of interest in that their hepatic neoplasms appear to be cured and apparently do not reoccur following successful orthotopic liver transplantation. This finding is quite different from that which occurs in adults with hepatoma and/or cholangiolar carcinoma not associated with metabol-

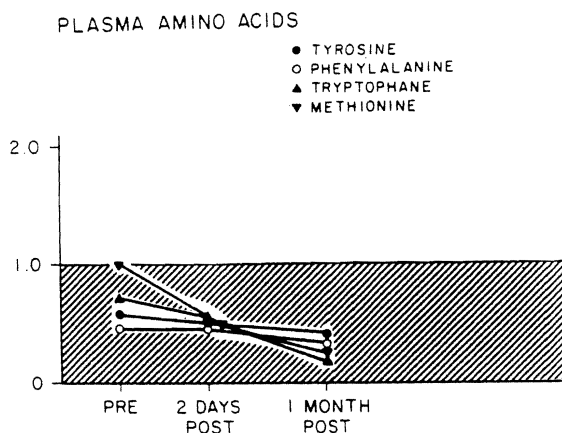


Fig. 4. Fasting plasma amino acids in Case 4 before and after liver transplantation.

ic liver disease who have been treated with transplantation. Such individuals, despite successful transplantation, redevelop or express their neoplasms in the transplanted liver and usually do so within 1 to 2 years following transplantation. Our experience with hereditary tyrosinemia is quite different yet it is similar to our experience with other metabolic liver diseases of children which also are associated with hepatic neoplasia such as glycogen storage disease (n = 4) and antitrypsin deficiency (n = 25). Following successful transplantation and resolution of the primary metabolic abnormality, hepatic neoplastic transformation has not been a problem in such children.

In summary, we describe 4 cases of tyrosinemia, each with hepatic cancer and liver failure, treated successfully with orthotopic hepatic transplantation and cured of both their metabolic disorder and their hepatic neoplasm. Normal linear growth has occurred following transplantation in the three children operated upon who were less than 5 years of age at the time of transplantation but has not occurred in the one adult with markedly retarded bone growth and sexual development due to prolonged disease (22 years).

NOTICE: THIS MATERIAL MAY BE PROTECTED BY COPYRIGHT LAW (TITLE 17 U. S. CODE)

## References

- 1 Lindblad B, Lindstedt S and Steen G. On the enzymatic defects in hereditary tyrosinemia. *Proc Nat Acad Sci (USA)* 1977; 74:4641-4645.
- 2 Berger R, Smith GPA, Stoker-de Vries SA, et al. Deficiency of fumaryl-acetoacetate in a patient with hereditary tyrosinemia. *Clin Chim Acta* 1981; 114:37-44.
- 3 Kvittingen EA, Jellum E and Stokke O. Assay of fumaryl-acetoacetate fumarylhydrolase in human liver-deficient activity in a case of hereditary tyrosinemia. *Clin Chim Acta* 1981; 115:311-319.
- 4 Christensen E, Jacobsen BB, Gregerson N, et al. Urinary excretion of succinylacetone and delta amino-levulinic acid in patients with hereditary tyrosinemia. *Clin Chim Acta* 1981; 116:331-341.
- 5 Fallstrom SP, Lindblad B and Steen G. On the renal damage in hereditary tyrosinemia and on the formation of succinylacetoacetate and succinylacetone. *Acta Paediat Scand* 1981; 70:315-320.
- 6 Grenier A, Lescault A, Laberge C, et al. Detection of succinylacetone and the use of its measurement in mass screening for hereditary tyrosinemia. *Clin Chim Acta* 1982; 123:93-99.
- 7 Tremblay M, Belanger L, Larochelle J, et al. Tyrosinémie héréditaire — Examen du foie en microscopie électronique de biopsies hépatiques. Observation de sept cas. *Union Méd Canada* 1977; 106:1014-1016.
- 8 Larochelle J, Mortezaei A, Belanger M, et al. Experience with 37 infants with tyrosinemia. *Can Med Ass J* 1967; 97:1051-1054.
- 9 Prive L. Pathological findings in patients with tyrosinemia. *Can Med Ass J* 1967; 97:1054-1056.
- 10 Weinberg AG, Mize CE and Worthen HG. The occurrence of hepatoma in the chronic form of hereditary tyrosinemia. *J Pediat* 1976; 88:434-438.
- 11 Bodegard G, Gentz J, Lindblad B, et al. Hereditary tyrosinemia, Part 3 (On the differential diagnosis and the lack of effect of early dietary treatment). *Acta Paediat Scand* 1969; 58:37-48.
- 12 Gaull GE, Rassin DK, Solomon GE, et al. Biochemical observations on so called hereditary tyrosinemia. *Pediat Res* 1970; 4:337-344.
- 13 Michals K, Matalon R and Wong PWK. Dietary treatment of tyrosinemia Type I. *J Amer Diet Ass* 1978; 73:507-514.
- 14 Fisch RV, McCabe ERB, Doeden D, et al. Homotransplantation of the liver in a patient with hepatoma and hereditary tyrosinemia. *J Pediat* 1978; 93:592-596.
- 15 Meister A and Greenstein JP. Enzymatic hydrolysis of 2,4-diketo acids. *J Biol Chem* 1948; 175:573-578.