

PORTAL VEIN GRAFTS IN HEPATIC TRANSPLANTATION

Byers W. Shaw, Jr., M.D., Shunzaburo Iwatsuki, M.D.,
Klaus Bron, M.D., *and* Thomas E. Starzl, M.D., PH.D., F.A.C.S.,
Pittsburgh, Pennsylvania

Reprint from

SURGERY, *Gynecology & Obstetrics*

JULY, 1985

VOLUME 161, 66-68

Copyright, 1985, by The Franklin H. Martin Memorial Foundation

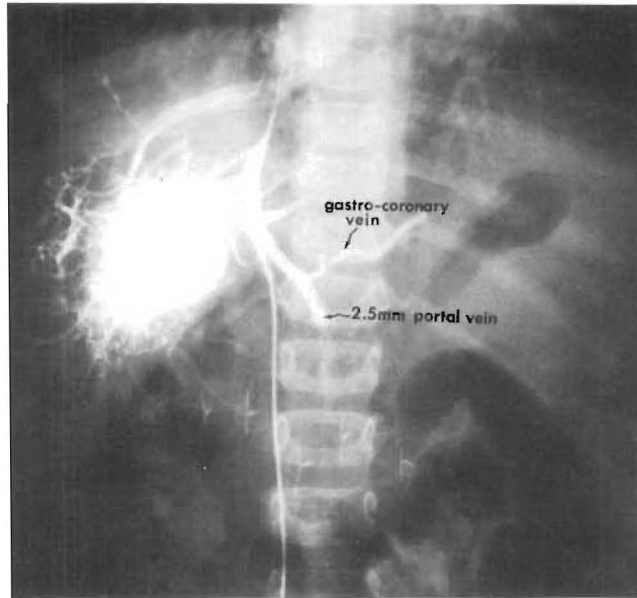


FIG. 1

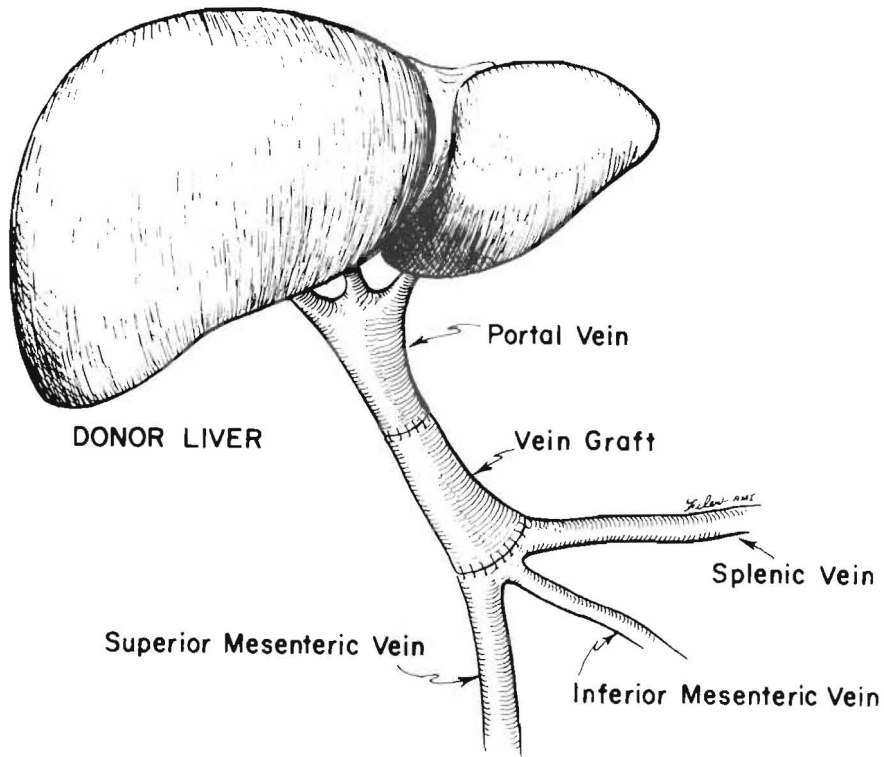


FIG. 2

FIG. 1. Wedged hepatic venogram showing patent, 2.5 millimeter portal vein.
 FIG. 2. Vessel graft for portal vein reconstruction.

*Portal Vein Grafts in Hepatic Transplantation.—Byers W. Shaw, Jr.,
 Shunzaburo Iwatsuki, Klaus Bron and Thomas E. Starzl.*

PORTAL VEIN GRAFTS IN HEPATIC TRANSPLANTATION

Byers W. Shaw, Jr., M.D., Shunzaburo Iwatsuki, M.D.,

Klaus Bron, M.D., and Thomas E. Starzl, M.D., PH.D., F.A.C.S.,

Pittsburgh, Pennsylvania

CONFIRMATION of patency of the portal vein by either ultrasound or angiography is a routine part of the evaluation of patients being considered for hepatic transplantation (1). Complete thrombosis of the portal vein usually has been viewed as precluding successful orthotopic hepatic replacement (1). In addition, some pediatric patients present with extremely small (less than 4 to 5 millimeters in diameter) portal veins which, although patent, have proved to be thick walled and sclerotic. Our recent experience has shown that, in both of these situations, successful and complete revascularization of hepatic allografts is quite feasible.

Two patients, ages 47 and 21 years, presented with complete thrombosis of the portal vein. In four pediatric patients ranging in age from one to five years, the portal vein proved to be patent but measured less than 4 millimeters in diameter (Fig. 1). Furthermore, when the vessels were transected, their luminal caliber was found to be further reduced by sclerosis. Another instance involved a seven year old boy who had a portal vein thrombosis with recanalization.

In all seven of these instances, restoration of adequate portal venous flow to the allograft was achieved by dissecting out the area of confluence between the splenic and superior mesenteric veins in order to obtain a patent vessel of adequate caliber. More importantly, in four of these instances, vessel grafts were required in order to span the distance from the more proximal recipient vessel to the hepatic allograft portal vein (Fig. 2). On the other hand, in three instances involving pediatric patients, the portal vein on the hepatic allograft was of adequate length to obviate the use of a vein graft.

The vessel grafts were obtained as part of the routine liver procurement procedure as has been

our practice for a number of years (2). To this end, following removal of the abdominal organs, the terminal abdominal aorta and inferior vena cava in continuity with the entire complex of iliac vessels are excised, placed in tissue culture medium and transported in ice along with the liver. The usefulness of arterial grafts has been described previously (3).

In the first patient, an iliac vein was used, and in the second and fourth patients, the distal end of the inferior vena cava was a better size match. In the third patient, a donor pulmonary artery was used as a graft because both the inferior vena cava and iliac vein grafts were unsatisfactory.

All patients have made uneventful recoveries except for the third patient who died of acute rejection on the tenth postoperative day but was found at autopsy to have a patent portal vein graft. The six surviving patients have now been observed from one to 24 months. Repeat angiograms in the second patient studied, four weeks after transplantation, showed a patent portal vein (Fig. 3).

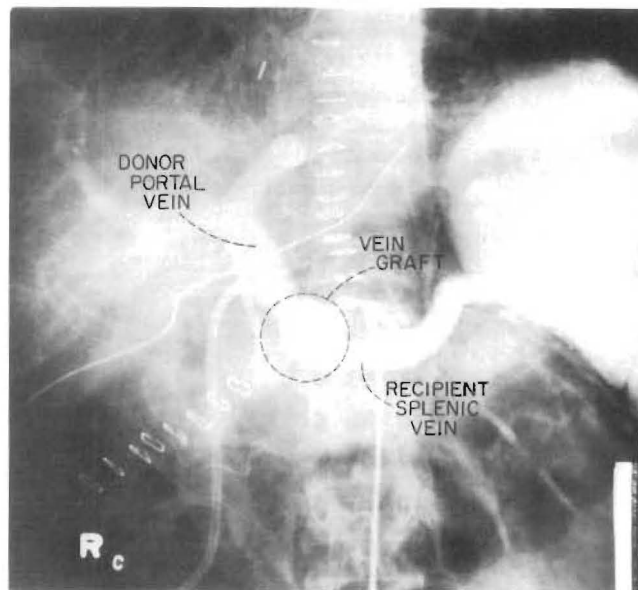


FIG. 3. Angiograms of the second patient showing patent vessel graft.

From the Department of Surgery, University of Pittsburgh Health Center, Pittsburgh.

Supported by research grants from the Veterans Administration; by project grant No. AM-29961 from the National Institutes of Health, and by grant No. RR-00084 from the General Clinical Research Centers Program of the Division of Research Resources, National Institutes of Health.

Reprint requests: Dr. Byers W. Shaw, Jr., 3601 Fifth Avenue, Room 103 Falk Clinic, Pittsburgh, Pennsylvania 15213.

In the course of the recipient operation for hepatic replacement, early recognition of a thrombosed or otherwise inadequate portal vein, combined with an aggressive approach at obtaining control of the more proximal area of confluence of the splenic and superior mesenteric veins, has resulted in a successful transplantation for several of the patients, one of whom died at a later date because of acute rejection. The dissection required, behind the neck of the pancreas and under the duodenum, has not resulted in any

injury to these organs or in additional hemorrhage.

REFERENCES

1. VAN THIEL, D. H., SCHADE, R. R., STARZL, T. E., and others. Liver transplantation in adults. *Hepatology*, 1982, 5: 637-640.
2. STARZL, T. E., HALGRIMSON, C. G., KOEP, L. J., and others. Vascular homografts from cadaveric organ donors. *Surg. Gynecol. Obstet.*, 1979, 149: 737.
3. SHAW, B. W., JR., IWATSUKI, S., and STARZL, T. E. Alternative methods of hepatic graft arterialization. *Surg. Gynecol. Obstet.*, 1984, 159: 490-493.