

Total Pancreaticoduodenal Homotransplantation in Dogs Immunosuppressed With Cyclosporine and Steroids

Hector S. Dillz-Perez, MD, Pittsburgh, Pennsylvania
Ho-Qun Hong, MD, Pittsburgh, Pennsylvania
Eduardo de Santibanes, MD, Pittsburgh, Pennsylvania
Carlos Bedetti, MD, Pittsburgh, Pennsylvania
Shunzaburo Iwatsuki, MD, Pittsburgh, Pennsylvania
Byers W. Shaw, Jr., MD, Pittsburgh, Pennsylvania
Thomas E. Starzl, MD, PhD, Pittsburgh, Pennsylvania

Improved survival of segmental pancreatic homografts has been obtained in animals using cyclosporine alone for immunosuppression [1,2]. Despite this, the results in clinical trials of pancreas transplantation have remained poor, in part because effective ways of draining or eliminating the exocrine drainage of the segmental grafts have not been developed [3]. Herein we report our experience in dogs with the alternative procedure of total pancreaticoduodenal homotransplantation using cyclosporine combined with small doses of steroids.

Material and Methods

Twenty mongrel dogs of both sexes weighing between 15 and 25 kg were used as donors or recipients in 10 experiments. The homografts were removed from the donor through a midline incision. The transplant specimen was prepared, preserving the splenic vessels out to their entry into the spleen at the site of splenectomy and retaining the hepatic artery throughout its course, including its termination as the gastroduodenal artery (Figure 1, top). The splenic, superior mesenteric, and portal veins were retained with the specimen which included both lobes of the pancreas as well as the duodenum. The composite organ graft was flushed through the celiac axis with chilled, modified Collin's solution (Travenol) and preserved for 2 to 3 hours.

The organ complex was revascularized in the left iliac fossa with end-to-side anastomoses of the donor celiac axis

and portal vein, to the recipient iliac vessels (Figure 1, above). The proximal duodenum of the graft was closed, and the distal end was anastomosed end-to-side to the proximal recipient jejunum. Either then or a few days later, the recipient dog underwent total pancreaticoduodenectomy. Gastrointestinal reconstruction was performed with cholecystojejunostomy and gastrojejunostomy (Figure 1, right).

All dogs were given intravenous fluids, penicillin, and gentamicin for 5 days postoperatively. The animals were allowed to drink water ad libitum after the second postoperative day and to eat solid food after the fifth postoperative day. Immunosuppression consisted of cyclosporine at an oral dose of 17 mg/kg per day beginning on the day after operation, and prednisone, 0.5 mg/kg per day. Fasting glucose concentrations in the venous plasma were measured daily during the first postoperative week and 3 times a week thereafter. Intravenous glucose tolerance tests were performed in two dogs who survived more than 60 days. The homografts were sampled at the time of sacrifice or at autopsy. The formalin-fixed tissues were stained with hematoxylin-eosin and examined by light microscopy.

Results

The mean survival of the 10 recipients was 50.6 days. The dogs were normoglycemic for 10 to 210 days, with a mean of 41.8 days (Table I). The postoperative blood glucose levels were within normal limits during most or all of the postoperative course of all 10 dogs. Hyperglycemia developed as a terminal event in most of the animals, including three whose grafts were rejected. The intravenous glucose tolerance test in the two dogs that survived for more than 60 days showed a rapid recovery from the glucose load (Figure 2).

Graft venous thrombosis, wound dehiscence, and acute pancreatitis with intestinal intussusception each caused one death. These were considered to be

From the the Department of Surgery, University of Pittsburgh Health Center, University of Pittsburgh, Pittsburgh, Pennsylvania, and The Department of Pathology, Veterans Administration Hospital, Pittsburgh, Pennsylvania. Supported in part by Grant AM-29961 from the National Institutes of Health and by Grant RR-00084 from the General Clinical Research Centers Program of the Division of Research Resources, Veterans Administration, National Institutes of Health, Bethesda, Maryland.

Requests for reprints should be addressed to Thomas E. Starzl, MD, Department of Surgery, 1084 Scaife Hall, Pittsburgh, Pennsylvania 15261.

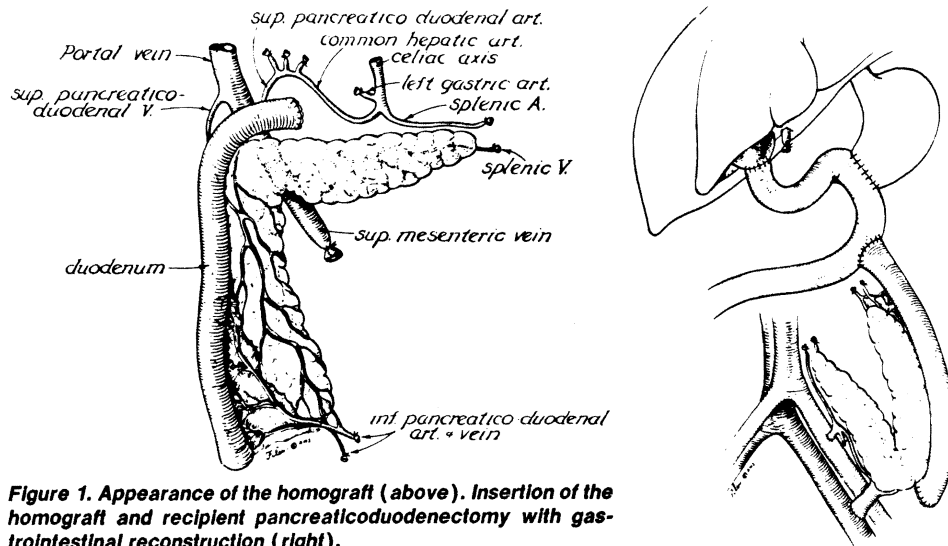


Figure 1. Appearance of the homograft (above). Insertion of the homograft and recipient pancreaticoduodenectomy with gastrointestinal reconstruction (right).

technical complications. Four dogs died between 16 and 210 days as the result of marginal ulcer perforation (two dogs) and hemorrhage (two dogs) at the site of the gastrojejunostomy. Three of the 10 deaths were attributed to rejection and subsequent diabetes, perforation, or both of the grafted duodenum (Table I).

Three of the 10 grafts were necrotic at the time of autopsy and were presumed to have been rejected; the duodenum had perforated in two of the three. A fourth graft was so severely autolyzed from pancreatitis that histopathologic analysis of the pancreas was not possible (Table II). A fifth graft had a thrombosed venous anastomosis with predominant

histopathologic findings of acute venous congestion. The histopathologic findings in the other five grafts after 16 to 210 days are summarized in Table II. The findings included light to moderate cellular infiltration, variable atrophy of the duodenal mucosa, and some thickening of the duodenal serosa. The exocrine and endocrine pancreatic tissues were surprisingly well preserved.

TABLE I Dog Survival and Cause of Death

Dog	Survival* (d)	Normoglycemia† (d)	Cause of Death
1	210	210	Hemorrhage from marginal ulcer
2	23	18	Wound dehiscence; sacrificed
3	33	26	Hemorrhage from marginal ulcer
4	27	24	Perforated marginal ulcer
5	13	10	Anastomotic venous thrombosis
6	24	15	Pancreatitis and pseudocyst; intussusception
7	88	63	Rejection; perforation of the grafted duodenum
8	16	16	Perforated marginal ulcer
9	24	16	Rejection
10	48	38	Rejection; perforation of the grafted duodenum

* The mean survival was 50.6 days.

† The mean duration of normoglycemia was 41.8 days.

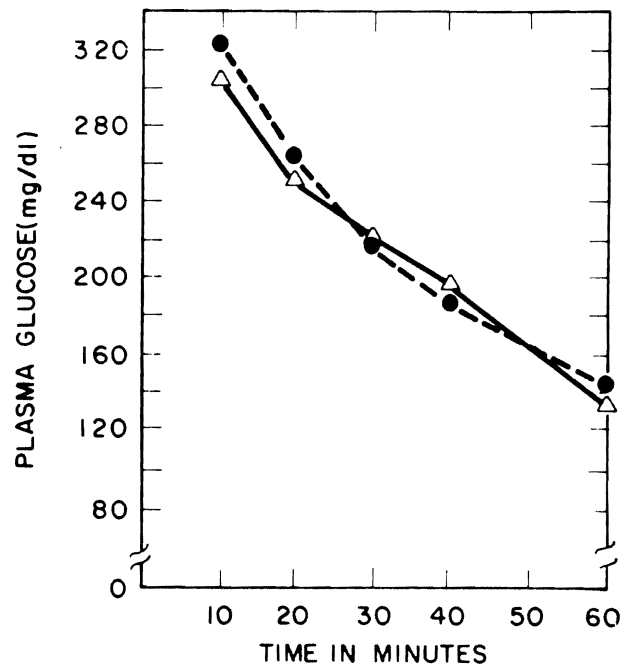


Figure 2. Intravenous glucose tolerance tests in two dogs that were long-term survivors of total pancreaticoduodenal homotransplantation. The glucose dose was 0.5 g/kg, and the sample collections were started 10 minutes after completion of the 5 minute infusion.

TABLE II Pathologic Findings in Grafts

Dog	Pancreas						Mucosa	Duodenum	SG Level at Time of Death (mg/dl)
	Exocrine Pancreas	Endocrine Pancreas	Fibrosis	Cellular Infiltrate	Vascular Changes	Serosa			
1	Normal	Normal	None	Minimum, mononuclear, and focal	None	Normal	Normal; some perivascular infiltrate	Normal	119
2	Well preserved	Well preserved	Mild interstitial	Minimum, mononuclear, and focal	Mild swelling of endothelial cells	Moderately atrophic	Normal; some perivascular infiltrate	Moderately thickened	160
3	Well preserved	Well preserved	None	Moderate mononuclear	Mild swelling of endothelial cells	Moderately atrophic	Moderate cellular infiltrate between layers	Mild thickening	111
4	Well preserved	Well preserved	Moderate interstitial	Moderate mononuclear	Mild thickening of arterial wall	Severe atrophy	Moderate cellular infiltrate between layers	Mild thickening	120
5	Venous congestion	Venous congestion	Congestion	Congestion	Congestion	118
6	Tissue autolyzed	Tissue autolyzed	Tissue autolyzed	Tissue autolyzed	Tissue autolyzed	309
7	Necrotic	Necrotic	Necrotic	Necrotic	Necrotic	266
8	Normal	Normal	None	Minimum mononuclear and focal	None	Normal	Normal	Normal	92
9	Necrotic	Necrotic	Necrotic	Necrotic	Necrotic	150
10	Necrotic	Necrotic	Necrotic	Necrotic	Necrotic	250

SG = serum glucose.

Comments

In the first attempts at whole pancreatic homotransplantation in dogs, the pancreas was part of a multiple gastrointestinal graft [4]. Five of the untreated canine recipients lived for 5.5 to 9 days, and during this time the blood sugar levels were nearly normal despite the fact that pancreatitis developed in four of the five pancreases [4]. Pancreaticoduodenal transplantation was first described by De Jode and Howard [5], and in 1967 and 1968 Lillehei et al [6,7] described a technique of pancreaticoduodenal transplantation which differed in only minor details from the technique described herein. Under immunosuppression with azathioprine and prednisone, one of the pancreaticoduodenal grafts functioned for several months [7].

The unique value of the composite graft technique is that the duodenal component of the organ complex can be used to drain the exocrine pancreatic excretions into the recipient gastrointestinal tract without jeopardizing the pancreatic duct system [8]. Unfortunately, it has not been possible to exploit this advantage using conventional immunosuppression with azathioprine and prednisone because of the inability to consistently control rejection of the duodenum. Complications of duodenal rejection have included ulceration and perforation and have been so lethal that after 1970, Lillehei et al [9] abandoned the pancreatic graft in favor of the segmental pancreatic transplant [3]. Acceptance of this position has been so general that no clinical pancreaticoduodenal transplantations have been recorded for a number of years [3].

With the improved immunosuppression that can be offered with cyclosporine and steroids, it may be appropriate to reassess the pancreaticoduodenal procedure. In the present study, the most important cause of death was peptic ulceration of the upper gastrointestinal tract in the recipient dog, a complication not of the graft but of the pancreaticoduodenal resection used to make the recipient animal diabetic. In the four dogs that died from this complication and in the dogs that died from dehiscence or graft venous

thrombosis, the preservation of the grafted duodenum was surprisingly good. The duodenal component of two necrotic grafts developed perforations, but the complications were late and were related to necrosis of the entire transplant. In a clinical setting there would have been ample time to reoperate and remove the graft.

Summary

Pancreaticoduodenal transplantation was performed with cyclosporine and steroid immunosuppressive therapy in 10 mongrel dogs that had pancreaticoduodenectomy. There was an average animal survival of 50.6 days and an average duration of normoglycemia of 41.8 days. We suggest that pancreaticoduodenal transplantation, which was abandoned as a clinical procedure 10 years ago, be reconsidered for clinical application.

References

1. Dutoit DF, Reece-Smith H, McShane P, Denton T, Morris PJ. Prolongation of segmental pancreatic allografts in dogs receiving cyclosporin A. *Transplantation* 1982;33:432-7.
2. McMaster P, Procyskyn A, Calne RY, Valdes R, Rolles K, Smith DJ. Prolongation of canine pancreas allograft survival with cyclosporin A: preliminary report. *Br Med J* 1980;280:444-5.
3. Sutherland DER. Report of international human pancreas and islet transplantation registry cases through 1981. *Diabetes* 1982;31(suppl 4):112-6.
4. Starzl TE, Kaupp HA Jr, Brock DR, Butz GW, Linman JW. Homotransplantation of multiple visceral organs. *Am J Surg* 1962;103:219-29.
5. De Jode LR, Howard JM. Studies in pancreaticoduodenal homotransplantation. *Surg Gynecol Obstet* 1962;114:553-8.
6. Lillehei RC, Idezuki Y, Feemster JA, et al. Transplantation of stomach, intestine, and pancreas: experimental and clinical observations. *Surgery* 1967;62:721-41.
7. Idezuki Y, Feemster JA, Dietzmann RH, Lillehei RC. Experimental pancreaticoduodenal preservation and transplantation. *Surg Gynecol Obstet* 1968;126:1002-14.
8. Orloff MJ, Lee S, Charters AC III, Grambort DE, Storck LG, Knox D. Long term studies of pancreas transplantation in experimental diabetes mellitus. *Ann Surg* 1975;182:198-206.
9. Lillehei RC, Simmons RL, Najarian JS. Pancreaticoduodenal allotransplantation. Experimental and clinical experience. *Ann Surg* 1970;172:405-36.