

539

# Liver transplantation

B3

L.J. Koep and T.E. Starzl

## Contents

1. Introduction	332
2. Indications for transplantation	332
2.1. Biliary atresia	333
2.2. Cirrhosis	333
2.2.1. Chronic aggressive hepatitis	333
2.2.2. Laennec's cirrhosis	334
2.2.3. Primary biliary cirrhosis, secondary biliary cirrhosis, sclerosing cholangitis and congenital biliary cirrhosis	335
2.3. Inborn errors of metabolism	335
3. Absolute and relative contraindications to orthotopic hepatic transplantation	336
3.1. Hepatic malignancy	336
3.2. Systemic infection	336
3.3. Massive hepatic necrosis	336
3.4. Portal vein thrombosis	337
3.5. Associated congenital anomalies	337
3.6. Inadequate personality	337
3.7. Age	337
4. Donor procurement	338
4.1. Donor selection	338
4.2. Donor hepatectomy	339
4.3. Multiple organ procurement	343
4.4. Anatomic variations in the donor liver	344
4.5. Preservation	345
5. The recipient operation	345
5.1. Recipient hepatectomy	345
5.2. Orthotopic hepatic homograft insertion	347
6. Postoperative management	351
6.1. Hemorrhage	351
6.2. Fluid and electrolyte balance	353
6.3. Antibiotics	354
6.4. Respiratory support	354
6.5. Nutrition	355
6.6. Immunosuppression	355
6.7. Biliary obstruction	356
7. Current results	362
7.1. 1963-1976	362
7.2. 1976-1978	362

8. Conclusions and future directions . . . . .	362
References . . . . .	363

### 1. Introduction

Considerable progress has been made in hepatic transplantation since the initiation of the University of Colorado series in March, 1963. Earlier work with orthotopic hepatic transplantation in dogs indicated the feasibility of this approach in man and fashioned the technical approach [14]. Since that time 165 patients have received orthotopic hepatic homografts and of these, 16 patients received two homografts. The current liver transplantation program at the University of Colorado has evolved primarily from experience derived from these patients. The details of the earlier experience have been fully described previously [16]. There fortunately has been a good dialogue with the Cambridge-King's College Hospital, London, group who have compiled the bulk of the remaining world experience [4].

This chapter discusses orthotopic hepatic transplantation as now performed at the University of Colorado. The indications, techniques, complications and results of hepatic transplantation in these 165 patients are presented. Hepatic transplantation clearly remains an unusual and heroic mode of therapy in terminal liver disease, but, nevertheless, one in which long-term survival and a good quality of life can be achieved.

### 2. Indications for transplantation

A candidate for orthotopic hepatic transplantation will have progressive liver disease unresponsive to more conventional therapy. Progression of the liver disease should in-

TABLE 1  
Indications for orthotopic hepatic transplantation, University of Colorado, March, 1963-July, 1978

Diagnosis	Number of patients	Number living over 1 year
Biliary Atresia	51	17
Chronic aggressive hepatitis	40	13
Primary liver malignancy	19	5
Alcoholic cirrhosis	15	4
Inborn errors of metabolism	10	6
Primary biliary cirrhosis	6	2
Sclerosing cholangitis	6	1
Secondary biliary cirrhosis	3	2
Congenital biliary cirrhosis	1	1
Budd-Chiari syndrome	1	1
Acute hepatic necrosis	1	0

dicating a terminal prognosis of less than one year. The patient, although deteriorating, should not be moribund and disease should be confined to the hepatobiliary system. Systemic disease, especially infection, must be readily controlled if present.

Obviously the goal of providing a life-sustaining homograft requires a recipient capable of withstanding the operative insult and postoperative immunosuppression. Preoperative blood pressure ideally should be within the normal range for the individual patient without inotropic cardiac support. The hepatorenal syndrome and hepatic encephalopathy, even with coma, have been common and should not deter transplantation in an otherwise stable patient. As survival in hepatic transplantation improves, selection of patients somewhat earlier in the course of their disease before the final cascade of multiple organ failures is justified. Earlier transplantation will expand the availability of transplantation for a given patient and hopefully further improve survival.

### 2.1. Biliary atresia

A prognosis, reliably established at under one year, is most readily available in biliary atresia. The inexorable fatal course of this disease has made inclusion of these children easy from the standpoint of early selection. Biliary atresia provided the single most common indication for transplantation in the University of Colorado series (Table 1). Portoenterostomy has prolonged survival in a select group of children at the University of Colorado [10]. In children relieved of jaundice but with progressive cirrhosis following portoenterostomy, the timing of transplantation becomes more difficult but some advantage is achieved by allowing time for growth. The existence of a previous portoenterostomy has the further advantage of providing a readily available roux limb for biliary reconstruction at the time of transplantation.

A limiting factor in hepatic transplantation for biliary atresia is donor availability. The youngest group of children transplanted have been around one year of age. Younger donors are preferred, although equivalent age donors are acceptable because the recipient livers are usually large for age. Criticism of biliary atresia as an indication for transplantation has been based on growth retardation and cushinoid appearance manifest by some of these children [4]. The quality of life enjoyed by those children both with and without obvious steroid effects has been, in our opinion, quite acceptable [18]. Pediatric clinic serving even the most stunted children is a very warm experience.

### 2.2. Cirrhosis

#### 2.2.1. Chronic aggressive hepatitis

In older children and adults, cirrhotic hepatic failure secondary to chronic active hepatitis is the most common indication for transplantation. Establishment of an imminently terminal prognosis is frequently difficult and often very advanced disease

362  
363

since the initiation with orthotopic hepatic in man and fashion received orthotopic grafts. The current evolved primarily liver experience have good dialogue with compiled the bulk

performed at the and results of hepatic transplantation liver disease, but, quality of life can be

massive liver disease disease should in-

1963-July, 1978

Number living  
over 1 year

17  
13  
5  
4  
6  
2  
1  
2  
1  
1  
0

must be accepted before transplantation is entertained. Patient acceptance of transplantation is sometimes difficult in those with recently discovered disease but usually is anxiously anticipated by those invalidated by years of chronic liver disease. Chronic hospitalization punctuated by only brief, poorly tolerated intervals at home signals the need for transplantation. Hepatic encephalopathy limits therapeutic options and may impose dietary restrictions incompatible with survival. When encephalopathy becomes difficult to control and in the absence of precipitating causes, such as bleeding or infection, transplantation is indicated on an urgent basis.

Clinical assessment of the need for transplantation can be supported by laboratory studies. Radionuclear scans, especially with the newer agents that display the hepatobiliary system, can estimate functioning hepatocyte mass and also reveal the development of primary liver malignancy. Synthesis capacity will be invariably depressed and reflected in low serum albumin and prolonged prothrombin times unresponsive to phytonadione. Detoxification of drugs, especially hypnotics, will be prolonged. Sulfo-bromophthalein sodium retention is prolonged but retention values have been quite variable. Serum bilirubin similarly can be variable with values as low as 2.5 mg% in terminal disease. Serum ammonia has been too inconsistent to be of any value. In terminal chronic aggressive hepatitis the serum transaminases are usually normal.

Chronic aggressive hepatitis associated with the hepatitis B surface antigen (HBsAg) indicates increased risk over cirrhosis of other etiologies following transplantation, because of the inability to eradicate the virus. Despite the administration of hyperimmune globulin in two patients at the University of Colorado before, during, and following transplantation, their condition eventually reverted to the HBsAg carrier state with one dying of progressive hepatic failure just short of one year. Cryptogenic cirrhosis would appear to involve serious risk but several patients have tolerated chronic antigenemia remarkably well following transplantation. One patient in the Cambridge-King's College series has been cleared of HBsAg with hyperimmune globulin following transplantation [7]. Chronic aggressive hepatitis both HBsAg-positive and -negative remains one of the preferred indications for hepatic transplantation at the University of Colorado.

#### 2.2.2. *Laennec's cirrhosis*

Alcoholic cirrhosis potentially provides the most frequent indication for hepatic transplantation in adults. The progressive aspect of this kind of cirrhosis is eliminated by absence from alcohol, but the subsequent prognosis is so variable that it may be difficult to define at what point alcoholic cirrhosis has become terminal. Clearly, any component of acute alcoholic hepatitis needs to be eliminated by prolonged documented abstinence in those patients whose livers are not shrunken. In the absence of acute alcoholic hepatitis, an alcoholic patient who exhibits hepatic failure and who is in reasonable general condition is considered to be an acceptable candidate for transplantation. Unfortunately, most patients die following alcoholic excess when acute alcoholic hepatitis is superimposed on alcoholic cirrhosis. Ideally, transplanted alcoholics

should avoid alcohol and two of the four now surviving have done that and are doing well. One patient is drinking excessively two years postoperatively and transient hepatic perturbations appear to follow binges. One patient is mixing street drugs and alcohol in moderation with apparently good results three years following transplantation.

### *2.2.3. Primary biliary cirrhosis, secondary biliary cirrhosis, sclerosing cholangitis and congenital biliary cirrhosis*

Cirrhosis arising from biliary tract disease is slowly progressive and again timing of transplantation is important in these diseases to facilitate with long survival. This group, more than others, is prone to social invalidism with prolonged hospitalizations. Pruritis can be incapacitating and uncorrectable without transplantation. Encephalopathy is less frequently an indication for transplantation. Primary biliary cirrhosis lends itself to technically easier transplantation due to the absence of portal hypertension and prior surgery. Both secondary biliary cirrhosis and sclerosing cholangitis, because of multiple prior operations, are technically the most hazardous. Because of their inexorable nature these diseases provide a readily identifiable indication for transplantation.

### *2.3. Inborn errors of metabolism*

Several enzymatic errors of metabolism resulting in cirrhosis have been corrected by liver transplantation. Approximately 15% of homozygotes deficient for  $\alpha_1$ -antitrypsin develop cirrhosis and hepatic insufficiency. Microscopically there is accumulation of an abnormal  $\alpha_1$ -antitrypsin within the hepatocyte but the mechanism of liver injury and scarring is uncertain. Hepatic transplantation corrected serum  $\alpha_1$ -antitrypsin levels avoiding homograft accumulation of this abnormal  $\alpha$ -globulin in seven patients [12]. When progressive liver disease with cirrhosis is documented, transplantation is indicated when the patient becomes debilitated.

Wilson's disease (hepatolenticular degeneration) is a disease of copper transport and storage. If diagnosed early, liver damage secondary to copper deposition can be prevented by treatment with penicillamine, but if advanced liver disease has already developed, patients with Wilson's disease are appropriate transplant candidates. Two patients in our series survived for 6 and 8½ years, with resolution of abnormal extrahepatic copper depositions and without copper deposition in their homograft livers. Two children, with congenital tyrosinemia and Type IV glycogen storage disease, respectively, complete the list of inborn errors of metabolism responding to transplantation in this series. Both children had clearly progressive hepatic failure preoperatively [6].

### *3. Absolute and relative contraindications to orthotopic hepatic transplantation*

#### *3.1. Hepatic malignancy*

Systemic disease, if not readily controllable, is a contraindication to hepatic transplantation. Malignancy, metastatic to the liver, has already demonstrated systemic involvement and for this reason has been avoided at the University of Colorado. The possibility of subsequent immunosuppression exacerbating metastatic disease has been the primary concern. Experience at King's College supports this view [26].

Primary hepatic malignancy was initially the leading indication for hepatic transplantation at the University of Colorado. A total of 19 patients were transplanted; the majority for hepatocellular carcinoma but four for bile duct carcinoma, one for intrahepatic cholangiocarcinoma, and two for an angiosarcoma. Nine survived over 3 months and all except one developed metastases. The one patient without metastases died at 5 months from complications of a subdural hematoma. Unlike the Cambridge-King's College experience, there have been no cures of hepatic malignancy in this series. The most significant palliation has been achieved in two patients with cholangiocarcinoma of the Klatskin type. These patients died at 2 and  $4\frac{1}{2}$  years of recurrent cancer. Two children, not included in the aforementioned group, were found to have small incidental hepatic malignancies after transplantation for biliary atresia and  $\alpha_1$ -antitrypsin deficiency. The child with biliary atresia has had no recurrence of her hepatoma now  $9\frac{2}{3}$  years following transplantation, and the other child is well  $1\frac{2}{3}$  years following incidental removal of her hepatoblastoma [25].

In those patients transplanted specifically for malignancy there have been no survivors at one year free of disease. Although palliation has been achieved in bile duct carcinomas, a more simplified approach employing transhepatic intubation appears to offer equivalent or superior results [23]. Barring an incidental finding, primary hepatic malignancy is now regarded as a relative contraindication, and malignancy metastatic to the liver as an absolute contraindication, to hepatic transplantation at the University of Colorado.

#### *3.2. Systemic infection*

While infection confined primarily to the liver, such as cholangitis and small hepatic abscesses, has responded well to transplantation, extrahepatic sources of infection have flared following the institution of immunosuppression. Transplantation should be avoided in the presence of pneumonia and extrahepatic abdominal abscesses. Spontaneous bacterial peritonitis has been observed to abate following transplantation.

#### *3.3. Massive hepatic necrosis*

Fulminant hepatitis may produce an autopsy picture of massive hepatic necrosis with

## Transplantation

hepatic transplanted systemic involvement. The possibility of disease has been the [26].

for hepatic transplanted; thecoma, one for intra- survived over 3 without metastases like the Cambridge- malignancy in this series with cholangio- years of recurrent were found to have biliary atresia and recurrence of her child is well 1½ years

have been no survived in bile duct intubation appears ending, primary he- and malignancy transplantation at

s and small hepatic es of infection have antation should be l abscesses. Spontaneous transplantation.

hepatic necrosis with

almost complete hepatocyte disappearance. The same process may, however, resolve almost completely with restitution of normal architecture. Acute fulminant hepatitis has been used as an indication for transplantation only once in our series. Now transplantation is avoided, in the hope that conventional support will allow time for hepatic regeneration. In these patients, there may be a place for auxiliary hepatic transplantation as a temporizing measure.

### 3.4. Portal vein thrombosis

Portal vein thrombosis has been incompatible with a technically satisfactory orthotopic transplant. When thrombosis has occurred in the postoperative period hepatic function has progressively deteriorated. If host portal vein thrombosis has preceded transplantation, the situation has proved hopeless. Inferior caval transposition to maintain portal flow in one patient was not successful and led to thrombosis of both the graft portal vein and recipient vena cava. It is usually difficult to detect portal vein thrombosis prior to transplantation, even with angiography, because of disturbed portal hemodynamics including hepatofugal portal flow. When portal vein thrombosis is a possibility, division of the other portal structures during recipient hepatectomy should be delayed until the portal vein is dissected and divided. The divided portal vein should be inspected carefully because recanalization of a thrombosed portal vein has been known to be inadequate to perfuse the homograft portal vein. Host hepatic artery thrombosis discovered at transplantation can be dealt with by anastomosing the donor hepatic artery or celiac axis to the recipient's celiac trunk or aorta.

### 3.5. Associated congenital anomalies

A pediatric cardiac murmur requires careful evaluation prior to considering transplantation. Major cardiac anomalies should disqualify a child for transplantation. Similarly a preduodenal portal vein discovered at the time of attempted portoenterostomy greatly complicates subsequent transplantation, however one such child has survived more than 5 years.

### 3.6. Inadequate personality

The psychological and social stress accompanying transplantation strains familial stability and exacerbates exogenous depressions. Unfortunately, preoperative evaluation is frequently impractical because of encephalopathy or urgency in proceeding with transplantation. When depression or rebellion threaten the continuity of immunosuppression, postoperative psychiatric support facilitates patient compliance [5].

### 3.7. Age

Only eight patients over age 50 have been transplanted and none are currently alive. The mean survival was 30 days, the longest being 87 days. At this time age 50 is

regarded as the upper age limit. In the range between age 45 and 50 years, transplantation is evaluated on an individual basis. Of the 11 patients within this range two survived over one year and one is still alive at 18 months, but the remainder had a mean survival of only 47 days. Over-age candidates regarded as otherwise good risk and having diseases technically less challenging, such as primary biliary cirrhosis would be considered for transplantation.

#### 4. Donor procurement

##### 4.1. Donor selection

The University of Colorado, located in Denver, Colorado, has an established referral pattern of organ donors within a metropolitan area of 1.6 million people. This population base has provided approximately 20 donors yearly. The ideal organ donor is a young adult or child, neurologically dead but with good perfusion of visceral organs. Cardiac output must not be compromised but cardiotropic drugs are frequently given. Continuous urinary output has been a good indicator of adequate visceral perfusion. Donors over age 50 are avoided as liver donors. Heart-beating cadaveric organ donors have been used at the University of Colorado since 1968 using the various specific criteria for the pronouncement of neurologic death by neurologists and neurosurgeons [3].

During the establishment of brain death a toxicology screen is run on the donors serum. Simultaneously the ABO group is determined and liver and kidney function tests ordered. The patient's history is reviewed for signs of malignancy, systemic infection or hepatitis. After declaration of brain death appropriate organs are harvested as expeditiously as possible.

Cytotoxic crossmatching is performed as preparations are being made for transplantation. Frequently the recipient's condition precludes further delay, and in ten patients transplantation was performed in the presence of a positive cytotoxic crossmatch. Five of these patients survived over 6 months. No hyperacute rejections were observed in this setting.

In certain desperate situations, particularly re-transplantation, even blood group incompatibility has been accepted. This breach of ABO compatibility has been accepted on eleven occasions. There were no hyperacute rejections but two patients had very severe early rejection.

Tissue typing has been performed, but because of a desperate recipient pool undergoing continuous attrition, the typing results have not been used for patient selection. The population of potential transplant candidates is so limited and volatile that application of tissue typing would remain severely restricted even if HLA typing correlated well with the clinical outcome, which has clearly not been the case in renal transplantation.



#### 4.2. Donor hepatectomy

The abdomen is opened through a midline xiphoid to pubis incision. An extension is made into the right chest by extending the incision laterally from just above the umbilicus and then superiorly through the 8th or 9th intercostal space. The large flaps of anterior chest and abdominal walls are retracted laterally by anchoring with towel clamps. Another extension is made to the left flank only to facilitate dissection of the left kidney. The falciform ligament is ligated and divided. The left triangular ligament of the liver is incised with electrocautery (Fig. 1). The tendinous insertion of the diaphragm overlying the suprahepatic vena cava is then incised sharply exposing the vena cava and the right and left phrenic veins, the latter being ligated and divided (Fig. 2). The anterior portion of the vena cava is then freed for a distance of about 2-3 cm exposing the superior hepatic veins (Fig. 3). The right triangular ligament of the liver is then incised and the light areola tissue is divided exposing the entire bare area of the liver. The right adrenal gland and its vein are identified. The adrenal vein is ligated and divided. The retrohepatic vena cava is then dissected free superiorly. Additional diaphragmatic insertions are divided and the posterior phrenic vein is ligated and divided. As the vena cava is further freed posteriorly the lesser sac is entered from behind the vena cava. The peritoneum of the lesser sac is then incised for the length of the retrohepatic vena cava. The peritoneum over the infrahepatic vena cava is then

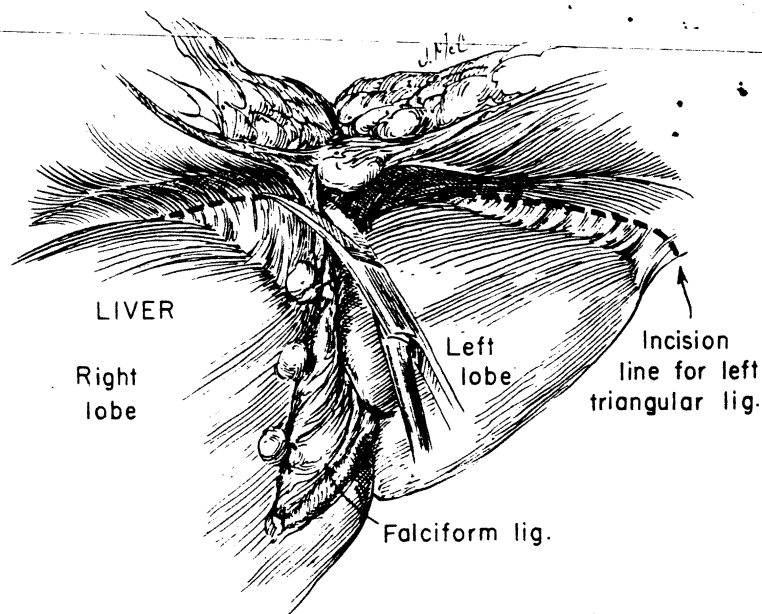


Fig. 1. Donor hepatectomy: dissection of falciform, coronary, and right triangular ligaments (from Starzl Ref. 16).

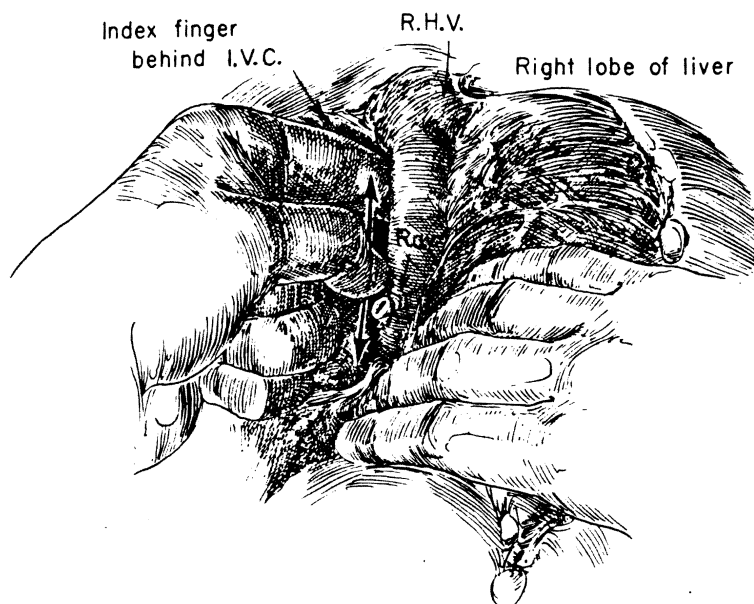


Fig. 4. Donor hepatectomy: dissection of retrohepatic vena cava (I.V.C.) after division of right triangular ligament and ligation of right adrenal vein (R.A.V.) (from Starzl Ref. 16).

incised and the dissection of the vena cava is completed to the level of the renal veins (Fig. 4). Usually only four tributaries of the vena cava must be divided: the right, left and posterior phrenic veins, and the right adrenal vein. The duodenum is then Kocherized and the peritoneum over the portal structures is divided as low as possible. The common bile duct is identified and dissected at its entrance at the pancreas preserving as much of its surrounding tissue as possible to preserve its blood supply (Fig. 5A). The common bile duct is divided and inspected to insure that it has single lumen. The gall bladder is then opened at the Fundus with an incision permitting a cholecystojejunostomy. The gall bladder is irrigated with saline to remove the bile. The portal area is then carefully inspected visually and by palpation to ascertain the presence of any vascular anomaly. Since the dissection of the remaining portal structures is carried close to the duodenum numerous small veins and arteries are encountered and must be meticulously ligated. The gastroduodenal artery is identified, ligated and divided. In dissecting the hepatic artery a plane is developed inside the dense neural sheath that surrounds it. The splenic artery is ligated and divided with care to leave a short stump, avoiding a tight ligature that may constrict the proper hepatic artery. The gastrohepatic ligament is carefully examined for an anomalous left hepatic artery. If this artery is present and of significant size, it is preserved. The left gastric artery (which supplies this anomalous left hepatic artery) then is likewise preserved when the major branches to the stomach are being divided. The celiac axis is then dissected to the aorta, ordinarily one or two small branches are encountered which are divided (Fig.

B.

after division of phren-  
Starzl Ref. 16).

the liver. After dissection is voluntarily dissected free of the abdominal cavity anterior to the splenic and superior mesenteric arteries. The spleen is removed.

The inferior vena cava and the superior mesenteric vein are cannulated with a chilled cannula. The liver is secured by dividing the abdominal wall below the celiac axis, clamping the vena cava 1½ cm and the infra-

hepatic vena cava is divided at the level of the renal veins. The perfusion of the liver is then completed *ex vivo*. The total amount of perfusion depends on the size of the liver and is done completely by gravity at 40–50 cm of water pressure. If the liver is to be transported, it is secondarily infused with 500–1000 cc of Collin's solution prior to iced storage.

#### 4.3. Multiple organ procurement

With cadaveric donors at a premium, there will be an increasing need to harvest multiple organs at one sitting. This has proved feasible and safe in the heart-beating cadaver, providing the harvesting is carried out in systematic steps.

If the heart, liver, and both kidneys are to be taken, a midline incision is made from the suprasternal notch to the pubis, splitting the sternum in the midline. As a first step, both kidneys are mobilized and the renal arteries and veins are cleaned off to their junctions with the aorta and vena cava, respectively. The kidneys are then placed back in their natural location.

Next, the liver is similarly mobilized, including dissection of the arterial blood supply back to the desired point of transection, even if this is as proximal as the celiac axis. Care must be taken not to cause hemodynamic instability when the liver is retracted for excision of the triangular and coronary ligaments and when the suprahepatic vena cava is dissected.

Finally, the preliminary dissection of the heart is performed, of which the most important part is mobilization of the ascending aorta. By this time all of the organs are ready for immediate removal.

The kidneys are removed first. Under these circumstances it is best to obtain all the length possible of the renal arteries but forego excision of an aortic patch. The renal artery and venous stumps should be ligated or sutured, leaving a blood-free operative field.

The cooling of the prepared liver can now be started by infusion with a chilled electrolyte solution into the superior mesenteric vein, leaving the rest of the portal circulation intact. After 100 or 200 ml fluid has passed into the liver the cardiac team proceeds quickly with harvesting of the heart. Undue delay could cause obstruction of the hepatic venous outflow if the suprahepatic vena cava is clamped as part of the heart removal, but if the suprahepatic clamp is not in place the cold solution could cause cardiac arrest. Consequently, the crucial step is transection of the suprahepatic vena cava which terminates the heart-beating state of the donor. The heart and liver removal teams must now work independently in completion of the respective organ removals.

The foregoing technique has been used without jeopardizing any of the four organs. The important principle is to maintain a physiologically intact donor until the last possible moment.

and divided. (B) Mobilized and dissected. (C) Portal circulation. (Ref. 16).

#### 4.4. Anatomic variations in the donor liver

The most common anomalies are of the arterial supply occurring in about 40% of the donors. In 15–20% of livers, the anomaly is surgically significant usually with the right hepatic artery arising from the superior mesenteric artery. When the need for such organs has been urgent, the right hepatic artery has been anastomosed to the splenic artery prior to homograft insertion (Fig. 6). Alternatively, the homograft superior mesenteric artery can be directly attached to any convenient recipient artery. If the entire arterial supply comes from the superior mesenteric artery, either the graft hepatic artery or the superior mesenteric artery stump can be anastomosed to the recipient hepatic artery or celiac axis.

An aberrant left lateral hepatic artery arising from the left gastric artery should be looked and palpated for when dividing the gastrohepatic ligament. When present, this vessel is preserved and the arterial anastomosis to the recipient constructed proximal to the origin of the left gastric artery.

As these and other vascular anomalies become apparent during donor hepatectomy, this information is accurately transmitted to the recipient team. Initially celiac angiography was used to evaluate the donor. This was abandoned because the delay often jeopardized the stability of the donor and the information derived was not as reliable as surgical exploration.

Anatomic variants of the biliary tree that could become obstructed are similarly of great concern. A long cystic duct parallelling the common hepatic duct was inadvertently ligated in two patients (Fig. 7). Biliary atresia was discovered in one neonatal donor.

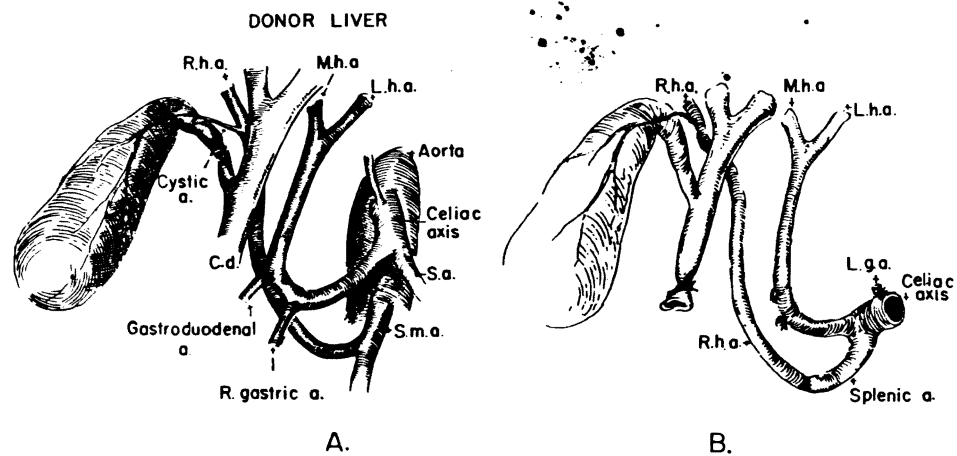


Fig. 6. A. Anomalous right hepatic artery (R.h.a.) arising from superior mesenteric artery (S.m.a.). B. Vascular reconstruction permitting anastomosis of homograft celiac axis to recipient hepatic artery. L.h.a., left hepatic artery; M.h.a., middle hepatic artery; S.a., splenic artery (from Starzl Ref. 16).

#### 4.5. Preservation

The development of liver preservation techniques has permitted the utilization of a greatly expanded donor pool. This has been most effective in increasing available pediatric donors. The technique at the University of Colorado consists of intravascular infusion of cold (4°C) Collins' solution followed by iced storage [2]. A similar technique using cold plasma protein fraction solution has been effective for preservation during transport within the United Kingdom [24]. Preservation times have been as long as 10 hours at the University of Colorado. The initial step of preservation during the completion of donor hepatectomy is flushing the liver with cold lactated Ringer's solution just prior to infusing the cold Collins' solution for storage. During subsequent graft insertion cold lactated Ringer's solution is re-infused to flush the Collins' storage solution from the graft, to maintain hypothermia during insertion of the graft, and to eliminate entrapped air.

### 5. The recipient operation

#### 5.1. Recipient hepatectomy

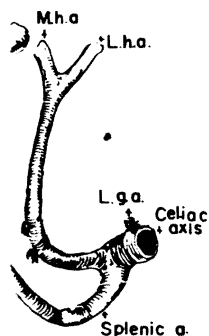
Vascular access for central venous pressure, cardiac output and peripheral arterial pressure are secured in the recipient upon arrival in the operating room, but anesthesia is usually not induced until the donor liver has been inspected and felt to be normal

in about 40% of the usually with the right the need for such proposed to the splenic homograft superior recipient artery. If the other the graft hepatosed to the recipient

ric artery should be When present, this instructed proximal

donor hepatectomy, initially celiac angio-use the delay often was not as reliable

ted are similarly of duct was inadverted in one neonatal



artery (S.m.a.). B. Vas-  
tic artery. L.h.a., left  
zl Ref. 16).

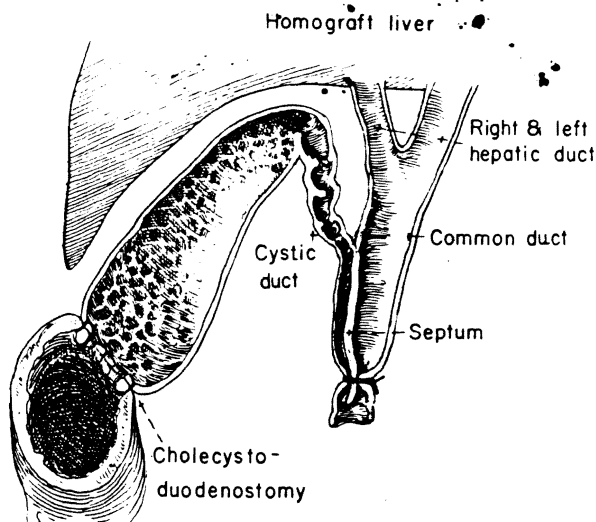


Fig. 7. Long parallel cystic duct that was inadvertently obstructed from ligation of the common bile duct (from Starzl Ref. 16).

[1]. When the donor hepatectomy is performed elsewhere, the recipient team usually waits until a telephone message from the donor team confirms the completed dissection of the donor and the arrival time of the liver in Denver. The patient is very carefully positioned for the lengthy procedure to maximize operative exposure, avoid nerve compression and increase physician comfort. A modified right anterolateral position is usually used.

A bilateral subcostal incision is placed far enough below the costal margin to avoid retraction of the incision across the costal margin when ascites is relieved (Fig. 8AA-BB). In adults, extensions are usually added, the most common of which is the vertical midline incision with excision of the xyphoid process (Fig. 8CC). This abdominal approach has provided good operative exposure in children and young adults who have flexible costal margins. For adults with narrow or rigid costal margins, a thoracic extension is made from the basic subcostal incision across the costal margin into the sixth or seventh interspace depending on the size and location of the liver (Fig. 8DD). Often a relatively recent laparotomy mandates use of a different incision, usually a midline incision through the linea alba. In these patients a right thoracic extension, often as high as the fifth interspace, is usually necessary.

Multiple previous operations on the liver or biliary tree and portal hypertension frequently make difficult even limited abdominal exploration. Initial dissection is along the inferior hepatic surface with the objective of visualizing the porta hepatis. Bleeding is difficult to control and even tiny vessels are scrupulously ligated. Electrocoagulation is used extensively on the mobilized hepatic surfaces but avoided elsewhere to minimize potential bowel injury.

• Access to the porta hepatis permits division of the hepatic blood supply in emergency situations where bleeding from the hepatic surface is excessive, but generally the portal vein and hepatic artery are preserved until shortly prior to removal of the diseased liver. The portal vein is palpated for patency, as soon as possible. Any cholangio-

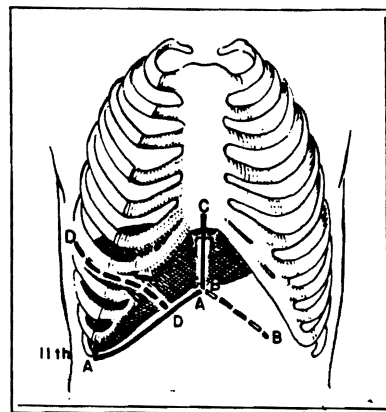


Fig. 8. Various incisions employed in hepatic transplantation (from Starzl et al. Ref. 17).

UNIVERSITY OF PENNSYLVANIA LIBRARY

recipient team usually completed dissection. Patient is very carefully exposed, avoid nerve anterolateral position

costal margin to avoid is relieved (Fig. 8AA- f which is the vertical This abdominal ap- ung adults who have margins, a thoracic costal margin into the the liver (Fig. 8DD). it incision, usually a t thoracic extension,

tal hypertension fre- al dissection is along rta hepatis. Bleeding l. Electrocoagulation d elsewhere to mini-

ood supply in emer- ve, but generally the removal of the dis- ble. Any cholangio-

digestive anastomoses are taken down. If present, the cystic duct is divided to allow hilar dissection to be performed superiorly. The common hepatic duct is dissected to its bifurcation and divided at this point. If it has not been done preoperatively, the distal common hepatic duct is probed to assess patency and the divided duct inspected for adequate bleeding. Division of the hepatic duct permits better exposure of the portal vein which is circumferentially dissected to and including its bifurcation where it will be divided later. The hepatic artery is extensively mobilized. The proper hepatic artery is dissected to its bifurcation where it is later divided. Dissection proceeds proximally until the origin of the gastroduodenal artery is identified. The gastroduodenal artery is dissected but not divided. A right hepatic artery arising from the superior mesenteric artery is almost always located directly posterior to the portal vein. Such a vessel is not extensively dissected since it has not been used for later hepatic artery revascularization. If this vessel is the sole arterial supply to the liver, it may be used and should be carefully dissected. The remainder of hepaticoduodenal ligament is ligated in small bites and divided. The portal lymph nodes can be a source of troublesome bleeding.

Much of the remainder of the recipient hepatectomy resembles that taking place in the donor room. The infrahepatic vena cava is circumferentially dissected superior to the renal veins. After dividing the right triangular and coronary ligaments the bare area is entered and the right adrenal vein is ligated and divided at its junction with the inferior vena cava. Sometimes the most inferior hepatic vein can be ligated and divided to provide maximum length at the infrahepatic cava. The falciform and left triangular ligaments are divided in small bites between ties. The remainder of the retroperitoneum is dissected from the retrohepatic vena cava on the left and the liver is ready to remove.

When the donor liver arrives, the recipient's portal vessels are clamped and divided at their bifurcations. Vascular clamps are placed across the suprahepatic and infrahepatic vena cava, a step closely coordinated with the anesthesiologist. A convenient and sometimes crucial way to develop a suprahepatic cuff is to obtain extra length within the parenchyma of the split, diseased liver [19] (Fig. 9). Open hepatic veins and other defects created by this maneuver are closed with a fine vascular suture. After liver removal, the area is checked for major bleeding before inserting the graft.

### 5.2. Orthotopic hepatic homograft insertion

Insertion of the homograft begins with anastomosis of the suprahepatic vena cava. Because of the bulk of the graft, exposure may be difficult. The anastomosis is made with a single layer running suture technique [15]. The posterior wall suture line is placed intraluminally with particular care because later reinforcement is difficult due to the limited exposure.

The cold perfusion is slowed somewhat as the egress of entrapped bubbles decreases, and the lower caval anastomosis is completed with a technique similar to that used

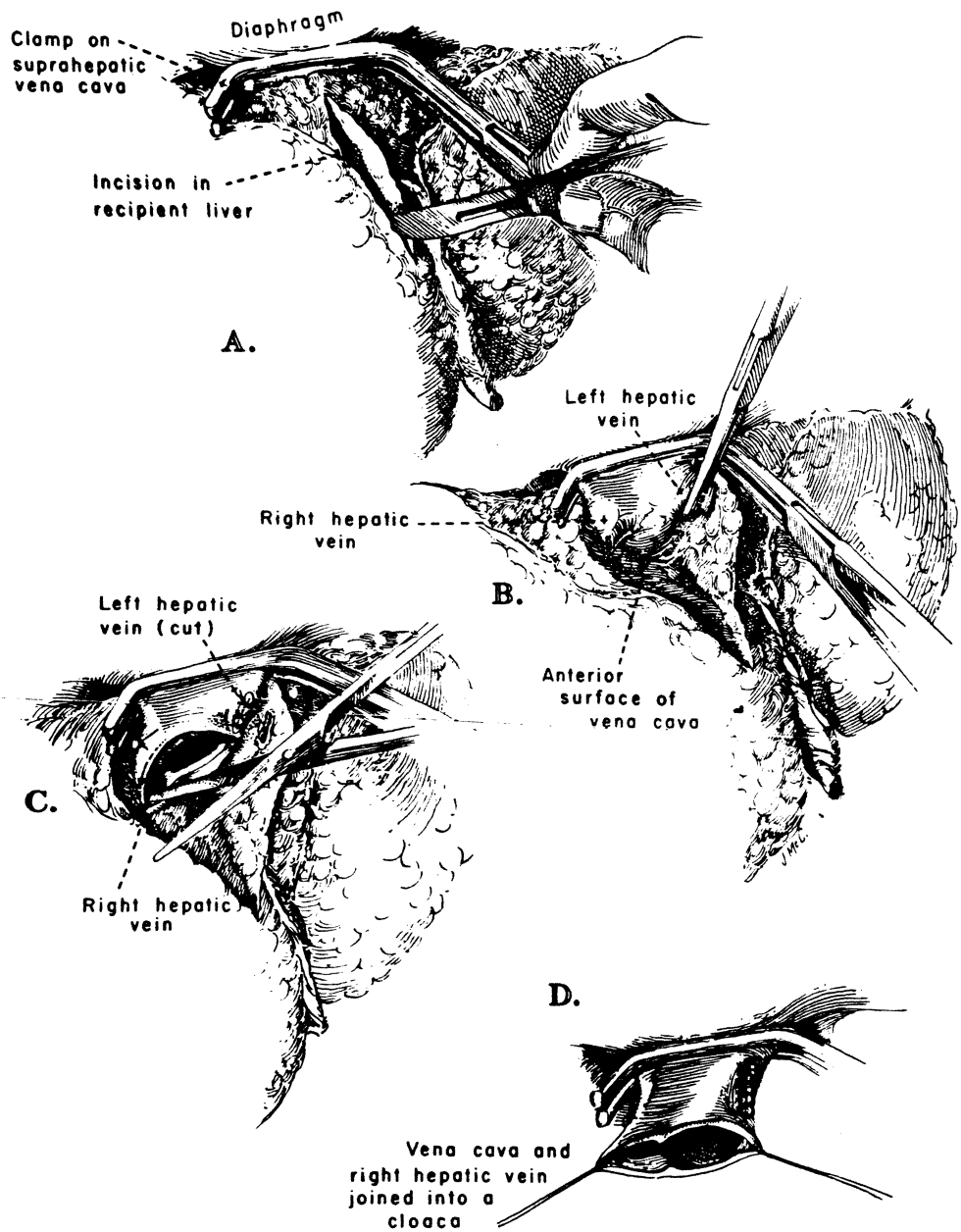


Fig. 9. Development of suprahepatic vena cava cuff. (A) Division of liver following clamping vena cava. (B) Division of hepatic veins from anterior approach. (C) Division of suprahepatic vena cava actually in intrahepatic portion. (D) Closure of hepatic veins (From Starzl et al. Ref. 19).



for the suprahepatic caval anastomosis. Just prior to completion of the anastomosis the perfusion is increased and all remaining air is forced from the hepatic veins and cava. Air embolism has been avoided with this technique [11].

With the liver in its natural position, perfusion is terminated and the graft portal vein is trimmed and if more shortening is required the recipient portal vein is also cut. Excessive length promotes kinking and subsequent thrombosis. Proper length is particularly important where the graft is larger than the diseased liver it is replacing. The anastomosis is end-to-end using the running, everting technique described earlier. Suture material is 6-0 braided which minimizes pursestringing. Any flaws or pursestringing effect require that the anastomosis be redone.

If portal hypertension is troublesome or if caval return is needed, the portal and caval clamps can be removed at this time, partially revascularizing the liver. Alternatively, the hepatic arterial anastomosis may be completed prior to declamping. The arterial anastomosis can be at any point on the hepatic artery, to and including the celiac trunk. The recipient hepatic artery is trimmed proximally to where it will provide a comfortable end-to-end anastomosis to the graft artery. This is usually the junction of the proper hepatic and gastroduodenal arteries. Arterial anastomoses usually have been made with 7-0 suture. Optical loops often are used for magnification at this point especially in pediatric patients. In declamping, vascular input is restored first, hepatic outflow is released only after the organ contains blood. The liver should assume a normal color and turgor within 5 min and evidence of clotting should be apparent in the wound within 15 min.

As soon as the portal pressure has decreased and coagulation has improved, splenectomy is considered. Splenectomy is performed earlier during hepatectomy only when there is marked splenomegaly and when difficulty achieving a comfortable homograft fit is anticipated.

When hemostasis is adequate, biliary drainage is established. Choledochocholedochostomy is preferred where appropriate. The homograft common bile duct is trimmed back until bleeding from the cut end is encountered. This point has usually been in the graft common bile duct. The recipient common hepatic duct which has been preserved, allows generous length for anastomosis. A late follow-up endoscopic retrograde cholangiogram demonstrates a considerable distance between the two remaining cystic duct stumps (Fig. 10). A T-tube is placed in the recipient common hepatic duct, usually with the long arm exiting out the recipient cystic duct. The proximal limb extends across the anastomosis into the graft common bile duct. The anastomosis is end-to-end without any beveling of the duct ends. A synthetic, absorbable, 5-0 suture has been preferred. Finally, the homograft gallbladder is removed and its cystic duct ligated (Fig. 11).

When the recipient choledochus is unacceptable, Roux-en-Y cholecystojejunostomy is preferred because of its simplicity. A long Roux-en-Y limb is constructed, or a previously constructed limb is utilized if it is of adequate length and can be mobilized adequately to avoid tension on the anastomosis. The jejunal limb is usually placed



g clamping vena cava.  
ava actually in intrahe-  
19).

UNIVERSITY OF PITTSBURGH  
PITTSBURGH, PENNSYLVANIA 15260



Fig. 10. Endoscopic retrograde cholangiopancreatography demonstrating two cystic ducts (solid arrows) separated by approximately 2 cm. Considerable redundancy is accepted to avoid tension if vascularity is adequate.

antecolic and anastomosed inferiorly to the fundus of the gallbladder using a double layer gastrointestinal anastomosis (Fig. 12B). The distal common bile duct is ligated. If the patency of the cystic duct is suspect for any reason, a choledochojejunostomy is utilized and the gallbladder removed. This anastomosis is double-layered over a stent which exits from the Roux-en-Y limb (Fig. 12C).

The wound is closed with interrupted, non-absorbable sutures in layers. Soft latex drains are placed near the anastomosis when choledochocholedochostomy or choledochojejunostomy are used but no drainage is provided for a cholecystojejunostomy.

## 6. Postoperative management

Upon leaving the operating room the patient is placed in an intensive care area. Facilities for monitoring and close observation are provided. A transplant surgeon is available in the unit until the patient is clearly stable. Postoperative orders are simple and are revised frequently as the patient improves (Table 2).

### 6.1. Hemorrhage

The patient remains in the operating room until hemostasis is achieved. Occasionally a damaged homograft thwarts all attempts to control bleeding due to defective clot-

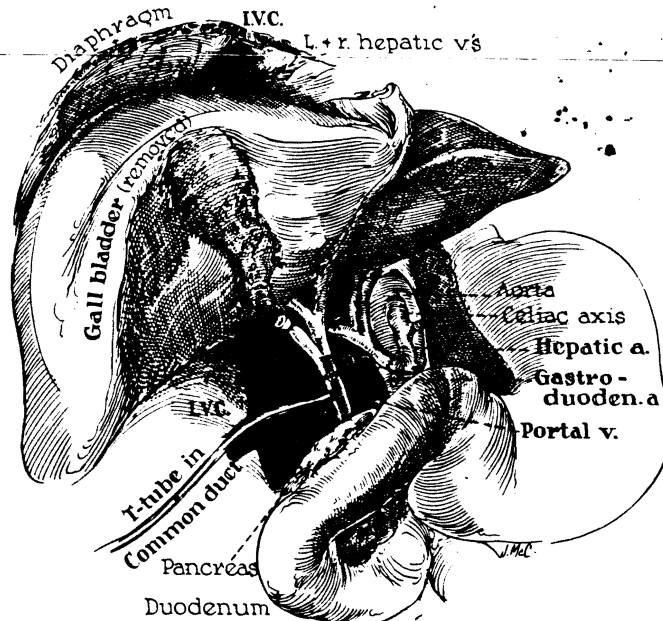


Fig. 11. Preferred biliary reconstruction. The proximal arm of the T-tube steps the choledochocholedochostomy (from Starzl Ref. 16).

ting. In this situation, if careful evaluation reveals all anastomoses to be patent and secure, the wound is closed and the recipient returned to the intensive care area. Here supportive care is given until the liver can recover. Blood is replaced as lost. Clotting can be depressed from loss of platelets and other clotting factors by dilution from bleeding, by consumption within a damaged homograft, or by intravascular consumption from unrecognized infection. Because, frequently, two or more factors are involved,

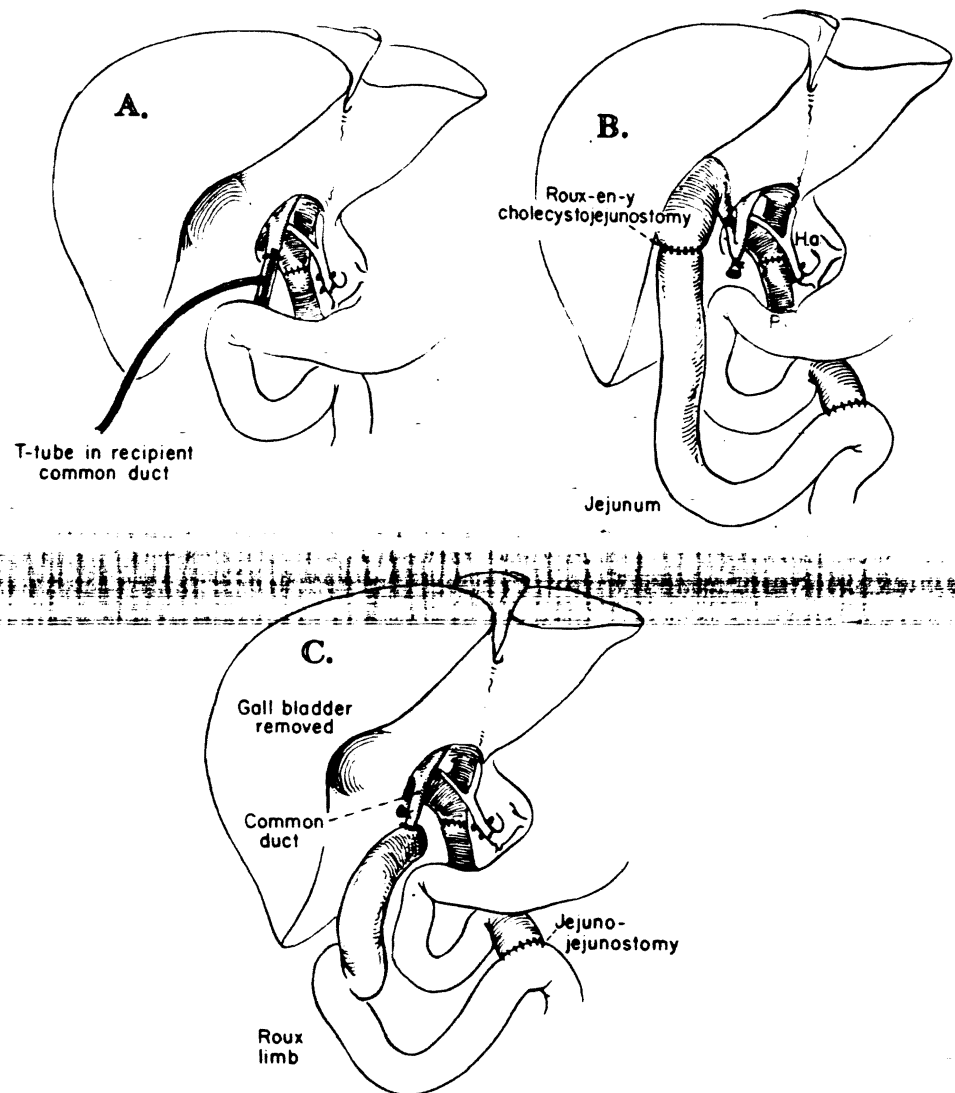


Fig. 12. Methods of biliary tract reconstruction. A. Preferred choledochocholedochostomy. B. Roux-en-Y cholecystojejunostomy, when the recipient common bile duct is diseased. C. Roux-en-Y choledochojejunostomy, when the recipient common bile duct is diseased and the homograft cystic duct is suspect (from Starzl et al. Ref. 20).

60–80 ml/kg of maintenance fluids in children and 2500–3000 ml/day in adults in the immediate postoperative phase. These requirements decrease during the recovery period. Vascular volume is continually re-evaluated and fluids are adjusted accordingly. Intravascular volume is estimated from peripheral arterial pressure, right and left atrial pressures, urinary output and daily weight.

Serum electrolytes are evaluated every 6 h for the first few days. Two features have been frequently found. First large quantities of intravenous potassium are required to maintain adequate serum levels. This probably reflects total body potassium depletion existing prior to surgery as well as potassium flux within the homograft. Urinary loss of potassium is not excessive. Secondly, a rather severe metabolic alkalosis frequently occurs with a well-functioning graft despite potassium replacement. Respirator adjustment can provide some compensatory respiratory acidosis but occasionally additional 0.1 N.HCl is administered. Glucose is administered as 10% dextrose but this concentration is usually reduced to 5% dextrose as the serum glucose climbs shortly after transplantation.

### *6.3. Antibiotics*

Barring allergies, an aminoglycoside and a cephalosporin antibiotic are each administered immediately preoperatively and continued at appropriate intervals for 72 h postoperatively. The cephalosporin or methicillin have been continued longer since the addition of thoracic duct drainage to the immunosuppressive regimen in order to prevent thoracic duct infections. Cultures are frequently taken but antibiotics are administered with some restraint. Opportunistic bacterial and fungal infections are still a threat especially in the patient with a compromised homograft [13].

### *6.4. Respiratory support*

Ventilatory support is provided until the patient is alert and fully capable of handling all respiratory needs. Generally, children can be extubated within a few hours, while adults frequently require about 12 h before extubation. When coma preceded surgery or when the homograft has been compromised longer support is necessary. Analgesics depressing respiration are reduced long before extubation.

Following extubation frequent encouragement to cough, postural drainage, and incentive spirometry are all employed. Both flexible and rigid bronchoscopy are used when the pulmonary toilet is inadequate. Every effort is made to extubate the patient and avoid tracheostomy even if later reintubation becomes necessary. Longer periods of respiratory depression have been encountered when there has been phrenic nerve injury either from high placement of suprahepatic caval clamps or from partial excision of the diaphragm. A large homograft resulting in abdominal distention may also compromise respiration.

### 6.5. Nutrition

Dietary restriction, particularly of protein, is almost invariable in the preoperative period. Additional demands from frequent infections, increased cardiac output, and stress produce a severely catabolic patient. Wounds heal slowly and incisional hernias are not uncommon. Skin breakdown can occur very easily. Nutrition is imperative as soon as the liver homograft appears capable of handling the protein load. In those patients without intestinal anastomoses and in children, an oral diet of negligible protein is begun on the third to fifth postoperative day. Protein is rapidly increased. Multivitamins are given intravenously.

Intravenous hyperalimentation is usually begun early on those patients recovering slowly or with intestinal anastomoses in whom feeding is delayed. The hyperalimentation is maintained until a good oral intake is documented. The liver is examined daily. Increasing liver size, especially if accompanied by rising enzymes, warrants decreasing the glucose administered. If hepatic deterioration continues, the liver is biopsied and hyperalimentation interrupted.

### 6.6. Immunosuppression

Immunosuppression begins during surgery when one gram of methylprednisolone is given shortly prior to declamping. For the 24 h following surgery, 50 mg of methylprednisolone is given intravenously every 6 h. Each successive day the total daily amount is reduced by 10 mg. The steroid dosage is reduced to around 30 mg daily by discharge and over the ensuing years is reduced further. All patients remain on some daily steroids. Children are begun on 6–7 mg/kg daily, which is similarly gradually reduced.

Azathioprine is begun immediately following transplantation with 1.5–2 mg/kg daily. The daily dosage is increased or decreased dependent on the degree of circulating leukocyte depression. This is continued for life. The most recent trial of antithymocyte globulin has been completed and has not been replaced.

Lymphocyte depletion by thoracic duct drainage has been added as a third modality of immunosuppression. The thoracic duct fistula is being started one month prior to transplantation. Drainage is discontinued at about one month following transplantation and reliance for immunosuppression then resides with azathioprine and with gradually decreasing steroids.

Cyclophosphamide is rarely used. When biopsy and cholangiography confirm intrahepatic cholestasis, azathioprine will sometimes be discontinued and cyclophosphamide at approximately the same dosage begun. If the intrahepatic cholestasis does not readily resolve, cyclophosphamide is discontinued and azathioprine resumed.

The diagnosis of rejection remains elusive. A review of clinical material in 1975 suggested overuse of this diagnosis. Patients were being treated for rejection and dying of infection. Microscopically rejection was, and remains, difficult to establish. It was

suspected that the treated patients that died had resolving rejection. An aggressive diagnostic approach was adopted and since 1976 multiple biopsies are taken during and after suspected rejection episodes. Treatment is occasionally withheld until after several biopsies have established a trend. Cholangiography, both retrograde and percutaneous, is routine. The slightest delay in the flow of contrast is interpreted as partial obstruction.

The frequent biopsy schedule has been both helpful and disappointing. Disappointment stems from occasional conflict between the clinical and microscopic pictures. Biliary obstruction, intrahepatic cholestasis, and rejection remain difficult to separate. Serial biopsies have helped in the diagnosis of rejection and have further defined the response to increased steroids. Serial biopsy evidence of response to a therapeutic trial of increased steroids has been very suggestive of rejection. Of those 26 patients transplanted since January, 1978, clinical and microscopic agreement of rejection has occurred on 11 occasions. Four patients have died as a direct result of rejection.

Several patients have experienced chronic rejection unresponsive to steroids. Thorough investigation including revision of biliary drainage has only confirmed the pathologic picture of chronic rejection. Persistently elevated serum bilirubin and, frequently, small hepatic infarcts are seen.

#### 6.7. Biliary obstruction

Serum levels of bilirubin, transaminases, and alkaline phosphate are closely followed. At the first suggestion of deteriorating liver function, further investigation is begun.



Fig. 13. Hepatobiliary radiopharmaceutical scan. Normal postoperative liver transplant. (A) Fifteen minutes following injection gallbladder visualized. (B) One hour later flow is demonstrated from gallbladder into Roux-en-Y jejunal limb.

on. An aggressive  
are taken during  
withheld until after  
etrograde and per-  
erpreted as partial

ating. Disappoint-  
oscopic pictures.  
difficult to separate.  
urther defined the  
a therapeutic trial  
26 patients trans-  
rejection has oc-  
ejection.

to steroids. Thor-  
firmed the patho-  
and, frequently,

closely followed.  
igation is begun.



Fig. 14. E.R.C.P. with angulation of the common bile duct at the previous T-Tube exit site (arrow). No evidence of stenosis has developed at the site of angulation over 2 years.

A Fifteen minutes  
from gallbladder into



When biliary stents are in and functioning, a tube cholangiogram is performed. Tube cholangiograms have not revealed extrahepatic obstruction in any situation where they clinically appeared to be draining well. When dislodged from their functional position as demonstrated by cholangiography, they become potentially obstructive and have been removed.

When hepatic dysfunction arises after the removal of the biliary stent or when a stent was not used, a liver scan is performed. The more recently developed hepatobiliary radiopharmaceuticals have been extensively used for routine follow-up screening and

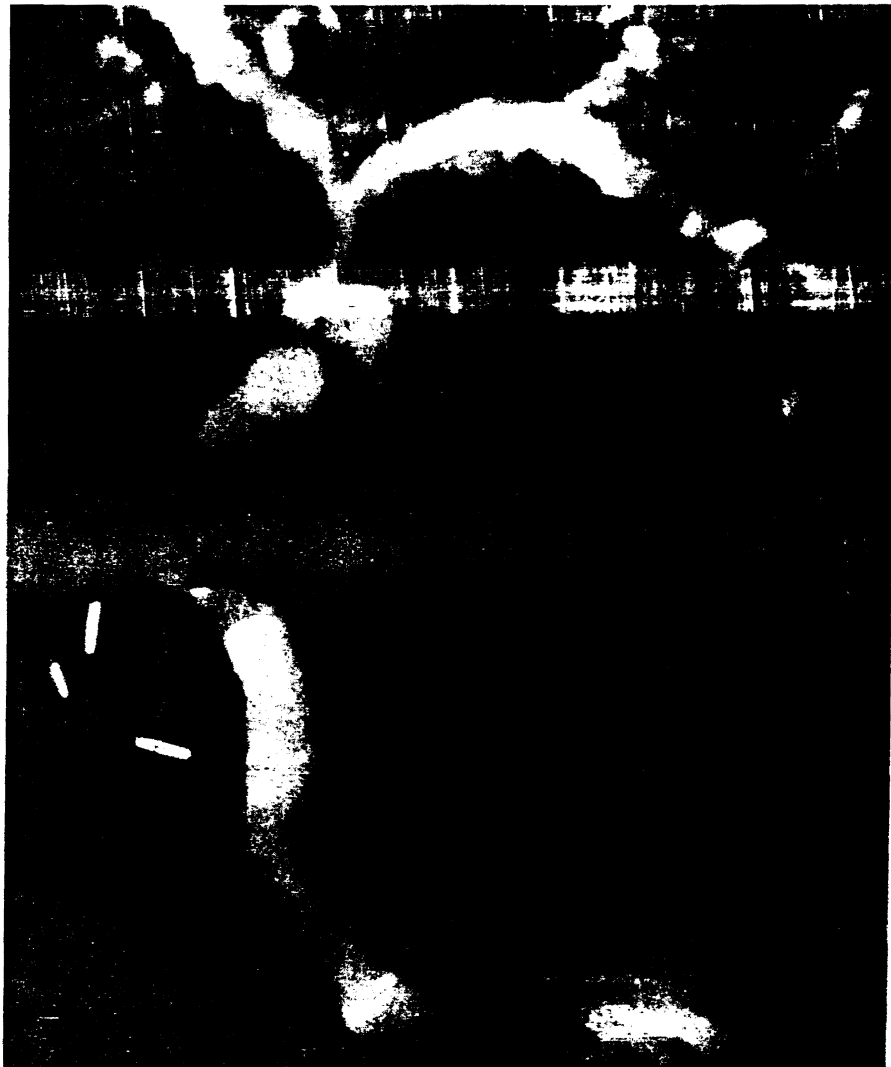


Fig. 15. E.R.C.P. demonstrates stricturing of common bile duct at anastomosis. Proximal dilatation has not yet developed.

performed. Tube  
 situation where  
 their functional po-  
 v obstructive and

nt or when a stent  
 for hepatobiliary  
 -up screening and



mal dilatation has not

have been helpful in distinguishing obstruction from hepatocellular dysfunction [8] (Fig. 13).

If the liver scan suggests partial obstruction or liver dysfunction persists more than a few days, a cholangiogram is performed. In patients with choledochostomies, endoscopic retrograde cholangiography (ERCP) has been most reliable. In the asymptomatic patient, the common bile duct frequently appears angulated at the exit site of the T-tube and the sinus tract of the T-tube may remain patent for several months (Fig. 14). Strictureing of the duct can be detected early before dilatation of the proximal bile ducts occurs (Fig. 15). If hepatic dysfunction occurs, biliary tract reconstruction is warranted despite the absence of dilated intrahepatic bile ducts. Recurrence of a bile duct carcinoma was responsible for one bile duct stricture with a spontaneous choledochoduodenal fistula (Fig. 16).

In those patients with a cholangiojejunal anastomosis, transhepatic cholangiography has been used. Dilated intrahepatic ducts, an aid in transhepatic cholangiography and common feature of biliary obstruction, often are absent. Careful fluoroscopy and multiple spot radiographs are necessary to detect small pieces of debris in the biliary tract or even a delay in the flow of contrast. These findings have been indicative of partial biliary obstruction. In patients with a cholecystojejunostomy the usual finding in partial obstruction is delayed flow at the cystic duct (Fig. 17). Approximately 30%

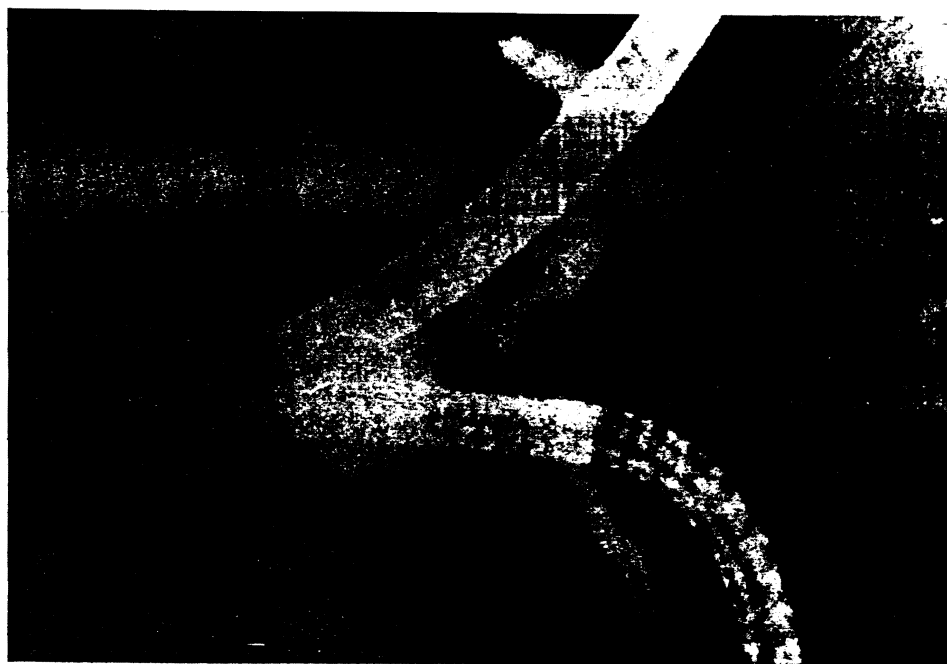

Fig. 16. E.R.C.P. with stricturing at distal common bile duct (arrow) and a proximal spontaneous choledochoduodenal fistula. Etiology of stricture was recurrent bile duct carcinoma.

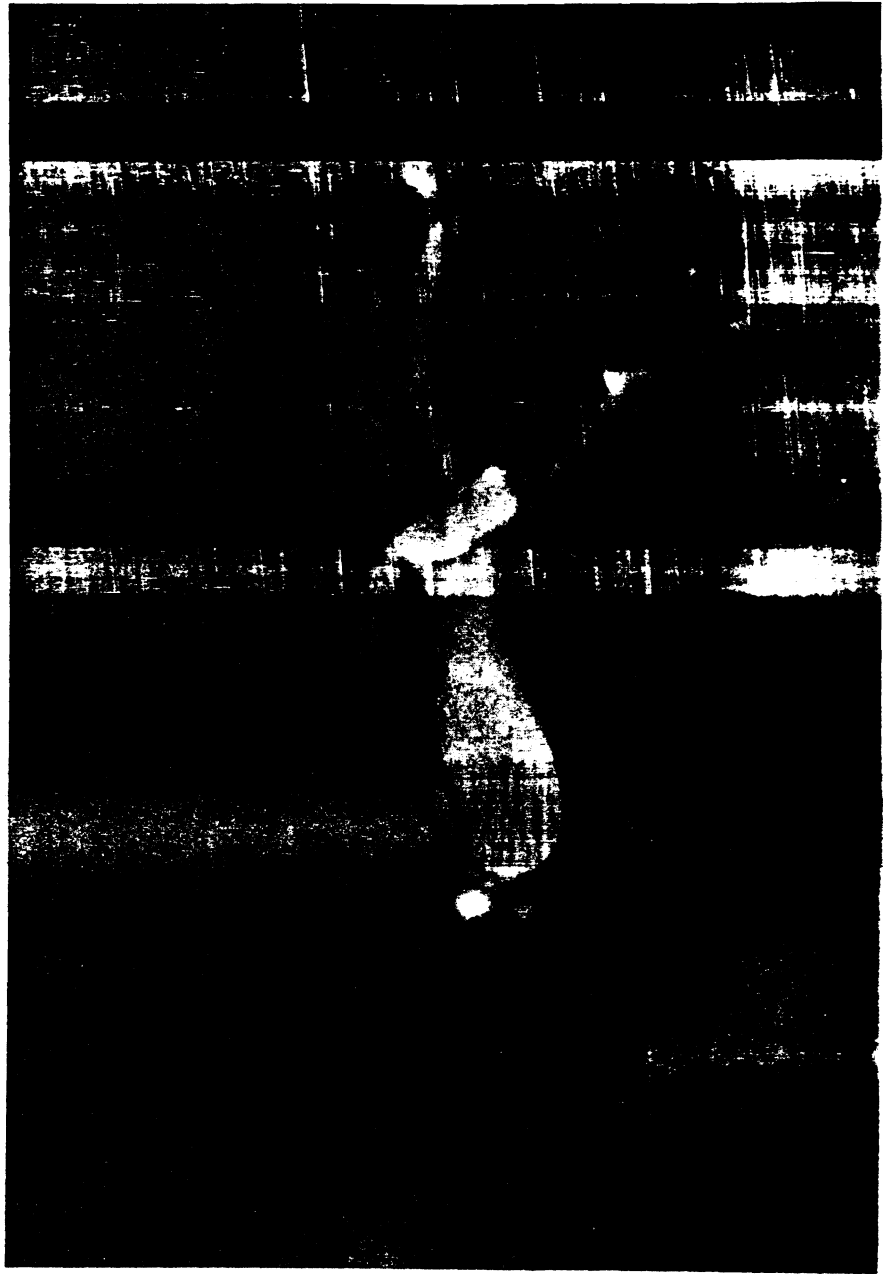

Fig. 17. Transhepatic cholangiogram demonstrated a delay in flow of contrast through the cystic duct (open arrow). The extravasation of contrast from the ligated common bile duct stump (solid arrow) also suggests a partial biliary obstruction at the cystic duct.

of patients with this method of biliary drainage have become partially obstructed at the cystic duct necessitating operative revision to choledochojejunostomy. The actual site of anastomosis at the cholecystojejunostomy has not been a site of obstruction.

The majority of patients with choledochojejunostomies were converted from a previous cholecystojejunostomy after cystic duct obstruction. If liver dysfunction does not improve after conversion to choledochojejunostomy or arises later, transhepatic cholangiography is indicated. However, most of these patients with persisting jaundice after biliary revision have shown the choledochojejunostomy to be patent with no delay in transit of contrast (Fig. 18). Nevertheless, the emphasis remains on revising the biliary tract unless some other clearly identifiable cause can be implicated as the source of hepatic dysfunction.

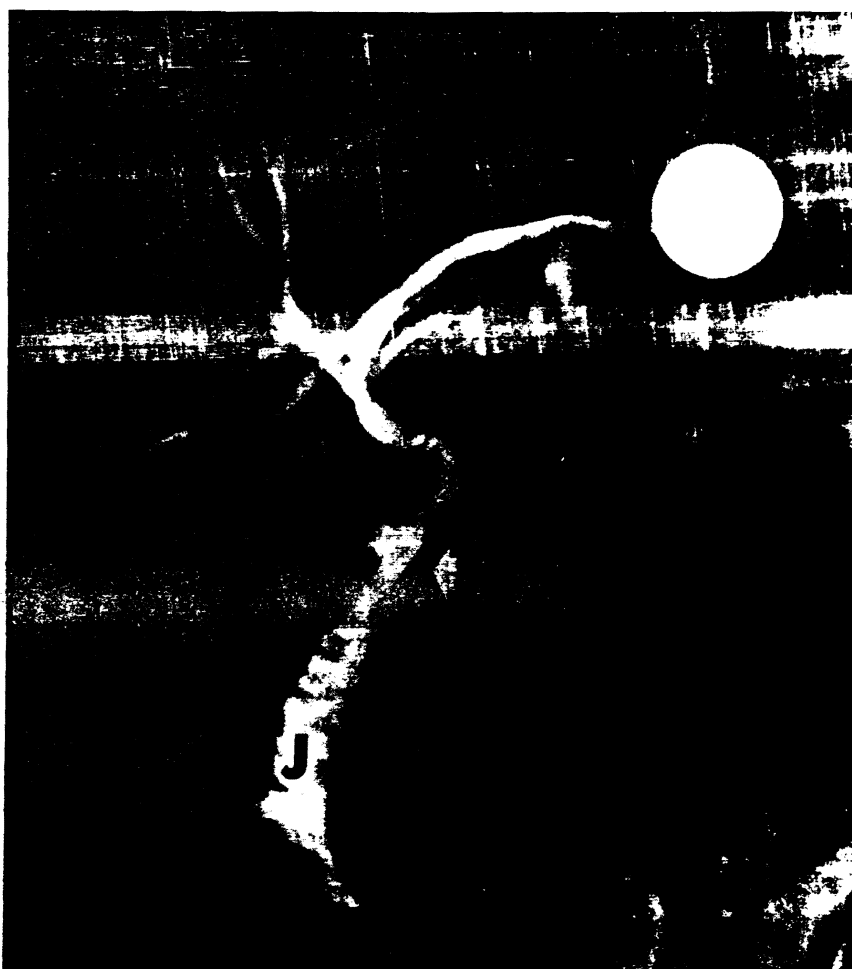

Fig. 18. Transhepatic cholangiogram with no obstruction follow-in conversion of this patient's cholecystojejunostomy into a choledochojejunostomy because of cystic duct obstruction. Arrow, anastomosis; J, jejunum; white circle, Roux-en-Y (from Starzl et al. Ref. 22).

cystic duct (open  
arrow) also suggests

16. Starzl, T.E. & Putnam, C.W.: *Experience in Hepatic Transplantation* (Philadelphia: W.B. Saunders Co., 1969).
17. Starzl, T.E., Porter, K.A., Putnam, C.W., Schröter, G.P.J., Halgrimson, C.G., Weil, R. III, Hoelscher, M. & Reid, H.A.S.: Orthotopic liver transplantation in ninety-three patients. *Surg. Gynecol. Obstet.* 142:487, 1976.
18. Starzl, T.E., Koep, L.J., Schröter, G.P.J., Hood, J., Halgrimson, C.G., Porter, K.A. & Weil, R. III: The quality of life after liver transplantation. *Transplant. Proc.* 11:252, 1979.
19. Starzl, T.E., Koep, L.K., Weil, R. III & Halgrimson, C.G.: Development of a suprahepatic recipient venacaval anastomosis for liver transplantation. *Surg. Gynecol. Obstet.* 149:76, 1979.
20. Starzl, T.E., Koep, L.J., Halgrimson, C.G., Hood, J., Schröter, G.P.J., Porter, K.A. & Weil, R. III: Liver transplantation, 1978. *Transplant. Proc.* 11:240, 1979.
21. Starzl, T.E., Koep, L.J., Schröter, G.P.J., Porter, K.A. & Weil, R. III: Liver replacement for pediatric patients. *Pediatrics* 63:825, 1979.
22. Starzl, T.E., Koep, L.J., Halgrimson, C.G., Hood, J., Schröter, G.P.J., Porter, K.A. & Weil, R. III: Fifteen years of clinical liver transplantation. *Gastroenterology* 77:375, 1979.
23. Terblanche, J.: Is Carcinoma of the main hepatic duct junction an indication for liver transplantation or palliative surgery? A Plea for the U-tube palliative procedure. *Surgery* 79:127, 1976.
24. Wall, W.J., Calne, R.Y., Herbertson, B.M., Baker, P.G., Smith, D.P., Underwood, J., Kostakis, A. & Williams, R.: Simple hypothermic preservation for transporting human livers long distances for transplantation. *Transplantation* 23:210, 1977.
25. Wells, M., Koep, L.J. & Shikes, R.H.: Hepatoblastoma in a child with alpha-1-antitrypsin deficiency. *Pediatrics*.
26. Williams, J., Shilling, M., Shikha, K.B., Herbertson, B., Jaysey, B. & Calne, R.Y.: Liver transplantation in man; the frequency of rejection, biliary tract complications and recurrence of malignancy based on an analysis of 26 cases. *Gastroenterology* 64:1026, 1973.