

0080 518

Chapter 50

LIVER TRANS- PLANTATION

Laurence J. Koep, M.D.,
and Thomas E. Starzl, M.D.

Experience in human hepatic transplantation began in March 1963, at the University of Colorado. A child, dying of biliary atresia, survived only a few hours after receiving the first orthotopic liver transplant. By September 1980, 184 patients had been transplanted in this program and 16 had been transplanted twice. The final patient, also a child with biliary atresia, is now alive and well. The total experience with hepatic transplantation now consists of over 300 patients worldwide. The second largest series of patients has been reported from the Cambridge-King's College Hospital, London (Calne and Williams, 1979).

The initial successes were few, and it was not until 1967 that the first liver transplant that would survive for a year was performed. These early cases have been thoroughly reviewed in an earlier monograph on this subject (Starzl, 1969). Patient survival gradually improved until in 1979 a series of 30 patients with 1 year survival of 50 per cent was reported (Starzl, 1979). Finally, those patients most recently transplanted will probably exceed 75 per cent 1 year survival.

This period of development at the University of Colorado produced techniques compatible with prolonged patient survival. Both the University of Colorado and Cambridge-King's College centers have enjoyed the greatest success with the orthotopic hepatic transplant. Both the operative indication of irreversible hepatic failure and the possible competition for vital hepatotropic factors necessitate the removal of the native liver. Transplantation of the liver homograft to the original upper abdominal, or orthotopic, site is thus favored.

Auxiliary transplantation or preservation of the diseased liver with transplantation of the homograft liver into a heterotopic site, usually the lower abdomen or iliac fossa, is advantageous when eventual recovery of the native liver is anticipated. The relatively brief period between diagnosis and death in acute liver failure has precluded extensive use of auxiliary hepatic transplantation. The longest survivor of an auxiliary transplant actually suffered from chronic disease. Following the transplant there was continued deterioration of his native liver with eventual assumption of all hepatic function by the auxiliary homograft (Fortner et al., 1979). The overwhelming preponderance of orthotopic transplants, however, reflects the current consensus of restriction of auxiliary transplantations to severe acute hepatic failure with a potential for eventual recovery.

INDICATIONS FOR HEPATIC TRANSPLANTATION

Hepatic transplantation is extraordinary therapy for progressive liver disease that is unresponsive to conventional therapy. Terminal hepatic failure should be anticipated within 1 year. Accelerated deterioration of progressive liver disease is usually the best indication of impending hepatic failure. The decision to utilize transplantation in hepatic failure should be resolved before multi-organ failure intervenes. The patient must be able to withstand the rigors of a long and arduous operation. For this reason, disease should be confined to the hepatobiliary

CULATURE
: Budd-Chass
rior vena cava
l: The Budd
epatic scintig
d pathological
enous outflow
375.
the anatomy,
e vascular sy
Royal College

Table 50-1. Indications for Orthotopic Hepatic Transplantation at University of Colorado, March 1963 through September 1980—Adults 19 to 68 years

Diagnosis	Number of Patients
Chronic active hepatitis	36
Laennec's cirrhosis	16
Primary hepatic malignancy	15
Primary biliary cirrhosis	9
Sclerosing cholangitis	8
Budd-Chiari syndrome	4
Secondary biliary cirrhosis	3
Inborn errors of metabolism	
Alpha ₁ -antitrypsin deficiency (2)	
Protoporphyrin (1)	3
Biliary hypoplasia	<u>2</u>
Total	96

system where immediate improvement would result from transplantation. Systemic infection and hypotension requiring ionotropic support have most often precluded transplantation. Hepatic encephalopathy, even coma, and the hepatorenal syndrome have not precluded transplantation, as these have resolved promptly following surgery. Usually the most difficult decision is not which patients are candidates for liver transplantation, but, rather, when is the proper time. As results have improved, earlier surgery has further decreased the operative risk.

Slightly over half of the patients transplanted have been adults. The majority of these patients were transplanted for chronic active hepatitis, Laennec's cirrhosis, or primary hepatic malignancy (Table 50-1). More recently, primary biliary cirrhosis, sclerosing cholangitis, and the Budd-Chiari syndrome have offered promising results.

Chronic Active Hepatitis

Chronic active hepatitis has been the most common operative indication in adults and older children. The timing of transplantation is difficult. The onset of the disease is often very difficult to date. Furthermore, determining the activity of the disease may be difficult because of biopsy sampling error or of the hazards of repeated liver biopsy. The clinical course is the best indicator. As episodes of encephalopathy become more frequent and the stimulus initiating encephalopathy becomes more subtle,

transplantation is appropriate. A debilitated patient with only intervals at home and whose diet is severely protein restricted succeeds only in increasing the hazards of transplantation.

Laboratory studies are of limited value. Hepatobiliary nuclear scans can give an estimate of hepatocyte function and may reveal a hepatoma as the etiology of recent deterioration. Similarly, depressed albumin synthesis and a prolonged prothrombin time that is unresponsive to phytonadione indicate hepatocyte loss. Bilirubin, transaminase, and ammonia levels have been too inconsistent in chronic disease to be of significant value.

The presence of hepatitis B surface antigen (HB_sAg) may impose some added risk following transplantation. HB_sAg positive patients have routinely remained positive for the antigen. Two HB_sAg positive patients were treated with hyperimmune globulin before, during, and following liver transplantation. Both of these patients again became antigen positive, with one dying of progressive hepatic failure in less than 1 year. Other transplant patients have tolerated the chronic antigenemia very well. Thus, chronic active hepatitis, both antigen positive and antigen negative, remains a favored indication for hepatic transplantation.

Laennec's Cirrhosis

By simple patient volume, alcoholic cirrhosis could easily overwhelm any liver transplant effort. Despite large numbers, patient selection is very difficult. Two features account for the difficulty. First, abstinence will eliminate any progression of the disease. Second, acute alcoholic hepatitis will show at least partial recovery. These features necessitate support and observation to insure recovery from any acute alcoholic component, then demonstration of inadequate hepatic reserve in the abstinent state. Nutrition is usually nonexistent in these patients.

Four alcoholics have survived over a year following liver transplantation. Two have stopped drinking and are doing very well. One man demonstrates marked transaminase elevation during binge drinking. His liver biopsy reveals cirrhosis developing in his homograft. The other alcoholic moderates his alcohol consumption with street drugs. His liver biopsy remains healthy.

Cirrhosis Arising from the Biliary Tract

Primary biliary cirrhosis, secondary biliary cirrhosis, and sclerosing cholangitis tend to be slowly but predictably progressive. Encephalopathy is unusual, but pruritus can be excruciating. Prolonged invalidism and constant pruritus drive these patients to transplantation. In primary biliary cirrhosis, the patients tend to be older but the surgery easier. In secondary biliary cirrhosis and sclerosing cholangitis, the patients are younger, but multiple previous surgical attacks on the biliary tract make the hepatectomy treacherous.

Budd-Chiari Syndrome

Four patients have been transplanted for the Budd-Chiari syndrome. All are alive and well at this time. The rapidly progressive course of this disease frequently produces hepatic failure, while nutrition and other systems are only modestly impaired. One of these women has even had a child following her liver transplant.

Slightly less than half of the orthotopic liver transplants performed at the University of Colorado have been in pediatric patients of age 18 or younger. The vast majority of these patients were young children with biliary atresia (Table 50-2). Chronic active hepatitis was more common in older children. Recently, an increasing number of children are being transplanted for inborn errors of metabolism.

Table 50-2. Indications for Orthotopic Hepatic Transplantation at University of Colorado, March 1963 through September 1980—Children \leq 18 years

Diagnosis	Number of Patients
Biliary atresia	53
Chronic active hepatitis	13
Inborn errors of metabolism	
Alpha ₁ -antitrypsin deficiency (8)	
Wilson's disease (2)	
Tyrosinemia (1)	
Glycogen storage disease IV (1)	12
Primary hepatic malignancy	4
Neonatal hepatitis	2
Congenital biliary cirrhosis	2
Secondary biliary cirrhosis	1
Intrahepatic cholestasis	1
Total	88

Biliary Atresia

Fifty-three children were transplanted for biliary atresia. Jaundice appearing early in life from biliary atresia, and not treated by portoenterostomy, has an early fatal outcome, and these children are obvious transplant candidates. Those children receiving an early portoenterostomy, but with a suboptimal response, are more difficult. Cirrhosis still occurs, but perhaps at a slower rate, and timing for transplantation is more difficult. Technically, the pre-existing portoenterostomy makes biliary reconstruction following transplantation easier and safer. Any improvement from portoenterostomy delaying cirrhosis also permits further growth, which increases the likelihood of suitable donor availability.

Inborn Errors of Metabolism

Twelve children and three adults were transplanted for inborn errors of metabolism, the most common disease being alpha₁-antitrypsin deficiency. Less than one quarter of homozygotes deficient for alpha₁-antitrypsin develop progressive cirrhosis. Microscopically, hepatocyte injury is not clear. With biopsy documented progressive cirrhosis, hepatic transplantation is indicated. Serum alpha₁-antitrypsin levels are restored and alpha globulins are not accumulated in the liver homograft (Hood et al., 1980).

In two children with Wilson's disease who developed cirrhosis-producing hepatic failure prior to the introduction of penicillamine, liver transplantation produced normal ceruloplasmin levels, a massive cupruresis, and gradual resolution of the neurological deficit. Both children survived over 5 years and one is still alive (Starzl et al. 1978).

CONTRAINDICATIONS TO ORTHOTOPIC HEPATIC TRANSPLANTATION

Age

Few patients over age 50 have been transplanted, and none have been transplanted in the past 5 years. The longest survival in a

patient older than 50 was 87 days. Age 50 has thus been regarded as the upper age limit. Between the ages of 45 and 50, candidates are a better risk. Patients with primary biliary cirrhosis usually fall into this latter category.

Hepatic Malignancy

Malignancy that is metastatic to the liver is a clear indication of systemic disease and, as such, has been a contraindication to transplantation. Malignancy arising in the liver is also a systemic disease, though this was not initially so apparent. Originally, extensive hepatic malignancy without obvious extrahepatic metastases was considered an indication for total hepatectomy and transplantation. Patients with hepatoma, cholangiocarcinoma, bile duct cancer, and angiosarcoma have been transplanted. Eleven patients lived beyond 3 months and nine have died of metastatic disease, usually within the liver homograft. However, considerable palliation has been achieved in bile duct carcinoma, with one patient living just over 5 years. Similarly, the Cambridge-King's College series experienced a high recurrence rate (Calne and Williams, 1979). Hepatic transplantation in malignancy is now restricted to tumors with unusual pathological features and demonstrated extremely slow growth characteristics.

Portal Vein Thrombosis

Portal vein revascularization is critical to graft function. Portal vein thrombosis occurring even months following transplantation has resulted in graft necrosis. Consequently, portal vein patency must be ascertained before any irreversible steps during the recipient hepatectomy. Cavernous transformation of the portal vein has prevented adequate portal flow and can occasionally be difficult to detect until division of the portal vein. An attempt to re-establish portal perfusion by vena caval transposition was not successful.

A previous portacaval shunt may be helpful because portal hypertension is not aggravated by portal clamping. Mesocaval "H" graft shunts have been difficult to take down during transplantation. This type of shunt should be avoided in patients who may eventually be considered for transplantation. The most convenient shunt

is the distal splenorenal shunt. Following transplantation of the liver, a splenectomy is performed effectively taking down the shunt. Hepatic artery thrombosis is not a problem but occasionally requires anastomosis of the homograft hepatic artery directly to the aorta.

Systemic Infection

Cholangitis and spontaneous bacterial peritonitis have frequently been observed in patients coming to transplantation. These infections have responded well to liver transplant. Other infectious sites, especially abdominal abscesses or fistulae, have been disastrous.

Acute Hepatitis

Acute hepatitis with massive hepatic necrosis is usually not an indication for orthotopic transplantation. Almost complete recovery can follow even severe cases, precluding hepatectomy and transplantation until late in the course of the disease. Auxiliary transplantation may also be used to provide temporary support.

PREOPERATIVE ASSESSMENT AND SUPPORT OF THE LIVER RECIPIENT

Candidates for liver transplantation are usually referred by hepatologists, but a significant number are self-referred. Medical records and biopsy slides are requested and reviewed. The vast majority of self-referrals are eliminated at this stage. Patients who conform to the indication and contraindication guidelines are admitted for further evaluation.

Assessment of liver disease is usually completed prior to admission. A biopsy may be repeated if the forwarded specimen is felt to be inadequate, but this is usually avoided. Radio-nuclide scans are usually performed to eliminate malignancy as the etiology of recent deterioration. Angiography is used only for suspected malignancy or portal vein thrombosis. Venocavography is performed for the Budd-Chiari syndrome. The most difficult decision is usually timing. Laboratory studies are of limited help. The best indicator of the appropriate time for

transplantation remains the previous medical records. Decreasing periods out of the hospital, more frequent episodes of encephalopathy or cholangitis, and debilitating pruritus establish the appropriate time for transplantation.

Extrahepatic disease is investigated and treated. Respiratory therapy is initiated, and frequently thoracentesis is necessary. Most patients are panendoscoped. Hepatorenal patients undergo hemodialysis. Nutrition is pushed to the maximum protein load tolerated. Intensive nursing care is necessary to avoid aspiration and decubitus in encephalopathic patients.

Bleeding is common, but must be localized and controlled. Several patients have been transplanted with their Sengstaken-Blakemore tubes in place. Hemorrhoids can be even more difficult to control.

Since there is no artificial liver support, the best treatment for the patient accepted for transplantation is prompt procurement of a suitable donor liver. Though the patient is precariously close to death at this point, transplantation is the safest option.

DONOR SELECTION AND PRESERVATION

Donor Selection

The greatest asset to the liver transplant program is an active kidney transplant program with an aggressive transplant coordinator. The ideal donor is a heart-beating, brain-dead young adult or child with good visceral perfusion. Good urine output remains the best indicator of liver perfusion. Fluids that may have been restricted prior to brain death are now pushed. Cardiotropic drugs are given as needed. Potential donors are eliminated if they are over 50 or have a history of malignancy, systemic infection, or hepatitis. Toxicology screens are performed prior to determining brain death, but evidence of ingestion of hepatotoxic drugs also needs to be evaluated. Acetaminophen ingestions have been regarded as unacceptable.

The recipient has then been selected based on the donor's size, ABO group, and nonreactivity on the cytotoxic crossmatch. In desperate situations, even ABO incompatibility and positive cytotoxic crossmatches have been accepted without evidence of hyperacute rejection.

Donor Hepatectomy

The abdomen is opened through a large cruciate incision; it has generally been unnecessary to open the chest. The falciform ligament is ligated and divided. Both right and left triangular ligaments are divided, with ligation of even small vessels, which may ooze later in the recipient. Inspection of the liver at this point permits hepatectomy of the recipient to be initiated. The right and left kidneys are completely mobilized to the cava and aorta, but these vessels and the ureters are left intact. The kidneys are later removed just prior to actual removal of the liver.

The suprahepatic vena cava is circumferentially dissected from the level of the most superior hepatic vein to well above the diaphragm. The membranous portion of the diaphragm is partially opened and the right, left, and posterior phrenic veins are ligated and divided (Fig. 50-1). A generous suprahepatic cuff is a luxury greatly appreciated during transplantation. Dissection around the vena cava inferiorly to the already dissected renal veins requires only division of the right adrenal vein(s) and of the peritoneum of the lesser sac to the left of the cava.

Dissection of the common bile duct begins as distally as possible in the porta hepatis, reflecting the duodenum anteriorly to divide it at its junction with the duodenum. The divided duct is carefully inspected to ensure that the cystic duct has already entered to form a single lumen. As much surrounding tissue as possible is preserved with the duct to enhance its vascularity. The gallbladder is opened at its fundus, and bile is irrigated from the biliary tree with saline.

Dissection of the hepatic artery begins distally in the porta hepatis, ligating and dividing the gastroduodenal and right gastric arteries at their junction with the hepatic artery. A right hepatic artery from the superior mesenteric may be present in 15 to 20 per cent of donors and is dissected prior to the bile duct. Before proceeding farther, the gastrohepatic ligament is carefully divided, and if an anomalous left hepatic artery is found it is preserved and dissected to its junction with the left gastric or celiac artery. Dissection of the proper hepatic artery is then continued to, and including, the celiac trunk.

The portal vein is dissected last. The coronary vein is ligated and divided, permitting

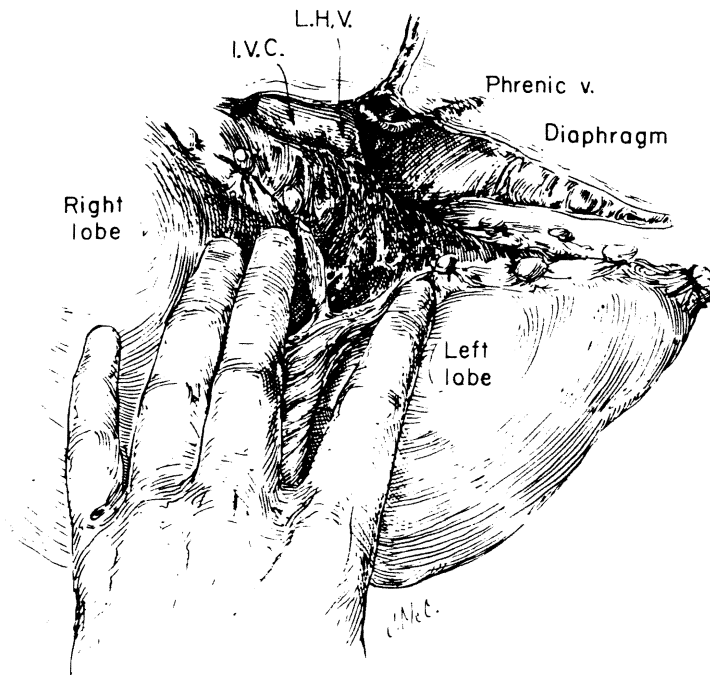


Figure 50-1. The suprahepatic inferior vena cava (I.V.C.) is generously dissected during the donor hepatectomy. The left hepatic vein (L.H.V.) may be exposed but preserved while the phrenic veins are divided to provide additional length. (From Starzl, T. E., and Putnam, C. W.: *Experience in Hepatic Transplantation*. Philadelphia, W. B. Saunders Co., 1969.)

the portal vein to be bluntly dissected to the junction of the superior mesenteric and splenic veins. The pancreas is usually divided anteriorly to facilitate dissection of the portal vein.

The kidneys are removed and perfused first. The superior mesenteric vein is divided and perfused with chilled Ringer's lactate. The aorta is clamped and the celiac artery removed with an aortic cuff. The cava is divided with long cuffs, and the graft is removed.

Preservation

Transplantation always necessitates graft protection by hypothermia. The portal vein is divided first, and perfusion with cold lactated Ringer's solution is begun. The liver is removed, and the hepatic artery is briefly rinsed with the same solution. For immediate reimplantation, the portal perfusion is maintained as the caval anastomoses are completed. Continued perfusion maintains hypothermia and flushes trapped air.

When a longer ischemic period is necessary, as in transfer from another city, an intracellular electrolyte solution is used. At the University of Colorado, 4°C Collins solution has been effective (Benichou et al., 1977). A slightly

different plasma solution has been utilized at Cambridge-King's College hospital (Wall et al., 1977.) After perfusion and immersion in these solutions, the liver is packed in ice for transit. Just prior to implantation, perfusion of the graft is begun with iced lactated Ringer's solution to flush the storage solution and to maintain hypothermia.

TECHNIQUE OF ORTHOTOPIC TRANSPLANTATION

Recipient Hepatectomy

The initiation of the recipient's operation occurs when the donor liver is first examined and felt to be normal. Since the recipient hepatectomy is frequently lengthy, it must be begun concurrently with the donor hepatectomy to avoid unnecessarily prolonged ischemia of the graft. When the recipient and donor hepatectomies are in different cities, the recipient's surgery is begun when the donor surgeon calls to confirm that the liver looks acceptable.

The recipient is carefully positioned in a slightly right anterolateral position. A bilateral subcostal incision is made (Fig. 50-2, A-A or B-B). For added exposure, a vertical midline

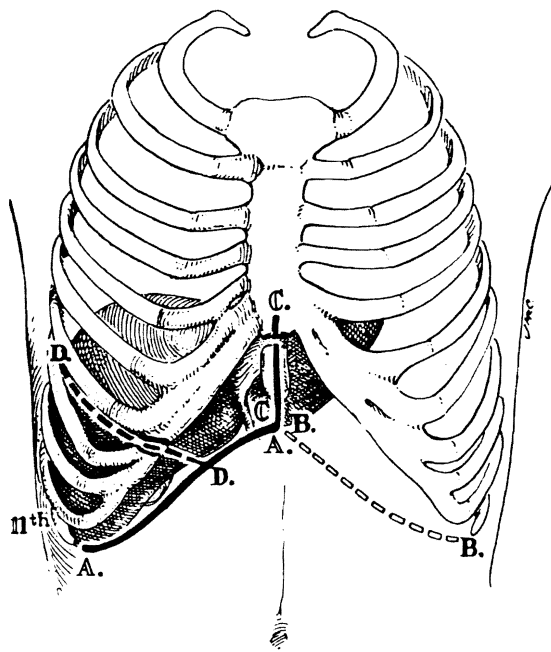


Figure 50-2. Subcostal incision with various extensions provides adequate exposure in hepatic transplantation. (From Starzl, T. E., et al.: *Surg. Gynecol. Obstet.* 142:487, 1976. By permission of Surgery, Gynecology and Obstetrics.)

incision with excision of the xyphoid is added (Fig. 50-2, C-C). In older adults with rigid costal margins, a thoracic extension is made from the subcostal margin into the right sixth or seventh interspace (Fig. 50-2, D-D). When a midline abdominal incision is used, it is always extended across the costal margin into the sixth interspace.

The porta hepatis is dissected first, carefully ligating lymphatics and even the tiniest vessels. The portal vein is circumferentially dissected and very carefully examined for patency, but is not divided. Any cholangiodigestive anastomoses are taken down. When present, the cystic duct is ligated and divided, with dissection of the common hepatic duct to its bifurcation. The hepatic artery is then dissected to the junction with the gastroduodenal artery. At this point, only the intact duct and vessels remain at the porta hepatis. Extensive bleeding from divided adhesions on the inferior hepatic surface may require division of the vessels at the porta hepatis at any time, but preferably they are retained until dissection is complete. Anomalous hepatic arteries arising from the superior mesenteric or left gastric arteries are not preserved, as they will not be used in reconstruction.

The remainder of the liver is mobilized in similar fashion to the donor hepatectomy, although portal hypertension usually makes the procedure more tedious. There is no need to dissect long caval cuffs beyond the liver, but, rather, when the cava is clamped the caval cuffs are developed from the intrahepatic cava, frequently dividing the hepatic veins as they enter the cava. The portal structures are clamped and divided just prior to clamping the cava.

After removal of the liver, a thorough search is made for bleeding. Caval cuffs are inspected and holes from small hepatic veins are repaired.

Orthotopic Transplant Operation

The homograft liver is inserted exactly as the diseased liver was removed. Continuous perfusion is maintained, or is reinstated, through the portal vein as the anastomoses are completed. This perfusion will maintain hypothermia and flush air trapped in the hepatic veins.

The suprahepatic cava is anastomosed first. The posterior wall is anastomosed from within the lumen with great caution, since later reinforcement of this suture line is very difficult because of the bulk of the graft. The infrahepatic cava is anastomosed next, although the cava is not declamped. The liver is massaged and perfusion is increased to remove all air prior to trying the infrahepatic suture.

With the liver in the orthotopic position, perfusion is terminated and the portal vein is trimmed to avoid redundancy. The portal vein is anastomosed end to end. If interruption of caval return has been a problem, the cava and portal vein can be declamped. If the recipient is stable, the hepatic artery will be anastomosed next. The hepatic artery can be anastomosed at any point, including directly on the aorta, but the most common site is to the proper hepatic artery at the bifurcation with the gastroduodenal. The gastroduodenal artery is divided, and this bifurcation is anastomosed end to end to the graft hepatic artery. Following declamping, hemostasis is secured. Hemostasis is primarily a function of the homograft liver, and considerable delay may occur at this point if the graft has sustained any injury. The graft should assume a good color and turgor within 5 minutes, and evidence of clotting should be apparent in the wound within 15 minutes.

Hypersplenism is usually present, necessitat-

ing splenectomy to alleviate the hypersplenism and to facilitate abdominal closure. Splenectomy is performed earlier, during the hepatectomy, only when splenomegaly would cramp insertion of the graft; otherwise, the spleen is removed when clotting has improved and the portal hypertension has been alleviated.

Finally, biliary drainage is re-established. The homograft common bile duct is cut back until bleeding from the divided stump is encountered. The recipient common hepatic duct, divided at its bifurcation, is probed to the duodenum. In the absence of primary bile duct disease, a choledochocholedochostomy is preferred (Fig. 50-3 D). A T-tube is placed in the recipient common hepatic duct, usually with the long arm exiting from the recipient cystic duct. The proximal limb extends across the anastomosis into the graft common bile duct. The anastomosis is end to end with interrupted 5-0 polyglycolic acid sutures. The distal limb of the T-tube is quite short. After an acceptable anastomosis, the graft cystic duct is ligated and

divided. The gallbladder is removed, and drains are placed near the anastomosis. A late follow-up retrograde cholangiogram demonstrates a considerable distance between the two cystic duct stumps (Fig. 50-4).

When the recipient common bile duct is diseased, a roux-en-Y cholecystojejunostomy is preferred. A previously constructed jejunal limb is used if available, otherwise a long jejunal limb is constructed. The end of the jejunal limb is anastomosed inferiorly to the fundus of the gallbladder in two layers (Fig. 50-3 B). The open end of the common bile duct is ligated with a nonabsorbable suture. No drains are used.

If the patency of the cystic duct is in question and the recipient's common bile duct is diseased, a choledochojejunostomy is necessary (Fig. 50-3 C). The anastomosis is over a stent with an absorbable inner layer and a nonabsorbable outer layer. The stent exits from the side of the jejunal limb. The gallbladder is removed and drains are placed near the anas-

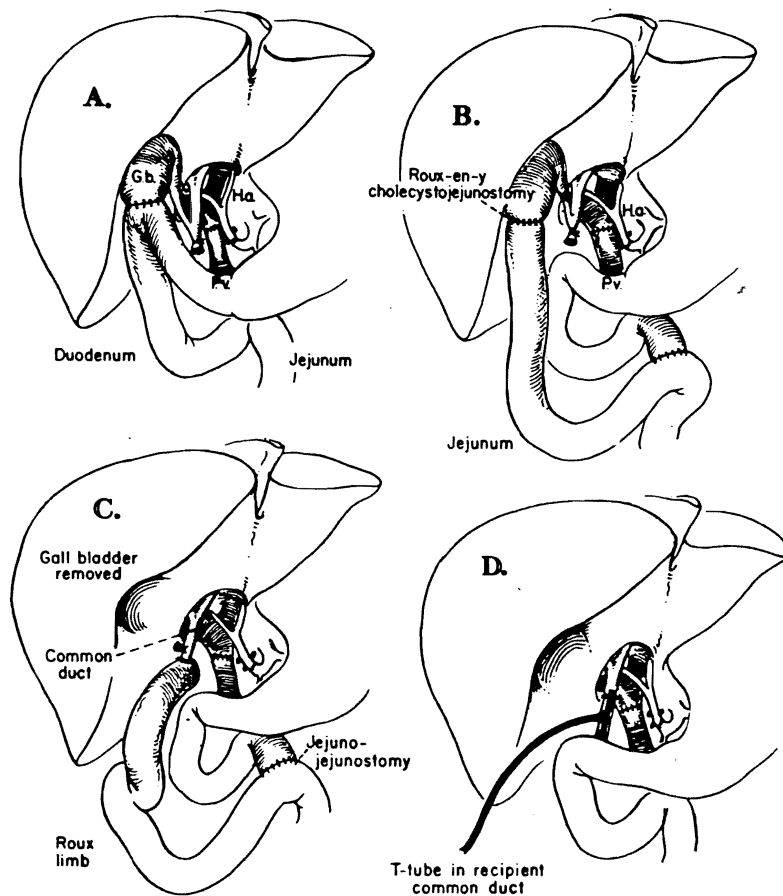


Figure 50-3. Four methods of biliary drainage employed in orthotopic hepatic transplantation: A. Cholecystoduodenostomy is no longer performed because of a high complication rate. B. Cholecystojejunostomy is necessary when the liver recipient's own bile duct is diseased and cannot be used. C. Choledochojejunostomy usually results from surgical revision of a cholecystojejunostomy obstructed at the cystic duct. D. Choledochocholedochostomy is preferred whenever possible. The T-tube usually exits from either the donor or recipient cystic duct stump. (From Starzl, T. E., et al.: *Surg. Gynecol. Obstet.* 142:487, 1976. By permission of Surgery, Gynecology and Obstetrics.)

Figure 50-4. Retrograde cholangiogram demonstrates unique feature of liver transplants—two cystic duct stumps. Vascularity of the bile duct usually permits considerable redundancy.



tomosis. The wound is closed in the routine fashion. Cholecystoduodenostomy (Fig. 50-3 A), originally the preferred method of drainage, is no longer performed because of a high complication rate.

POSTOPERATIVE MANAGEMENT

Hemorrhage

Occasionally a damaged homograft thwarts all attempts to achieve hemostasis. Clotting can be prolonged by dilution of platelets and clotting factors from excessive bleeding, by consumption within the graft, by intravascular consumption, or simply by failure of the liver to replenish clotting factors. Occasionally complete hemostasis is impossible, and sometimes it is necessary to close a bleeding wound. Blood and fresh frozen plasma are replaced as necessary, and the patient is returned to the intensive care unit to await liver recovery. After bleeding ceases, it is best to plan on returning to the operating room for evacuation of clots. If hepatic injury occurs in the postoperative period, either from rejection or thrombosis, the bleeding diathesis may recur. Late bleeding warrants further investigation of the graft.

Immunosuppression

Immunosuppression is begun in the operating room with the administration of 1 gram of

methylprednisolone during the vascular anastomoses. Methylprednisolone is continued in the postoperative period, initially at 50 mg. every 6 hours and then reduced by 20 mg. daily until a maintenance schedule of 30 mg. daily is reached. Later, oral prednisone is begun at an equivalent dosage. Children are begun at 7 mg. per kg. per day and follow a similar reduction schedule. At 1 year an adult takes about 30 mg. of prednisone daily.

Azathioprine is begun immediately following transplantation with the administration of 2 to 3 mg. per kg. per day. This amount is then varied, depending upon the peripheral white blood count. Occasionally, with biopsy proven intrahepatic cholestasis, azathioprine is discontinued in favor of cyclophosphamide in an equivalent dosage.

Most recently, cyclosporin A has demonstrated impressive immunosuppressive properties. It is currently initiated at a dosage of 17.5 mg. per kg. per day immediately following transplantation. It is maintained at this level unless nephrotoxicity or hepatotoxicity necessitates a reduction (Starzl et al., 1981). Dosages of half the initial amount have preserved graft function while permitting resolution of nephrotoxicity. Generally the liver recipients have been well maintained on 10 to 12 mg. per kg. per day of cyclosporin A.

With cyclosporin A, neither azathioprine nor cyclophosphamide is given. Methylprednisolone, however, is given in the same initial dose of 200 mg. per day but is then reduced by 40 mg. per day until a maintenance schedule of 20 mg. per day is reached. Rejection episodes are treated with increased steroid administra-

tion, but cyclosporin A is not increased. Because of the possibility of cyclosporin A hepatotoxicity, in the face of possible rejection cyclosporin A is frequently reduced while steroids are temporarily increased.

Rejection remains an elusive diagnosis. In earlier liver transplantations this diagnosis was probably made too frequently. Much of the improvement achieved after 1976 arose from a vigorous diagnostic approach to jaundice. Cholangiography, both retrograde and percutaneous, became routine. Even the slightest hesitation in contrast flow was regarded as partial obstruction and biliary revision was undertaken.

A single liver biopsy has had only limited usefulness in the diagnosis of rejection. The biopsy is frequently difficult to correlate with the clinical course. Serial biopsies have, however, been of considerable value. Biopsies before and after changes in steroids or other medications have given added confidence in biopsy interpretation. Errors in the diagnosis of rejection are now much less frequent, but chronic irreversible rejection may persist despite intense immunosuppression. The introduction of cyclosporin A as a powerful immunosuppressant with its markedly improved graft survival confirms the central role of rejection in the earlier immunosuppression schedules. Rejection during cyclosporin A administration has been responsive to increased steroids, although the pathology may be slightly different (Starzl et al., 1981).

Biliary Obstruction

Liver homograft function is monitored daily for at least a month. Alkaline phosphatase is usually the first biochemical test to reflect a deterioration in liver function, although bilirubin, transaminases, prothrombin time, albumin, and globulins are watched daily. Any change warrants a tube cholangiogram if a stent is still in the biliary tree. If no stent is available, an hepatobiliary liver scan is obtained.

If partial obstruction is suggested by the liver scan, or if liver dysfunction persists, a cholangiogram is obtained. Now the majority of patients have choledochocholedochostomies, which are best studied by retrograde cholangiography. Strictureing of the bile duct can be quite severe without producing proximal dilatation. A stricture, even without proximal dilatation, warrants operative repair. Normally the

intrahepatic ducts appear somewhat smaller than are usually seen. The common duct also frequently appears angulated at the former exit site of the T-tube, and a sinus tract may persist for several months, although these findings do not indicate obstruction. In one patient a bile duct stricture with a spontaneous proximal choledochoduodenal fistula was actually a recurrence of a bile duct carcinoma.

Retrograde cholangiography is not feasible in those liver recipients with cholangiodigestive anastomoses. Furthermore, transhepatic cholangiography is made more difficult by the frequently decreased size of the intrahepatic ducts. Ultrasonography of dilated ducts is too late a finding and usually is not helpful. The cholangiography must be carefully reviewed, since the only suggestion of partial obstruction may be a delay in emptying or some sludge seen only on early films. The most frequent site of obstruction has been at the cystic duct; the cholecystojejunal anastomoses are rarely, if ever, at fault.

Most of the patients with choledochojejunostomies originally had cholecystojejunostomies that had become obstructed at the cystic duct. Approximately 30 per cent of patients with cholecystojejunostomies became obstructed at the cystic duct. If jaundice persists or recurs after conversion to a choledochojejunostomy, transhepatic cholangiography is indicated. Cholangiojejunostomies have generally maintained good patency and the majority will demonstrate a normal choledochojejunostomy.

RESULTS OF LIVER TRANSPLANTATION

1963 to 1976

Between March 1963 and July 1976, 111 liver transplants were performed at the University of Colorado. Of these 111 patients, 31 patients (28 per cent) survived over 1 year. Currently 13 of these patients are still alive, with the longest survivor having been transplanted in 1970.

A review of the first 93 patients indicated that mechanical problems, especially biliary obstruction, were the primary causes of death in those patients dying within the first year following operation (Starzl et al., 1976). Rejection was an unusual finding in those coming to autopsy. In those patients who died after surviving a

year, however, rejection was the most common factor. In the summer of 1976, a number of changes were initiated as a result of this study.

1976 to 1980

In July 1976 patient selection eliminated patients over age 50, and those with hepatic malignancy, from consideration for transplantation. Technical changes in the development of vena cava cuffs and microsurgical techniques were initiated. The main changes, however, were in postoperative management, where an aggressive diagnostic approach was adopted. Cholangiography, serial liver biopsies, and surgical biliary revision became more common.

Two years into this period a 50 per cent 1 year survival was happily reported (Starzl et al., 1979). During the latter 2 years of the period a decline in survival was seen, probably related to a variety of technical problems and also to the employment of thoracic duct drainage for lymphocyte depletion (Starzl et al., 1980).

In February 1980, this series was completed, with the last patient treated by conventional immunosuppression. The survival at 1 year for adults for the entire period 1963 to 1980 was 28 per cent (Table 50-3). Children enjoyed a slightly improved survival at 1 year of 38 per cent (Table 50-4). One hundred seventy patients had been transplanted, half being children and half adults.

Fortunately, the prognosis for those achieving the first year milestone improves

Table 50-3. Results of Orthotopic Hepatic Transplantation at University of Colorado, March 1963 through February 1980 (Follow-up to February 1981)—Adults 19 to 68 years

Diagnosis	Number of Patients	Number Living Over 1 Year
Chronic active hepatitis	34	11
Laennec's cirrhosis	16	4
Primary hepatic malignancy	14	3
Primary biliary cirrhosis	8	2
Sclerosing cholangitis	6	1
Budd-Chiari syndrome	1	1
Secondary biliary cirrhosis	1	1
Inborn errors of metabolism	3	0
Biliary hypoplasia	2	1
Total	85	24 (28%)

Table 50-4. Results of Orthotopic Hepatic Transplantation at University of Colorado, March 1963 through February 1980 (Follow-up to February 1981)—Children \leq 18 years

Diagnosis	Number of Patients	Number Living Over 1 Year
Biliary atresia	52	15
Chronic active hepatitis	12	4
Inborn errors of metabolism	12	8
Primary hepatic malignancy	4	2
Neonatal hepatitis	2	1
Congenital biliary cirrhosis	2	0
Secondary biliary cirrhosis	1	2
Total	85	32 (38%)

markedly. From the entire series, the majority of those alive at 1 year are still alive at this time. Those patients dying subsequent to achieving 1 year survival were almost invariably in trouble and on more immunosuppression at 1 year. Those patients enjoying normal hepatic function at 1 year have usually continued to do so and have achieved good rehabilitation (Starzl et al., 1979). Most adults have not returned to work, although many have, and the children are attending school regularly.

1980

Between March 1980 and September 1980, 14 patients have received liver transplants with

Table 50-5. Results of Orthotopic Hepatic Transplantation at University of Colorado, March 1980 through September 1980 (Follow-up to February 1981)

Diagnosis	Number of Patients	Number Living at 5 to 11 Months
Chronic active hepatitis	3	3
Budd-Chiari syndrome	3	3
Secondary biliary cirrhosis	2	1
Sclerosing cholangitis	2	1
Primary hepatic malignancy	1	1
Primary biliary cirrhosis	1	1
Biliary atresia	1	1
Intrahepatic cholestasis	1	0
Total	14	11 (79%)

cyclosporin A immunosuppression. Eleven of these patients are alive at 5 to 11 months following their liver transplant (Table 50-5). Two of the deaths were operative. All of the 11 surviving patients from this series currently have good hepatic function. These are clearly the best results achieved to date. This striking improvement in survival, if maintained at a year as it apparently will be, would strongly support the clinical feasibility of liver transplantation.

REFERENCES

- Benichou, J., Halgrimson, C. G., Weil, R., Koep, L. J., and Starzl, T. E.: Canine and human liver preservation for 6-18 hours by cold infusion. *Transplantation* 24:407, 1977.
- Calne, R. Y., and Williams, R.: Liver transplantation. *Curr. Prob. Surg.* 16:1, 1979.
- Fortner, J. G., Yeh, S. D. J., Kim, D. K., Shui, M. H., and Kinne, D. W.: The case for and technique of heterotopic liver grafting. *Transplant. Proc.* 11:269, 1979.
- Hood, J. M., Koep, L. J., Peters, R. L., Schröter, G. P. J., Weil, R. III, Redeker, A. G., and Starzl, T. E.: Liver transplantation for advanced liver disease with alpha-1-antitrypsin deficiency. *N. Engl. J. Med.* 302:272, 1980.
- Starzl, T. E., and Putnam, C. W.: *Experience in Hepatic Transplantation*. Philadelphia, W. B. Saunders Co., 1969.
- Starzl, T. E., Porter, K. A., Putnam, C. W., Schröter, G. P. J., Halgrimson, C. G., Weil, R. III, Hoelscher, M., Reid, H. A. S.: Orthotopic liver transplantation in ninety-three patients. *Surg. Gynecol. Obstet.* 142:487, 1976.
- Starzl, T. E., Koep, L. J., Halgrimson, C. G., Hood, J., Schröter, G. P. J., Porter, K. A., and Weil, R. III: Fifteen years of clinical liver transplantation. *Gastroenterology* 77:375, 1979.
- Starzl, T. E., Koep, L. J., Schröter, G. P. J., Hood, J., Halgrimson, C. G., Porter, K. A., and Weil, R. III: The quality of life after liver transplantation. *Transplant. Proc.* 11:252, 1979.
- Starzl, T. E., Koep, L. J., Porter, K. A., Schröter, G. P. J., Weil, R. III, Hartley, R. B., and Halgrimson, C. G.: Decline in survival after liver transplantation. *Arch. Surg.* 115:815, 1980.
- Starzl, T. E., Klintmalm, G., Porter, K. A., Iwatsuki, S., and Schröter, G. P. J.: Liver transplantation, with use of cyclosporin A and prednisone. *N. Engl. J. Med.* 305:266, 1981.
- Starzl, T. E., Putnam, C. W., and Kolp, L.: Liver transplantation for inborn errors of metabolism. *In* Bionchi, L., Gerok, W., and Sickinger, K.: *Liver and Bile*. Baltimore, University Park Press, 1978, p 343.
- Wall, W. J., Calne, R. Y., Herbertson, B. M., Baker, P. G., Smith, D. P., Underwood, J., Kostakis, A., and Williams, R.: Simple hypothermic preservation for transporting human livers long distances for transplantation. *Transplantation* 23:210, 1977.