

475 ~~4000~~

19

LIVER, GALLBLADDER, AND EXTRAHEPATIC BILE DUCTS

John R. Lilly, M.D.

Thomas E. Starzl, M.D., Ph.D.

Most operations upon the biliary tract in infants and children are done for congenital malformations rather than for acquired disease. Surgical complications, consequently, are often different and sometimes quite distinct from those encountered in adult patients. In contrast, the majority of liver operations in children are done for the same indications as in older patients, e.g., trauma, tumor. Complications are similar.

bile duct is grossly patent in its proximal portion but atretic distally. Bile flow is blocked outside the liver. Operative relief of biliary obstruction is relatively straightforward. Biliary drainage is provided by Roux-en-Y choledochojejunostomy (in which the jejunum is anastomosed to the patent proximal bile duct) or by choledochoduodenostomy. In "noncorrectable" biliary atresia, the lumen of the proximal, and often the entire, extrahepatic bile duct is obliterated, and thus biliary obstruction is intrahepatic. Surgical correction is more complicated.

THE BILIARY SYSTEM

The principal malformations of the biliary system requiring surgical correction are biliary atresia, biliary hypoplasia, choledochal cyst (and Caroli's disease), and spontaneous perforation of the extrahepatic bile ducts. Landing has presented evidence indicating that the first three entities are simply different manifestations of a single disease.¹⁷ Nevertheless, the operations for the individual conditions are so disparate that each is considered separately.

CORRECTABLE BILIARY ATRESIA

The distal extrahepatic bile duct is obliterated in patients with correctable biliary atresia. Contrary to what would be anticipated with longstanding obstruction, the intrahepatic biliary system is not dilated but is, in fact, hypoplastic (Fig. 19-1). Histologically and morphologically, the hepatic parenchymal changes are indistinguishable from those of noncorrectable biliary atresia. Because of intrahepatic disease, the postoperative course generally parallels that observed in patients with noncorrectable biliary atresia. The severity of complications is attested to in a survey conducted by the Surgical Section of the American Academy of Pediatrics.

Biliary Atresia

Traditionally, biliary atresia has been separated into "correctable" and "noncorrectable" types. In the former, the extrahepatic

This work was supported in part by research grants from the Veterans Administration, by grants AM-17260 and AM-07772 from the National Institutes of Health, and by grants RR-00051 and RR-00069 from the General Clinical Research Centers Program of the Division of Research Resources, National Institutes of Health.




Figure 19-1 Operative cholecystogram in an infant with "correctable" biliary atresia. The gallbladder, cystic duct, and common hepatic ducts are open and communicate with the intrahepatic biliary system. The common bile duct is nonpatent. Note that the intrahepatic bile ducts (and common hepatic duct) are hypoplastic despite prolonged biliary obstruction. The patient was treated by cholecystojejunostomy (Roux-en-Y) by Dr. Dennis Shermeta and was well when last seen (6 months).

rics. Half of the patients with correctable biliary atresia were dead at the time of the report.¹³

One complication, anastomotic stricture, may be preventable. The distal end of the patent portion of the extrahepatic bile duct is almost always structurally abnormal and often lacks a mucosal surface. Intestinal anastomosis to this end may result in late anastomotic stricture. To avoid this complication, the intestinal anastomosis should be done not to the end of the patent bile duct, but to its proximal portion, at the liver hilus. In this location the duct is usually normal. In addition to anastomotic stricture, all the complications of noncorrectable biliary atresia described in the following section are encountered in patients with correctable biliary atresia, albeit usually in a less severe form.

NONCORRECTABLE BILIARY ATRESIA

Despite the connotation of atresia, the extrahepatic bile ducts are patent in most infants less than 2 months of age who have biliary atresia. The common hepatic duct contains a minute bile duct that communicates with the intrahepatic biliary tree. Sometime between the third and fourth months of life, patency of the residual duct is lost. The reason for the ongoing obliteration of the ductal system is that biliary atresia is not a true error of bile duct devel-

opment but is instead a dynamic obliterative disease of the biliary tract. The concept of a progressive disease process is essential to understanding and treating the complications following corrective surgery for biliary atresia.

Corrective surgery is considered to be the operation described by Kasai and coworkers in which the fibrotic extrahepatic biliary tree is totally excised and bile drainage is established by anastomosis of an intestinal conduit to the liver hilus.¹⁵ If the residual bile duct is still patent, bile drains from the intrahepatic biliary system into the interposed bowel. In time, an autoanastomosis presumably occurs between the transected bile duct and the intestinal mucosa. The diminutive caliber of this anastomosis is most likely responsible for the main complication of Kasai's operation, cholangitis. The operation is a major undertaking requiring extensive dissection of the portal triad. Operative technical intricacies are compounded in 10 to 20 per cent of patients by the presence of associated perihepatic intestinal and vascular anomalies such as a preduodenal portal vein (Fig. 19-2) and intestinal malrotation.²¹ Incorporation of portal vein or hepatic artery adventitia or both is often required for the hilar anastomosis. The operation is hazardous, and intraoperative complications include injury to the hepatic arterial or portal venous system. Late problems include subphrenic abscess, biliary fistula, and intestinal anastomotic breakdown.

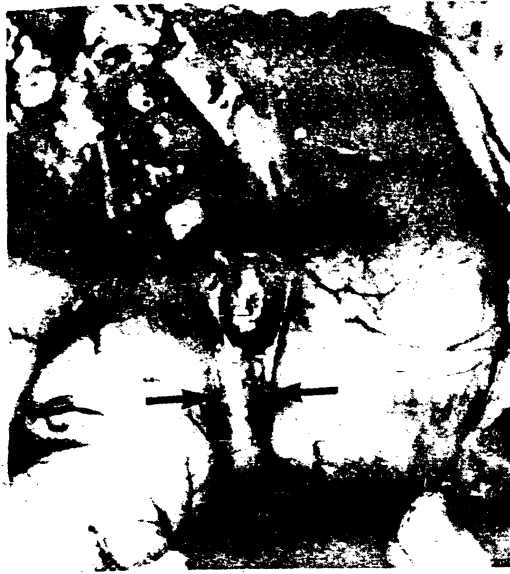

Figure 19-2 Operative photograph in an infant with biliary atresia and associated preduodenal portal vein (arrows). The patient had no clinical signs of duodenal obstruction. A standard hepatic portoenterostomy procedure was done.

Early in our experience, a subphrenic abscess occurred in a patient secondary to a hilar bile leak. Because the abdominal bilioenteric exteriorization site was too small, bile drainage was impeded, causing a disruption of the hilar anastomosis. A deliberate effort is now made to make the intestinal conduit exteriorization site adequate in caliber. Other complications specific to Kasai's hepatic portoenterostomy operation are listed in Table 19-1 and described below.

Absence of Bile Flow. Failure of biliary drainage after operation indicates that the intrahepatic ductal system has not been surgically opened at the porta hepatis. The complication may stem from pre-existing total obliteration of the residual extrahepatic bile duct or from obstruction of the intrahepatic bile ducts. In either case, surgery has nothing to offer. However, postoperative absence of bile flow may be a consequence of too distal transection of the

common hepatic bile duct. Histologic verification of a microscopic bile duct in the most proximal portion of the surgical specimen is an essential requirement of the operation. Moreover, it is crucial that the residual bile duct (Fig. 19-3A) be distinguished from biliary glands (Fig. 19-3B) and collecting ductules of biliary glands (Fig. 19-3C) at the time of intraoperative histologic evaluation.³⁰ These glands and ductules do not communicate with the intrahepatic biliary system. In the absence of a true bile duct, operative exploration should be extended deeper into the porta hepatis.

Postoperative Cholangitis. In the Denver series, every patient in whom biliary obstruction was relieved and bile drainage was achieved by means of an intestinal conduit experienced recurrent cholangitis during the first postoperative year. The pathogenesis of the complication is unknown. Absence of cholangitis in patients who have undergone hepatic portocholecystostomy using the gallbladder, cystic duct, and common bile duct for the biliary conduit (Fig. 19-4) incriminates an "ascending" bacterial infection from the intestinal conduit.²⁰ If either a lymphatic¹¹ or a portal venous⁶ mechanism were responsible, the incidence of cholangitis would be the same irrespective of the type of biliary reconstruction.

Cholangitis is characterized by an otherwise unexplained fever followed by decreased quality and quantity of bile drainage, leukocytosis, and finally a rise in serum bilirubin level. The keystone of treatment is the parenteral administration of aminoglycoside antibiotics. In recalcitrant cases, carbenicillin may also be required. Systemic steroid therapy is used if fever persists despite antibiotic administration.

Modification of Kasai's original operation (simple Roux-en-Y hepatic portoenterostomy) by exteriorization of the biliointestinal conduit lessens the severity and facilitates control of individual attacks of cholangitis. Most types of biliary reconstruction currently in use are designed to isolate the hilar anastomosis from the gastrointestinal tract (Fig. 19-4). Since the predisposition to cholangitis appears to be a consequence of a contaminated intestinal conduit¹² in immediate proximity to a partially obstructed intrahepatic biliary system, even trivial aggravation of bile flow from intestinal stasis triggers attacks of cholangitis.

TABLE 19-1 COMPLICATIONS OF HEPATIC PORTOENTEROSTOMY FOR BILIARY ATRESIA

Absence of bile drainage
Recurrent cholangitis
Progressive cirrhosis
Fat-soluble vitamin deficiency
Portal hypertension

ive chole-
with correct-
the gallblad-
and common
and commu-
epatic biliary
bile duct is
intrahepatic
non hepatic
despite pro-
non. The pa-
ecystojejun-
Dr. Dennis
II when last

bliterative
cept of a
sential to
complica-
for biliary

to be the
oworkers
iliary tree
ge is es-
intestinal
residual
from the
he inter-
astomosis
ansected
osa. The
mosis is
a compli-
gitis. The
requiring
riad. Op-
pound-
s by the
intestinal
preduo-
intestinal
rtal vein
is often
is. The
perative
hepatic
e prob-
ary fis-
ckdown.

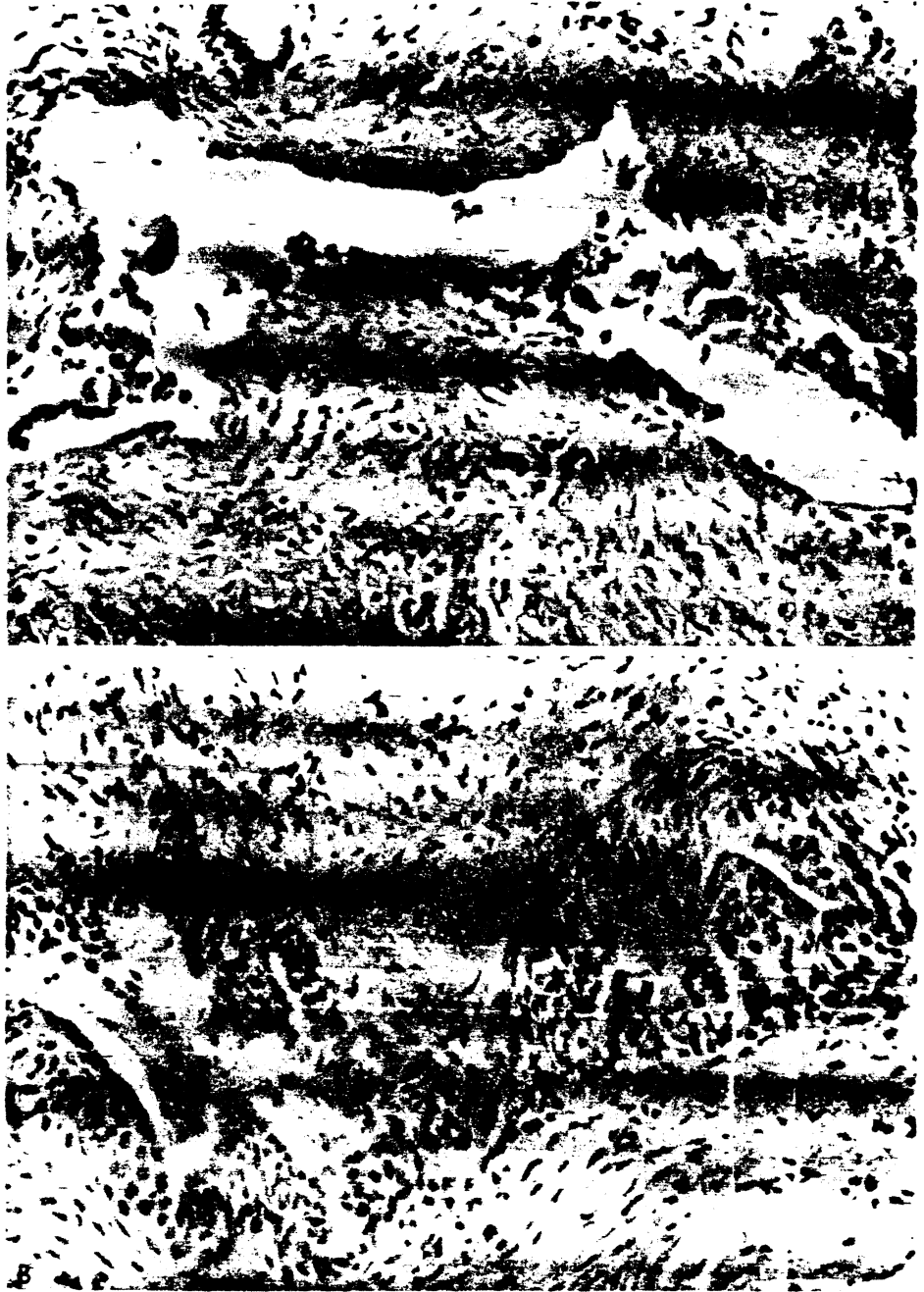


Figure 19-3 Biliary atresia. Histology of three different specimens of bile duct remnants at the porta hepatis. **A**, Bile duct: The lining cells are of flat columnar epithelium. There is partial epithelial ulceration and no evidence of cellular proliferation. An inflammatory reaction is present in the surrounding concentric layers of fibrous tissue. Bile is not present in the lumen in this case, but it is occasionally noted in other specimens containing a true bile duct. **B**, Biliary glands: Biliary glands are randomly distributed in the fibrous tissue. The glandular walls are exclusively lined by cuboidal epithelium. The lumen never contains bile.

Illustration continued on opposite page



Figure 19-3 Continued C. Collecting ductules of biliary glands: The basic morphologic characteristic is that of a biliary gland. The walls are perfectly lined by high cuboidal epithelium, which sometimes shows cellular proliferation. As is true in biliary glands, bile is never found in the lumen. Occasionally a dilated lumen may be filled with an epithelial cluster or amorphous material.

In the early postoperative period, severe cholangitis may result in cessation of bile flow. Operation and ductal re-excision at the liver hilus may cause a resumption of bile drainage and should be attempted (Fig. 19-5). A short course of systemic steroid therapy, in this situation, may be helpful in maintaining a patent bilioenteric anastomosis.

About 12 to 18 months after operation, bile flow becomes normal and susceptibility to cholangitis resolves. Thereafter, cholangitis is usually a consequence of mechanical factors such as partial obstruction of the intestinal conduit at the stoma or by adhesive bands across the defunctionalized intestinal limb. Secondary surgical procedures to alleviate the partial obstruction may be required.

Progressive Cirrhosis. All children with biliary atresia have some degree of liver disease at the time of operative intervention. Pre-existing hepatic damage is rarely reversed and, indeed, is often progressive during the first postoperative year.² At least two mechanisms may be responsible. First, serum bile acid studies have shown that bile

flow, although sufficient to eliminate jaundice, is inadequate for many months after operation.²⁴ Second, as alluded to earlier, biliary atresia is a pancreatic disease involving intrahepatic as well as extrahepatic bile ducts. Inflammation of the intrahepatic bile ducts continues for some time after operation, even with surgical relief of extrahepatic biliary obstruction.⁴ In the majority of patients having successful surgery, the intrahepatic disease appears to be self-limited. After several years, first stabilization and then improvement of liver histology is noted.¹⁶ In a significant subgroup, however, hepatobiliary disease continues despite biliary drainage. Though anicteric, these patients frequently have evidence of progressive hepatic disease. Unless saved by liver transplantation, most die of liver failure within the first postoperative year.

Fat-soluble Vitamin Deficiency. Fat-soluble vitamins require bile salts for absorption. Since bile salt flow does not reach normal for many months, impairment in fat-soluble vitamin absorption is to be anticipated. Low serum levels of vitamins A and E have been documented in all the pa-

hepatitis. A. Bile
ence of cellular
is not present
biliary glands.
cuboidal epi-

opposite page

tients we have tested thus far. Radiographic evidence of vitamin D deficiency is routinely observed. In most patients in whom bile flow was re-established surgically, radiographic improvement and cure of rickets was noted within 2 to 3 years without vitamin D supplementation. A recent patient, however, sustained bilateral rachitic femoral fractures. Vitamin D metabolite treatment in this exceptional patient resulted in healing of the fractures.

Delay in gross motor development may be secondary to vitamin E deficiency.³ Susceptibility to infection (cholangitis) may be aggravated by vitamin A deficiency. Postoperative supplementation of vitamins A and E is currently being evaluated.

Portal Hypertension. Because of pre-existing liver damage, most infants with biliary atresia have elevated portal pressure at the time of initial surgery.⁴² Esophageal varices frequently develop despite gradual return of serologic liver functions toward normal. Variceal hemorrhage, however, is unusual following successful operations. Moreover, long-term studies demonstrate that in many patients, varices spontaneously disappear.¹ This disappearance may reflect decreased portal hypertension subsequent to improvement of hepatic parenchymal disease. Because of the rarity of significant variceal hemorrhage and the background of

spontaneous improvement, we have shied away from portal diversion operations. Instead, the few Denver patients with variceal hemorrhage have been treated by endosclerosis of the esophageal varices.^{23, 26} Although experience with this new technique is limited, variceal bleeding has not recurred to date.

Biliary Hypoplasia

Biliary hypoplasia describes a morphologic state of the biliary system. Usually demonstrated by operative cholangiography, the extrahepatic bile ducts appear exceptionally small although patent throughout (Fig. 19-6). Biliary hypoplasia is not a specific disease entity but is a consequence of a variety of hepatobiliary disorders, both structural and functional (Table 19-2). Examples of the latter are neonatal hepatitis, alpha₁-antitrypsin deficiency, and intrahepatic biliary atresia. The diminutive caliber of the biliary system in this group of patients is most likely a result of "disease atrophy" secondary to severely impaired bile flow.

Biliary hypoplasia may also occur secondary to structural damage of the ductal system. The predisposing disease is probably a variant, or a milder form, of classic biliary

Figure 19-6 Operative cholangiogram via the gallbladder in an infant with biliary hypoplasia secondary to severe neonatal hepatitis. The extrahepatic biliary system is patent from the liver to the duodenum. Only a liver biopsy was done; the infant subsequently became anicteric.



biliary re-
the hepatic
or biliary

3/19/68

TABLE 19-2 ETIOLOGIC FACTORS IN BILIARY HYPOPLASIA

Functional	Structural
Neonatal hepatitis	Choledochal cyst
Alpha ₁ -antitrypsin deficiency	Extrahepatic biliary atresia
Intrahepatic biliary atresia	

atresia.²⁷ Prolonged survival has been reported in some patients,²⁸ presumably because patency of the extrahepatic biliary system persists. However, we have encountered three of 62 infants with biliary atresia and one of nine patients with a choledochal cyst in whom patency of the initially hypoplastic biliary system was subsequently lost. A Kasai hepatic portoenterostomy procedure was ultimately required in all four patients.¹⁸ At the time of operation, the extrahepatic bile ducts were totally obliterated. Biliary hypoplasia in these patients simply represents a way station in the disease process of biliary atresia.

Complications of operations for biliary hypoplasia may be due to misinterpretation of low flow syndromes as structural malformations. We have observed two infants with biliary hypoplasia, one secondary to homozygous ZZ alpha₁-antitrypsin deficiency and one secondary to intrahepatic biliary atresia, both of whom were treated by Kasai hepatoportoenterostomy procedure without improvement. It is unlikely that bypassing the hypoplastic extrahepatic ductal system will relieve intrahepatic cholestasis. Procrastination in the converse situation, i.e., structural disease misinterpreted as a functional syndrome, is even more dangerous. Infants in whom biliary hypoplasia is secondary to an underlying ductal sclerotic process may lose ductal patency and require total extirpation of the extrahepatic biliary system and replacement with an intestinal conduit. The operation should be done promptly under

these circumstances, since protracted biliary obstruction will result in irreversible biliary cirrhosis.

Choledochal Cyst

Internal drainage and primary excision are the operative procedures generally employed for treatment of congenital choledochal cyst in infants and children. Traditionally, the former has been performed by most surgeons in the United States, whereas the latter is preferred by many pediatric surgeons in Japan, France, and Australia. The specific complications of internal intestinal drainage, either by choledochocystoduodenostomy or choledochocystojejunostomy, consist of anastomotic stricture, biliary stasis, recurrent cholangitis, biliary lithiasis, and pancreatitis (Table 19-3). The incidence of such complications was recently reviewed by Flanigan and found to be from 34 per cent to 58 per cent.⁷

The fundamental reason for the high rate of complications is that diseased tissue is employed for the biliary reconstruction. Choledochal cysts are composed essentially of scar tissue (Fig. 19-7A, B). Consequently, the cyst rarely shrinks to a normal caliber, biliary stasis persists, and the stage is set for recurrent cholangitis and biliary lithiasis. Furthermore, the absence of a normal cyst epithelial lining in most cases prevents a mucosa-to-mucosa anastomosis with the intestine, thus predisposing to subsequent anastomotic stricture.

Two recent reviews have also reported that the incidence of malignancy of the extrahepatic biliary tract is about 20 times greater in patients with choledochal cysts than in the population at large.^{8, 41} The susceptibility to malignancy was not eliminated by internal drainage of the cyst. In fact, in about half the patients, carcinoma

TABLE 19-3 COMPLICATIONS FOLLOWING CORRECTION OF CHOLEDOCHAL CYST

Internal Drainage	Primary Excision
Anastomotic stricture (12%)	Anastomotic stricture (5%)
Recurrent cholangitis (50%)	Recurrent cholangitis (8%)
Biliary malignancy (2.5%)	Biliary malignancy (<1%?)
Biliary lithiasis	Pancreatic fistula (<1%)
Pancreatitis (1%?)	

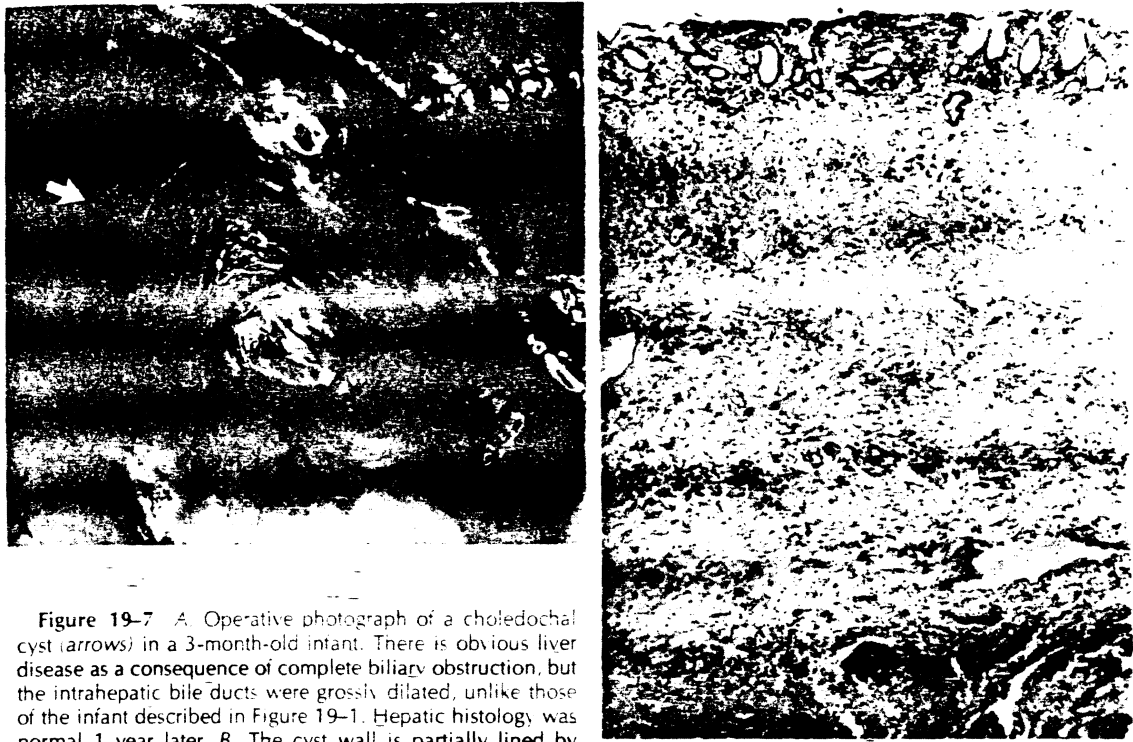


Figure 19-7 A, Operative photograph of a choledochal cyst (arrows) in a 3-month-old infant. There is obvious liver disease as a consequence of complete biliary obstruction, but the intrahepatic bile ducts were grossly dilated, unlike those of the infant described in Figure 19-1. Hepatic histology was normal 1 year later. B, The cyst wall is partially lined by epithelium and contains scattered distorted glands. The mucosa is infiltrated with chronic inflammatory cells. In some areas the mucosal epithelium is replaced by fibrin. A muscle layer is not present. Most of the wall consists of dense fibrous connective tissue containing scattered blood vessels. (Magnification $\times 30$. Courtesy of Dr. Robert H. Shikes.)

developed a mean of 4 years after an internal drainage procedure.

The mortality resulting from excision of choledochal cyst was long thought to be greater than that from internal drainage operations. This belief has not been confirmed by contemporary reviews, which report operative mortality to be about 7 per cent for both operations.⁷⁻³³ The dissection of the cyst from the adjacent portal vein and hepatic artery does, however, present a hazard in resectional operations that is not encountered in internal drainage procedures. Injury to neighboring vascular structures may be avoided by excising the cyst except for the outer shell of its posterior wall overlying the vascular structures.²¹ A plane of dissection is developed in the posterior wall by opening the cyst and carrying out the dissection from the inside (Fig. 19-8A, B).

Complications specific to resection of choledochal cyst consist of intraoperative hemorrhage, anastomotic stricture, recurrent

cholangitis, and pancreatic fistula (Table 19-3). Stricture of the choledochojejunostomy occurs in about 5 per cent of patients after excisional operations.³³ Anastomotic stricture is almost always a consequence of failure to excise the cyst completely. Hence, the defunctionalized Roux-en-Y jejunostomy is anastomosed to a diseased, scarred portion of the common hepatic duct. To avoid this complication, care must be taken to excise all of the choledochal cyst to the normal hepatic duct. Although attractive technically, leaving a rim of the choledochal cyst behind to facilitate the intestinal anastomosis is actually counterproductive. When the choledochal cyst disease process extends into the primary branches of the intrahepatic bile ducts, anastomotic stricture may be inescapable because intestinal anastomosis to a normal duct is not possible. Under these circumstances, the anastomosis should be made as large as feasible. This may necessitate laying open a portion of the main right or left hepatic duct.²²

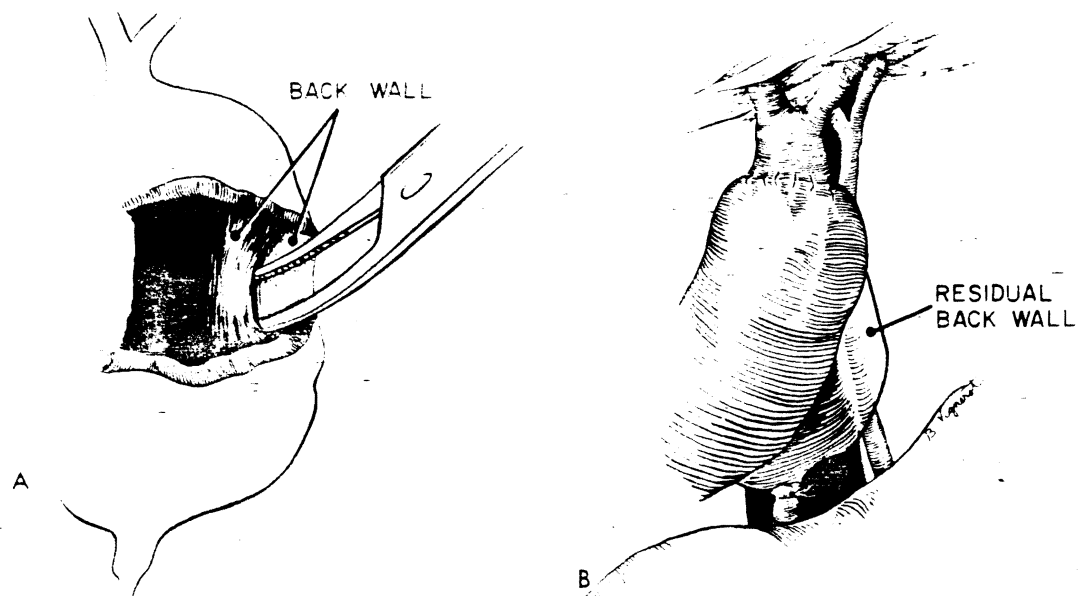


Figure 19-8 A. Excision of choledochal cyst. After the cyst is opened, dissection is begun in the posterior wall, separating it into two layers. The inner layer is completely transected and the cyst is excised except for the outer layer of the back wall. B. The operation is completed by end-to-end choledochojejunostomy (Roux-en-Y). The distal common bile duct has been suture ligated. The residual back wall of the choledochal cyst overlies the portal vein and hepatic artery. (From Lilly, J. R.: Total excision of choledochal cyst. *Surg. Gynecol. Obstet.* 146:254, 1978, by permission.)



Figure 19-9 Operative cholangiogram in a patient with a choledochal cyst demonstrating the aberration of the junction of the common bile duct and the pancreatic duct (arrows). Note that the union of the two ducts is almost at a right angle and is much farther from the ampulla of Vater than is normal, creating a long "common channel." The cholangiogram was obtained by dividing the choledochal cyst, excising the proximal cyst, and placing a vascular clamp across the distal cyst before injecting the contrast medium. (Courtesy of Dr. David C. Hiten.)

Recurrent cholangitis after cyst excision may be secondary to anastomotic stricture or to associated intrahepatic cystic disease. Coexisting intrahepatic biliary cysts are more common than was previously appreciated (nine of 16 patients reported by Tsuchida and Ishida⁴⁰ and four of 11 patients in Denver). Excision of the choledochal cyst is not curative in this situation. Biliary stasis and the likelihood of cholangitis persist despite provision of normal extrahepatic bile drainage.

Finally, in most, if not all, patients with choledochal cyst, the pancreatic duct joins the common bile duct at a point considerably more proximal than normal. Unwary surgery during the distal dissection of the cyst may lead to inadvertent transection of the pancreatic duct.¹⁴ The complication is preventable by visualizing the common bile duct-pancreatic duct junction either by operative cholangiogram (Fig. 19-9) or by direct inspection before resecting the choledochal cyst.

Caroli's Disease

In true Caroli's disease the secondary and tertiary branches of the bile ducts are grossly distorted with multiple cysts. There is no, or only limited, disease of the extrahepatic

bile ducts. In most patients with intrahepatic cystic disease, however, a choledochal cyst is also present (Fig. 19-10). Because of biliary stasis, afflicted persons are subject to recurrent cholangitis, biliary lithiasis, and biliary cancer. Excision of a coexisting choledochal cyst, when present, may aid in the control of the complications but is not curative. Hepatic lobectomy or segmentectomy should be considered for patients in whom the intrahepatic disease is localized.

Perforation of the Common Bile Duct

Spontaneous perforation of the extrahepatic bile duct is a rare but highly specific lesion in infants. It probably originates from a localized mural malformation of the common bile duct, since the site of the perforation is almost always at the union of the cystic and common ducts. The operative cholecystogram frequently demonstrates a biliary pseudocyst (Fig. 19-11). Slow escape of bile from the tiny perforation permits its temporary encapsulization. Because of sludge in the partially defunctionalized distal common bile duct, there may be a mistaken impression of distal obstruction.

Surgical dissection of the inflamed portal triad should not be undertaken. Multiple soft rubber drains are placed in the area of



Figure 19-10 Oral cholecystogram in a child with "Caroli's disease." The intrahepatic cystic disease (arrows) is associated with a choledochal cyst. The choledochal cyst was excised and a choledochojejunostomy (Roux-en-Y) was performed for biliary drainage. The child has improved but is not cured. The intrahepatic cysts are unchanged 1 year later.

JAL
WALL

or wall,
layer of
bile
artery.

t with a
junction
rows
angle
normal,
m was
ng the
distal
Dr




Figure 19-11 Operative cholangiogram in an infant with perforation of the common bile duct. Contrast medium injected into the gallbladder spills out into a biliary pseudocyst (straight arrows). A meniscus sign (curved arrow) in the distal common bile duct suggests a choledocholith. Resolution of the perforation, biliary pseudocyst, and "choledocholith" followed simple peritoneal drainage adjacent to the site of perforation.

the perforation, and the abdomen is closed. A cholecystostomy catheter is left in place so that healing of the perforation may be assessed postoperatively. Premature removal of the drains will lead to reaccumulation of bilious ascites.²⁷ Spontaneous closure of the ductal leak may take several weeks.

Surgical complications of perforation of the common bile duct are primarily due to overzealous surgery. In most cases, spontaneous closure of the leak and subsequent cure have followed simple drainage of the perforation.³² Attempts to close the perforation, drain the common bile duct, remove the ductal sludge, or bypass a mistakenly interpreted distal obstruction may lead to major biliary complications. An even more serious complication results from the misinterpretation of the biliary pseudocyst as a choledochal cyst. An intestinal anastomosis to the pseudocyst is usually lethal.

The overall experience with spontaneous perforation of the extrahepatic ducts in infants indicates that the lesion is self-limited and the sole error in ductal development. Thus, residual biliary tract disease or other sequelae would not be anticipated.

THE LIVER

There are few congenital malformations of the liver that necessitate surgical inter-

vention. The bulk of hepatic surgery in infants and children consists of resectional operations, usually for tumor and occasionally for trauma. The complications of resectional operations have a common pathogenesis irrespective of the original condition for which the surgery was performed.

Hepatic surgery in infants and children is not often indicated. When required, the operation most commonly consists of partial resection. In the most extreme case, complete removal and replacement of the liver with a cadaveric organ (orthotopic transplantation) may be performed.

Partial Hepatic Resections

Removal of part of the liver is done usually for tumors and occasionally for trauma. The basis for orderly subtotal resection of the liver is found in anatomic studies, which have been summarized.³³ For practical purposes, only four surgical units lend themselves to controlled excision (Fig. 19-12), including the right and left true lobes, which consist of two segments each. The third possibility is removal of the complete right lobe plus the medial segment of the left lobe. This operation (Fig. 19-12) is most correctly called right trisegmentectomy, although the term "extended right hepatic lobectomy" has frequently been used. The

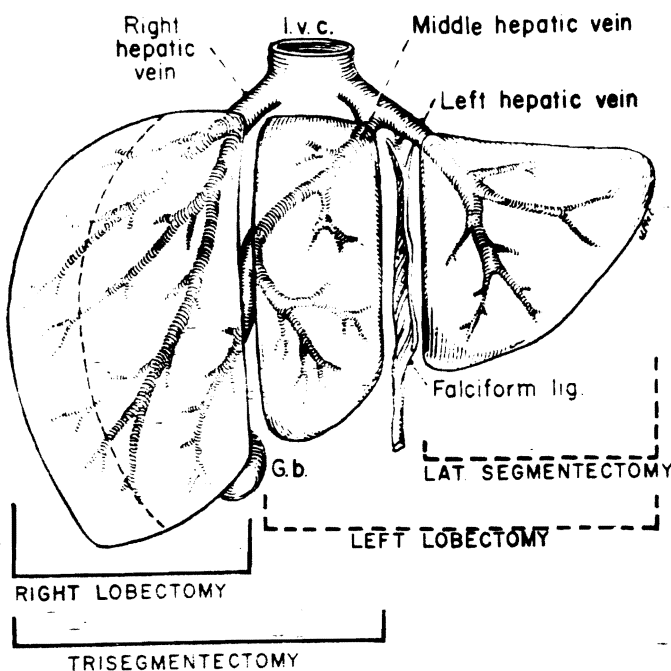


Figure 19-12 The usual kinds of partial hepatectomy. Note that there are only four common resections. (From Starzl, T. E., Bell, R. H., Beart, R. W., et al.: Hepatic trisegmentectomy or extended right lobectomy: Relation to other liver resections. *Surg. Gynecol. Obstet.* 141:429, 1975, by permission.)

fourth possibility is excision of the liver to the left of the falciform ligament. The removal of this single segment (Fig. 19-12) should be known as lateral segmentectomy instead of left lobectomy.

In infants and children, any of the four resections can be done through an abdominal incision (Fig. 19-13). The principles of the operations are simple.^{34, 37} They consist of preliminary ligation of the hilar structures going to the planned specimen (Fig. 19-14), early control of the drainage hepatic veins when possible, and transection of the hepatic parenchyma along exact intersegmental or interlobar planes (Fig. 19-15). Sometimes the huge size of right lobar tumors or invasion of the diaphragm by these tumors makes it impossible to obtain preliminary control of the right hepatic vein. In such cases, we have approached the right hepatic vein from within the right hepatic parenchyma (Fig. 19-15).³⁸

There are five complications after hepatic resections in children.^{9, 10, 28, 35, 38, 43} The most avoidable is injury to the triad structures that pass to the retained fragment. When the right three segments (trisegmentectomy) (Fig. 19-15) or the left lateral segment (Fig. 19-16) is removed, the anatomy in and around the plane of the falciform ligament (Fig. 19-16) must be understood

precisely. In the first instance, an injury to the hilar structures passing to the residual lateral segment would almost immediately be lethal (see Fig. 19-15). In the second instance, an injury to the medial segmental ("feedback") hilar structures during lateral segmentectomy (see Fig. 19-16) would cause a regional infarction. Sometimes only one structure is damaged, most commonly the hepatic duct to the liver remnant. We have performed liver transplantation 5 years after such an injury in a teenage girl who had been kicked by a horse, because repeated efforts to repair the severed duct had failed.

Even in modern times, hemorrhage has been the most common cause of death during and just after partial hepatic resection. That such a complication is unnecessary has been shown in our experience with 87 consecutive hepatic resections in adults and children. Although brisk bleeding was always encountered at the time of parenchymal transection, this promptly came under control after removal of the specimen. No matter how alarming the hemorrhage as the parenchyma was split, hemostasis was easily achieved because the plane of resection was anatomically correct. Secondary postoperative hemorrhage necessitating re-exploration was seen only once.

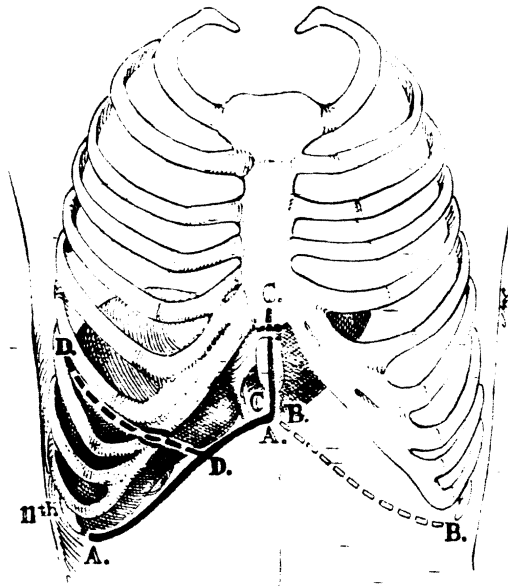


Figure 19-13 Approaches for trisegmentectomy and true right lobectomy. Note that several extensions may be made from the basic right subcostal incision, A to A, that is always used. More than one of the depicted extensions may be required in a given patient. For left hepatic lobectomy or lateral segmentectomy, mirror images of the extensions shown can be added to the basic left subcostal incision. In infants and children it is almost never necessary to have a thoracic component, since the mobility of the costal margin permits effective retraction. (From Starzi, J. E., Bell, R. H., Beart, R. W., et al.: Hepatic trisegmentectomy or extended right lobectomy: Relation to other liver resections. *Surg. Gynecol. Obstet.* 141:429, 1975, by permission.)

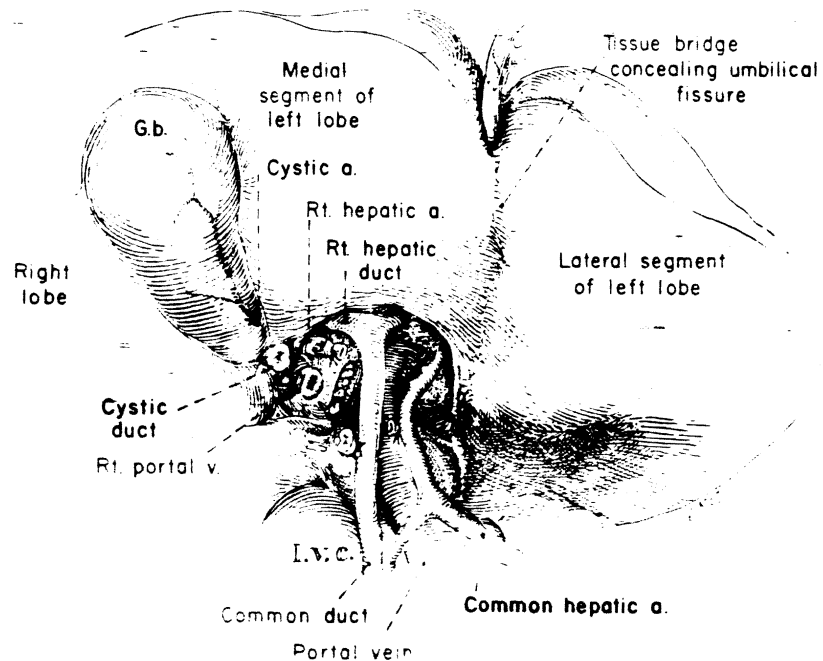


Figure 19-14 Devascularization of the true right lobe. The cystic artery and cystic duct are ligated and divided to aid in the dissection. Of the structures constituting the portal triad, the bifurcation of the common duct is almost always the most superior, the portal vein is intermediate, and the hepatic artery is most inferior. The lateral suture closure of the portal vein is at the site of detachment of the right portal branch. The tissue bridge conceals the umbilical fissure, behind which a finger can be inserted. The bridge is present in about half of all patients. (From Starzi, T. E., Bell, R. H., Beart, R. W., et al.: Hepatic trisegmentectomy or extended right lobectomy: Relation to other liver resections. *Surg. Gynecol. Obstet.* 141:429, 1975, by permission.)

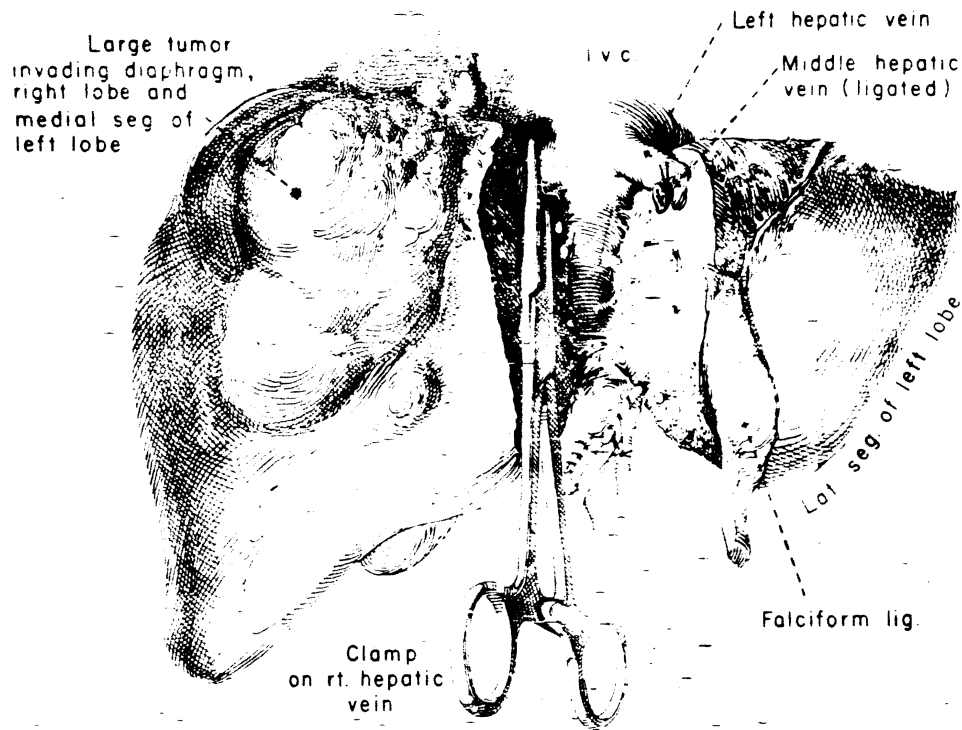


Figure 19-15 Control of right hepatic vein from within the liver. The technique may be required when large tumors prevent preliminary dissection and clamping of this vein. (From Starzl, T. E., Koep, L. J., Weil, R., et al.: Right trisegmentectomy for hepatic neoplasms. *Surg. Gynecol. Obstet.* 150:208, 1980, by permission.)

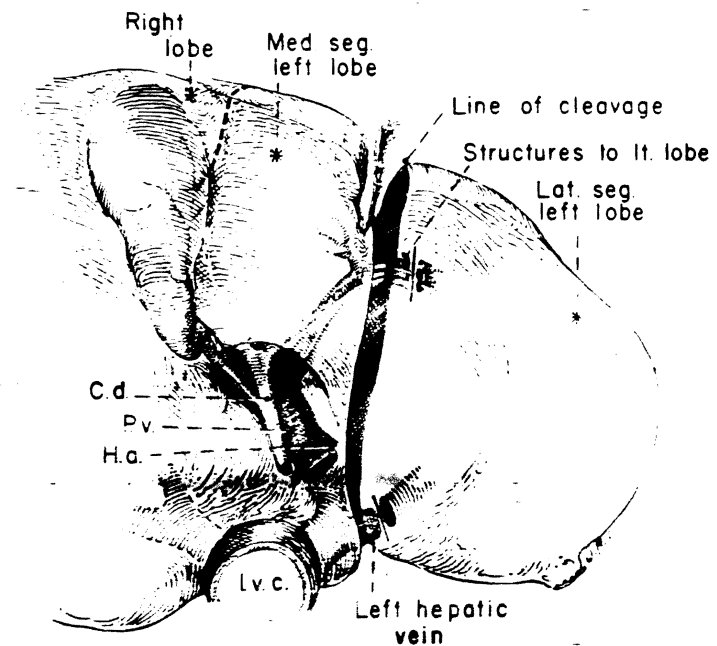


Figure 19-16 Site of ligation of portal structures for lateral segmentectomy. The dissection is kept to the left of the umbilical fissure to prevent injury to the structures feeding back from the fissure to the medial segment. (From Starzl, T. E., Bell, R. H., Beart, R. W., et al.: Hepatic trisegmentectomy or extended right lobectomy: Relation to other liver resections. *Surg. Gynecol. Obstet.* 141:129, 1975, by permission.)

and may be that is ns may my or ensions sion. In ve a margin . R. H., tended Surg.

d to aid avs the eportal vchic a et al.: Obstet.

Two historically important causes of death, air embolism and hypothermia, have essentially been eliminated by improvements in anesthesia. The air emboli originated from cut hepatic veins and were sucked into the circulation in patients whose diaphragm was intact and whose anesthesia was light enough to permit respiratory efforts. The combination of adequate depth of anesthesia and end-expiratory positive pressure ventilation has prevented air embolism in our experience. Intraoperative temperature control is important because infants and children may be poikilothermic.

Aside from hemorrhage, the most frequently fatal complication in modern times has been regional infection. To avoid this, the cavities caused by major resections must be adequately drained. We often achieve this by leaving open a portion of the wound through which eight to 12 1-inch Penrose drains are inserted (Fig. 19-17). Two or 3 days after operation the drains are removed and daily irrigations of the cavity are begun. The cavity is allowed to close in from the bottom over several weeks. In spite of these precautions, abscesses in residual subphrenic cavities have required later drainage in about 10 per cent of our patients following right lobectomy or right trisegmentectomy. Occasionally, partial evisceration through the drain tracts may require control by packing. In one of our patients it was necessary to carry out formal repair of an incisional hernia at this site.

With right and left true lobectomy and with lateral segmentectomy, jaundice should not occur postoperatively, nor should there be any major disturbances of liver function, provided that the retained liver tissue is normal. In contrast, all patients become jaundiced after right trisegmentectomy (Fig. 19-18). The residual 10 to 30 per cent of liver represented by the lateral segment begins prompt regeneration, and completely normal liver function can be expected within a few days.

There should be no later functional sequelae following successful hepatic resection. The special question of late morbidity following trisegmentectomy was recently examined in 30 patients.³⁶ Only one death (3 per cent) occurred in the hospital or within the first 2 postoperative months. Those who survived for longer periods, including four

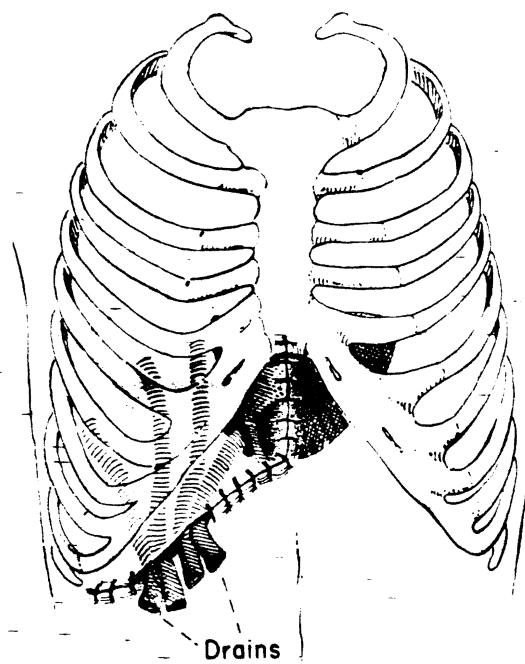


Figure 19-17 Wound drainage after trisegmentectomy. Usually either the medial or the lateral portion of the wound is kept open 3 or 4 inches. (From Starzl, T. E., Bell, R. H., Beart, R. W., et al.: Hepatic trisegmentectomy or extended right lobectomy: Relation to other liver resections. *Surg. Gynecol. Obstet.* 141:129, 1975, by permission.)

who had benign lesions, had completely normal results of liver function tests when followed up as long as 9 years after resection.

Pediatric patients with malignant neoplasms should be strongly considered for adjuvant chemotherapy. Although postoperative treatment with drugs and irradiation has been said to be worthless, we have made a case for using these modalities.³⁸ Eight of our children with very advanced neoplasms were treated after trisegmentectomy with cyclophosphamide, vincristine, and 5-fluorouracil to which doxorubicin (Adriamycin) was frequently added. Seven of these eight patients are still alive 1 to 6½ years after operation, a record of survival hard to envision with treatment of such unfavorable lesions by surgery alone.

The safety of major hepatic resections has increased our willingness to perform such procedures, which at one time were viewed as heroic. Only one death, that of an elderly woman, has occurred among the last 90

19 y/o ♀

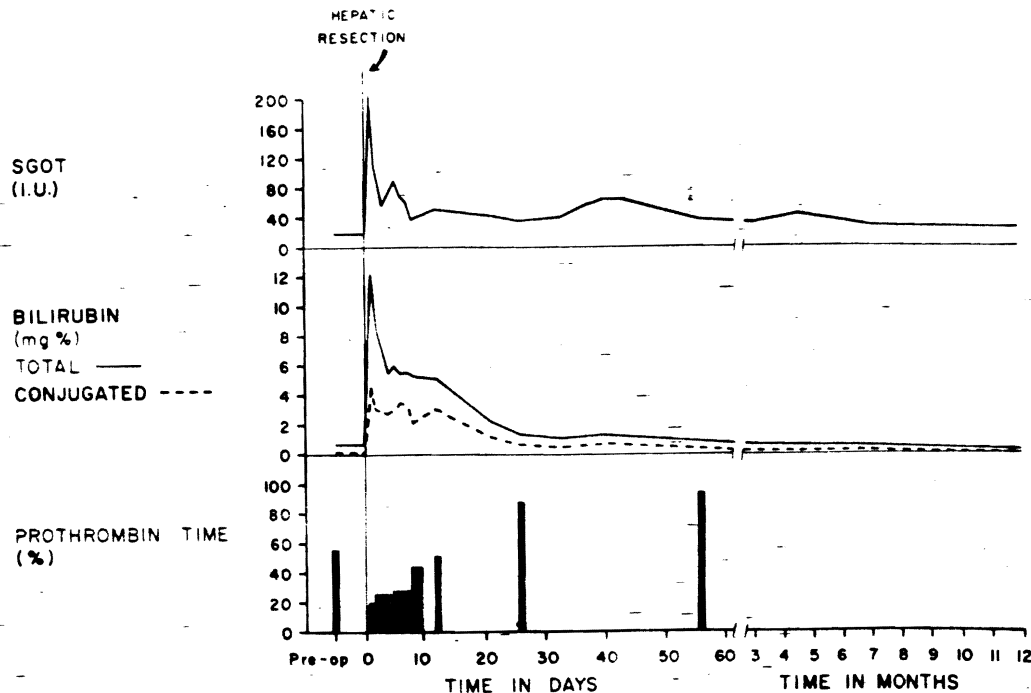


Figure 19-18 Postoperative course after trisegmentectomy. The elevated bilirubin level and the depressed prothrombin time returned to normal in about 1 month. (From Starzl, T. E., Putnam, C. W., Groth, C. G., et al.: Alopecia, ascites, and incomplete regeneration after 85 to 90 per cent liver resection. *Am. J. Surg.* 129:587, 1975.)

patients treated by resection, 37 of whom were given right trisegmentectomies. Exceptionally low mortality has been reported by other surgeons as well.^{9, 10, 28, 43}

Liver Transplantation

The ultimate extirpative procedure is orthotopic liver transplantation, an approach now rarely used to treat otherwise nonresectable malignant tumors. The tumors have recurred with such regularity after liver replacement that the potential value of transplantation has been vitiated.^{36, 37} Interestingly, the tumors have reappeared in the graft itself.

In a recent summary of the indications for liver replacement in children, the leading indication was biliary atresia.³⁷ This diagnosis accounted for 48 of the first 74 pediatric liver replacements. Chronic aggressive hepatitis was a distant second. An especially interesting group of patients had

inborn errors of metabolism (Wilson's disease, alpha₁-antitrypsin deficiency, Type IV glycogen storage disease, and tyrosinemia) that were cured by the provision of phenotypically normal livers.^{36, 37}

Although much progress has been made in liver transplantation, the procedure has not yet provided predictable and reliable results. In our own experience and that of Calne and Williams,⁵ the results have improved during the last few years, but at best we have been able to achieve only a 50 per cent 1-year patient survival.^{36, 37}

Many of the lethal complications of liver transplantation have derived directly from or have been made worse by immunosuppression, which is necessary for any kind of homotransplantation. However, an extensive list of nonimmunologic complications has been recorded.^{5, 36, 37} These have included biliary tract obstruction and/or fistulae, enteric fistulae, thrombosis of the homograft and host vessels, unknowing use of irreversibly damaged organs, air emboliza-

tion from the large veins of the homograft, crushing and paralysis of the recipient right phrenic nerve, venous infarction of the right adrenal gland, postoperative gastrointestinal hemorrhage, and pancreatitis, to provide a very incomplete listing. In addition, hepatitis caused by hepatitis B surface antigen, adenovirus, cytomegalovirus, and herpesvirus have been shown to cause post-operative homograft dysfunction that has sometimes been so severe and acute as to cause death.

The avoidance of these many problems and their treatment when they occur have been discussed extensively elsewhere.^{5, 34, 36, 37} The management principles are much the same as for immunologically normal patients, but the margin of permissible error is much smaller or may be nonexistent in recipients under immunosuppression. The interested reader should refer to specialty publications^{5, 34, 36, 37} to obtain insight into the complex problems that can result from such a massive surgical procedure in metabolically and immunologically depleted patients.

References

1. Alagille, D.: Long-term results of hepatic portoenterostomy. In Javitt, N. B. (ed.): *Neonatal Hepatitis and Biliary Atresia*. DHEW Publication No. (NIH) 79-1296. Washington, D.C., U.S. Government Printing Office, 1979.
2. Altman, R. P., Chandra, R., and Lilly, J. R.: Ongoing cirrhosis after successful porticoenterostomy in infants with biliary atresia. *J. Pediatr. Surg.* 10:685, 1975.
3. Barkin, R. M., and Lilly, J. R.: Biliary atresia and the Kasai operation: Continuing care. *J. Pediatr.* 96:4015, 1980.
4. Bill, A. H., Haas, J. E., and Foster, G. L.: Biliary atresia: Histopathologic observations and reflections upon its natural history. *J. Pediatr. Surg.* 12:977, 1977.
5. Calne, R. Y., and Williams, R.: Liver transplantation. *Curr. Prob. Surg.* 16:1, 1979.
6. Danks, D. M., Campbell, P. E., Clarke, A. M., et al.: Extrahepatic biliary atresia. The frequency of potentially operable cases. *Am. J. Dis. Child.* 128:684, 1974.
7. Flanigan, D. P.: Biliary cysts. *Ann. Surg.* 182:635, 1975.
8. Flanigan, D. P.: Biliary carcinoma associated with biliary cysts. *Cancer* 40:880, 1976.
9. Fortner, J. G., Dong, K. K., MacClean, B. J., et al.: Major hepatic resection for neoplasia. *Ann. Surg.* 188:363, 1978.
10. Foster, J. H.: Survival after liver resection for cancer. *Cancer* 26:493, 1970.
11. Hirsig, J., Kara, O., and Rickham, P. P.: Experimental investigations into the etiology of cholangitis following operation for biliary atresia. *J. Pediatr. Surg.* 13:55, 1978.
12. Hitch, D. C., and Lilly, J. R.: Identification, quantification, and significance of bacterial growth within the biliary tract after Kasai's operation. *J. Pediatr. Surg.* 13:563, 1978.
13. Izant, R. J., Jr., Akers, D. R., Hays, D. M., et al.: Biliary atresia survey. Surgical Section, American Academy of Pediatrics, 1965.
14. Kasai, M., Asakura, Y., and Taira, Y.: Surgical treatment of choledochal cyst. *Ann. Surg.* 182:844, 1970.
15. Kasai, M., Kimura, S., Asakura, Y., et al.: Surgical treatment of biliary atresia. *J. Pediatr. Surg.* 3:665, 1968.
16. Kasai, M., Watanabe, I., and Ohi, R.: Follow-up studies of long-term survivors after hepatic portoenterostomy for "noncorrectable" biliary atresia. *J. Pediatr. Surg.* 10:173, 1975.
17. Landing, B. H.: Considerations of the pathogenesis of neonatal hepatitis, biliary atresia, and choledochal cyst. The concept of infantile obstructive cholangiography. In Bill, A. H., and Kasai, M. (eds.): *Progress in Pediatric Surgery*, Vol. 6. Baltimore, University Park Press, 1974, p. 113.
18. Lilly, J. R.: The surgery of biliary hypoplasia. *J. Pediatr. Surg.* 11:815, 1976.
19. Lilly, J. R.: Total excision of choledochal cyst. *Surg. Gynecol. Obstet.* 146:254, 1978.
20. Lilly, J. R.: Hepatic portocholecystostomy for biliary atresia. *J. Pediatr. Surg.* 14:301, 1979.
21. Lilly, J. R.: The surgical treatment of choledochal cyst. *Surg. Gynecol. Obstet.* 149:36, 1979.
22. Lilly, J. R.: Surgery of coexisting biliary malformations in choledochal cyst. *J. Pediatr. Surg.* 14:643, 1979.
23. Lilly, J. R.: Treatment of esophageal variceal hemorrhage by endosclerosis. *Surg. Gynecol. Obstet.* (in press).
24. Lilly, J. R., and Javitt, N. B.: Biliary lipid excretion after hepatic portoenterostomy. *Ann. Surg.* 184:369, 1976.
25. Lilly, J. R., and Starzl, T. E.: Liver transplantation in children with biliary atresia and vascular anomalies. *J. Pediatr. Surg.* 9:707, 1974.
26. Lilly, J. R., Terblanche, J., and Silverman, A.: Sclerotherapy of esophageal varices in children. *Gastroenterology* 75:974, 1978.
27. Lilly, J. R., Weintraub, W. H., and Altman, R. P.: Spontaneous perforation of the extrahepatic bile ducts and bile peritonitis in infancy. *Surgery* 75:664, 1974.
28. Lin, T.: Recent advances in technique of hepatic resections and results of surgical treatment for primary carcinoma of the liver. *Prog. Liver Dis.* 5:668, 1976.
29. Longmire, W. P.: Congenital biliary hypoplasia. *Ann. Surg.* 159:335, 1964.
30. Ohi, R., Shikes, R. H., and Lilly, J. R.: Bile duct remnants in biliary atresia. *Ann. Surg.* (in press).
31. Popper, H., and Schaffner, F.: *Liver: Structure and Function*. New York, McGraw-Hill Book Co., The Blakiston Division, 1957, Chap. 20.
32. Prevot, J., and Babut, J. M.: Spontaneous perfora-

- tions of the biliary tract in infancy. *Prog. Pediatr. Surg.* 3:187, 1971.
33. Saito, S., and Ishida, M.: Congenital cyst (cystic dilatation of the common bile duct). *In* Bill, A. H., and Kasai, M. (eds.): *Progress in Pediatric Surgery*, Vol. 6. Baltimore, University Park Press, 1974, p. 63.
34. Starzl, T. E. (with the assistance of Putnam, C. W.): *Experience in Hepatic Transplantation*. Philadelphia, W. B. Saunders Co., 1969.
35. Starzl, T. E., Bell, R. H., Beart, R. W., et al.: Hepatic trisegmentectomy or extended right lobectomy: Relation to other liver resections. *Surg. Gynecol. Obstet.* 141:429, 1975.
36. Starzl, T. E., Koep, L. J., Halgrimson, C. G., et al.: Fifteen years of clinical liver transplantation. *Gastroenterology* 77:375, 1979.
37. Starzl, T. E., Koep, L. J., Schroter, G. P. J., et al.: Liver replacement for pediatric patients. *Pediatrics* 63:825, 1979.
38. Starzl, T. E., Koep, L. J., Weil, R., et al.: Right trisegmentectomy for hepatic neoplasms. *Surg. Gynecol. Obstet.* 150:208, 1980.
39. Starzl, T. E., Putnam, C. W., Groth, C. G., et al.: Alopecia, ascites, and incomplete regeneration after 85 to 90 per cent liver resection. *Am. J. Surg.* 129:587, 1975.
40. Tsuchida, Y., and Ishida, M.: Dilatation of the intrahepatic bile ducts in congenital cystic dilatation of the common bile duct. *Surgery* 69:776, 1971.
41. Tsuchiya, R., Harada, N., Ito, T., et al.: Malignant tumors in choledochal cysts. *Ann. Surg.* 186:22, 1977.
42. Valayer, J.: Hepatic porto-enterostomy. *Surgical problems and results. In* Berenberg, S. R. (ed.): *Liver Diseases in Infancy and Childhood*. The Hague, Martinus Nijhoff Medical Division, 1976.
43. Wilson, S. M., and Adson, M. A.: Surgical treatment of hepatic metastases from colorectal cancers. *Arch. Surg.* 111:330, 1976.