

394

Partial Resections of the Liver

Thomas E. Starzl, M.D., Ph.D.

Department of Surgery, Veterans Administration Hospital and
University of Colorado Medical Center, Colorado

and

Charles W. Putnam, M.D.

Department of Surgery, Veterans Administration Hospital and
University of Colorado Medical Center, Colorado

INTRODUCTION

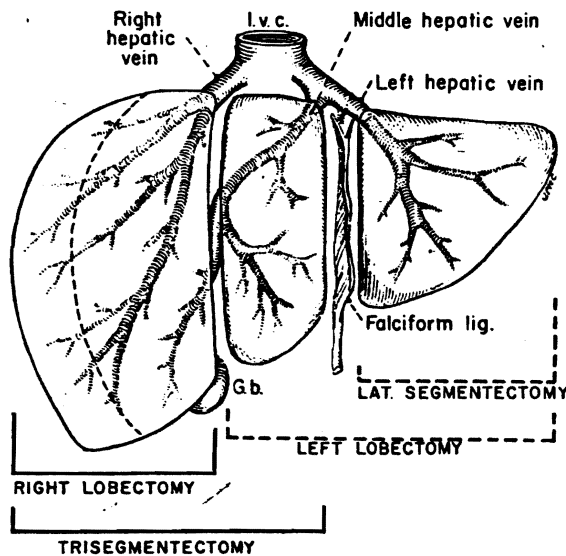
Excision of a portion of the liver has been known to be feasible for more than 100 years. By 1899 the Philadelphia surgeon W. Keen was able to collect 73 examples of hepatic resection from the literature and to add three more of his own (Keen, 1899).

However, most if not all of these early extirpations were limited ones, and were performed with inadequate knowledge of liver lobar and segmental anatomy as this is understood today. The modern age of hepatic resection had to wait for a better understanding of gross liver structure along with improvements in surgical, anaesthetic and transfusion techniques.

SURGICAL ANATOMY

The basis for orderly subtotal resection of the liver is found in anatomical studies which were published a quarter of a century apart. The first of these influential reports was by McIndoe and Counseller in 1927. They proved that the division between the true right and left lobes of the liver was not at the falciform ligament, as had been previously believed, but rather at a line through the bed of the gall-bladder and projecting posteriorly toward the vena cava. From 1950 to 1954, Hjortsjö (1950), Healey, Jr. (1954) and

Healey, Jr. and Schroy (1953) demonstrated that each true lobe was further divided into two segments. The portal venous, hepatic arterial, and hepatic duct branches conformed to the four-segment organization. These observations were confirmed and extended by Couinaud (1957) and Goldsmith and Woodburne (1957). The larger hepatic veins were distributed differently since a number of their important ramifications are between rather than within segments and lobes.



(By kind permission of *Surgery Gynec. Obstet.* 141, 429, 1975)

1

Usual kinds of partial hepatectomy

For practical purposes, there are only four surgical blocks of hepatic tissue that lend themselves to controlled excision: the right and left true lobes which consist of two segments each. A third possibility is to resect the liver to the left of the falciform ligament—a single segment and its removal should be termed lateral segmentectomy instead of left lobectomy. Fourth, the complete right lobe plus the medial segment of the left lobe may be removed. We have called this operation trisegmentectomy (Starzl *et al.*, 1975) although the term of Pack, Miller and Brasfield (1955) of extended right hepatic lobectomy has been more frequently used.

In the descriptions that follow, much of the emphasis will be placed on the most demanding operation of trisegmentectomy. Once the procedure of trisegmentectomy is understood, the other three common hepatic resections can be described in terms of variations on the same theme and with employment of the same principles.

PRE-OPERATIVE EVALUATION

A patient presenting with a hepatic mass should have studies to determine the nature of the lesion, and its extent within or outside the liver. Primary hepatic tumours may manifest as asymptomatic or symptomatic masses in the liver area, or by a variety of other symptoms or findings including those of distant metastases. A liver scan will help define the extent of the lesion. Since more than 90 per cent of hepatic tumours are metastatic, it is important to search for a primary cause elsewhere. Gastro-intestinal series, barium enema, intravenous urogram, and metastatic surveys of the chest and bones are usually indicated.

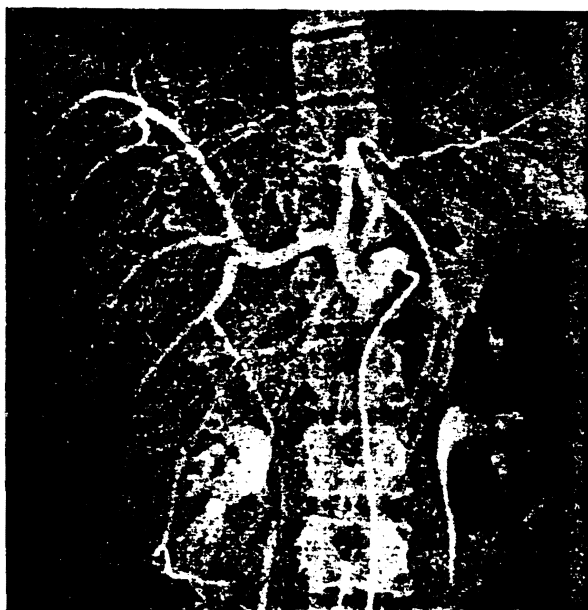
In all patients with hepatic masses the presence

and amount of alpha fetoprotein (a protein of the alpha₁-globulin class which is synthesized by undifferentiated hepatoma cells and which is found in the serum of 30-90 per cent of patients with liver cell carcinoma) should be assessed. False positive tests from hepatic metastases have been documented in only a few paediatric patients with primary embryonal malignant lesions. Thus, not only does a positive test strongly support the diagnosis of a primary liver cell carcinoma, but later quantitative determinations are of great help in following the progress and effectiveness of treatment (Alpert, Uriel and de Nechaud, 1968).



*99m Technetium liver scan (anteroposterior projection) showing the very large filling defect
(By kind permission of Am. J. Surg. 129, 587, 1975)*

2a



2b

2a & b

Radiographic study showing large hepatic adenoma

Unless some reason has been found with these studies not to proceed, angiographic study of the hepatic arterial supply is performed. Transhepatic and retrograde (transduodenal) cholangiography are very useful procedures if jaundice is a symptom.

The diagnosis of an isolated hepatic metastasis after the resection of a primary malignancy elsewhere is apt to result either from careful follow-up physical examination or from serial liver scans. The role of resection for isolated metastases to the liver has been controversial since its advocacy by Brunschwig (1963); however, the use of this aggressive approach, especially for metastases from colon cancer, has been strongly supported by the recent reports of Flanagan, Jr. and Foster (1967) and of Wilson and Adson of the Mayo Clinic (1976).

Selective common hepatic arteriogram. The broad arrows indicate the extent of the tumour as outlined by the abnormal configuration of vessels. The thin arrow points to the dorsolateral branch of the left hepatic artery. This vessel, supplying the lateral segment of the left lobe, was the only hepatic arterial branch preserved

(By kind permission of Am. J. Surg. 129, 587, 1975)

TRISEGMENTECTOMY (EXTENDED RIGHT HEPATIC LOBECTOMY)

The first to successfully remove all of the liver located to the right of the falciform ligament, or about 80–85 per cent of the organ, were Wangenstein (1951), Lortat-Jacob and Robert (1952) and Quattlebaum (1953). The initial enthusiasm for the procedure, which became known as extended right hepatic lobectomy, was apparently dampened by a heavy mortality rate in the early trials of its use by Brunschwig (1955) and by others. Although Pack and Molander (1960) and Miller (1974) acquired experience with more than 40 patients in the ensuing two decades, large collections were not reported by others until a recent series from our unit (Starzl *et al.*, 1975).

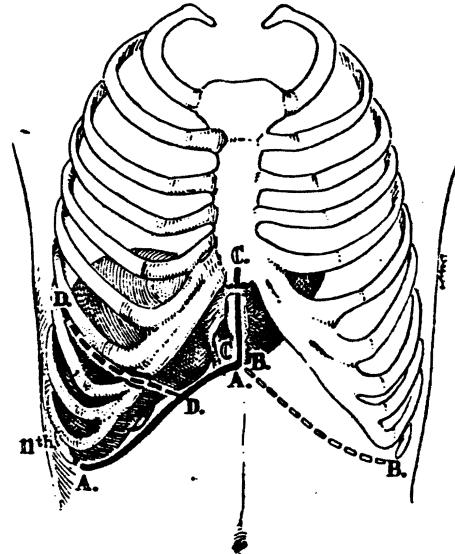
3

The incisions

A right subcostal incision (A to A) is always used, often with the extension shown. Additional exposure may be obtained by continuing superiorly in the midline, particularly if the xiphoid process is removed. The incision may be carried across into the left subcostal area. If a thoracic extension is decided upon, the incision used by Quattlebaum (1953) permits a better view of the suprahepatic inferior vena cava and right hepatic vein, and it allows the triangular and coronary ligaments to be incised under direct vision.

Most authors have considered a thoraco-abdominal incision to be obligatory for right hepatic lobectomy or trisegmentectomy. The authors' experience has been that a thoracic component is almost never needed in children under the age of 12 years and that it is usually not required in adults. For this reason, a thoracic extension is not made unless the need for it becomes evident during the early steps of dissection described subsequently. If a thoracic extension is made, the incision in the diaphragm is carried only half way from its periphery to the vena cava rather than completely to the vena cava as has usually been advocated.

After exposing the liver and ruling out the possibility of extrahepatic metastases, a decision is made about the size of the resection and a plan is developed for the steps of dissection. The sequence of the



(By kind permission of *Surgery Gynec. Obstet.* 141, 429, 1975)

operation may vary from patient to patient depending upon the location and size of the lesion. Usually, the right triangular and coronary ligaments are incised and the bare area is broadly entered. By so doing, it becomes possible to elevate the right lobe into the wound and to retract it toward the left when this manoeuvre becomes desirable at a later time. The inability to mobilize the liver safely at this time or difficulty visualizing the entrance of the right hepatic vein into the inferior vena cava is the main reason to consider a thoracic extension. Having settled upon the final incision and having completed the preliminary right lobar mobilization, attention is turned to the hilus. During all of these manoeuvres, the falciform ligament and ligamentum teres are usually not cut, and if possible, they are retained throughout the operation.

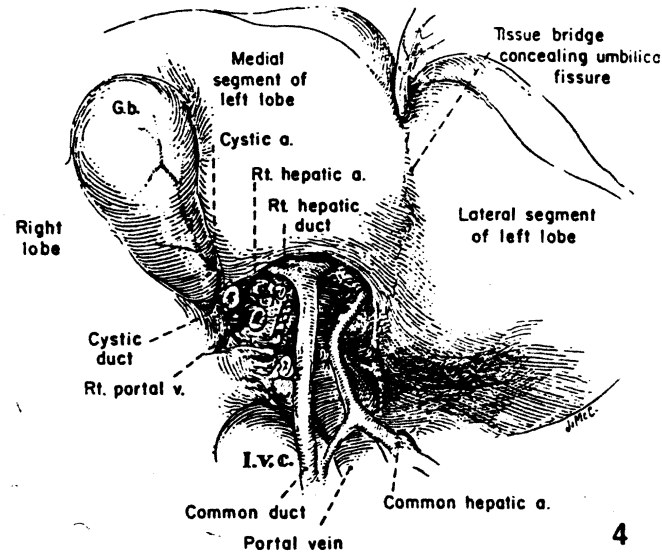
Dissection of the hilus

4

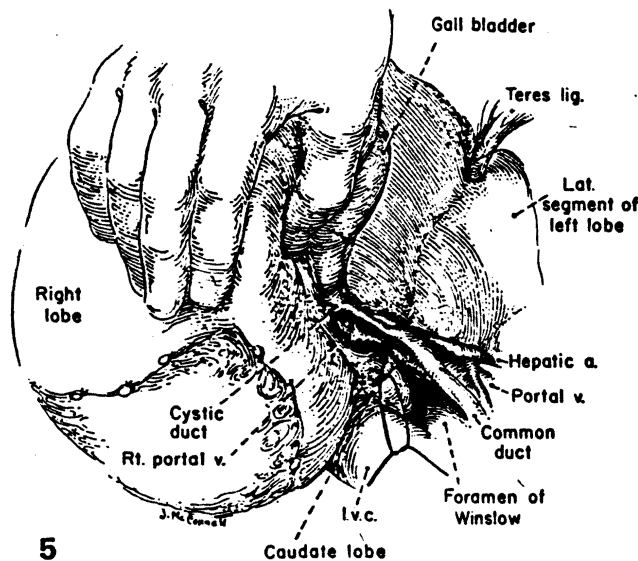
The necessary first step in trisegmentectomy is ligation and division of the cystic artery and duct. The cystic artery normally arises from the right hepatic artery. The right branches of the structures of the portal triad are now isolated.

The right hepatic artery is sacrificed first. As already noted, the dissection for trisegmentectomy is greatly facilitated by prior knowledge of the arterial blood supply of the liver obtained with pre-operative aortography or selective coeliac arteriography. In performing this examination, it is especially important to be certain of the origin of the arterial supply to the lateral segment of the left lobe, which is to be retained. Normally, the right hepatic artery originates from the proper hepatic artery and passes posterior to the common duct. However, arterial anomalies are so numerous that ligation should never be performed without preliminary test occlusion or without being sure that during this occlusion there are pulsations distally in the region of the umbilical fissure.

At a more superior level, the right branch of the portal vein is detached, and the defect is closed with continuous 6/0 arterial suture.



(By kind permission of *Surgery Gynec. Obstet.* 141, 429, 1975)



(By kind permission of *Surgery Gynec. Obstet.* 141, 429, 1975)

5

If any difficulty is encountered, the portal vein can easily be approached posteriorly, by retracting the right lobe of the liver anteriorly and to the left. The posterior approach is especially helpful if venous branches emanate from the back of the portal bifurcation, as is often the case. After dividing the right hepatic artery and the right portal vein, a line of demarcation between the true right and left lobes, passing through the gall-bladder and directed toward the vena cava, as described in the corrosion cast studies of McIndoe and Counseller (1927), is evident.

Invariably, the most superior bifurcation is the common duct (see *Illustration 4*), which is sometimes within the substance of the liver. The right duct is ligated and divided where it comes off almost like a crossbar of a T.

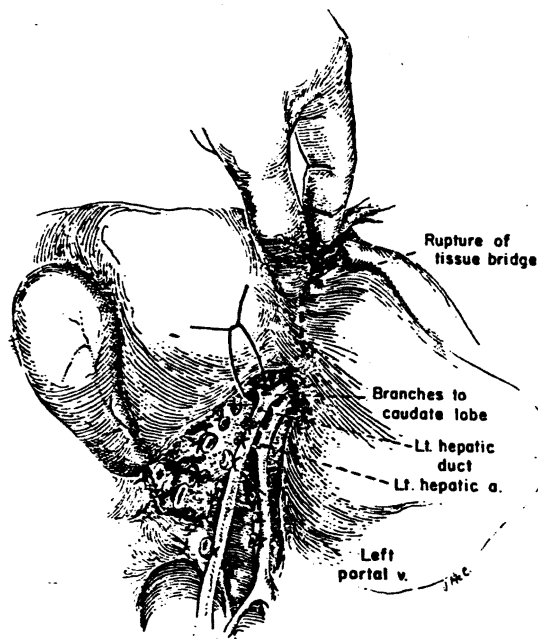
6&7

Dissection of the left branches

Before beginning this phase of the operation, the exact location of the umbilical fissure must be determined. In many human livers, the umbilical fissure is concealed by a fusion of the inferior lips of the medial and lateral segments of the left lobe. Even if the fusion is complete and involves a large surface, it can readily be opened with finger fracture since no large structures pass through it. In the base of the opened field lie the distal portions of the portal triad structures.

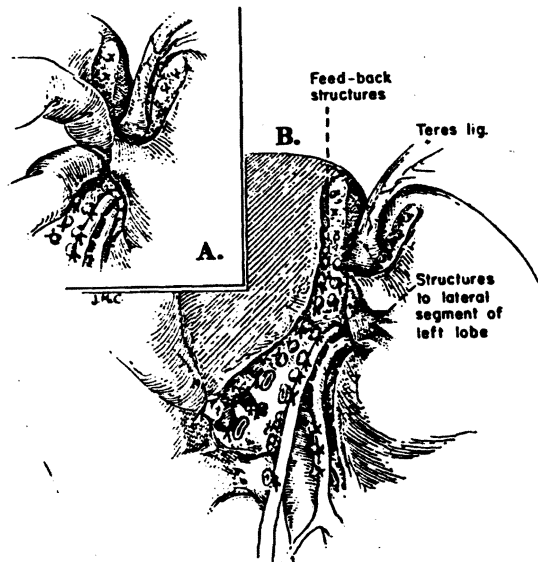
The left branches of the triad structures, which are several centimetres in length, are dissected completely free from the under-surface of the liver. The portion of the left portal vein is called the pars transversa, and usually gives off several small branches to adjacent liver tissue. These fine ramifications are doubly ligated and divided. Small ducts and arteries which parallel the venous branches must be dealt with. If there is an anomalous artery to the entire left lobe or to the lateral segment arising from the coeliac axis or from the left gastric artery, such an aberrant vessel almost always enters the base of the umbilical fissure considerably to the left of the field of dissection of the pars transversa and the left hepatic duct. This anomaly, if recognized, is a technical advantage since its presence virtually eliminates the danger of dearterializing the lateral segment remnant.

The leftward mobilization of the left portal structures is stopped short of the umbilical fissure for the reasons to be discussed in the section on transection of the liver. The last two major branches before the fissure is reached pass posteriorly to the left portion of the caudate lobe. If a decision is made to sacrifice these branches (see *Illustration 6*), the caudate lobe will be devascularized and ideally then should be removed in its entirety from the surface of the inferior vena cava and from its junction with the lateral segment. Such total caudate lobe removal will usually leave the lateral segment drained by a single vein, the left hepatic vein. If the final posterior branches of the left triad structures going to the caudate lobe are retained, as the authors believe is the usual practice in trisegmentectomy, the intrinsic risk of the operation is undoubtedly reduced. However, in several of the authors' patients, total caudate extirpation has been necessary to obtain complete tumour removal.



6

(By kind permission of *Surgery Gynec. Obstet.* 141, 429, 1975)



7

(By kind permission of *Surgery Gynec. Obstet.* 141, 429, 1975)

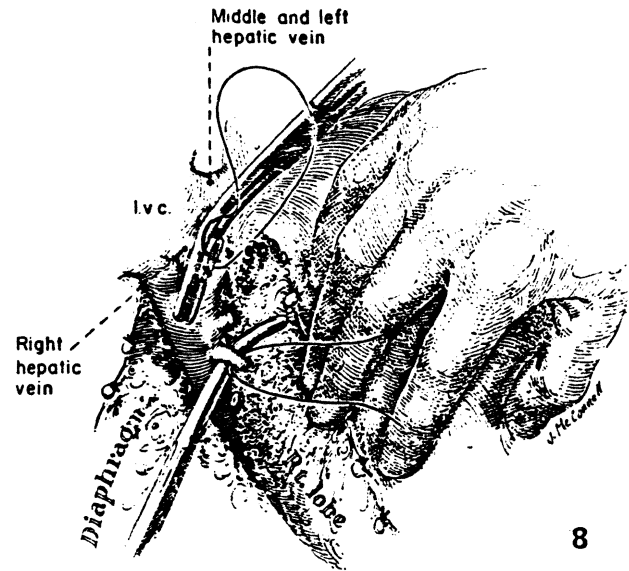
8

Hepatic veins

At this point or in some instances at an earlier stage of the operation, the right hepatic vein is encircled by cautious dissection as the right lobe is retracted. The vein is doubly clamped with angled paediatric Pott's clamps, divided and sewed shut on both sides with continuous vascular suture. This manoeuvre is potentially dangerous because the hepatic vein is extremely short and because a tear during the dissection would create a defect in the side of the vena cava that would be difficult to control or repair. A number of more inferior, smaller hepatic veins entering the anterior surface of the retrohepatic inferior vena cava are also ligated and divided. As noted earlier, all vena caval tributaries except the left hepatic vein are ligated and divided if the caudate lobe is to be totally excised.

'Feedback structures' to the medial segment

The crucial step in trisegmentectomy is the identification of the complex of venous, arterial and duct structures that originate in the umbilical fissure and feedback from the main left trunks to the medial segment of the left lobe. Although these originate in the umbilical fissure, they are not dissected there. Instead, the feedback structures are found just to the right of the falciform ligament within the substance of the liver (*see Illustration 7*). The parenchyma of the liver can be crushed down to them, either with clamps and ligatures or with the fingers (*see Illustration 7A*). Only with the occlusion of the contained vessels does the medial segment become cyanotic.



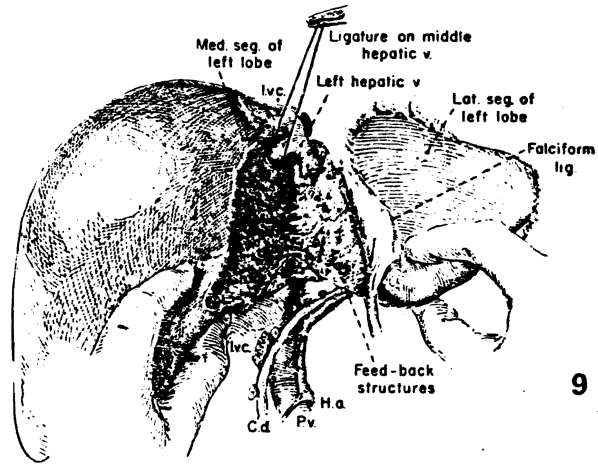
(By kind permission of *Surgery Gynec. Obstet.* 141, 429, 1975)

The feedback blood supply and duct drainage of the medial segment were not evident in the pioneer studies of Healey, Jr. (1954) and Healey, Jr. and Schroy (1953). However, this feature was accurately noted by Goldsmith and Woodburne (1957), who cautioned, in connection with lateral segmentectomy, that dissection in the umbilical fissure should be avoided for fear of injuring vessels and ducts passing to the retained medial segment. Cognizance has not been taken of their warning by most subsequent authors.

9

The liver transection

With all three segments devascularized, the liver is split toward the diaphragm at the exact line of colour demarcation. We do not develop a parasegmental line of transection, which leaves a centimetre or so of devitalized tissue, as has been commonly advocated. Knife handles, clamps and ligatures can be used to crush down to intersegmental strands, as described by Quattlebaum (1953) or else the finger fracture method of Lin, Chen and Liu (1960) may be preferable. If the line of transection is in the appropriate place, good-sized intersegmental veins are soon encountered. These are pushed toward the lateral segment, preserved when possible, and used as a guide to further cleavage. Near the diaphragm, the middle hepatic vein (see *Illustration 1*) is ligated. It either enters the inferior vena cava separately or more commonly joins the left hepatic vein to form a short common trunk. The liver transection is facilitated by grasping the edges of the hepatic fragments and pulling them down and by pushing down the right lobe with the flat of the operator's left hand, which is placed in the subphrenic space on the diaphragmatic surface of the liver. As the liver is split, anaesthesia should be deep enough to prevent spontaneous respiratory efforts. If the diaphragm is intact, the negative intrathoracic pressure with breathing could result in air embolus.



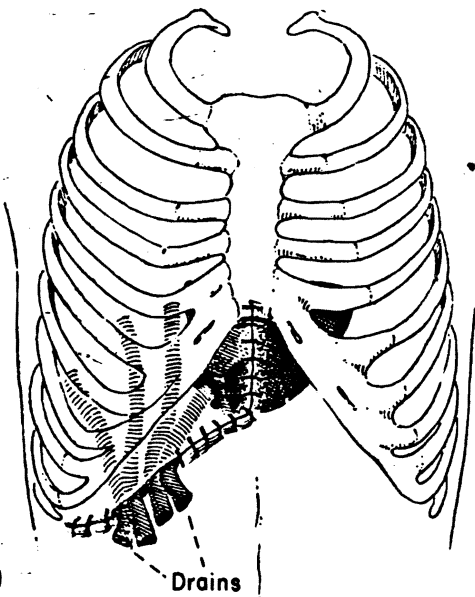
(By kind permission of *Surgery Gynec. Obstet.* 141, 429, 1975)

After removal of the specimen, the raw surface of the residual lateral segment is pink and well vascularized. It is usually remarkably dry. Since residual bleeders are not covered by dead tissue, they can easily be identified and suture ligated. Large intersegmental veins which are visible at the plane of transection are protected during the check for haemostasis. No effort is made to cover the raw surface with living tissue or with haemostatic materials.

10

Importance of drainage and other care

T-tubes are not used. However, the huge right subphrenic dead space must be perfectly drained. To achieve this, a portion of the wound 3–5 inches (7.5–12.5 cm) in length is usually left open. Five to ten 1 inch (2.5 cm) drains are brought out through the wound. A gauze strip impregnated with antibiotics is packed into the wound more superficially to prevent evisceration through the large drain area. This is removed after 48–72 hr, and twice daily irrigations of the cavity are begun. Within a day or so, the drains are also removed.



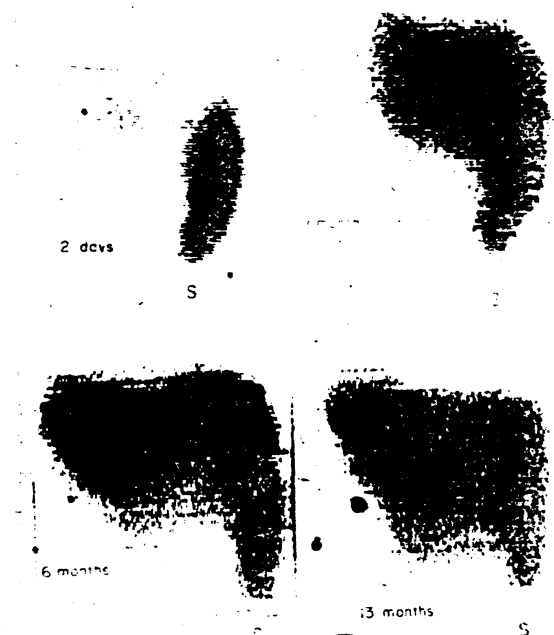
(By kind permission of *Surgery Gynec. Obstet.* 141, 429, 1975)

11

Regeneration

As this occurs the cavity rapidly becomes smaller. Within 2 or 3 weeks, the patient can be discharged with instructions for self-irrigation of the sinus tract. After 4-8 weeks, all wounds are totally healed.

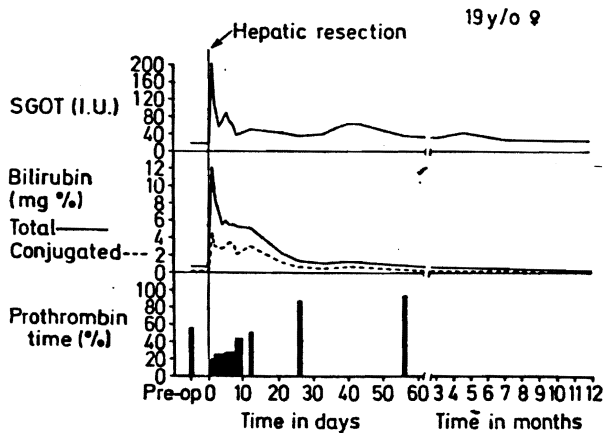
Other aspects of postoperative care are beyond the scope of this chapter, but in essence they are supportive. Antibiotics are started before operation and continued for several days after. Human albumin is frequently given for a few days postoperatively.



Serial postoperative 99m technetium liver scans after trisegmentectomy for adenoma. Two days, only a tiny fragment of the liver is visualized; the spleen (S) has enlarged in comparison with the pre-operative study. One month, regeneration has begun. Six months, further regeneration has occurred. Thirteen months, the hepatic mass has increased slightly in the intervening 7 months, but regeneration remains incomplete

(By kind permission of Am. J. Surg. 129, 587, 1975)

11



(By kind permission of Am. J. Surg. 129, 587, 1975)

12

12

Jaundice in the postoperative patient

All patients with trisegmentectomy become jaundiced, as described by Pack and Molander (1960), but this finding begins to recede in 7 or 10 days. It has been unusual for the patient not to be able to resume a diet within 3 or 4 days.

TRUE RIGHT OR LEFT LOBECTOMY

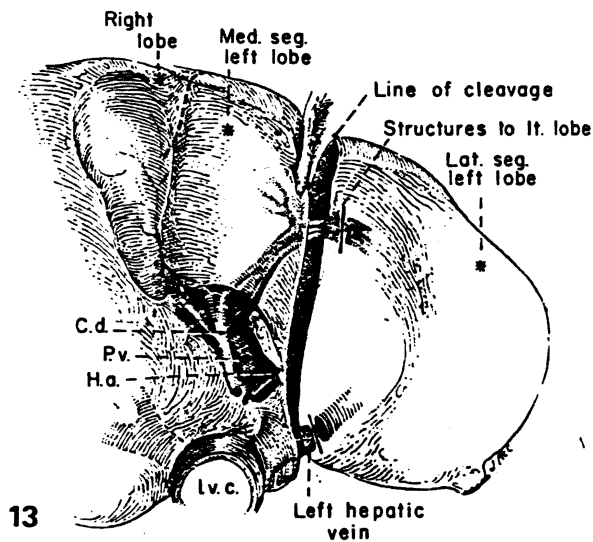
The first true right hepatic lobectomy was performed by Wendell Longmire, Jr. (1965) has attributed the first anatomical left lobectomy to Pettinari (1955).

A right lobectomy removes about 55 per cent of the liver and left lobectomy 45 per cent. When true right or left lobectomy is performed, the gall-bladder must be removed, but the tedious dissection of the left branches of the structures of the portal triad is not necessary. With right lobectomy, the main right hepatic vein is sacrificed before the liver transection, and with left lobectomy the smaller left hepatic vein is incised and sutured. The liver must be split across its thick part with either kind of true lobectomy but this does not create a problem if the plane is a correct one. Tributaries of the central vein are left with the hepatic remnant. As with trisegmentectomy, dead tissue is not deliberately left by the development of a parasegmental plane. However, an attempt

is made to leave the middle hepatic vein with the remnant since it drains both the right and left lobes. Although the raw area with true lobectomy is much greater than after trisegmentectomy, the intrinsic risk of operation is unquestionably less since hepatic failure should be no problem.

LATERAL SEGMENTECTOMY

Because of uncertainties of nomenclature in very old publications, it is difficult to say who performed the first lateral segmentectomy. About 25 years ago, the British surgeon Ronald Raven standardized the operation and popularized precise hilar dissection and ligation of the structure going to the proposed specimen (Raven, 1949). The left hepatic vein is sacrificed, and the liver is split along the falciform ligament. Adequate exposure is usually provided by the left subcostal incision shown in *Illustration 3*.



13

The features of lateral segmentectomy are summarized schematically. In the performance of this operation, the blood supply and duct drainage should be sacrificed well to the left of the falciform ligament and umbilical fissure, as was originally emphasized by Goldsmith and Woodburne (1957) to avoid damaging the structures feeding back to the medial segment. Massive drainage of the wound such as is employed after lobectomy and trisegmentectomy is not usually needed.

(By kind permission of *Surgery Gynec. Obstet.* 141, 429, 1975)

OTHER POSSIBLE RESECTIONS

Although resections of other single or multiple segments or subsegments are theoretically possible and actually have been carried out by McBride and Wallace (1972), by Miller (1974) and by others, we have not performed such procedures. It would be difficult, for example, to justify the isolated removal of the medial segment of the left lobe or the anterior or posterior segment of the right lobe when full lobectomy is so safe and easy.

Mortality and morbidity

Since 1963, the authors have not had an operative death in segmentectomies, right lobectomies or left lobectomies.

No patients required re-operation for postoperative haemorrhage. One subphrenic abscess developed and was drained in a child in whom drainage after trisegmentectomy was inadequate. Although bile-stained fluid was occasionally irrigated in the cavities, persistent bile leakage was found in one patient but this stopped spontaneously.

The question of adjuvant therapy

Since 1972, all patients in whom the resected tumour was proven to be malignant have received systemic (intravenous) chemotherapy. This has been initiated as soon as the wound has shown satisfactory healing and usually continued for 1 year. Such treatment has not appeared to inhibit hepatic regeneration. Patients with hepatoma have received a combination of vincristine, cyclophosphamide and actinomycin D; a variety of agents alone or in combination have been selected in consultation with our oncologists for the other tumours.

Recurrent disease has been treated by resumption or intensification of chemotherapy, local irradiation

and on two occasions by surgical excision. In one patient, a right lower lobectomy of the lung was performed 7 months after trisegmentectomy for an isolated metastasis of colonic origin. In the other case, a recurrence in the residual left lateral segment 14 months after trisegmentectomy was removed by wedge resection. Neither patient has clinical evidence of further recurrence 6 and 12 months later, respectively.

Recent technical innovations

Lin (1960, 1973) has advocated hepatic resection by several techniques which do not require preliminary dissection and control of the vascular and duct structures entering the proposed specimen, nor is early control obtained of the hepatic veins. The mortality rate with these techniques has been low, the operating times have been short and the blood loss has been small, particularly with Lin's adaptation of a special clamp originally described by Storm and Longmire Jr. (1971) to control bleeding from the raw surface. However, Lin's techniques have not been adaptable to the performance of the more extensive trisegmentectomy which is often required to remove a tumour with adequate margins. They probably do not permit even a complete true lobectomy. There were no trisegmentectomies in Lin's series (1973). We have used Lin's methods only occasionally.

Fortner *et al.* (1974) described chilling of the whole liver by infusion techniques developed for liver transplantation. After this preliminary step, the diseased portion of the organ was removed in a bloodless field. A mortality rate of 10 per cent was reported in 29 operations of which at least 26 were lesser procedures than trisegmentectomy. The results in the authors' experience have indicated that even the radical trisegmentectomy can be safely achieved with a far less complicated approach. Since the same is doubtless true for lesser procedures, such as true hepatic lobectomy or segmentectomy, the authors have not employed this approach.

Acknowledgements

This work was supported by research grants MRIS 8118-01 and 7227-01 from the Veterans Administration; by Grant Numbers AM-17260 and AM-07772 from the National Institutes of Health; and by Grant Numbers RR-00051 and RR-00069 from the General Clinical Research Centres Program of the Division of Research Resources, National Institutes of Health.

References

- Alpert, M. E., Uriel, J. and de Nechaud, B. (1968). 'Alpha-fetoglobulin in the diagnosis of human hepatoma.' *New Engl. J. Med.* 278, 984
- Brunschwig, A. (1955). 'The surgery of hepatic neoplasms with special reference to right and left lobectomies.' *XVI Congress de la Societe Internationale de Chirurgie*, Copenhagen. Brussels, Imprimerie Medicale et Scientifique, p. 1122.
- Brunschwig, A. (1963). 'Hepatic lobectomy for metastatic cancer.' *Cancer* 16, 277
- Couinaud, C. (1957). *Le Foie. Etudes Anatomiques et Chirurgicales*. Paris: Masson
- Flanagan, L., Jr. and Foster, J. H. (1967). 'Hepatic resection for metastatic cancer.' *Am. J. Surg.* 113, 551
- Fortner, J. G., Shiu, M. H., Kinne, D. W., *et al.* (1974). 'Major hepatic resection using vascular isolation and hypothermic perfusion.' *Ann. Surg.* 180, 644
- Goldsmith, N. A. and Woodburne, R. T. (1957). 'The surgical anatomy pertaining to liver resection.' *Surgery Gynec. Obstet.* 105, 310
- Healey, J. E., Jr. (1954). 'Clinical anatomic aspects of radical hepatic surgery.' *J. Int. Coll. Surg.* 22, 542
- Healey, J. E., Jr. and Schroy, P. C. (1953). 'Anatomy of the biliary ducts within the human liver.' *Archs Surg.* 66, 599
- Hjortsjö, C. H. (1950). 'The topography of the intrahepatic duct systems.' *Acta Anat.* 11, 599
- Keen, W. (1899). 'Report of a case of resection of the liver for the removal of a neoplasm, with a table of seventy-six cases of resection of the liver for hepatic tumors.' *Ann. Surg.* 30, 267
- Lin, T. -Y. (1973). 'Results in 107 hepatic lobectomies with a preliminary report on the use of a clamp to reduce blood loss.' *Ann. Surg.* 177, 413
- Lin, T. -Y., Chen, K. M. and Liu, T. K. (1960). 'Total right hepatic lobectomy for primary hepatoma.' *Surgery* 40, 1048
- Longmire, W. P., Jr. (1965). 'Hepatic surgery: trauma, tumors and cysts.' *Ann. Surg.* 161, 1
- Lortat-Jacob, J. L. and Robert, H. G. (1952). 'Hepatectomie droite reglee.' *Presse Méd.* 60, 549
- McBride, C. M. and Wallace, S. (1972). 'Cancer of the right lobe of the liver.' *Archs Surg.* 105, 289
- McIndoe, A. H. and Counseller, V. S. (1927). 'The bilaterality of the liver.' *Archs Surg.* 15, 589
- Miller, T. R. (1974). 'Neoplasms of the liver.' In *Abdominal Operations*, Vol. II, Edited by R. Maingot. New York: Appleton-Century-Crofts
- Pack, G. T., Miller, T. R. and Brasfield, R. D. (1955). 'Total right hepatic lobectomy for cancer of the gallbladder.' *Ann. Surg.* 142, 6
- Pack, G. T. and Molander, D. W. (1960). 'Metabolism before and after hepatic lobectomy for cancer.' *Archs Surg.* 80, 685
- Pettinari, V. (1955). *Cong. Soc. Int. Chir.*, p. 1169
- Quattlebaum, J. K. (1953). 'Massive resection of the liver.' *Ann. Surg.* 137, 787
- Raven, R. W. (1949). 'Partial hepatectomy.' *Br. J. Surg.* 36, 397
- Starzl, T. E., Bell, R. H., Beart, R. W. and Putnam, C. W. (1975). 'Hepatic trisegmentectomy and other liver resections.' *Surgery Gynec. Obstet.* 141, 429
- Storm, F. K. and Longmire, W. P., Jr. (1971). 'A simplified clamp for hepatic resection.' *Surgery Gynec. Obstet.* 133, 103
- Wangensteen, O. H. (1951). 'Cancer of the esophagus and stomach.' In *Proceedings of the 3rd National Cancer Conference*. Philadelphia: J. B. Lippincott
- Wilson, S. M. and Adson, M. A. (1976). 'Surgical treatment of hepatic metastases from colorectal cancers.' *Archs Surg.* 111, 330

[The illustrations for this Chapter on Partial Resections of the Liver were drawn by Jean McConnell.]